

Pathophysiological Basis and Rationale for Early Outpatient Treatment of SARS-CoV-2 (COVID-19) Infection

Peter A. McCullough, MD, MPH,^{a,b,c} Ronan J. Kelly, MD,^a Gaetano Ruocco, MD,^d Edgar Lerma, MD,^e James Tumlin, MD,^f Kevin R. Wheelan, MD,^{a,b,c} Nevin Katz, MD,^g Norman E. Lepor, MD,^h Kris Vijay, MD,ⁱ Harvey Carter, MD,^j Bhupinder Singh, MD,^k Sean P. McCullough, BS,^l Brijesh K. Bhambi, MD,^m Alberto Palazzuoli, MD, PhD,ⁿ Gaetano M. De Ferrari, MD, PhD,^o Gregory P. Milligan, MD, MPH,^a Taimur Safder, MD, MPH,^a Kristen M. Tecson, PhD,^b Dee Dee Wang, MD,^p John E. McKinnon, MD,^p William W. O'Neill, MD,^p Marcus Zervos, MD,^p Harvey A. Risch, MD, PhD^q

^aBaylor University Medical Center, Dallas, Tex; ^bBaylor Heart and Vascular Institute, Dallas, Tex; ^cBaylor Jack and Jane Hamilton Heart and Vascular Hospital, Dallas, Tex; ^dCardiology Division, Regina Montis Regalis Hospital, Mondovì, Cuneo, Italy; ^eChrist Advocate Medical Center, Chicago, Ill; ^fEmory University School of Medicine, Atlanta, Ga; ^gJohns Hopkins School of Medicine, Baltimore, Md; ^hCedars Sinai Medical Center, Los Angeles, Calif; ⁱAbrazo Arizona Heart Hospital, Abrazo Health System, Phoenix, Ariz; ^jCarter Eye Center, Dallas, Tex; ^kCardiorenal Society of America, Phoenix, Ariz; ^lUniversity of Texas McGovern Medical School, Houston, Tex; ^mBakersfield Heart Hospital, Bakersfield, Calif; ⁿUniversity of Siena, Le Scotte Hospital Viale Bracci, Siena, Italy; ^oUniversity of Torino, Torino, Italy; ^pHenry Ford Hospital, Detroit, Mich; ^qYale University School of Public Health, New Haven, Conn.

Specialties

Internal Medicine
Critical Care
Nephrology
Cardiology
Electrophysiology
Infectious Diseases
Ophthalmology
Epidemiology
Biostatistics

ABSTRACT

Approximately 9 months of the severe acute respiratory syndrome coronavirus-2 (SARS-CoV-2 [COVID-19]) spreading across the globe has led to widespread COVID-19 acute hospitalizations and death. The rapidity and highly communicable nature of the SARS-CoV-2 outbreak has hampered the design and execution of definitive randomized, controlled trials of therapy outside of the clinic or hospital. In the absence of clinical trial results, physicians must use what has been learned about the pathophysiology of SARS-CoV-2 infection in determining early outpatient treatment of the illness with the aim of preventing hospitalization or death. This article outlines key pathophysiological principles that relate to the patient with early infection treated at home. Therapeutic approaches based on these principles include 1) reduction of reinoculation, 2) combination antiviral therapy, 3) immunomodulation, 4) antiplatelet/antithrombotic therapy, and 5) administration of oxygen, monitoring, and telemedicine. Future randomized trials testing the principles and agents discussed will undoubtedly refine and clarify their individual roles; however, we emphasize the immediate need for management guidance in the setting of widespread hospital resource consumption, morbidity, and mortality.

© 2020 The Authors. Published by Elsevier Inc. This is an open access article under the CC BY-NC-ND license. (<http://creativecommons.org/licenses/by-nc-nd/4.0/>) • *The American Journal of Medicine* (2020) 000:1–7

KEYWORDS: Ambulatory treatment; Anticoagulant; Anti-inflammatory; Antiviral; COVID-19; Critical care; Epidemiology; Hospitalization; Mortality; SARS-CoV-2

US/Italian Multicenter Collaboration

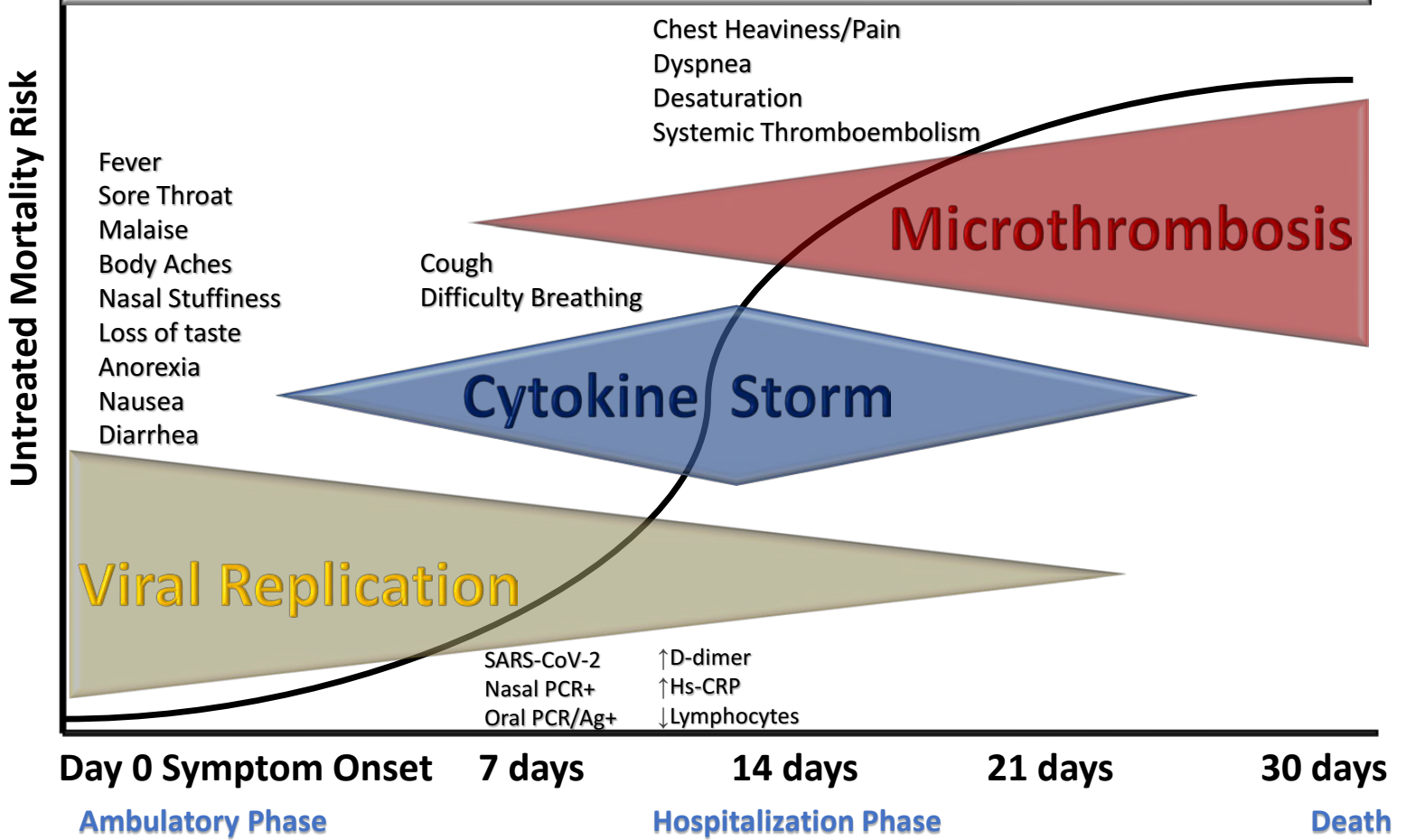
Academic Medical Centers
Public Health
Integrated Health Systems
Community Practice
Biotech Industry

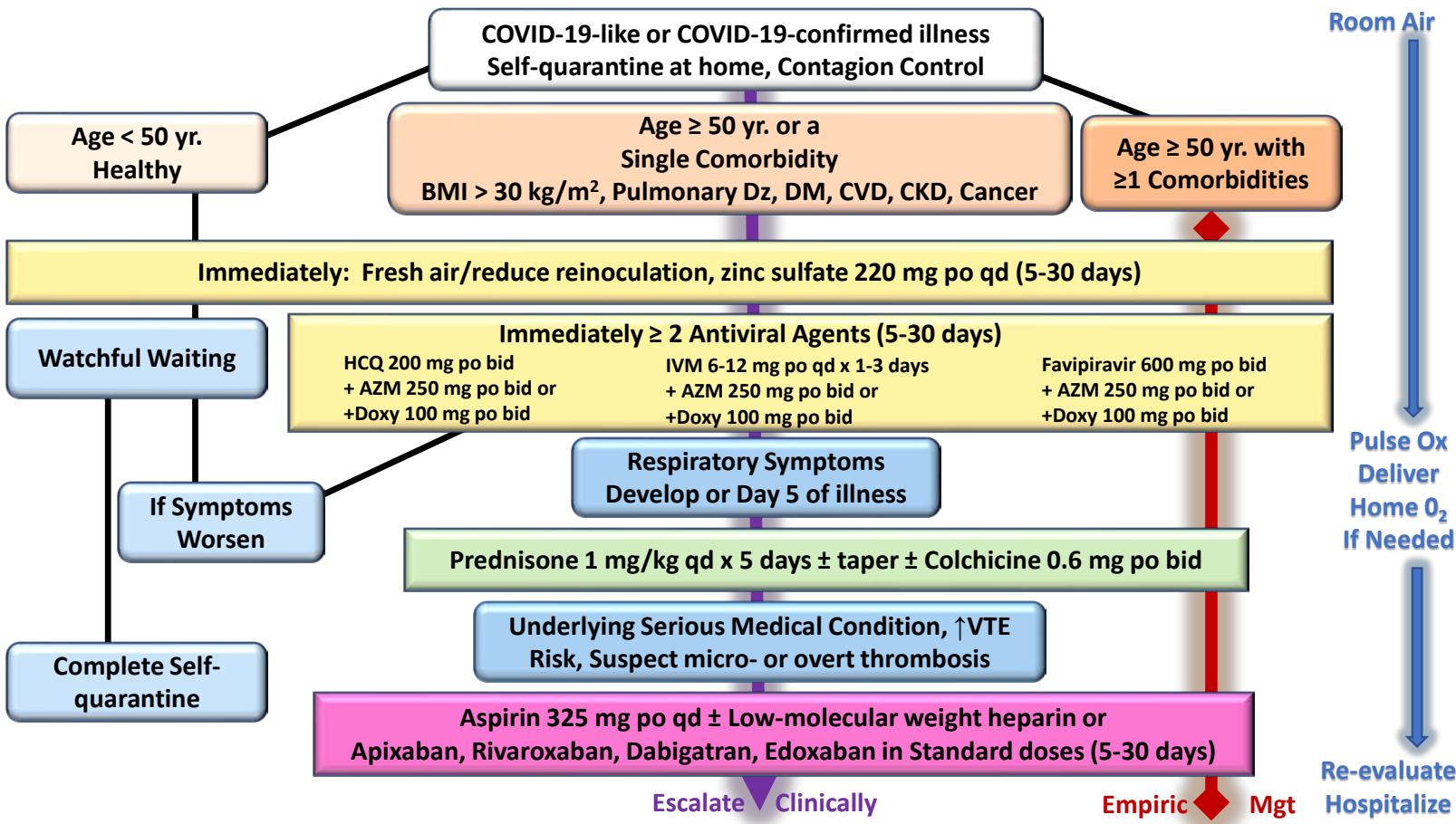
Off-Target Antivirals

McCullough PA, Fourth-Quarter 2020 COVID-19 Drug and Diagnostic Developments A Virtual Conference Monday, November 2nd 2020, 9:00am - 6:00pm CET McCullough PA Proc (Bayl Univ Med Cent). 2020 (in press)

Corticosteroids

Antiplatelet Drugs/Antithrombotics





BMI=body mass index, Dz=disease, DM=diabetes mellitus, CVD=cardiovascular disease, CKD=chronic kidney disease, yr=years, HCQ=hydroxychloroquine, AZM=azithromycin, Doxy=doxycycline, IVM=ivermectin, VTE=venous thrombo-embolic