




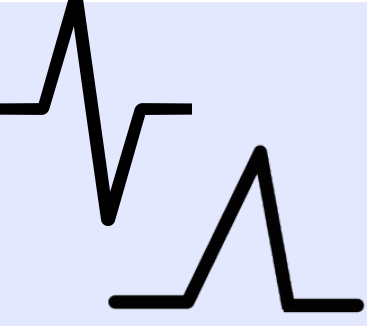












<b>AXIS</b> 	<b>LEAD 1</b>	<b>LEAD 2</b>	<b>LEAD 3</b>	<b>EXAMPLES</b>
<b>NORMAL AXIS</b> <b>0 TO 90</b>				
<b>PHYSIOLOGIC LEFT AXIS</b> <b>0 TO -40</b>				
<b>PATHOLOGIC LEFT AXIS</b> <b>-40 TO -90</b>				<b>ANTERIOR HEMIBLOCK</b>
<b>RIGHT AXIS</b> <b>+90 TO +180</b>				<b>POSTERIOR HEMIBLOCK</b>
<b>EXTREME RIGHT AXIS</b> <b>-90 TO -180</b>				<b>VENTRICULAR IN ORIGIN</b>