


## Original Studies

# A Novel Approach to Percutaneous Removal of Large Tricuspid Valve Vegetations Using Suction Filtration and Venovenous Bypass: A Single Center Experience

Bennet George,<sup>1\*</sup> MD , Anthony Voelkel,<sup>2</sup> MD, John Kotter,<sup>1</sup> MD, Andrew Leventhal,<sup>1</sup> MD, and John Gurley,<sup>1</sup> MD

**Background:** Tricuspid valve surgery has been the de facto standard treatment for tricuspid valve endocarditis (TVE) refractory to medical therapy. It is now possible to remove right-sided vegetations percutaneously using a venous drainage cannula with an extracorporeal bypass circuit. **Objectives:** The purpose of our study is to describe our single-center experience of percutaneous tricuspid valve vegetation removal. **Methods:** We reviewed the perioperative course of 33 consecutive patients with large tricuspid valve vegetations who carried high surgical risk. **Results:** The cohort included 12 males and 21 females over a 40-month period with an average age of 37 years. A preponderance of patients carried an admitted or confirmed diagnosis of injection drug use (72.7%). Average vegetation size was 2.1 +/- 0.7 cm prior to the procedure with a 61% reduction in size after the procedure. All patients survived the procedure and 90.9% survived the index hospitalization. Three patients proceeded to elective tricuspid valve replacement due to worsening severity of tricuspid regurgitation. **Conclusion:** Percutaneous removal of large tricuspid valve vegetations is a safe and effective alternative for patients with TVE who carry high-surgical risk. © 2017 Wiley Periodicals, Inc.

**Key words:** tricuspid valve endocarditis; AngioVac; percutaneous suction filtration; venovenous bypass

## INTRODUCTION

Infective endocarditis presents a major public health concern with a high economic burden on society and health care organizations. Hospitalizations related to endocarditis are steadily increasing, mirroring the rise of prescription opioid, heroin, and overdose epidemics nationally [1,2]. Tookes et al reported a single-center experience with \$11.4 million spent annually in treatment costs for injection drug-related infections with an adjusted mean cost of over \$180,000 for endocarditis-related hospitalizations [3]. Tricuspid valve endocarditis (TVE), specifically, accounts for 10–25% of all cases of endocarditis [4–7]. Regional prevalence trends are also worrisome with both the incidence tricuspid valve involvement and intravenous drug use (IVDU) rising [8].

The management of TVE requires highly individualized care without definite evidence-based guidelines

<sup>1</sup>Department of Cardiovascular Medicine, Gill Heart & Vascular Institute, University of Kentucky Medical Center, Lexington, Kentucky

<sup>2</sup>Department of Cardiovascular Medicine, Ohio State University Wexner Medical Center, Columbus, Ohio

**Conflict of Interest:** AngioDynamics provided funding for the images in this manuscript to be printed in color.

**Authorship Statement:** All authors had full access to the data and participated in the data collection, design and writing of the manuscript. Each author has seen and approved the submitted version.

**\*Correspondence to:** Bennet George, MD, University of Kentucky, Gill Heart Institute, 900 South Limestone, Room 326 Wethington Building, Lexington, KY 40536. E-mail: bennet.george@uky.edu

Received 16 September 2016; Revision accepted 25 March 2017

DOI: 10.1002/ccd.27097

Published online 00 Month 2017 in Wiley Online Library (wileyonlinelibrary.com)

for effective treatment. While medical therapy remains the cornerstone of treatment, it may be inadequate in managing patients with large vegetations (>1 cm), persistent bacteremia despite antimicrobial therapy, fungal lesions, or recurrent septic embolization [9,10]. Surgical treatment, if offered, carries its own drawbacks given the 6–10% operative mortality along with high post-operative morbidity and mortality associated with unique patient characteristics which may cause reinfection of surgically implanted materials [11–13]. Specifically, valvectomy may result in high morbidity related to right ventricular failure while valve replacement increases the risk of valve-related complications and the risk of recurrent endocarditis, especially with IVDU [14–17].

Recent advances in percutaneous techniques make it possible to remove large tricuspid valve vegetations, promoting infectious source control while avoiding the major disadvantages of surgery. Previous case reports have described percutaneous vacuum-assisted removal/debulking of right-sided intracardiac masses [18–22]. We retrospectively reviewed our single-center experience of nonsurgical debridement of tricuspid valve vegetations utilizing the AngioVac (AngioDynamics, Latham, NY) system to better understand this novel approach to TVE care. The AngioVac Circuit and Cannula are indicated for the removal of soft, fresh thrombi, or emboli, during extracorporeal bypass for up to 6 hr.

## MATERIALS AND METHODS

### Study Population

We reviewed 33 patients (12 male and 21 female) over a 40 month period. The decision to offer a percutaneous vegetation filtration (PVF) procedure was a consensus opinion amongst a team of physicians (consisting of a general cardiologist, interventional cardiologist, infectious disease specialist, and cardiothoracic surgeon) who felt that the patients would not do well with medical therapy alone. These patients were typically declined traditional surgical management due to various comorbidities felt to increase the risk of surgery including septic shock, respiratory failure, renal insufficiency, and bleeding tendency. Written informed consent prior to the procedure was obtained from the patient or a surrogate.

### Device Description

The AngioVac venous drainage cannula and the extracorporeal bypass circuit provide suction-assisted removal of endovascular masses (e.g., thrombus, tumor, or vegetation) from the vena cava, right atrium, right ventricle, and pulmonary trunk (Fig. 1). The distal tip

of the large bore inflow cannula has a balloon-actuated, expandable, and funnel-shaped tip (Fig. 2). An inline filter traps intravascular debris while returning blood to the patient and maintaining hemodynamic stability with a veno-venous extracorporeal bypass circuit. No arterial access is required for this circuit.

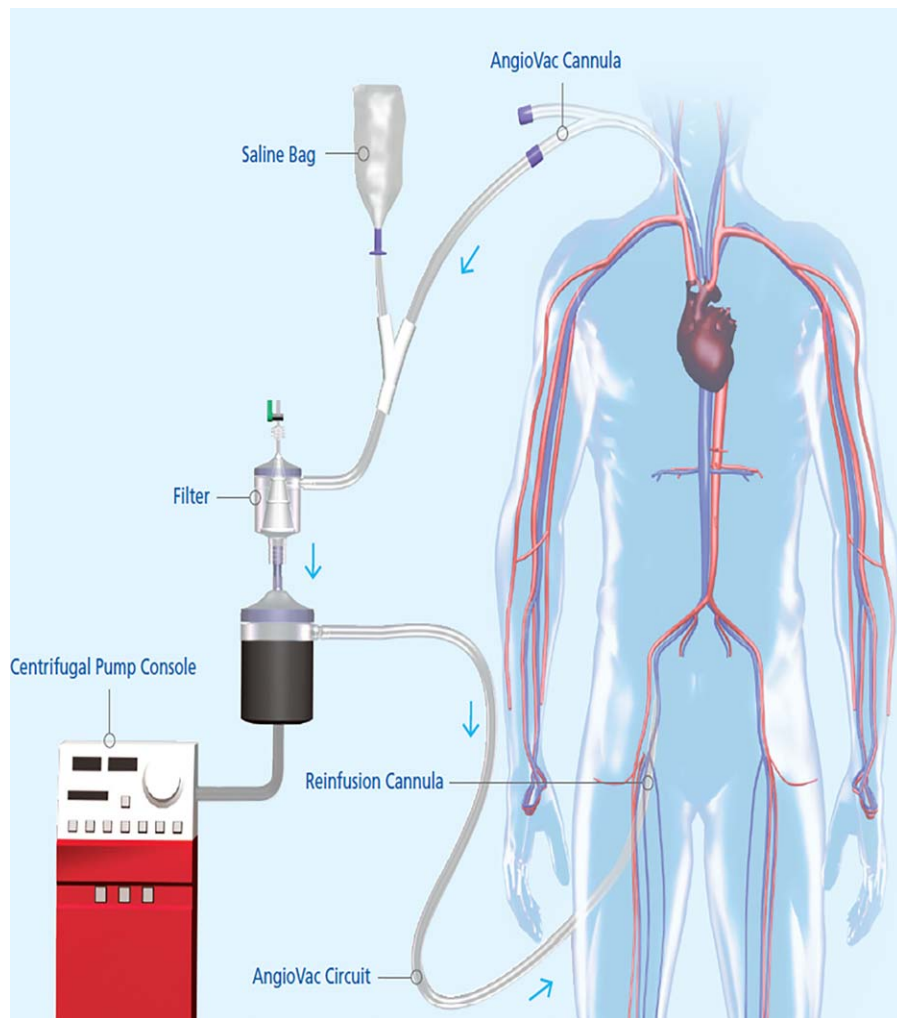
### Procedure Description

All PVF procedures were performed in the cardiac catheterization laboratory under conscious sedation (intravenous midazolam, fentanyl, and ketamine) and local anesthesia (lidocaine infiltration) along with technical support from a perfusionist and intrafacility surgical back-up. Anticoagulation was achieved with unfractionated heparin titrated by point of care activated clotting time targeted to a goal of > 250 sec as measured on a Hemochron® machine. A 17 or 19-French sheath was inserted into the femoral vein followed by insertion of a 26-French GORE® DrySeal (W.L Gore & Associates, Flagstaff, AZ) sheath in the right internal jugular vein. The 22-French AngioVac inflow cannula and its dilator were inserted into the right internal jugular venous sheath over a wire and advanced to the right atrium under direct fluoroscopic guidance. Once the dilator and guidewire were removed, the AngioVac cannula was temporarily clamped and connected to the cardiopulmonary bypass circuit and filter, and the 17-French return cannula was inserted into the femoral venous sheath. Finally, the AngioVac circuit was primed and de-aired. Veno-venous extracorporeal bypass was started with 3–4 liters per minute flow (3000–4000 RPM). Under direct transesophageal or intracardiac echocardiographic monitoring, multiple passes across the tricuspid valve were made to remove the valvular vegetation (Fig. 3).

After satisfactory debulking was achieved (as defined as removal of >1 cm of particulate and/or the inability to remove any additional particulate), the inflow cannula was removed from the internal jugular sheath and the blood from the extracorporeal circuit was purged and returned to the patient via the return cannula. The particulate was collected in a filter and sent for microbiologic analysis. The vascular sheaths were removed and vascular closure was achieved with a “purse-string” suture. The patients were monitored in the catheterization recovery area and subsequently for at least one night in an intensive care unit. Further care was dictated by the patients’ inpatient care team.

### Statistical Analysis

For descriptive purposes, quantitative variables are presented as mean ± standard deviation and categorical variables are summarized as percentages.



**Fig. 1.** The AngioVac cannula and circuit are used with a standard centrifugal pump, bubble trap, and reinfusion cannula. The inflow cannula is a 22-French coil-reinforced cannula. Blood and thrombus/vegetative material flow through the cannula into a filter. The thrombus/vegetation is trapped in the filter while blood is returned to the body through a second 17-French venous cannula. Images courtesy of AngioDynamics, Inc.

## RESULTS

### Preprocedural Patient Characteristics

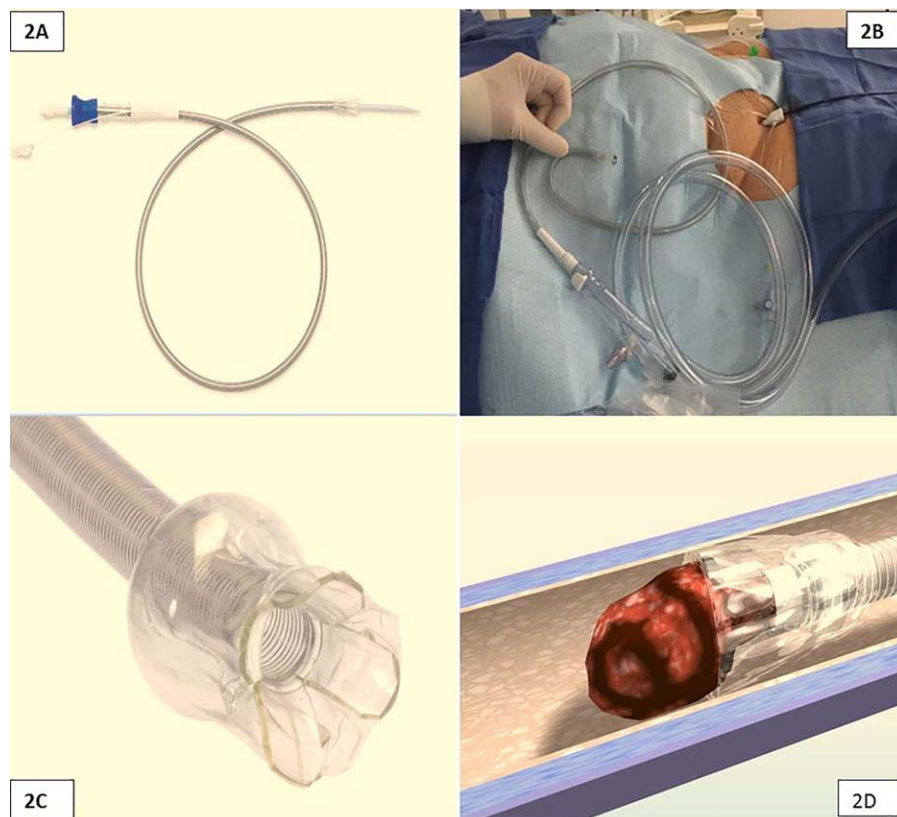
A total of 33 patients were reviewed whose baseline clinical characteristics are summarized in Table I. Mean age was  $37 \pm 12$  years and 33% of the patients were men. Overall, 6.1% had hypertension, 12.1% had diabetes mellitus, 18.2% had left ventricular dysfunction (estimated ejection fraction  $< 50\%$  by echocardiogram), 69.7% were tobacco users, 57.6% had hepatitis C, and 72.7% had a confirmed or admitted history of substance abuse. Indwelling catheters were present in 6.1% of patients. Pacemaker/defibrillator leads were also present in 6.1% of patients. All patients had native TVE aside from one patient who had a prior bioprosthetic valve.

Most patients (75.8%) grew *Staphylococcus* organisms with 14 patients growing methicillin-resistant

*Staphylococcus aureus* (MRSA) and 11 patients growing methicillin-sensitive *S. aureus* (MSSA). Five patients had polymicrobial infections with an average of 3 organisms per patient. Five patients had fungemia, all growing various *Candida* species. Roughly half (54.5%) of the patients had active bacteremia with a positive blood culture within 48 hours of the procedure. The average size of the vegetations as measured by echo was  $2.12 \pm 0.7$  cm in the longest dimension. Severe tricuspid regurgitation was appreciated by echocardiogram in 18.1% of patients. The average time from diagnosis to procedure was  $10 \pm 9$  days.

### Postprocedure Outcomes

A summary of clinical outcomes is displayed in Table II. All patients survived the PVF procedure and



**Fig. 2.** The AngioVac venous drainage cannula is a 22-French coil-reinforced cannula (A) designed with a balloon-actuated, funnel-shaped distal tip, which creates a flow vortex that facilitates aspiration of thrombotic material into the cannula (C and D). Images courtesy of AngioDynamics, Inc. Thermal modification of the cannula into a “candy cane” shape helps to facilitate greater steerability through the tricuspid valve (B).

30 (90.9%) patients survived the index hospitalization. The only periprocedural complication noted was the development of cardiac tamponade requiring emergency pericardiocentesis in one patient.

With regard to the three deaths, one involved a 24-year-old male with previous bioprosthetic tricuspid valve infected with MRSA, *Enterococcus faecium*, *Acinetobacter baumannii*, and *Candida glabrata*, who injected drugs intravenously during the index hospitalization, and ultimately passed away 22 days after PVF from severe sepsis. The second death occurred in a 48-year-old female with MRSA infection who was later diagnosed with an extensive epidural abscess extending from C1 to T1 with spinal cord compression and extensive spinal cord edema in whom the family decided to withdraw care 18 days after the PVF. The last death involved a 69-year-old male who had been bedbound for several years prior to becoming septic. He developed an aortic valve perforation and spinal osteomyelitis, was not an acceptable surgical candidate, and subsequently died.

Echocardiograms were performed in 23 of the patients after the procedure was complete. Patients

typically had an echocardiogram  $4 \pm 3$  days before PVF but  $13 \pm 15$  days would elapse before a subsequent echo was performed. While 43.5% of patients with a post-PVF echocardiogram demonstrated a worsening severity of tricuspid regurgitation, only three (9.1%) proceeded to elective tricuspid valve replacement after medical stabilization and clearance of blood cultures. Figure 4 illustrates the changes in the degree of tricuspid regurgitation before and after the procedure. As expected, 82.6% of patients with a postprocedure echocardiogram demonstrated a visible persistent vegetation. The average vegetation size on follow-up echocardiogram was  $0.82 \pm 0.5$  cm in longest dimension, representing an average vegetation size reduction of 1.3 cm (61%). Five patients had follow-up blood cultures demonstrating persistent bloodstream infection, three of which were actively infected at the time of the PVF procedure. No patients required surgery because of progression of infection or persistent/recurrent bacteremia.

The average hemoglobin in the patients at the time of the procedure was 8.52 g/dL. On post-PVF day one, the average reduction in hemoglobin was  $0.4 \pm 1$  and

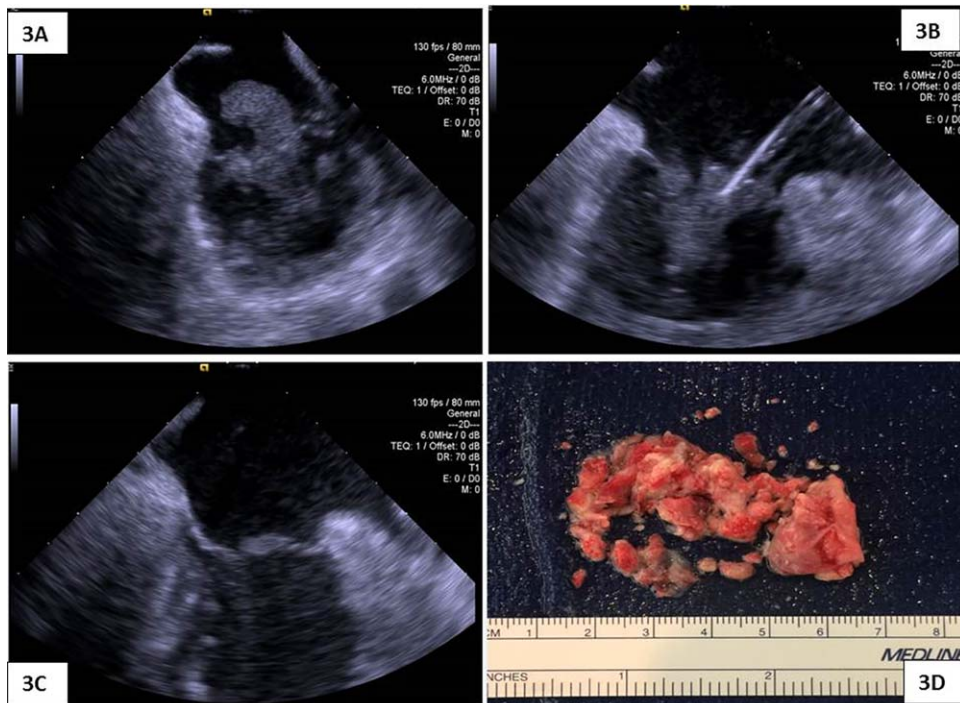


Fig. 3. Tricuspid valve vegetation imaged with intracardiac echo (ICE). Insert A shows a 2.5 × 1.7 cm tricuspid valve vegetation on ICE before the start of the debulking procedure. Intraoperative ICE imaging shows suction removal of the tricuspid valve vegetation during the procedure (B) and immediately after (C). The gross specimen is shown after removal from the filter (D).

TABLE I. Baseline Clinical Characteristics of Patients

Variable	
Age (years)	37 ± 12
Male (%)	36.3%
Hypertension	6.1%
Diabetes mellitus, type 2	12.1%
Left ventricular dysfunction	18.2%
Tobacco abuse	69.7%
Hepatitis C	57.6%
Pacemaker/defibrillator present	6.1%
Indwelling catheter present	6.1%
Bioprosthetic tricuspid valve	3.0%
History of polysubstance abuse	72.7%
Average vegetation size (cm)	2.1 ± 0.7
Severe tricuspid regurgitation	18.1%

TABLE II. Clinical Outcomes of Patients after Debulking Procedure

Variable	
Death from any cause during index hospitalization	9.1%
Proceeded to tricuspid valve surgery	9.1%
Subsequent bacteremia	15.2%
Persistent vegetation	82.6%
Average vegetation size (cm)	0.82 ± 0.5
Worsening degree of tricuspid regurgitation	43.5%
Average hemoglobin drop one-day postprocedure (g/dL)	0.40 ± 1.0
Average hemoglobin drop one-week postprocedure (g/dL)	0.11 ± 1.8
Transfusion required	33.0%
Average units blood per patient requiring transfusion	2.7
Access-site related bleeding (n)	1.0

0.11 ± 1.8 g/dL after one week. One-third of the patients (33%) required a blood transfusion within the first week after PVF. On average, 2.7 units of packed red blood cells were needed for a patient requiring a transfusion. Only one patient requiring transfusion, had access-site related bleeding.

DISCUSSION

Right-sided endocarditis accounts for 10–25% of all endocarditis cases [4–7]. The optimal management of

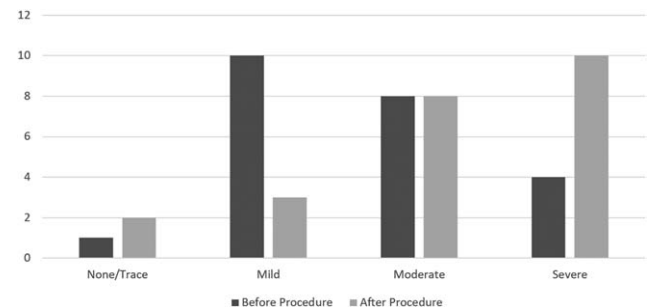


Fig. 4. Tricuspid regurgitation before and after procedure.

patients presenting with tricuspid valve vegetations that persist despite appropriate medical therapy represents a significant therapeutic challenge. Current guidelines for surgical intervention in patients with endocarditis do not include right-sided lesions, and alternative therapies need study to supplement conventional surgical approaches [23]. The unique risk factors accompanying this patient population (e.g., increased risk of reinfection of prosthetic surgical materials) confer increased morbidity with cardiac surgery. While vacuum-assisted debulking of tricuspid valve vegetations has been described in case reports before [18–20,22], this is the largest published series using this novel approach.

Although TVE carries lower risk of mortality when compared with endocarditis involving other valves, mortality is still high, ranging from 15.4 to 37% [4,6,11,24,25]. Institutionally, mortality for TVE has ranged from 25 to 28% [8]. Vegetation size is a major predictor of prognosis. Vegetation sizes >2 cm carried 25% mortality compared with 3.8% in a retrospective review of 220 patients with TVE [24]. In another series of 21 patients with TVE, vegetations <1 cm in size had a cure rate of 100% while vegetations >1 cm were cured only 60% of the time [9]. Comparatively, inpatient mortality was 9.1% in our patient cohort, which, despite the small sample size, appears substantially less than what is reported in the literature.

While many patients developed a worsening severity of tricuspid regurgitation, right-sided valvular dysfunction is often well-tolerated and right-sided valvectomy resulting in wide open regurgitation may be the operation of choice among injection drug users [14]. The long-term consequences of prolonged open regurgitation remain unknown and serial follow-up would be needed.

Blood loss appears to have been a significant complication related PVF. While the average hemoglobin difference of  $0.11 \pm 1.8$  g/dL from the day of PVF to one week later appears minimal, 33% of the cohort required blood transfusion. The majority of blood loss, however, was not directly related to the procedure itself, as only one patient had access-site bleeding. It is important to note that the majority of the patients were septic and coinfecting with hepatitis C making disseminated intravascular coagulation, thrombocytopenia, and coagulopathy related to liver dysfunction significant clinical challenges during inpatient management.

All limitations of a retrospective study design apply to this study as well. The sample size was small and the study was conducted at a single center. Furthermore, there was no control group available for comparison. As a result, our findings may not be generalizable to different populations. Another potential limitation of the study is the lack of data detailing the extent of

pulmonary septic emboli caused by the procedure. Nonetheless, this current dataset represents the largest series of patients treated with vacuum-assisted suction filtration and describes the successful use of the Angio-Vac device as a potential alternative to tricuspid valve surgery. By debulking the infectious site, there is potential for a lower microbial burden leading to more effective antimicrobial therapy. Future randomized, controlled trials are needed to validate our assertions.

## CONCLUSION

Right-sided endocarditis is an infectious disease carrying significant morbidity and mortality. Percutaneous removal using suction filtration and veno-venous bypass may provide a safe alternative to open heart surgery for removal of large tricuspid valve vegetations. Further evaluation is warranted regarding this potentially paradigm-shifting alternative to open heart surgery.

## REFERENCES

1. Wurcel AG, Anderson J, Chui KKH, Skinner S, Knox TA, Snyderman DR, Stopka TJ. Increasing Infectious Endocarditis Admissions Among Young People Who Inject Drug. *Open Forum Infect Dis* 2016;3.
2. Cooper HL, Brady JE, Ciccarone D, Tempalski B, Gostnell K, Friedman SR. Nationwide increase in the number of hospitalizations for illicit injection drug use-related infective endocarditis. *Clin Infect Dis* 2007;45:1200–1203.
3. Tookes H, Diaz C, Li H, Khalid R, Doblecki-Lewis S. A Cost Analysis of Hospitalizations for Infections Related to Injection Drug Use at a County Safety-Net Hospital in Miami, Florida. *PLoS One* 2015;10:e0129360.
4. Murdoch DR, Corey GR, Hoen B, Miro JM, Fowler VG, Jr., Bayer AS, Karchmer AW, Olaison L, Pappas PA, Moreillon P, Chambers ST, Chu VH, Falco V, Holland DJ, Jones P, Klein JL, Raymond NJ, Read KM, Tripodi MF, Utili R, Wang A, Woods CW, Cabell CH; and International Collaboration on Endocarditis-Prospective Cohort Study. Clinical presentation, etiology, and outcome of infective endocarditis in the 21st century: the International Collaboration on Endocarditis-Prospective Cohort Study. *Arch Intern Med* 2009;169:463–473.
5. Heiro M, Helenius H, Makila S, Hohenthal U, Savunen T, Engblom E, Nikoskelainen J, Kotilainen P. Infective endocarditis in a Finnish teaching hospital: A study on 326 episodes treated during 1980–2004. *Heart* 2006;92:1457–1462.
6. Duval X, Delahaye F, Alla F, Tattevin P, Obadia JF, Le Moing V, Doco-Lecompte T, Celard M, Poyart C, Strady C, Chirouze C, Bes M, Cambau E, Iung B, Selton-Suty C, Hoen B, Group AS. Temporal trends in infective endocarditis in the context of prophylaxis guideline modifications: Three successive population-based surveys. *J Am Coll Cardiol* 2012;59:1968–1976.
7. Hoen B, Alla F, Selton-Suty C, Beguinot I, Bouvet A, Briancon S, Casalta JP, Danchin N, Delahaye F, Etienne J, Le Moing V, Leport C, Mainardi JL, Ruimy R, Vandenesch F; Association pour l'Etude et la Prevention de l'Endocardite Infectieuse Study

- G. Changing profile of infective endocarditis: results of a 1-year survey in France. *JAMA* 2002;288:75–81.
8. Seratnahaei A, Leung SW, Charnigo RJ, Cummings MS, Sorrell VL, Smith MD. The changing 'face' of endocarditis in Kentucky: An increase in tricuspid cases. *Am J Med* 2014;127:786 e1–786.
  9. Robbins MJ, Frater RW, Soeiro R, Frishman WH, Strom JA. Influence of vegetation size on clinical outcome of right-sided infective endocarditis. *Am J Med* 1986;80:165–171.
  10. Kang DH, Kim YJ, Kim SH, Sun BJ, Kim DH, Yun SC, Song JM, Choo SJ, Chung CH, Song JK, Lee JW, Sohn DW. Early surgery versus conventional treatment for infective endocarditis. *N Engl J Med* 2012;366:2466–2473.
  11. Gaca JG, Sheng S, Daneshmand M, Rankin JS, Williams ML, O'Brien SM, Gammie JS. Current outcomes for tricuspid valve infective endocarditis surgery in North America. *Ann Thorac Surg* 2013;96:1374–1381.
  12. Thourani VH, Sarin EL, Kilgo PD, Lattouf OM, Puskas JD, Chen EP, Guyton RA. Short- and long-term outcomes in patients undergoing valve surgery with end-stage renal failure receiving chronic hemodialysis. *J Thorac Cardiovasc Surg* 2012;144:117–123.
  13. Kamalakannan D, Pai RM, Johnson LB, Gardin JM, Saravolatz LD. Epidemiology and clinical outcomes of infective endocarditis in hemodialysis patients. *Ann Thorac Surg* 2007;83:2081–2086.
  14. Arbulu A, Holmes RJ, Asfaw I. Surgical treatment of intractable right-sided infective endocarditis in drug addicts: 25 years experience. *J Heart Valve Dis* 1993;2:129–137. discussion 138-9.
  15. Stern HJ, Sisto DA, Strom JA, Soeiro R, Jones SR, Frater RW. Immediate tricuspid valve replacement for endocarditis. Indications and results. *J Thorac Cardiovasc Surg* 1986;91:163–167.
  16. Carozza A, Della Corte A, Ursomando F, Cotrufo M. The choice of valve prosthesis for infective endocarditis in intravenous drug users: Between evidence and preference. *Ann Thorac Surg* 2008;85:1141. author reply 1142.
  17. Kaiser SP, Melby SJ, Zierer A, Schuessler RB, Moon MR, Moazami N, Pasque MK, Huddleston C, Damiano RJ, Jr., Lawton JS. Long-term outcomes in valve replacement surgery for infective endocarditis. *Ann Thorac Surg* 2007;83:30–35.
  18. Divekar AA, Scholz T, Fernandez JD. Novel percutaneous transcatheter intervention for refractory active endocarditis as a bridge to surgery-angiovac aspiration system. *Catheter Cardiovasc Interv* 2013;81:1008–1012.
  19. Todoran TM, Sobieszczyk PS, Levy MS, Perry TE, Shook DC, Kinlay S, Davidson MJ, Eisenhauer AC. Percutaneous extraction of right atrial mass using the Angiovac aspiration system. *J Vasc Interv Radiol* 2011;22:1345–1347.
  20. Patel N, Azemi T, Zaeem F, Underhill D, Gallagher R, Hagberg R, Sadiq I. Vacuum assisted vegetation extraction for the management of large lead vegetations. *J Card Surg* 2013;28:321–324.
  21. Dudy Y, Kronzon I, Cohen HA, Ruiz CE. Vacuum thrombectomy of large right atrial thrombus. *Catheter Cardiovasc Interv* 2012;79:344–347.
  22. Makdisi G, Casciani T, Wozniak TC, Roe DW, Hashmi ZA. A successful percutaneous mechanical vegetation debulking used as a bridge to surgery in acute tricuspid valve endocarditis. *J Thorac Dis* 2016;8:E137–E139.
  23. Nishimura RA, Otto CM, Bonow RO, Carabello BA, Erwin JP, 3rd, Guyton RA, O'Gara PT, Ruiz CE, Skubas NJ, Sorajja P, Sundt TM, III, Thomas JD; American College of Cardiology/American Heart Association Task Force on Practice Guidelines. 2014 AHA/ACC guideline for the management of patients with valvular heart disease: Executive summary: A report of the American College of Cardiology/American Heart Association Task Force on Practice Guidelines. *J Am Coll Cardiol* 2014;63:2438–2488.
  24. Martin-Davila P, Navas E, Fortun J, Moya JL, Cobo J, Pintado V, Quereda C, Jimenez-Mena M, Moreno S. Analysis of mortality and risk factors associated with native valve endocarditis in drug users: The importance of vegetation size. *Am Heart J* 2005;150:1099–1106.
  25. Cabell CH, Jollis JG, Peterson GE, Corey GR, Anderson DJ, Sexton DJ, Woods CW, Reller LB, Ryan T, Fowler VG, Jr. Changing patient characteristics and the effect on mortality in endocarditis. *Arch Intern Med* 2002;162:90–94.