

OPHTHALMIC HOSPITALIST INTEREST GROUP

NEWSLETTER

Donna Kim, MD | Maggie Hymowitz, MD

Announcements

New AAO/OHIG Online Community

We are excited about a new interactive online platform for OHIG members on AAO's Community website. Launch date is **Wed July 14th**. Details coming!

AAO Meeting 2021

Save the date for the **OHIG Meet and Greet** at the AAO meeting, **Sat Nov 13th** at 4:00pm CDT.

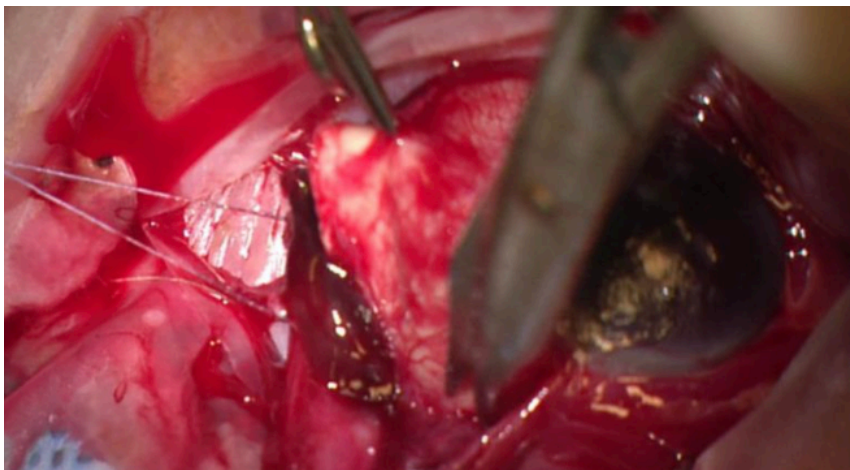
Hospitalist Positions

Interested in becoming an ophthalmic hospitalist? Check out these open positions!

- 1) [UC Davis](#)
- 2) [Ohio State University](#)
- 3) [Univ of Florida](#)

ASOT Meeting Video

Congratulations to OHIG members **Grant Justin, Fasika Woreta**, and **James Auran** for their work at The American Society of Ophthalmic Trauma meeting. [Click here](#) to view.



Articles

[Open Globe Injury in COVID-19 Patient: Lessons Learned, Retina Today, May 2020](#)

An interesting article highlighting challenges of urgent surgical care for COVID positive patients along with suggested PPE for the OR.

[Effect of Time To Primary Repair on Final Visual Outcome After Open Globe Injury, BJO, Jan 2019](#)

A study showing the benefit of early surgical repair for ruptured globes in terms of its impact on final visual acuity.

[Antibiotic Prophylaxis for Endophthalmitis and Demographics of Hospital Stay After Open Globe Repair, IOVS, April 2010](#)

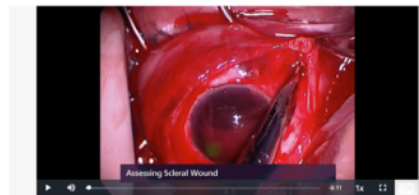An ARVO abstract looking at antibiotic regimens for open globe endophthalmitis prophylaxis and ocular factors associated with longer hospital admissions.



PEARLS

AAO Open Globe Video

Repair of the Open Globe: Scleral Laceration and Intraoperative Considerations



By Sheri L. DeMartelaere, MD, FACS

A helpful surgical video for residents featuring OHIG member **Sheri DeMartelaere**.
[Click here](#) to view

Eyes for Ears Podcasts

EYES FOR EARS



An OKAPS Review Podcast for Residents

Check out these fun podcast videos which include ocular trauma and many other high yield topics for residents.
[Click here](#) to view

CONSULT ROUNDS



You are the on-call ophthalmologist for a Level I trauma center. You receive a page about a 43 year old male who sustains a ruptured globe after being involved in an altercation.

His vision is 20/50 in the affected eye with a visible flat AC and 4mm corneal limbal laceration with mild uveal prolapse. There is no APD by reverse. Examination of the other eye is wnl. He has no other significant injuries.

In preparation for OR, the patient undergoes routine pre-op COVID testing which happens to come back positive. The patient has no symptoms. You and your OR staff wonder what additional precautions you should take while operating for this case.

Case Comments:

COVID testing has now become a standard part of pre-op evaluation - and in the majority of situations negative testing is required for OR clearance. However, situations arise when urgent eye surgery is needed for a patient who is COVID positive.

How will you and your OR staff prepare?

Image source:

Open Globe Injury in COVID-19 Patient: Lessons Learned, Retina Today, May 2020

Open Globe Survey Questions

Q1: What precautions are you using for globe repairs on COVID+ patients in the OR?

- A) N95
- B) Goggles
- C) Face Shield
- D) Head Covering
- E) PAPR
- F) We defer surgery in these patients
- G) Nothing additional since all our providers are vaccinated
- G) Other:

Q2: When do you typically perform globe repairs at your institution on weekdays?

- A) During regular business hours
- B) Between 5pm-12am
- C) Between 12am-7am
- D) Globe repairs are given priority over routine cases
- E) Other

Q3: Do you routinely use prophylactic PRE-operative systemic antibiotics for globe repairs?

- A) Yes
- B) No

If yes, which antibiotics?

Q4: Do you routinely use prophylactic POST-operative systemic antibiotics for globe repairs?

- A) Yes
- B) No

If yes, which antibiotics?

[Click here](#) to access the Monkey Survey - thank you for your responses!