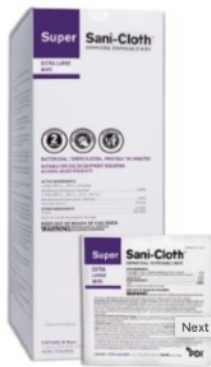

Donna Kim, MD | Maggie Hymowitz, MD



Individual Sani Wipe Packets



Losing precious time on consults searching for wipes to sanitize your equipment? Bring your own individual wipes which easily store in the consult bag.

[Click Here](#) for more info

Consult Sign Out List

For those who utilize EHR, consider creating a shared "consult list" which can keep track of patients and help ensure reliable patient hand offs. This list can be shared with relevant attendings, fellows, residents, and medical students.

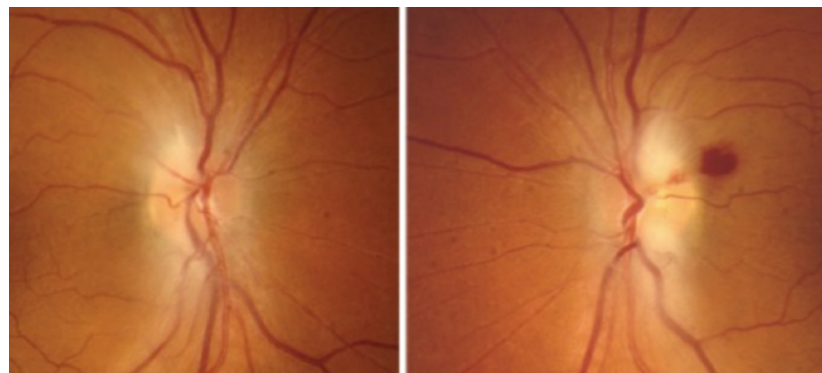
See page 4 for example.

CONSULT ROUNDS

You are consulted about a 53 year old female with a history of metastatic Breast CA involving the lung, stomach, and peritoneum. She is admitted to the hospital for malignant small bowel obstruction (SBO) and reports a recent history of fatigue, weakness, frequent vomiting, and decreased oral intake. Her review of systems is also notable for bilateral blurry vision OD>OS, for which ophthalmology is consulted.

On exam the patient appears slightly confused and is slow to respond to questions. Her general movements are also slowed. Her visual acuity is 20/400 OD and 20/50 OS with decreased color vision OU. Her pupils are reactive without APD. Her extraocular movements are full with slow upgaze and endgaze nystagmus OU. Her anterior exam is otherwise unremarkable. Dilated fundusoscopic exam is notable for blurring temporal optic disc margins OU with a large disc hemorrhage OS.

Representative Case Photo:



Given her ocular findings of decreased visual acuity, color vision, and temporal disc swelling, a diagnosis of infiltrative vs nutritional optic neuropathy was considered. She underwent MRI imaging of the brain and orbit which was normal. Laboratory work up was notable for low Vitamin B1 levels. She was treated with high dose IV thiamine with subsequent dramatic improvement in her mental status and vision after 3 days.

Case Comments:

Nutritional optic neuropathy can be seen in conditions leading to poor intake or malabsorption, including alcoholism, starvation, or

Pandemic Projects

COVID-19 got you down? Make the most of it with a personal project that can be meaningful for you, your family, and others.

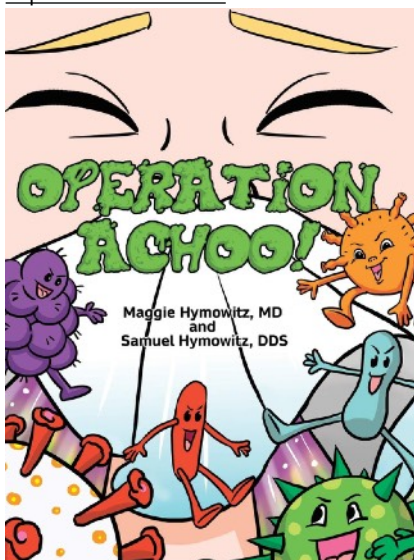
Here are some exciting projects that Maggie Hymowitz has done!

Surgical Scrub Cap Drive



Maggie and her family made 250 surgical scrub caps during the pandemic. With the support of other ophthalmologists, they fundraised over \$1200 for the AAO Surgical Scope Fund

Operation Achoo!



Maggie and her father co-authored a children's book emphasizing hand washing as a fun way to inspire kids to stay safe during COVID. [Check it out!](#)

malignancies. Wernicke's Encephalopathy can also be present.

This patient had remarkable recovery and serves a great reminder of how dietary supplementation can be essential for vision. We are what we eat – or in this case what we do not eat.

Selected Articles:

[Thiamine-Deficient Optic Neuropathy Associated with Wernicke's Encephalopathy in Patients with Chronic Diarrhea](#)

Representative Case Photo Source:

[Visual Loss and Optic Nerve Head Swelling in Thiamine Deficiency Without Prolonged Dietary Deficiency](#)

* Special thanks to OHIG member Dr. Ella Suyeon Yu for sharing this very interesting case! She is currently a resident at Northwell Health in NY.

Sample Consult Sign Out List for EHR

Name, Age, Sex, Location

MRN

Admission Diagnosis





Dilation Clearance

Hand Off To Do's

Primary Service

First Call Pager (for updates)

Cosign Confirmation

CEI Consult List 7 Patients						
Patient ▲	MRN	Diagnosis	Handoff To Do	Service	First Call	Cosign Notes
Patient A 23 years/Male ED/Room 15	011111111	ruptured globe	[] OR tomorrow with Dr. Bailey - time TBD, likely after 1pm [x] priority covid sent (should...	—	Ipt Ed #4-7551	—
Patient B 78 years/Female ED/Room 28	011111111	Pneumocephalus [G93.89]	[] 10/20 DFE	ENT	Ann M Wood, PA-C	
Patient C 28years/Female Neuro ICU/Room 4	011111111	Visual loss [H54.7]	[] dilate and see with Brittini at lunch on 10/19	Medicine	Julia A Frey, PA-C	
Patient D 43years/Female COVID ward/Room 15	011111111	Congenital hydrocephalus (HCC) [Q03.9]	[] staff 10/20	Neurosurgery	Ipt Peds Neurosurgery Np #14421	
Patient E 43years/Male 5C/Room 22	011111111	Pancytopenia (HCC) [D61.818]	[] 10/20 repeat DFE	Hematology & Oncology	Lori Morgan, MD	—
Patient F 79years/Male 8C/Room 12	011111111	Gunshot injury, initial encounter [W34.00XA]	[] 10/19 t/b plastics and NSG	Trauma Surgery	Ipt Tsicu #15579	
Patient G 12 years/Male Children's Hospital/Room 10	011111111	Hypertensive heart failure (HCC) [I11.0]	Follow up on 10/20/20 regarding discharge plan (will either see Brittini on 10/20 or Thomas...	Cardiology	Emily J Armstrong, PA-C	