

OPHTHALMIC HOSPITALIST INTEREST GROUP NEWSLETTER

Donna Kim, MD | Maggie Hymowitz, MD

AAO Webinar

Friendly reminder about the upcoming AAO Webinar on "The Ophthalmic Hospitalist". Featured topics will include chairman advice on creating positions, model examples being used in the US, consult based teaching, and adaptations for COVID-19. There will also be a live Q&A. We welcome all OHIG members to share their own expertise.

Please join us on **Thursday Oct 8th at 8pm EST/5pm PST**. Pre-registration required.

[Click here](#) to register

PPE Survey Results

Thank you for participating in last month's survey about PPE use at your institution. It appears that many of us are routinely wearing an N95 mask for all consults among other PPE.

Results are available at the end of this newsletter

Using your voice
shouldn't mean
losing your vision.

#NoRubberBullets #NotOneMoreEye

© 2020 American Academy of Ophthalmology

Articles

[Rubber Bullets and Responsibilities - EyeNet, June 2020](#)

A thoughtful opinion supported by the AAO regarding ocular injuries caused by rubber bullets during protest demonstrations.

[Ocular Trauma During COVID-19 Stay at Home Orders - CO Ophthalmology, Sept 2020](#)

A nice review of ocular trauma characteristics in the ER during stay at home orders during the COVID-19 pandemic.

[A Measured Approach to Inpatient Ophthalmologic Screening in the COVID-19 Era - Ophthalmology, In Press, 2020](#)

An interesting AAO editorial looking at the utility of existing screening guidelines for hospitalized patients with various systemic conditions such as Fungemia during the COVID pandemic.


* Click on links for articles, PDF copies are also attached to email



PEARLS

Dirty Instrument Case

Trauma consults can require bedside surgical procedures such as eyelid laceration repair and emergent lateral canthotomy cantholysis. We recommend making sure your consult bag has a dedicated container for used instruments to help prevent self-injuries and avoid damaged or lost items.

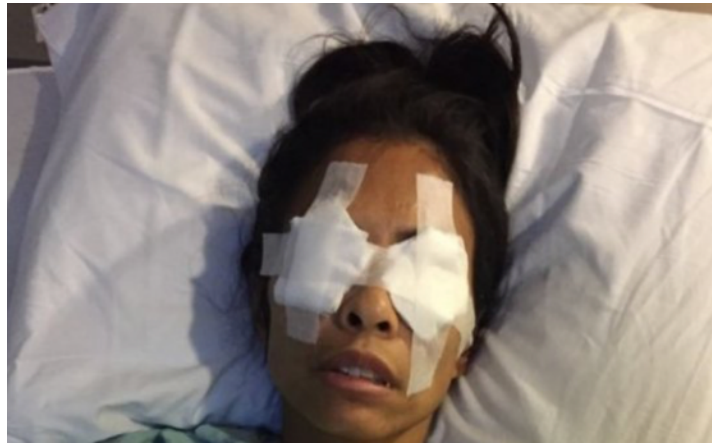

Open Globe Update

It's still early in the academic year and a good time to review trauma management with residents. This is a nice updated review on open globe injuries from the AAO which can be shared with trainees.

[Open Globe Injury: Assessment and Preoperative Management, EyeNet, August 2020](#)

CONSULT ROUNDS



You are consulted about a 31 year old female with a history of Schizoaffective Disorder who is brought to the ER by ambulance after being found roaming the street and pulling at her eye. She tells ER providers that “children are in danger unless I remove my eye” and “I must save them”.

You see the patient at bedside, she is remarkably calm. Your exam is notable for a left ruptured globe with axial proptosis and a large cornea scleral laceration with uveal prolapse. The right globe is intact with no signs of self induced trauma.

The patient is taken to the OR for ruptured globe repair of the left eye. Post-operatively she is evaluated by psychiatry who places her on a medical hold. The patient remains calm and is transferred to a hospital room with soft restraints and a sitter.

A few hours later you are paged by the on-call ophthalmology resident who informs you of terrible news. The patient has ruptured her good remaining right eye. Her soft restraints had been briefly loosened during a meal during which she suddenly grabbed her eye despite the sitter's best attempt to stop her.

The patient went back to the OR later that day for a second globe repair. Her visual course was extremely guarded. She ultimately underwent bilateral enucleation due to poor visual potential and ongoing attempts to remove her eyes even while blind.

Case Comments:

Self induced ocular trauma can be a memorable consult. Bilateral involvement is not uncommon. These cases are challenging to navigate since patients may struggle with significant underlying psychiatric disease and require collaborative multidisciplinary care.

Selected Articles:

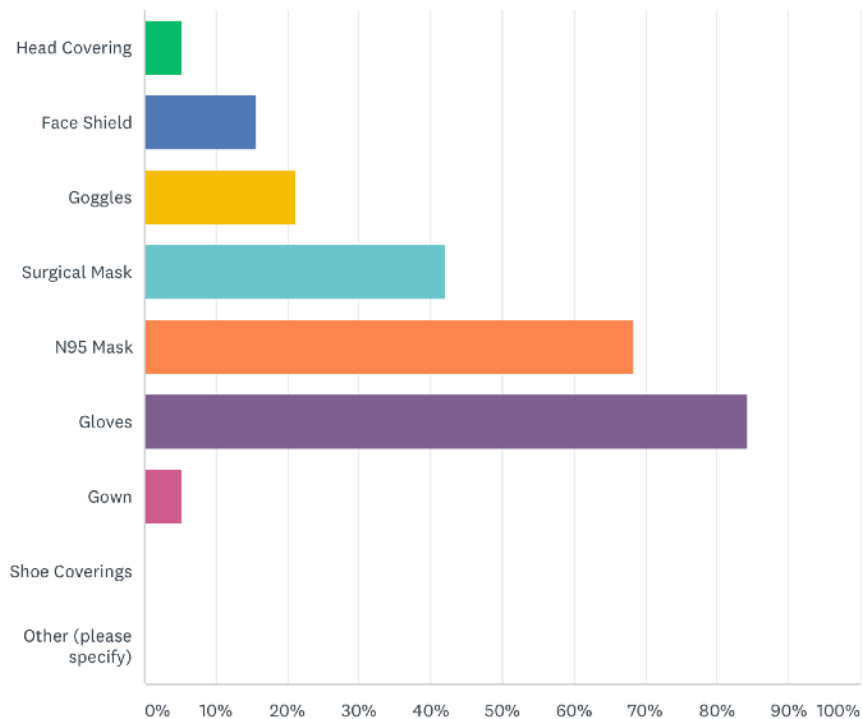
[Self Inflicted Eye Injuries: A Review - Eye, 2004](#)

PDF copy of the article also attached to the email

[Representative Case Photo Source](#)

PPE Survey Results

What forms of PPE do you wear routinely on inpatient/ER consults? Check all that apply.



What forms of PPE do you wear specifically for COVID+ patients? Check all that apply

