

# OPHTHALMIC HOSPITALIST INTEREST GROUP NEWSLETTER

Donna Kim, MD | Maggie Hymowitz, MD

## AAO Webinar

We are excited to host an upcoming AAO Webinar on "The Ophthalmic Hospitalist". Featured topics will include chairman advice on creating positions, model examples being used in the US, consult based teaching, and adaptations for COVID-19. Please join us on **Thursday Oct 8th at 8pm EST/5pm PST**. Pre-registration required.

[Click here to Register](#)

## AAO 2020

We continue to work on a virtual OHIG "meet and greet" for the upcoming fall meeting in November.

A Doodle poll will be sent out later this month to inquire about date/time availability for OHIG members. Stay tuned!



## Articles

[\*Addressing Decontaminated Respirators: Some Methods Appear to Damage Mask Integrity and Protective Function - ICHE, July 2020\*](#)

A study looking at the integrity and post-decontamination efficacy of N-95 masks using different techniques

[\*Face Shields for Infection Control: A Review - J Occup and Env Hygiene, Feb 2016\*](#)

A review supporting the use of face shields in conjunction with PPE for sufficient protection of the facial area

[\*SARS-CoV2 Infection Among Community Health Workers in India Before and After Use of Face Shields - JAMA, Aug 2020\*](#)

Another brief research letter looking at the utility of adding a face shield to current PPE

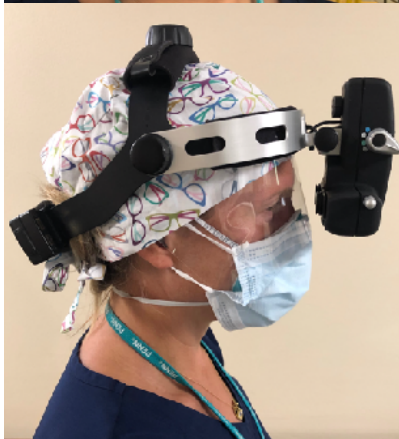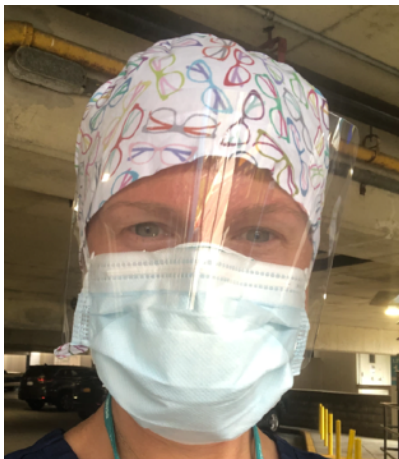\* PDF copies of all articles are attached to the email



## PEARLS

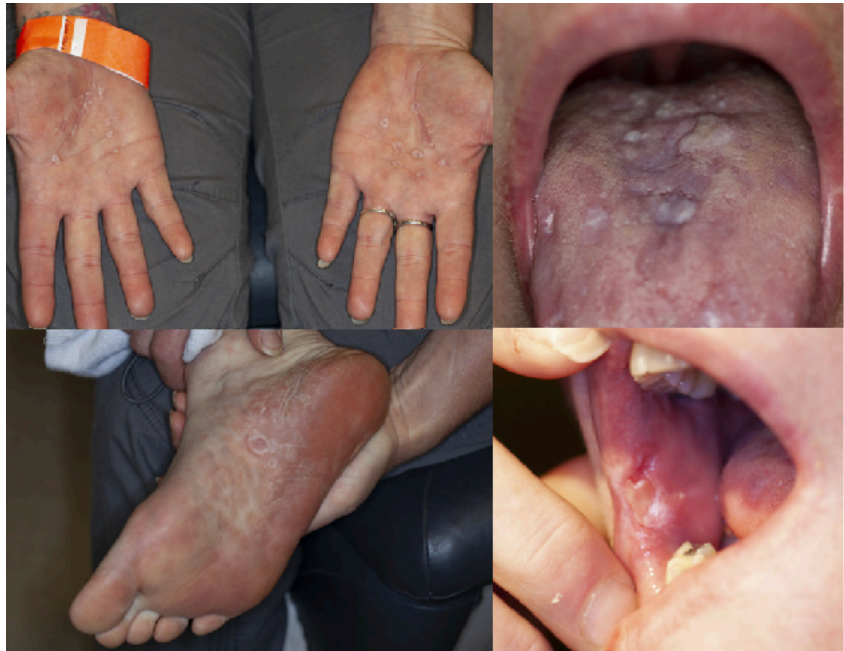### Face Shield

Face shields can be bulky to use with indirect ophthalmoscopy. Here is a nice option which combines a mask with a top face shield portion that remains very close to the face.



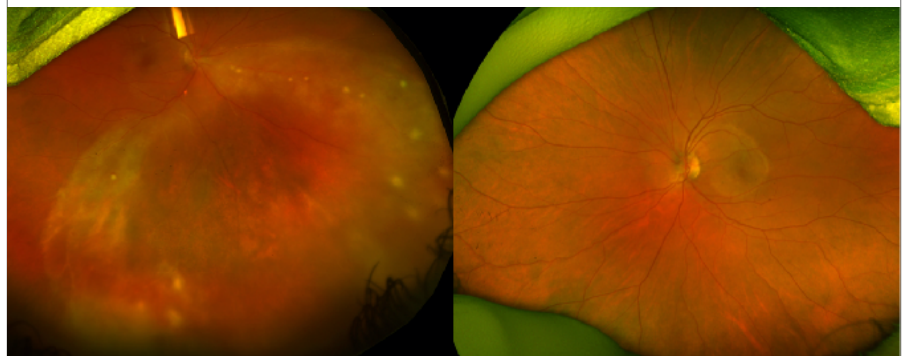
[Click here](#) for Procedural Mask with Earloop (not the surgical mask option which has ties)

## CONSULT ROUNDS



You receive an ER consult for a 43 year old diabetic female who complains of a skin rash, mouth lesions, and vision changes OU. She recently went to an urgent care clinic 2 weeks prior and was told she had a diagnosis of Hand, Foot, and Mouth Disease. Her rash and oral lesions did not improve. She started to develop blurry vision in both eyes x 1 week which brought her to the ER.

On exam, you note multiple skin lesions involving the palms of her hands and soles of her feet. She has several deep ulcerated lesions within her mouth. Her visual acuity is 20/400 OU. Her pupil responses are normal without APD. Her anterior and posterior exam is notable for a bilateral panuveitis OD>OS with AC and vitreous cell, retinal vascular sheathing, and placoid lesions involving the retina OU.



### Consult "Carry Bag"

Many of us use a wheeled "consult bag" for equipment. During the pandemic, you might consider downsizing to a carry bag which lets you avoid crowded elevators and take the stairs. It also protects delicate equipment from being broken during bumpy wheeled transport.

This bag/backpack has reasonable room, good pockets for lenses and equipment.



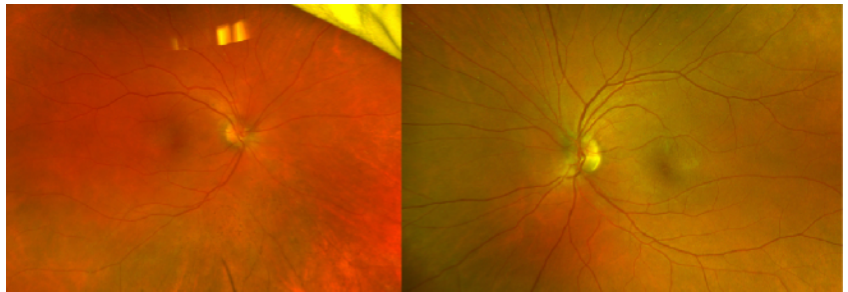
[Click here](#) to order the bag

\* We have no financial interest

Given her ocular and systemic findings, an infectious and inflammatory work up was sent. Results were notable for a reactive serum RPR (1:32) and TPA-ABS confirming a diagnosis of neurosyphilis.

The patient was started on topical steroid and admitted to the hospital for further management including an LP, IV PCN, and Infectious Disease consultation. She was seen for follow up at the eye clinic in 2 weeks with dramatic improvement of her ocular findings and her vision.

After PCN Treatment x 2 weeks



#### *Case Comments:*

With its variable ocular and systemic presentations, Syphilis remains "The Great Masquerader" with often delayed diagnosis. Here is a nice review update of Ocular findings related to Syphilis.

#### Selected Article:

[Ocular Syphilis: An Update, Ocular Immunology and Inflammation, Oct 2017](#)

\*PDF copy of the article also attached to the email