

# EQUINE FACT SHEET

## Contact Us

Phyllis Creech Greene  
Livestock Agent  
North Carolina Cooperative Extension  
Columbus County Center  
45 Government Complex Rd.  
Suite A  
Whiteville, NC 28472  
910.640.6605 Phone  
910.642.6315 Fax

columbus.ces.ncsu.edu

North Carolina State University and North Carolina A&T State University commit themselves to positive action to secure equal opportunity regardless of race, color, creed, national origin, religion, sex, age, veteran status, or disability. In addition, the two Universities welcome all persons without regard to sexual orientation. North Carolina State University, North Carolina A&T State University, U.S. Department of Agriculture, and local governments cooperating.

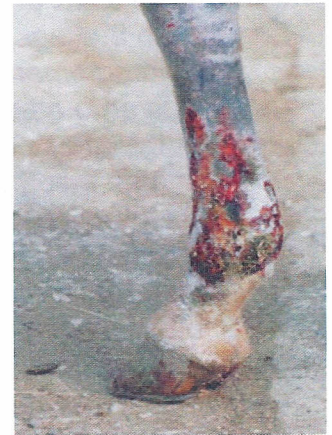For accommodations for persons with disabilities, contact the Cooperative Extension Office at 910.640.6605, no later than five business days before the event.

## Scratches, Mud Fever, Greasy Heel or Dew Poisoning

*Whatever name you use to refer to this condition, it is one you should be familiar with and be prepared to treat if it should occur at your farm.*

### What is it?

A skin infection that affects the lower limbs of horses, it is most often found on the heel and pastern but can be found on the ankle, cannon bone and knee.



### What causes it?

The bacterial causes are:

- Dermatophilus Congolensis – bacteria and fungus characteristics.
- Staphylococcus

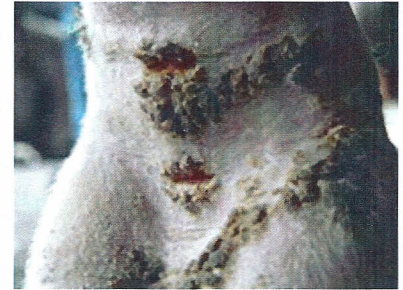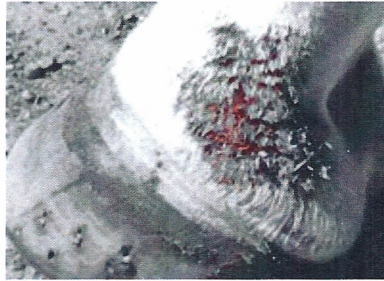
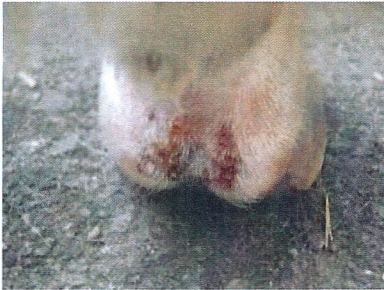Dermatophilus Congolensis is a micro-organism that lives in the soil and inhabits the skin but as long as a horse's skin remains healthy it will maintain a barrier that will prevent the microorganisms from entering.

External conditions that contribute to the infection process:

- Persistent moisture – this can be rain, mud and heavy dews.
- Damage to the skin – a cut, bug bite, or an abrasion caused by grit and stubble.
- Prolonged exposure to sweat - extreme exercising or extreme heat will produce sweat that will irritate and inflame the skin as it settles into the pastern.
- Horses with white socks - highly susceptible due to their pink skin and the irritation brought on by sunburn.

## What are the characteristic signs?

- The skin will first appear red, irritated, and inflamed, some swelling may occur.
- A weepy discharge will appear that looks 'greasy'.
- The crusts and deep matting start to appear as the inflamed skin begins to ooze serum and adhere to the hair.
- Swelling of the leg and lameness can also develop.



## How do you treat the condition?

- Wash the legs in warm water with an anti-microbial shampoo.  
*It is recommended you wear rubber gloves or wash your hands thoroughly to prevent transfer to other horses.*
- Let the affected areas soak and soften, so you can remove the crusts or scabs. You can use a soft brush or cloth.
- The infectious agents live on the skin underneath the crusts so you need to gently remove them. *Pulling the crusts off dry will be painful for the horse.*
- Once the infected areas are clean and exposed wash the legs in an anti-microbial solution, such as betadine. Let the legs soak for 5-10 minutes before rinsing.
- Let the legs dry thoroughly.
- Treat with a topical solution.
- You will want to collect any scabs and dispose of them in a trash bin. *They can stay contagious for an extended period.*
- Don't apply bandages – the areas need to be dry.

Grease heel is a painful condition that can progress into a very serious medical problem if not addressed. It can go into deep tissue and cause lameness and permanent damage. If your horse does not quickly respond to the treatments you should seek help from your vet.

### **Other Related Conditions:**

**Rain Scald or Rain Rot** – caused by the same infectious organism except it is found on the upper body of the horse. It is brought on by the same conditions; prolonged exposure to moisture and a weakened area on the skin lets the organism begin to grow.

**Pastern Leukocytoclastic Vasculitis** – an immune disease that resembles Greasy Heel, especially in the beginning. It is found on white or nonpigmented skin, primarily the pasterns, which strongly suggest UV radiation plays a significant role in its development. This condition can become very serious, with chronic cases developing thickened skin that is rough and warty on the surface.

**Chronic Progressive Lymphedema** - this condition is found in draft horses and it is very serious. CPL is a disease that appears to be genetic in nature and can't be reversed. CPL starts at a young age and is a disease of the lymphatic system. The skin lesions on the lower legs are a secondary result. What begins, as a thickening and crusting on the skin, which can only be seen after clipping the feathers, will in time, develop into ulcers and lesions that will go as high as the knee/hock.