

## PennHIP Report

Referring Veterinarian: Dr Hayley Phipps Robinson	Clinic Name: Belle Meade Animal Hospital of TN
Email: hrobinson@bellemeadeanimalhospital.com	Clinic Address: 6210 Highway 100 Nashville, TN 37205
	Phone:
	Fax: (615) 352-5659

## Patient Information

Client: BLAIR, JACLYN	Tattoo Num:
Patient Name: CERES	Patient ID: 25158
Reg. Name:	Registration Num:
PennHIP Num: 191224	Microchip Num: 985113007731181
Species: Canine	Breed: MAREMMA SHEEPDOG
Date of Birth: 04 Aug 2022	Age: 11 months
Sex: Female	Weight: 79.2 lbs/35.9 kgs
Date of Study: 11 Jul 2023	Date Submitted: 11 Jul 2023
Date of Report: 11 Jul 2023	

## Findings

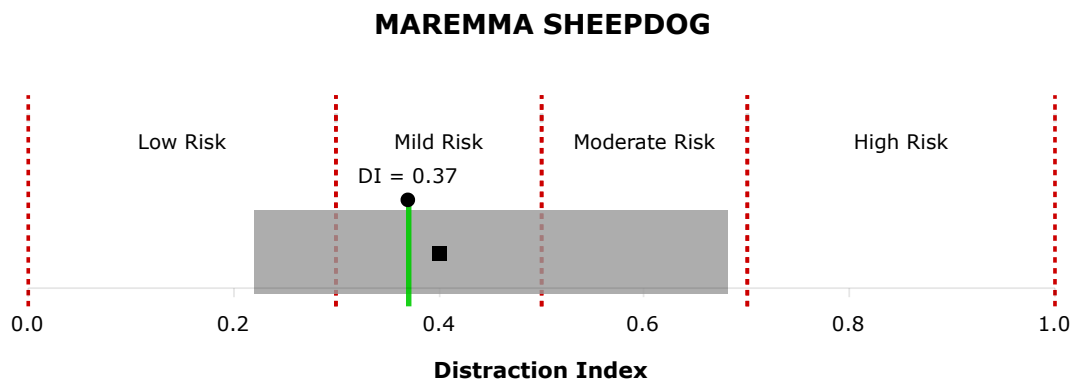
Distraction Index (DI): Right DI = 0.35, Left DI = 0.37.  
 Osteoarthritis (OA): **No radiographic evidence of OA for either hip.**  
 Cavitation/Other Findings: No cavitation present.

## Interpretation

Distraction Index (DI): The laxity ranking is based on the hip with the greater laxity (larger DI). In this case the DI used is 0.37.

OA Risk Category: The DI is between 0.31 and 0.49. This patient is at mild risk for hip OA.

Distraction Index Chart:



**BREED STATISTICS:** This interpretation is based on a cross-section of 243 canine patients of the MAREMMA SHEEPDOG breed in the AIS PennHIP database. The gray strip represents the central 90% range of DIs (0.22 - 0.68) for the breed. The breed average DI is 0.40 (solid square). The patient DI is the solid circle (0.37).

**SUMMARY:** The degree of laxity (DI = 0.37) falls within the central 90% range of DIs for the breed. This amount of hip laxity places the hip at a mild risk to develop hip OA. **No radiographic evidence of OA for either hip.**

