

PennHIP Report

Referring Veterinarian: Dr Jeaneen Metzler
Email: orangevalevet@yahoo.com

Clinic Name: Orangevale Veterinary Hospital
Clinic Address: 6248 Main Ave #D
Orangevale, CA 95662
Phone:
Fax: (916) 987-2052

Patient Information

Client: Spencer, Becky
Patient Name: Yellow Collar
Reg. Name:
PennHIP Num: 190876
Species: Canine
Date of Birth: 06 Feb 2023
Sex: Male
Date of Study: 28 Jun 2023
Date of Report: 29 Jun 2023

Tattoo Num:
Patient ID: 956000005141236/Yellow
Registration Num:
Microchip Num:
Breed: MAREMMA SHEEPDOG
Age: 20 weeks
Weight: 56 lbs/25.4 kgs
Date Submitted: 28 Jun 2023

Findings

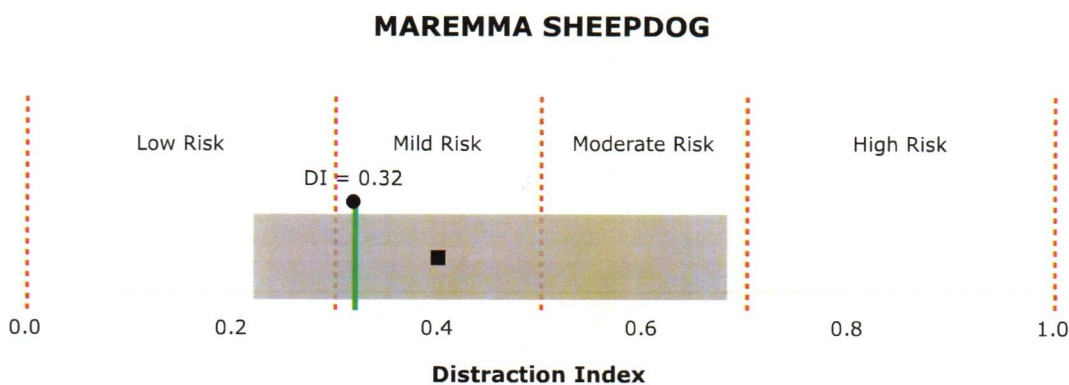
Distraction Index (DI): Right DI = 0.32, Left DI = 0.29.
Osteoarthritis (OA): **No radiographic evidence of OA for either hip.**
Cavitation/Other Findings: No cavitation present.

Interpretation

Distraction Index (DI): The laxity ranking is based on the hip with the greater laxity (larger DI). In this case the DI used is 0.32.

OA Risk Category: The DI is between 0.31 and 0.49. This patient is at mild risk for hip OA.

Distraction Index Chart:



BREED STATISTICS: This interpretation is based on a cross-section of 243 canine patients of the MAREMMA SHEEPDOG breed in the AIS PennHIP database. The gray strip represents the central 90% range of DIs (0.22 - 0.68) for the breed. The breed average DI is 0.40 (solid square). The patient DI is the solid circle (0.32).

SUMMARY: The degree of laxity (DI = 0.32) falls within the central 90% range of DIs for the breed. This amount of hip laxity places the hip at a mild risk to develop hip OA. **No radiographic evidence of OA for either hip.**