

# Comprehensive Report

Table Report | Image Report

Name:

Gender: Height: Weight: Date of Birth:

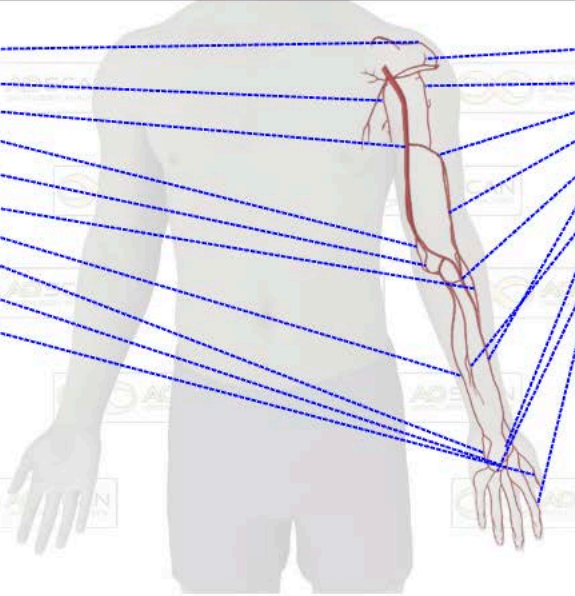


## Arteries: Arm Left

% From Ideal: 38

Left Acromial Branch Thoracoacromial	5	5
Left Lateral Thoracic Artery	5	5
Left Brachial Artery	4	1
Left Anterior Ulnar Recurrent	6	4
Left Superior Ulnar Collateral Artery	7	5
Left Posterior Intersosseous Artery	6	4
Left Ulnar Artery	5	5
Left Deep Palmar Branch Ulnar Artery	7	9
Left Deep Palmar Arterial Arch	4	1
Left Princes Pollicis Artery	4	6

Left Anterior Circumflex Humeral Artery	8	1
Left Posterior Circumflex Humeral Artery	7	9
Left Deep Brachial Artery	5	5
Left Radial Collateral Artery	5	1
Left Middle Collateral Artery	5	1
Left Radial Artery	7	5
Left Anterior Intersosseous Artery	5	3
Left Superficial Palmar Branch Radial	7	6
Left Superficial Palmar Arterial Arch	7	8
Left Palmar Digital Arteries	5	4

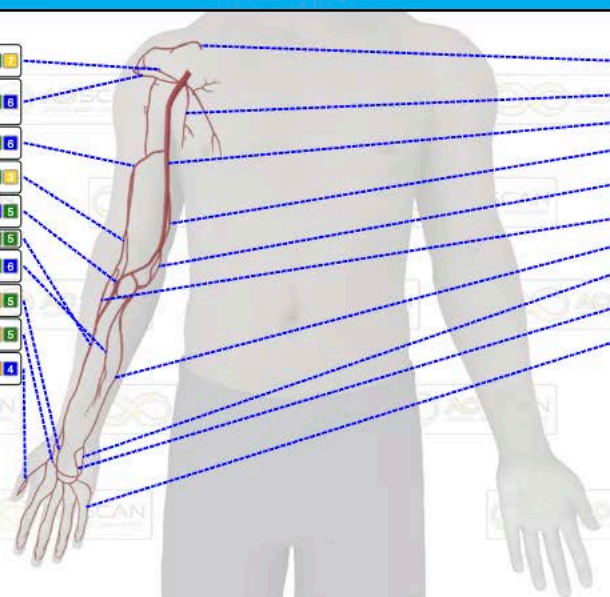


## Arteries: Arm Right

% From Ideal: 31

Right Anterior Circumflex Humeral Artery	5	7
Right Posterior Circumflex Humeral Artery	5	6
Right Deep Brachial Artery	5	6
Right Radial Collateral Artery	5	3
Right Middle Collateral Artery	6	5
Right Radial Artery	5	5
Right Anterior Intersosseous Artery	5	6
Right Superficial Palmar Branch Radial	4	5
Right Deep Palmar Arterial Arch	7	5
Right Princes Pollicis Artery	2	4

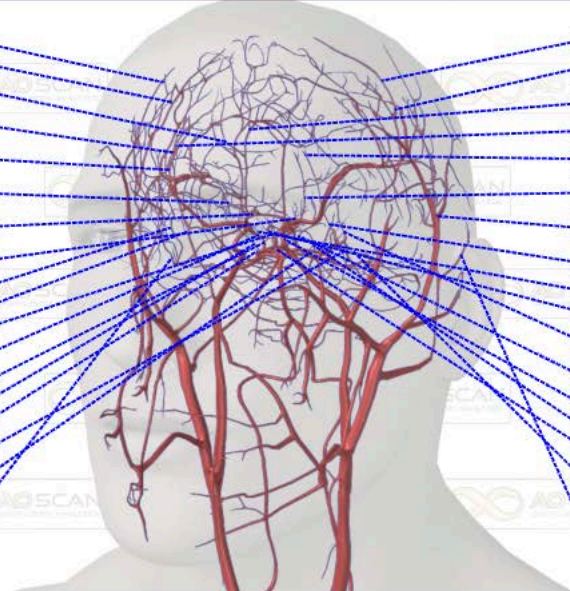
Right Acromial Branch Thoracoacromial	4	2
Right Lateral Thoracic Artery	8	5
Right Brachial Artery	7	8
Right Superior Ulnar Collateral Artery	7	5
Right Anterior Ulnar Recurrent	7	9
Right Posterior Intersosseous Artery	5	1
Right Ulnar Artery	6	6
Right Deep Palmar Branch Ulnar Artery	4	5
Right Superficial Palmar Arterial Arch	2	3
Right Palmar Digital Arteries	4	4





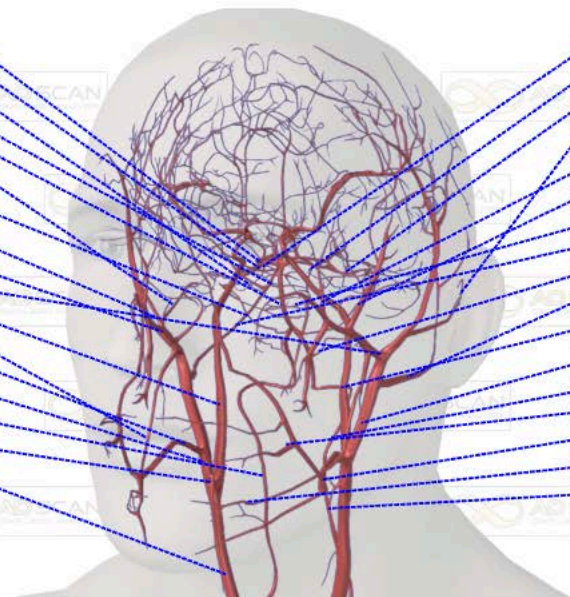
Right Angular Artery	5 5
Right Meningeal Artery	5 6
Right Anterior Cerebral Artery	4 6
Right Middle Cerebral Artery	4 2
Right Superior Temporal Artery	7 9
Right Lenticulostriate Artery	5 6
Left Anterior Communicating Artery	6 7
Left Lenticulostriate Artery	4 2
Left Eye Arteries	5 1
Left Angular Artery	4 9
Left Ophthalmic Artery	5 5
Right Posterior Communicating Artery	4 5
Left PCA P01	6 4
Right PCA P03	5 9
Right PCA P04	7 9
Right PCA Calcarine Artery	7 5
Right PCA P01	6 5
Right PCA Anterior Temporal Artery	8 5

Left Meningeal Artery	6 5
Left Middle Cerebral Artery	4 5
Left Anterior Cerebral Artery	5 5
Right Ophthalmic Artery	5 5
Right PCA Posterior Pericallosal Artery	7 9
Left PCA Posterior Pericallosal Artery	4 4
Left Superior Temporal Artery	6 8
Left PCA Parietal Occipital Artery	2 4
Right Eye Arteries	5 5
Right Perforator Artery	7 6
Right PCA Parietal Occipital Artery	2 1
Left Posterior Communicating Artery	5 5
Left Perforator Artery	5 9
Left PCA P02	7 9
Left PCA P03	7 9
Left PCA Posterior Temporal Artery	6 5
Left PCA Anterior Temporal Artery	6 4



Right PCA P02	5 4
Left PCA P04	6 5
Right PCA Posterior Temporal Artery	5 5
Right Pontine Artery	9 7
Basilar Artery	5 5
Right Posterior Auricular Artery	8 7
Right Anterior Inferior Cerebellar Artery	4 6
Right Deep Temporal Artery	7 5
Right Maxillary Artery	2 4
Left Maxillary Artery	2 1
Right Internal Carotid Artery	5 5
Right Alveolar Artery	5 7
Right Facial Artery	6 5
Right External Carotid Artery	5 1
Right Vertebral Artery	5 5
Right Superior Thyroid Artery	4 1
Left Common Carotid Artery	5 5

Right Superior Cerebellar Artery	8 1
Left PCA Calcarine Artery	7 5
Left Superior Cerebellar Artery	5 5
Left Posterior Auricular Artery	5 2
Left Deep Temporal Artery	4 2
Left Anterior Inferior Cerebellar Artery	6 4
Left Pontine Artery	4 6
Right Occipital Artery	8 8
Right Posterior Inferior Cerebellar Artery	4 6
Left Occipital Artery	7 5
Left Internal Carotid Artery	5 5
Left External Carotid Artery	7 5
Left Vertebral Artery	5 3
Left Facial Artery	2 4
Left Superior Laryngeal Artery	8 8
Left Alveolar Artery	6 5
Left Superior Thyroid Artery	1 1



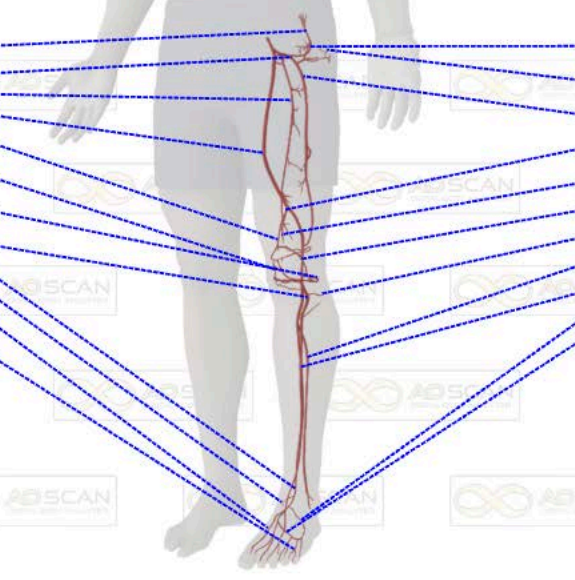


## Arteries: Leg Left

% From Ideal: 33

Left Ascending Lat. Circumflex	2	1
Left Lateral Circumflex	5	9
Left Deep Femoral Artery	4	2
Left Femoral Artery	8	5
Left Articular Descending Genicular	6	6
Left Medial Inferior Genicular	6	4
Left Lateral Inferior Genicular	7	5
Left Anterior Tibial Recurrent	6	1
Left Anterior Tibial Artery	4	5
Left Medial Tarsal Arteries	7	9
Left Dorsal Metatarsals Arteries	2	4
Left Dorsal Digital Arteries	8	1

Left Medial Circumflex Artery	8	5
Left Transverse Lat. Circumflex	2	1
Left Descending Lat. Circumflex	4	2
Left Descending Genicular Artery	6	4
Left Saphenous Descending Genicular	5	5
Left Popliteal Artery	5	5
Left Circumflex Fibular Artery	5	6
Left Fibular Artery	5	7
Left Posterior Tibial Artery	7	9
Left Lateral Tarsal Artery	8	1
Left Arcuate Artery	5	5

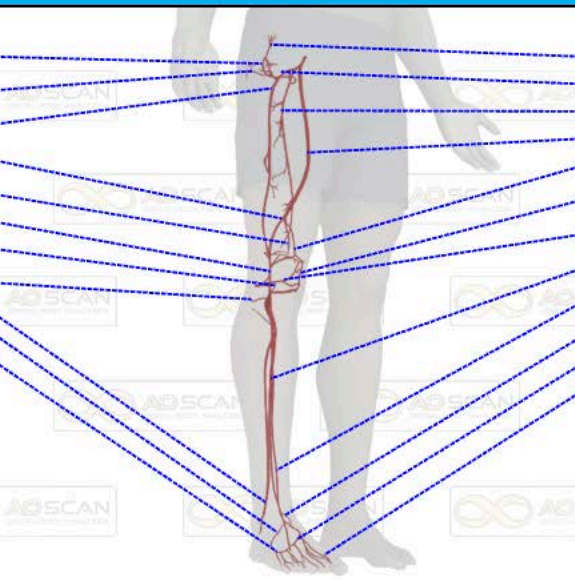


## Arteries: Leg Right

% From Ideal: 23

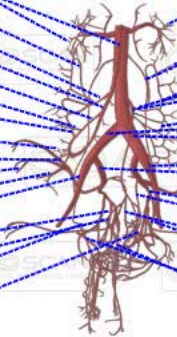
Right Medial Circumflex Artery	5	5
Right Transverse Lat. Circumflex	7	9
Right Descending Lat. Circumflex	5	5
Right Descending Genicular Artery	5	5
Right Saphenous Descending Genicular	4	5
Right Popliteal Artery	7	9
Right Anterior Tibial Recurrent	5	7
Right Circumflex Fibular Artery	3	5
Right Fibular Artery	6	5
Right Lateral Tarsal Artery	5	5
Right Dorsal Metatarsal Arteries	8	5

Right Ascending Lat. Circumflex	4	2
Right Lateral Circumflex	4	2
Right Deep Femoral Artery	3	1
Right Femoral Artery	5	4
Right Articular Descending Genicular	5	4
Right Medial Inferior Genicular	5	5
Right Lateral Inferior Genicular	2	1
Right Posterior Tibial Artery	3	5
Right Anterior Tibial Artery	5	5
Right Medial Tarsal Arteries	7	9
Right Arcuate Artery	5	5
Right Dorsal Digital Arteries	4	5



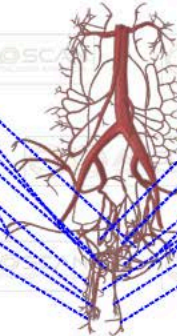
Right Renal Artery	9	9
Abdominal Aorta	2	4
Right Middle Colic Artery	7	5
Right Colic Artery	7	5
Right Superior Mesenteric Artery	6	6
Right Ileoocolic Artery	4	3
Right Colic Branch Ileoocolic Artery	9	7
Right Ileal Branch Ileoocolic Artery	5	7
Right Anterior Cecal Artery	6	5
Right Posterior Cecal Artery	4	2
Right Superior Gluteal Artery	5	3
Right Appendicular Artery	5	7
Right External Iliac Artery	6	5
Right Umbilical Artery	6	5
Right Superior Rectal Artery	7	5
Right Artery of Ductus Deferens	4	5
Left Artery of Ductus Deferens	6	6

Left Renal Artery	9	1
Right Marginal Artery	2	4
Ascending Branch Left Colic Artery	5	5
Descending Branch Left Colic Artery	6	9
Left Pampiniform Venous Plexus	7	5
Right Inferior Mesenteric Artery	7	5
Right Sigmoid Arteries	4	6
Right Common Iliac Artery	5	1
Left Common Iliac Artery	5	8
Left External Iliac Artery	8	4
Right Internal Iliac Artery	4	5
Left Superior Gluteal Artery	5	5
Left Internal Iliac Artery	9	1
Left Lateral Sacral Artery	4	9
Right Lateral Sacral Artery	5	5
Left Umbilical Artery	9	1
Left Inferior Gluteal Artery	5	5
Right Testicular Artery	6	9
Right Middle Rectal Artery	6	9

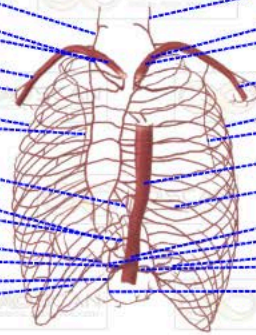


Right Inferior Gluteal Artery	5	5
Right Obturator Artery	4	6
Left Middle Rectal Artery	5	5
Right Internal Pudendal Artery	7	5
Right Inferior Rectal Artery	5	8
Right Deep Artery of the Penis	5	4
Right Dorsal Artery of the Penis	6	9
Right Bulbourethral Artery	7	6
Right Posterior Scrotal Arteries	6	5

Right Inferior Vesical Artery	5	1
Left Testicular Artery	5	1
Left Obturator Artery	2	4
Left Internal Pudendal Artery	3	5
Left Deep Artery of the Penis	5	7
Right Inferior Rectal Artery	7	8
Left Dorsal Artery of the Penis	4	4
Left Bulbourethral Artery	4	4
Left Posterior Scrotal Arteries	7	9



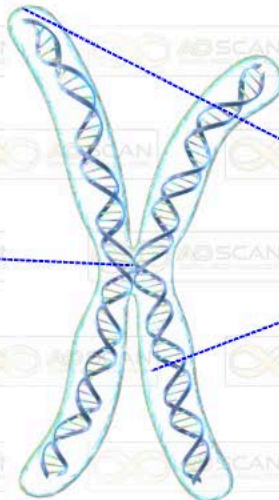
Right Inferior Thyroid Artery	6	9
Right Subclavian Artery	5	8
Right Brachiocephalic Trunk	7	9
Right Axillary Artery	2	5
Right Suprascapular Artery	3	1
Right Intercostal Arteries	5	8
Right Transverse Cervical Artery	4	5
Right Esophageal Arteries	7	5
Left Hepatic Artery	4	3
Left Accessory Hepatic Artery	6	9
Right Proper Hepatic Artery	2	9
Right Gastric Artery	3	5
Right Gastroduodenal Artery	3	1
Right Hepatic Artery	8	9



Left Inferior Thyroid Artery	4	2
Left Subclavian Artery	7	9
Left Brachiocephalic Trunk	5	5
Left Axillary Artery	3	4
Left Suprascapular Artery	3	4
Left Intercostal Arteries	5	8
Left Transverse Cervical Artery	2	4
Right Descending Aorta	2	5
Right Inferior Phrenic Arteries	7	5
Right Celiac Trunk	5	9
Right Common Hepatic Artery	5	4
Right Splenic Artery	6	9
Left Gastric Artery	5	5
Right Gastroepiploic Artery	7	9



DNA Marker 01	6	9
DNA Marker 03	4	6
DNA Marker 05	5	7
DNA Marker 07	4	6
DNA Marker 09	5	5
DNA Marker 11	5	5
DNA Marker 13	5	9
DNA Marker 15	6	5
DNA Marker 17	5	4
DNA Marker 19	5	9
DNA Marker 21	7	5
DNA Marker 23	5	5
Centromere	5	6

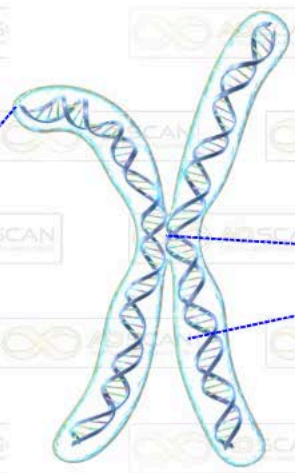


DNA Marker 02	5	8
DNA Marker 04	4	2
DNA Marker 06	3	5
DNA Marker 08	4	6
DNA Marker 10	4	2
DNA Marker 12	9	9
DNA Marker 14	5	5
DNA Marker 16	7	5
DNA Marker 18	4	2
DNA Marker 20	4	2
DNA Marker 22	7	9
Telomere	6	8
Chromatid	6	5



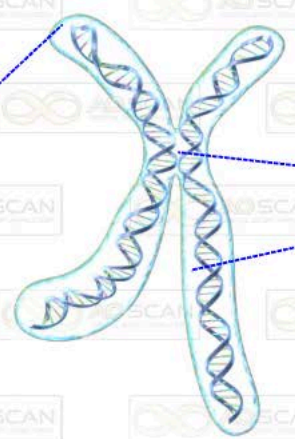
DNA Marker 01	9 1
DNA Marker 03	5 5
DNA Marker 05	2 2
DNA Marker 07	9 8
DNA Marker 09	5 5
DNA Marker 11	4 8
DNA Marker 13	5 7
DNA Marker 15	9 1
DNA Marker 17	7 9
DNA Marker 19	6 6
DNA Marker 21	4 4
DNA Marker 23	5 5
DNA Marker 25	9 1
Telomere	4 8

DNA Marker 02	6 8
DNA Marker 04	7 5
DNA Marker 06	7 6
DNA Marker 08	5 7
DNA Marker 10	5 5
DNA Marker 12	6 9
DNA Marker 14	8 8
DNA Marker 16	6 8
DNA Marker 18	7 5
DNA Marker 20	1 2
DNA Marker 22	9 5
DNA Marker 24	6 5
DNA Marker 26	9 5
Centromere	6 9
Chromatid	4 8



DNA Marker 01	4 6
DNA Marker 03	3 6
DNA Marker 05	4 6
DNA Marker 07	7 9
DNA Marker 09	4 6
DNA Marker 11	7 6
DNA Marker 13	5 8
DNA Marker 15	7 9
DNA Marker 17	7 9
DNA Marker 19	5 4
DNA Marker 21	4 6
Telomere	9 9

DNA Marker 02	9 1
DNA Marker 04	8 1
DNA Marker 06	7 9
DNA Marker 08	5 5
DNA Marker 10	6 8
DNA Marker 12	9 6
DNA Marker 14	6 8
DNA Marker 16	2 2
DNA Marker 18	7 9
DNA Marker 20	5 1
DNA Marker 22	7 5
Centromere	8 5
Chromatid	8 1



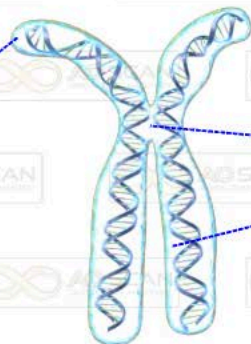

Chromosomes: 04

% From Ideal: 24

DNA Marker 01	5	8
DNA Marker 03	6	5
DNA Marker 05	4	2
DNA Marker 07	4	2
DNA Marker 09	7	5
DNA Marker 11	7	9
DNA Marker 13	4	2
DNA Marker 15	7	9
DNA Marker 17	5	4
DNA Marker 19	7	5
DNA Marker 21	4	2
Telomere	5	8

DNA Marker 02	5	8
DNA Marker 04	6	8
DNA Marker 06	3	5
DNA Marker 08	6	7
DNA Marker 10	8	5
DNA Marker 12	3	5
DNA Marker 14	5	7
DNA Marker 16	6	8
DNA Marker 18	5	8
DNA Marker 20	8	5
DNA Marker 22	5	7
Centromere	5	5
Chromatid	8	1

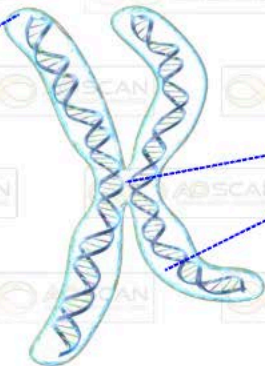


Chromosomes: 05

% From Ideal: 39

DNA Marker 01	8	5
DNA Marker 03	7	5
DNA Marker 05	8	6
DNA Marker 07	6	8
DNA Marker 09	5	5
DNA Marker 11	7	5
DNA Marker 13	4	2
DNA Marker 15	7	5
DNA Marker 17	1	1
Telomere	8	1

DNA Marker 02	4	5
DNA Marker 04	6	1
DNA Marker 06	8	8
DNA Marker 08	7	5
DNA Marker 10	7	5
DNA Marker 12	5	8
DNA Marker 14	6	7
DNA Marker 16	5	5
DNA Marker 18	4	2
Centromere	6	8
Chromatid	4	2



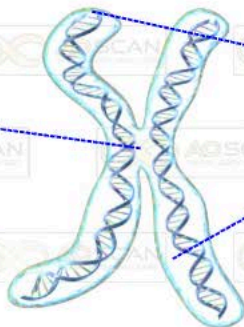

Chromosomes: 06

% From Ideal: 30

DNA Marker 01	7	9
DNA Marker 03	3	4
DNA Marker 05	5	7
DNA Marker 07	7	9
DNA Marker 09	4	7
DNA Marker 11	5	6
DNA Marker 13	5	7
DNA Marker 15	5	5
DNA Marker 17	5	5
DNA Marker 19	5	7
Centromere	4	4

DNA Marker 02	5	5
DNA Marker 04	6	9
DNA Marker 06	5	7
DNA Marker 08	5	7
DNA Marker 10	7	5
DNA Marker 12	5	5
DNA Marker 14	7	5
DNA Marker 16	6	9
DNA Marker 18	7	5
Telomere	5	5
Chromatid	5	5

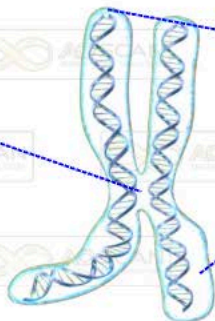


Chromosomes: 07

% From Ideal: 34

DNA Marker 01	7	5
DNA Marker 03	7	1
DNA Marker 05	5	5
DNA Marker 07	5	7
DNA Marker 09	7	5
DNA Marker 11	9	7
DNA Marker 13	6	5
DNA Marker 15	6	5
DNA Marker 17	5	5
Centromere	6	5

DNA Marker 02	5	5
DNA Marker 04	6	9
DNA Marker 06	7	4
DNA Marker 08	7	4
DNA Marker 10	7	5
DNA Marker 12	5	4
DNA Marker 14	6	5
DNA Marker 16	6	5
Telomere	5	5
Chromatid	7	5



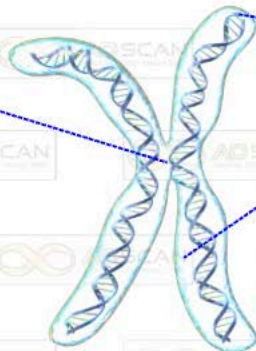

Chromosomes: 08

% From Ideal: 28

DNA Marker 01	7	5
DNA Marker 03	5	9
DNA Marker 05	7	9
DNA Marker 07	7	3
DNA Marker 09	4	9
DNA Marker 11	4	9
DNA Marker 13	5	5
DNA Marker 15	7	5
Centromere	6	9

DNA Marker 02	7	5
DNA Marker 04	5	5
DNA Marker 06	7	1
DNA Marker 08	5	5
DNA Marker 10	5	5
DNA Marker 12	7	9
DNA Marker 14	7	9
Telomere	5	4
Chromatid	4	9

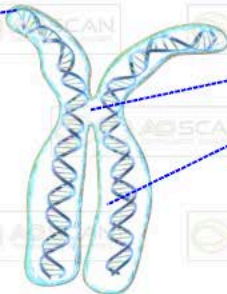


Chromosomes: 09

% From Ideal: 37

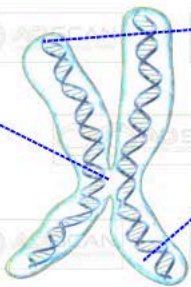
DNA Marker 01	5	9
DNA Marker 03	5	1
DNA Marker 05	5	9
DNA Marker 07	4	1
DNA Marker 09	9	9
DNA Marker 11	5	5
DNA Marker 13	4	4
DNA Marker 15	7	9
Telomere	3	4

DNA Marker 02	7	1
DNA Marker 04	7	9
DNA Marker 06	7	9
DNA Marker 08	7	1
DNA Marker 10	4	9
DNA Marker 12	7	9
DNA Marker 14	3	4
DNA Marker 16	7	1
Centromere	1	9
Chromatid	7	5



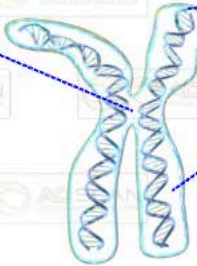DNA Marker 01	4	2
DNA Marker 03	1	1
DNA Marker 05	7	5
DNA Marker 07	4	2
DNA Marker 09	4	3
DNA Marker 11	5	1
DNA Marker 13	5	5
Centromere	0	2

DNA Marker 02	7	5
DNA Marker 04	7	5
DNA Marker 06	6	1
DNA Marker 08	9	1
DNA Marker 10	4	3
DNA Marker 12	6	1
Telomere	0	6
Chromatid	5	5



DNA Marker 01	3	4
DNA Marker 03	5	1
DNA Marker 05	5	8
DNA Marker 07	4	2
DNA Marker 09	3	4
DNA Marker 11	5	5
DNA Marker 13	1	1
Centromere	2	5

DNA Marker 02	5	1
DNA Marker 04	1	6
DNA Marker 06	5	5
DNA Marker 08	5	5
DNA Marker 10	5	5
DNA Marker 12	2	1
DNA Marker 14	5	4
Telomere	4	2
Chromatid	1	9



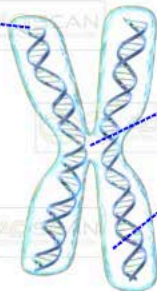

Chromosomes: 12

% From Ideal: 40

DNA Marker 01	6	5
DNA Marker 03	4	6
DNA Marker 05	5	6
DNA Marker 07	1	2
DNA Marker 09	7	5
DNA Marker 11	6	1
Telomere	6	5

DNA Marker 02	7	1
DNA Marker 04	4	5
DNA Marker 06	7	6
DNA Marker 08	6	3
DNA Marker 10	7	5
DNA Marker 12	6	1
Centromere	6	3
Chromatid	6	3

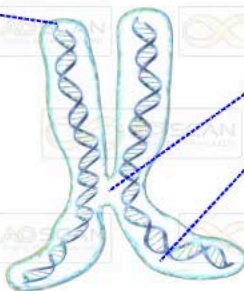


Chromosomes: 13

% From Ideal: 40

DNA Marker 01	7	5
DNA Marker 03	5	4
DNA Marker 05	9	4
DNA Marker 07	5	7
DNA Marker 09	7	1
Telomere	5	6

DNA Marker 02	3	4
DNA Marker 04	6	1
DNA Marker 06	3	5
DNA Marker 08	6	1
DNA Marker 10	6	4
Centromere	6	3
Chromatid	6	1



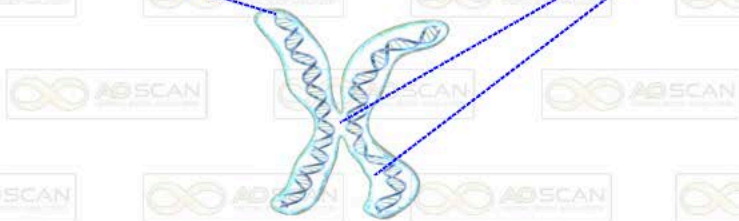


Chromosomes: 14

% From Ideal: 17

DNA Marker 01	6	9
DNA Marker 03	5	9
DNA Marker 05	5	9
DNA Marker 07	5	6
DNA Marker 09	8	9
Telomere	5	5

DNA Marker 02	9	1
DNA Marker 04	8	5
DNA Marker 06	4	2
DNA Marker 08	5	5
DNA Marker 10	9	1
Centromere	6	5
Chromatid	5	5

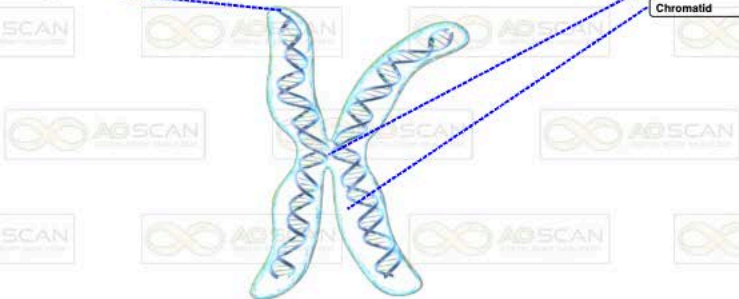


Chromosomes: 15

% From Ideal: 39

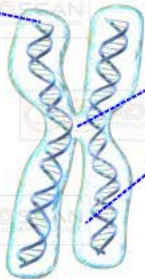
DNA Marker 01	9	1
DNA Marker 03	4	1
DNA Marker 05	7	5
DNA Marker 07	7	6
DNA Marker 09	2	2
Telomere	5	5

DNA Marker 02	4	2
DNA Marker 04	5	5
DNA Marker 06	5	9
DNA Marker 08	5	7
DNA Marker 10	4	3
Centromere	4	3
Chromatid	5	5



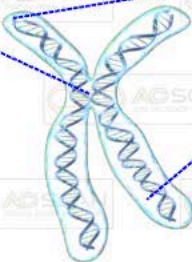
DNA Marker 01	5 5
DNA Marker 03	5 5
DNA Marker 05	4 4
DNA Marker 07	6 5
DNA Marker 09	5 5
Telomere	5 1

DNA Marker 02	5 4
DNA Marker 04	5 5
DNA Marker 06	5 5
DNA Marker 08	5 1
DNA Marker 10	5 5
Centromere	1 1
Chromatid	4 4



DNA Marker 01	4 5
DNA Marker 03	5 5
DNA Marker 05	5 5
DNA Marker 07	5 5
DNA Marker 09	5 5
DNA Marker 11	2 1
Centromere	5 1

DNA Marker 02	5 1
DNA Marker 04	5 5
DNA Marker 06	5 5
DNA Marker 08	4 5
DNA Marker 10	5 5
Telomere	5 5
Chromatid	4 5



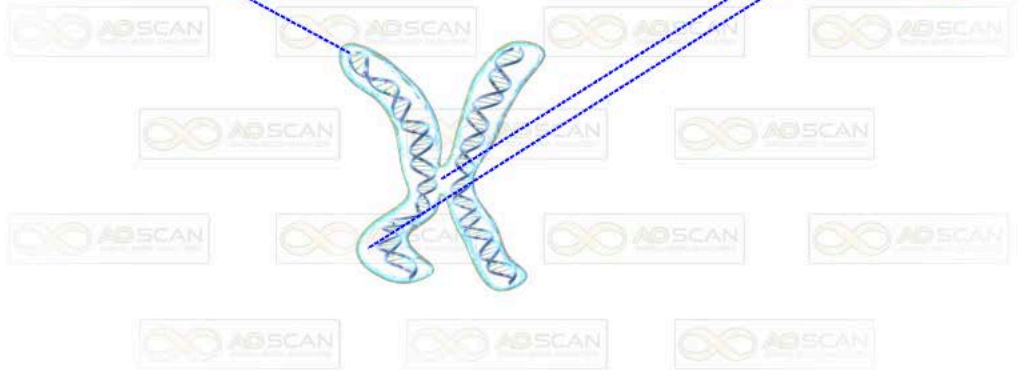


Chromosomes: 18

% From Ideal: 36

DNA Marker 01	5	5
DNA Marker 03	5	5
DNA Marker 05	6	4
DNA Marker 07	1	6
Telomere	4	2

DNA Marker 02	5	5
DNA Marker 04	1	2
DNA Marker 06	5	5
DNA Marker 08	1	5
Centromere	5	5
Chromatid	4	2

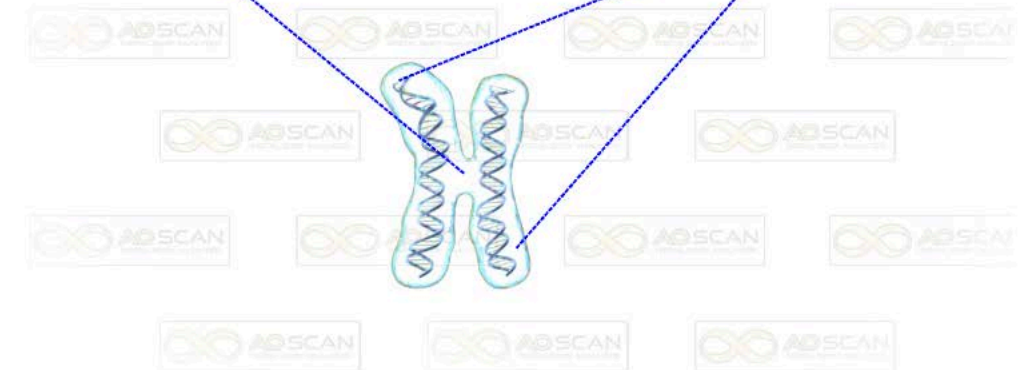


Chromosomes: 19

% From Ideal: 31

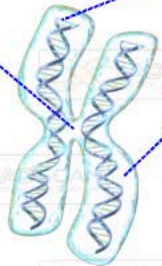
DNA Marker 01	5	5
DNA Marker 03	2	2
DNA Marker 05	5	2
Centromere	5	5

DNA Marker 02	6	8
DNA Marker 04	5	1
Telomere	5	1
Chromatid	5	8



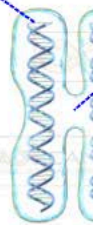
DNA Marker 01	5	5
DNA Marker 03	4	9
DNA Marker 05	9	9
DNA Marker 07	5	5
Centromere	5	5

DNA Marker 02	9	5
DNA Marker 04	4	9
DNA Marker 06	5	5
Telomere	5	5
Chromatid	5	5



DNA Marker 01	1	1
DNA Marker 03	5	5
Telomere	5	5

DNA Marker 02	9	9
DNA Marker 04	5	5
Centromere	5	5
Chromatid	5	5



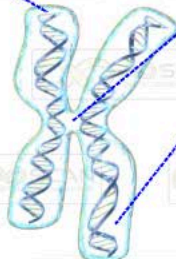


Chromosomes: 22

% From Ideal: 18

DNA Marker 01	5	5
DNA Marker 03	5	5
Telomere	4	4

DNA Marker 02	4	5
DNA Marker 04	4	4
Centromere	5	5
Chromatid	5	5

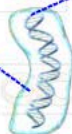


Chromosomes: Y

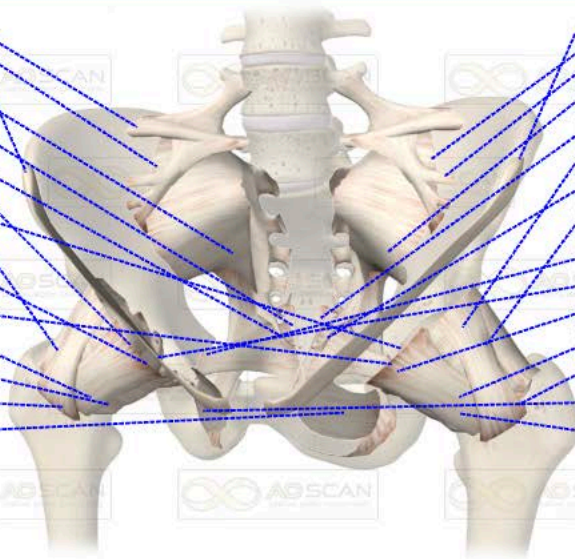
% From Ideal: 42

Centromere	4	5
DNA Marker 02	4	4
Chromatid	4	4

DNA Marker 01	4	5
DNA Marker 03	4	5
Telomere	4	4



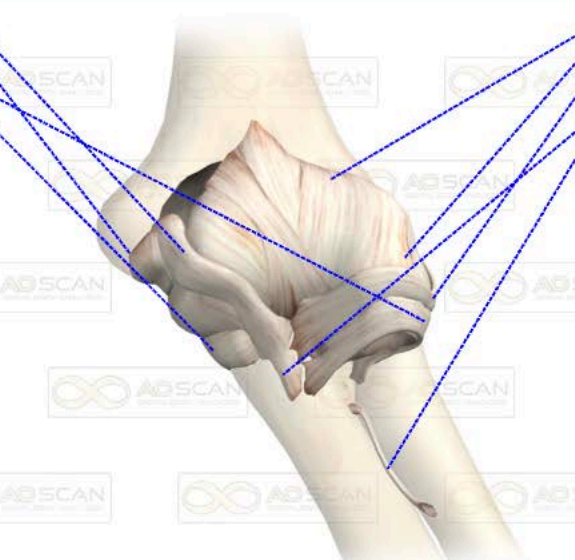
Right Iliolumbar Ligament	5	4
Right Sacroiliac Ligament	6	6
Right Inguinal Ligament	1	1
Right Sacrotuberous Ligament Connective	5	5
Right Anterior Sacrococcygeal Ligament	6	6
Right Lateral Sacrococcygeal Ligament	4	1
Right Acetabular Labrum	7	9
Left Round Ligament	5	5
Right Ischiofemoral Ligament	4	2
Right Transverse Acetabular Ligament	5	4
Left Sacrospinous Ligament	2	2
Right Pubofemoral Ligament	6	3
Right Zona Orbicularis	5	5
Right Iliofemoral Ligament	4	5
Left Obturator Membrane	5	5



Left Inguinal Ligament	1	1
Left Sacroiliac Ligament	2	4
Left Iliolumbar Ligament	9	9
Left Sacrotuberous Ligament Connective	7	5
Left Anterior Sacrococcygeal Ligament	6	5
Left Acetabular Labrum	4	5
Left Lateral Sacrococcygeal Ligament	4	3
Left Ischiofemoral Ligament	7	2
Right Sacrospinous Ligament	2	5
Right Round Ligament	4	3
Left Transverse Acetabular Ligament	7	5
Left Pubofemoral Ligament	1	1
Left Iliofemoral Ligament	9	9
Right Obturator Membrane	5	4
Left Zona Orbicularis	5	5

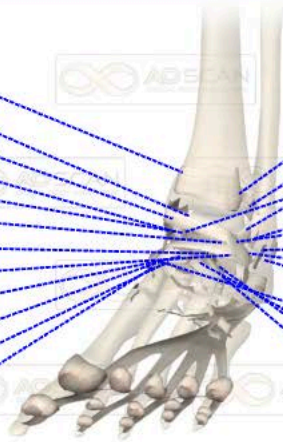


Left Olecranon Bursa	2	2
Left Ulnar Collateral Ligament Anterior	5	1
Left Annular Ligament	4	3
Left Ulnar Collateral Ligament Intermediate	5	3



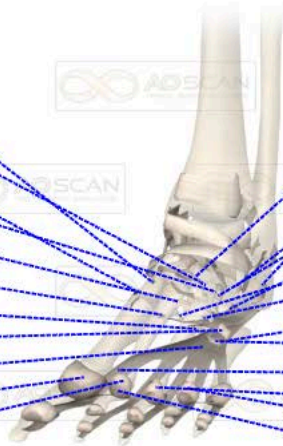
Left Elbow Capsule	5	3
Left Posterior Radiocollateral Ligament	5	3
Left Anterior Radiocollateral Ligament	7	5
Left Ulnar Collateral Ligament Posterior	7	3
Left Oblique Cord	3	4

Left Superior Extensor Retinaculum	7 9
Left Posterior Tibiotalar Ligament	4 2
Left Anterior Tibiotalar Ligament	2 2
Left Tibeonavicular Ligament	5 5
Left Dorsal Talonavicular Ligament	7 5
Left Posterior Talocalcaneal Ligament	2 4
Left Medial Talocalcaneal Ligament	5 5
Left Flexor Retinaculum Foot	2 1
Left Dorsal Cuneonavicular Ligament 4	4 3
Left Dorsal Tarsometatarsal Ligament 1	3 4
Left Dorsal Intercuneiform Ligament 1	4 2
Left Dorsal Cuneonavicular Ligament 2	5 1



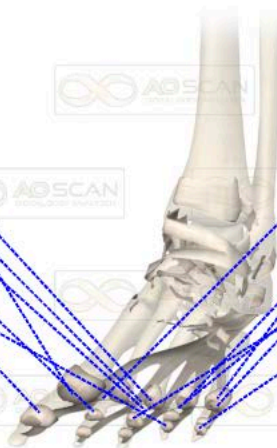Left Posterior Tibiofibular Ligament	6 3
Left Anterior Tibiofibular Ligament	2 2
Left Anterior Talofibular Ligament	5 5
Left Tibiocalcaneal Ligament	7 9
Left Posterior Talofibular Ligament	5 1
Left Inferior Extensor Retinaculum	7 9
Left Calcaneofibular Ligament	5 8
Left Lateral Talocalcaneal Ligament	4 8
Left Superior Peroneal Calcaneonavicular Ligament	7 9
Left Plantar Calcaneonavicular Ligament	5 5
Left Dorsal Cuneonavicular Ligament 3	5 7
Left Bifurcate Ligament	3 1
Left Dorsal Cuboideonavicular Ligament	5 5

Left Dorsal Cuneonavicular Ligament 1	5 3
Left Dorsal Tarsometatarsal Ligament 3	5 5
Left Plantar Metatarsal Ligament 1	7 9
Left Plantar Cuboideonavicular Ligament	7 9
Left Dorsal Metatarsal Ligament 1	7 9
Left Dorsal Tarsometatarsal Ligament 2	5 5
Left Plantar Metatarsal Ligament 3	5 1
Left Dorsal Metatarsal Ligament 3	5 5
Left Long Plantar Ligament	7 9
Left Proximal Joint Capsule Foot 1	7 9
Left Proximal Joint Capsule Foot 2	2 1



Left Dorsal Intercuneiform Ligament 2	3 3
Left Inferior Peroneal Retinaculum	5 8
Left Dorsal Calcaneocuboid Ligament	5 1
Left Dorsal Tarsometatarsal Ligament 4	1 2
Left Short Plantar Ligament	7 5
Left Plantar Metatarsal Ligament 2	8 4
Left Dorsal Metatarsal Ligament 2	5 1
Left Dorsal Tarsometatarsal Ligament 5	5 5
Left Plantar Metatarsal Ligament 4	4 6
Left Plantar Fascia	5 8
Left Proximal Joint Capsule Foot 3	7 3
Left Proximal Joint Capsule Foot 4	7 9
Left Plantar Ligament Plate 2	5 5

- Left Plantar Ligament Plate 1 5 8
- Left Plantar Ligament Plate 3 6 5
- Left Deep Transverse Metatarsal Ligament 2 5 5
- Left Deep Transverse Metatarsal Ligament 3 6 6
- Left Distal Joint Capsule Foot 2 7 9
- Left Distal Joint Capsule Foot 1 5 8
- Left Distal Joint Capsule Foot 4 7 5



- Left Deep Transverse Metatarsal Ligament 1 5 5
- Left Proximal Joint Capsule Foot 5 1 2
- Left Plantar Ligament Plate 4 4 2
- Left Plantar Ligament Plate 5 5 8
- Left Deep Transverse Metatarsal Ligament 4 4 5
- Left Distal Joint Capsule Foot 3 5 5
- Left Distal Joint Capsule Foot 5 4 2



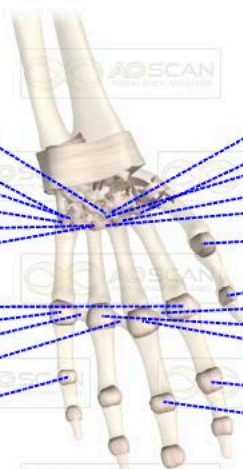Left Dorsal Radioulnar Ligament 1	5 6
Left Articular Disc	7 9
Left Dorsal Radioulnar Ligament 2	5 6
Left Radioscapholunate Ligament	4 5
Left Palmar Ulnolate Ligament	7 9
Left Interosseous Intercarpal Ligament 1	5 5
Left Scaphotrapezial Ligament 2	7 6
Left Ulnocarpal Ligament 1	5 6
Left Ulnocarpal Ligament 2	1 2
Left Dorsal Radiocarpal Ligament	7 9
Left Interosseous Intercarpal Ligament 2	4 2
Left Dorsal Intercarpal Ligament 9	5 5
Left Ulnar Arcuate Ligament	5 1
Left Medial Pisotriquetral Ligament	4 3

Left Retinaculum	7 5
Left Volar Radioulnar Ligament	7 5
Left Radioscaphocapitate Ligament	5 5
Left Radiolunate Ligament 1	4 2
Left Radial Collateralcarpal Ligament	5 5
Left Radialarcuate Ligament	5 5
Left Scaphotrapezial Ligament 1	6 7
Left Scaphotrapezial Ligament 3	5 3
Left Dorsal Intercarpal Ligament 7	5 5
Left Dorsal Carpometacarpal Ligament 6	2 2
Left Dorsal Intercarpal Ligament 6	5 5
Left Capitotrapezial Ligament	4 5
Left Dorsal Intercarpal Ligament 1	5 6

Left Dorsal Intercarpal Ligament 4	5 7
Left Dorsal Intercarpal Ligament 5	7 9
Left Dorsal Carpometacarpal Ligament 8	4 2
Left Dorsal Intercarpal Ligament 3	5 5
Left Capitoamate Ligament	4 5
Left Pisometacarpal Ligament	5 5
Left Dorsal Carpometacarpal Ligament 5	5 4
Left Dorsal Carpometacarpal Ligament 4	5 1
Left Dorsal Carpometacarpal Ligament 2	1 2
Left Palmar Carpometacarpal Ligament 5	5 2
Left Palmar Carpometacarpal Ligament 2	5 1

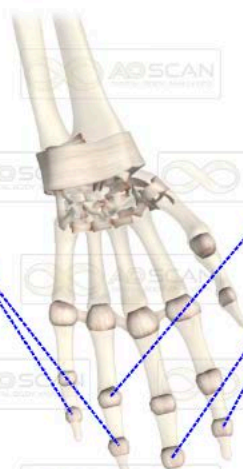
Left Dorsal Intercarpal Ligament 2	6 4
Left Thumb Capsule	7 5
Left Dorsal Carpometacarpal Ligament 9	5 1
Left Dorsal Carpometacarpal Ligament 10	5 5
Left Dorsal Carpometacarpal Ligament 7	4 3
Left Pisohamate Ligament	7 9
Left Dorsal Carpometacarpal Ligament 14	6 3
Left Trapeziometacarpal Ligament	6 5
Left Dorsal Carpometacarpal Ligament 3	5 5
Left Radiolunate Ligament 2	5 5
Left Dorsal Carpometacarpal Ligament 13	5 5

Left Palmar Carpometacarpal Ligament 3	4 4
Left Dorsal Carpometacarpal Ligament 1	5 5
Left Dorsal Carpometacarpal Ligament 11	5 5
Left Palmar Carpometacarpal Ligament 6	5 5
Left Dorsal Carpometacarpal Ligament 12	5 5
Left Palmar Metacarpal Ligament 4	7 9
Left Proximal Joint Capsule Arm 2	4 2
Left Proximal Joint Capsule Arm 5	5 4
Left Deep Transverse Metacarpal Ligament 3	8 8
Left Deep Transverse Metacarpal Ligament 2	8 4
Left Medial Joint Capsule Arm 5	6 5



Left Palmar Carpometacarpal Ligament 1	5 5
Left Palmar Metacarpal Ligament 1	1 5
Left Palmar Carpometacarpal Ligament 4	5 7
Left Palmar Metacarpal Ligament 2	4 2
Left Palmar Metacarpal Ligament 3	5 7
Left Proximal Joint Capsule Arm 1	5 5
Left Distal Joint Capsule Arm 1	7 8
Left Deep Transverse Metacarpal Ligament 1	7 5
Left Proximal Joint Capsule Arm 4	4 2
Left Proximal Joint Capsule Arm 3	7 5
Left Medial Joint Capsule Arm 2	5 5
Left Medial Joint Capsule Arm 3	4 2

Left Distal Joint Capsule Arm 5	5 3
Left Distal Joint Capsule Arm 4	5 5



Left Medial Joint Capsule Arm 4	3 5
Left Distal Joint Capsule Arm 2	5 3
Left Distal Joint Capsule Arm 3	3 1

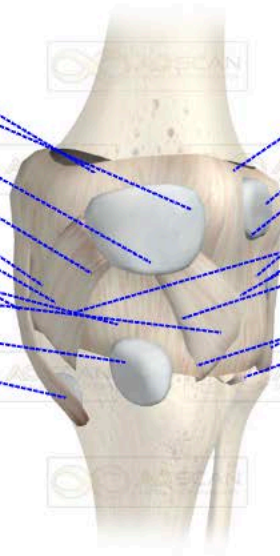


## Connective Tissue: Left Knee

% From Ideal: 32

Left Medial Gastrocnemius Bursa	5	1
Left Subcutaneous Prepatellar Bursa	7	5
Left Anterior Cruciate Ligament	5	5
Left Oblique Popliteal Ligament	5	4
Left Medial Meniscus	5	5
Left Semimembranosus Bursa	5	1
Left Tibial Collateral Ligament	1	2
Left Posterior Cruciate Ligament	5	5
Left Lateral Patellar Ligament	5	5
Left Deep Infrapatellar Bursa	5	5
Left Anserine Bursa	5	5

Left Lateral Gastrocnemius Bursa	5	5
Left Iliotibial Tract Bursa	5	5
Left Arcuate Popliteal Ligament	5	5
Left Biceps Femoris Bursa	5	5
Left Fibular Collateral Bursa	5	5
Left Lateral Meniscus	5	5
Left Medial Patellar Ligament	4	5
Left Transverse Ligament	5	4
Left Fibular Collateral Ligament	5	5
Left Knee Joint Capsule	4	5
Left Fibular Ligament	7	5

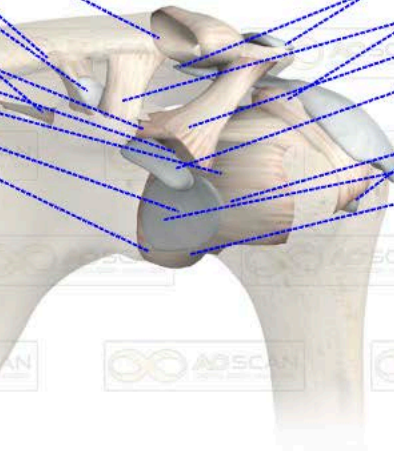


## Connective Tissue: Left Shoulder

% From Ideal: 39

Left Acromioclavicular Ligament	5	4
Left Conoid Ligament	5	1
Left Coracoclavicular Bursa	7	5
Left Superior Transverse Ligament	5	5
Left Coracohumeral Ligament	5	5
Left Infraspinatus Bursa	4	5
Left Superior Glenohumeral Ligament	5	5
Left Subscapular Bursa	5	5
Left Capsular Ligament	4	5

Left Supra Acromion Bursa	7	5
Left Subdeltoid Bursa	5	5
Left Transverse Humeral Ligament	5	5
Left Trapezoid Ligament	5	5
Left Coracocromial Ligament	5	1
Left Inferior Coracoid Bursa	5	5
Left Intertubercular Tendon Sheath	2	1
Left Middle Glenohumeral Ligament	7	5
Left Glenoid Labrum	5	5
Left Inferior Glenohumeral Ligament	5	5



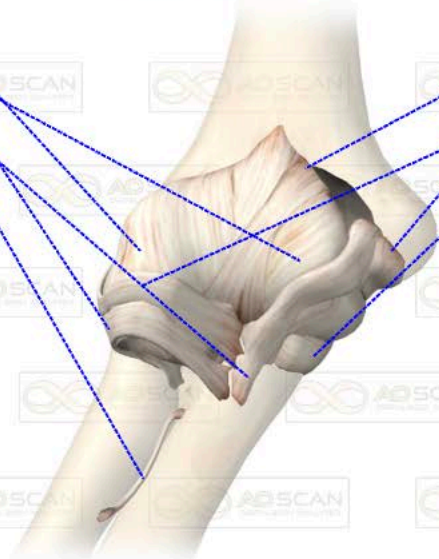


### Connective Tissue: Right Elbow

% From Ideal: 25

Right Posterior Radiocollateral Ligament	6	3
Right Olecranon Bursa	5	4
Right Annular Ligament	5	2
Right Ulnar Collateral Ligament Posterior	5	5
Right Oblique Cord	5	5

Right Elbow Capsule	5	5
Right Ulnar Collateral Ligament Anterior	5	4
Right Anterior Radiocollateral Ligament	5	5
Right Ulnar Collateral Ligament Intermediate	5	4

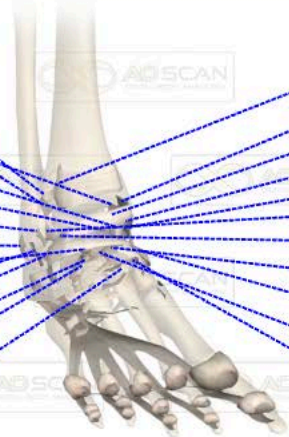


### Connective Tissue: Right Foot

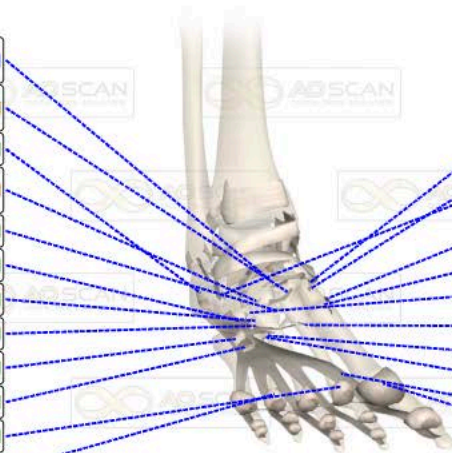
% From Ideal: 29

Right Posterior Tibiofibular Ligament	5	5
Right Anterior Tibiofibular Ligament	6	6
Right Inferior Extensor Retinaculum	5	5
Right Anterior Tibiotalar Ligament	5	8
Right Dorsal Talonavicular Ligament	6	4
Right Posterior Talofibular Ligament	1	1
Right Superior Peroneal Retinaculum	4	3
Right Medial Talocalcaneal Ligament	5	5
Right Calcaneofibular Ligament	4	2
Right Lateral Talocalcaneal Ligament	5	5
Right Bifurcate Ligament	6	3
Right Dorsal Cuboideonavicular Ligament	5	5
Right Dorsal Tarsometatarsal Ligament	5	5

Right Superior Extensor Retinaculum	1	1
Right Flexor Retinaculum Foot	4	5
Right Posterior Tibiotalar Ligament	5	5
Right Tibionavicular Ligament	4	2
Right Tibiocalcaneal Ligament	5	5
Right Anterior Talofibular Ligament	3	4
Right Posterior Talocalcaneal Ligament	2	5
Right Dorsal Cuneonavicular Ligament	3	8
Right Plantar Calcaneonavicular Ligament	5	4
Right Dorsal Cuneonavicular Ligament	5	8
Right Dorsal Intercuneiform Ligament	5	8

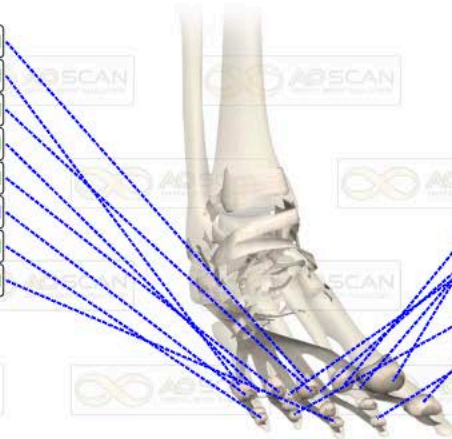


Right Dorsal Intercuneiform Ligament 2	3 4
Right Plantar Cuboideonavicular Ligament	5 2
Right Inferior Peroneal Retinaculum	2 6
Right Dorsal Tarsometatarsal Ligament 4	4 2
Right Dorsal Metatarsal Ligament 1	5 5
Right Short Plantar Ligament	3 5
Right Dorsal Metatarsal Ligament 2	6 5
Right Long Plantar Ligament	2 5
Right Dorsal Metatarsal Ligament 3	5 5
Right Plantar Metatarsal Ligament 4	3 5
Right Proximal Joint Capsule Foot 2	5 6
Right Proximal Joint Capsule Foot 4	5 2



Right Dorsal Cuneonavicular Ligament 2	4 2
Right Dorsal Cuneonavicular Ligament 1	2 2
Right Dorsal Calcaneocuboid Ligament	4 6
Right Dorsal Tarsometatarsal Ligament 2	5 4
Right Dorsal Tarsometatarsal Ligament 1	2 9
Right Dorsal Tarsometatarsal Ligament 5	2 9
Right Plantar Metatarsal Ligament 1	4 5
Right Plantar Metatarsal Ligament 2	3 1
Right Plantar Metatarsal Ligament 3	3 4
Right Plantar Fascia	1 1
Right Proximal Joint Capsule Foot 1	5 5

Right Proximal Joint Capsule Foot 3	6 5
Right Proximal Joint Capsule Foot 5	5 5
Right Plantar Ligament Plate 3	3 6
Right Deep Transverse Metatarsal Ligament 4	5 5
Right Plantar Ligament Plate 4	2 5
Right Plantar Ligament Plate 5	2 4
Right Distal Joint Capsule Foot 5	3 5
Right Distal Joint Capsule Foot 3	6 5



Right Plantar Ligament Plate 1	2 5
Right Plantar Ligament Plate 2	5 6
Right Deep Transverse Metatarsal Ligament 1	8 8
Right Deep Transverse Metatarsal Ligament 2	4 2
Right Deep Transverse Metatarsal Ligament 3	5 3
Right Distal Joint Capsule Foot 1	6 3
Right Distal Joint Capsule Foot 4	3 5
Right Distal Joint Capsule Foot 2	3 5



Right Retinaculum	7 9
Right Dorsal Radioulnar Ligament 2	6 4
Right Radiolunate Ligament 1	5 5
Right Radioscaphocapitate Ligament	5 5
Right Radial Collateralcarpal Ligament	5 5
Right Palmar Ulnolunate Ligament	7 5
Right Scaphotrapezial Ligament 2	9 8
Right Scaphotrapezial Ligament 1	8 5
Right Dorsal Intercarpal Ligament 7	7 9
Right Dorsal Intercarpal Ligament 9	5 5
Right Radialarcuate Ligament	8 2
Right Dorsal Intercarpal Ligament 1	4 6
Right Thumb Capsule	7 5
Right Ulnar Arcuate Ligament	5 7

Right Dorsal Radioulnar Ligament 1	7 5
Right Volar Radioulnar Ligament	4 5
Right Articular Disc	4 5
Right Radioscapholunate Ligament	3 1
Right Interosseous Intercarpal Ligament 1	3 1
Right Ulnocarpal Ligament 1	5 7
Right Ulnocarpal Ligament 2	5 5
Right Scaphotrapezial Ligament 3	4 5
Right Interosseous Intercarpal Ligament 2	5 6
Right Radiolunate Ligament	5 7
Right Dorsal Radiocarpal Ligament	7 5
Right Dorsal Intercarpal Ligament 6	2 1
Right Dorsal Intercarpal Ligament 2	5 4
Right Dorsal Intercarpal Ligament 5	2 2

Right Dorsal Carpometacarpal Ligament 8	5 4
Right Dorsal Carpometacarpal Ligament 9	3 1
Right Dorsal Carpometacarpal Ligament 10	3 2
Right Dorsal Carpometacarpal Ligament 7	6 9
Right Dorsal Carpometacarpal Ligament 6	5 3
Right Dorsal Carpometacarpal Ligament 14	5 5
Right Dorsal Carpometacarpal Ligament 4	9 9
Right Trapeziometacarpal Ligament	5 5
Right Palmar Carpometacarpal Ligament 2	7 5

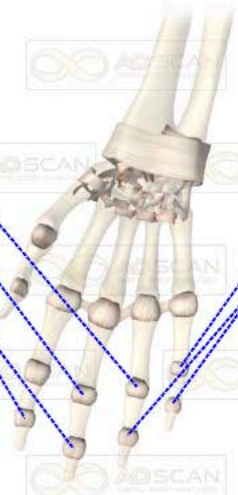
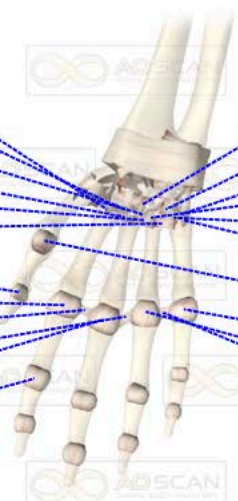
Right Medial Pisotriquetral Ligament	7 5
Right Dorsal Radioulnar Ligament 4	5 6
Right Dorsal Intercarpal Ligament 3	5 5
Right Capitoltrapezial Ligament	6 8
Right Pisohamate Ligament	2 4
Right Capitolhamate Ligament	2 2
Right Dorsal Carpometacarpal Ligament 5	6 7
Right Dorsal Carpometacarpal Ligament 3	5 5
Right Pisometacarpal Ligament	5 5
Right Palmar Carpometacarpal Ligament 5	7 9
Right Palmar Carpometacarpal Ligament 1	7 5

Right Palmar Metacarpal Ligament 1	9	9
Right Dorsal Carpometacarpal Ligament 13	9	8
Right Palmar Carpometacarpal Ligament 4	7	5
Right Palmar Metacarpal Ligament 2	5	1
Right Palmar Metacarpal Ligament 3	7	9
Right Palmar Metacarpal Ligament 4	4	5
Right Distal Joint Capsule Arm 1	7	5
Right Proximal Joint Capsule Arm 2	5	6
Right Deep Transverse Metacarpal Ligament 1	2	4
Right Deep Transverse Metacarpal Ligament 2	5	1
Right Proximal Joint Capsule Arm 3	9	9
Right Medial Joint Capsule Arm 2	6	8

Right Palmar Carpometacarpal Ligament 3	4	5
Right Dorsal Carpometacarpal Ligament 2	7	5
Right Dorsal Carpometacarpal Ligament 1	8	1
Right Dorsal Carpometacarpal Ligament 12	9	2
Right Dorsal Carpometacarpal Ligament 11	9	1
Right Palmar Carpometacarpal Ligament 6	5	7
Right Proximal Joint Capsule Arm 1	8	1
Right Proximal Joint Capsule Arm 5	5	5
Right Proximal Joint Capsule Arm 4	7	5
Right Deep Transverse Metacarpal Ligament 3	6	8

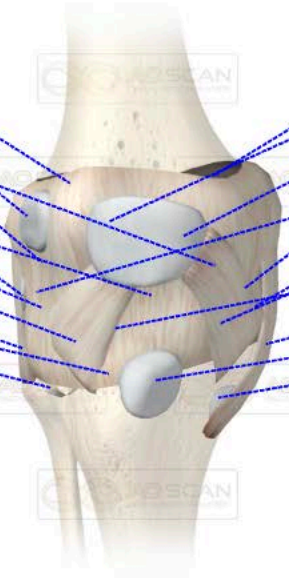
Right Medial Joint Capsule Arm 4	1	1
Right Medial Joint Capsule Arm 3	8	8
Right Distal Joint Capsule Arm 2	5	7
Right Distal Joint Capsule Arm 3	6	8

Right Medial Joint Capsule Arm 5	4	2
Right Distal Joint Capsule Arm 5	7	5
Right Distal Joint Capsule Arm 4	6	8



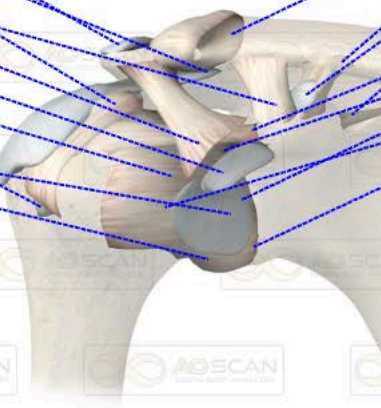
- Right Lateral Gastrocnemius Bursa 7 5
- Right Iliotibial Tract Bursa 4 4
- Right Arcuate Popliteal Ligament 2 5
- Right Oblique Popliteal Ligament 9 2
- Right Fibular Collateral Bursa 2 5
- Right Anterior Cruciate Ligament 5 5
- Right Lateral Meniscus 5 2
- Right Lateral Patellar Ligament 6 3
- Right Fibular Collateral Ligament 7 8
- Right Knee Joint Capsule 7 5
- Right Fibular Ligament 5 5

- Right Medial Gastrocnemius Bursa 4 5
- Right Subcutaneous Prepatellar Bursa 5 5
- Right Posterior Cruciate Ligament 7 8
- Right Semimembranosus Bursa 4 2
- Right Biceps Femoris Bursa 5 2
- Right Medial Meniscus 3 5
- Right Medial Patellar Ligament 6 3
- Right Transverse Ligament 5 3
- Right Tibial Collateral Ligament 5 1
- Right Deep Infrapatellar Bursa 5 5
- Right Anserine Bursa 7 9



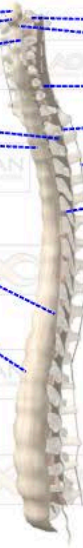- Right Supra Acromion Bursa 2 1
- Right Subdeltoid Bursa 3 5
- Right Transverse Humeral Ligament 5 5
- Right Trapezoid Ligament 2 2
- Right Coracoacromial Ligament 4 2
- Right Inferior Coracoid Bursa 3 5
- Right Superior Glenohumeral Ligament 4 2
- Right Intertubercular Tendon Sheath 5 2
- Right Subscapular Bursa 6 3
- Right Inferior Glenohumeral Ligament 9 8

- Right Acromioclavicular Ligament 4 5
- Right Conoid Ligament 4 2
- Right Coracoclavicular Bursa 6 5
- Right Superior Transverse Ligament 3 5
- Right Coracohumeral Ligament 7 5
- Right Infraspinatus Bursa 9 7
- Right Glenoid Labrum 5 3
- Right Middle Glenohumeral Ligament 6 3
- Right Capsular Ligament 3 5



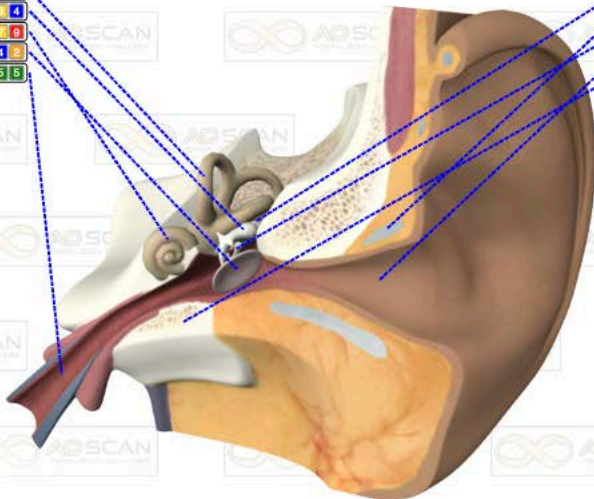
Anterior Atlanto Occipital Membrane	5	5
Alar Ligament	4	2
Tectorial membrane of atlanto axial joint	9	9
Interspinous Ligaments	5	6
Right Intertransverse Ligaments	6	6
Posterior Longitudinal Ligament	4	2
Anterior Longitudinal Ligament	7	5

Posterior Atlanto Occipital Membrane	5	5
Transverse ligament of Atlas	8	1
Nuchal Ligament	8	1
Supraspinous Ligament	5	7
Left Intertransverse Ligaments	8	1
Ligamenta Flava	7	9

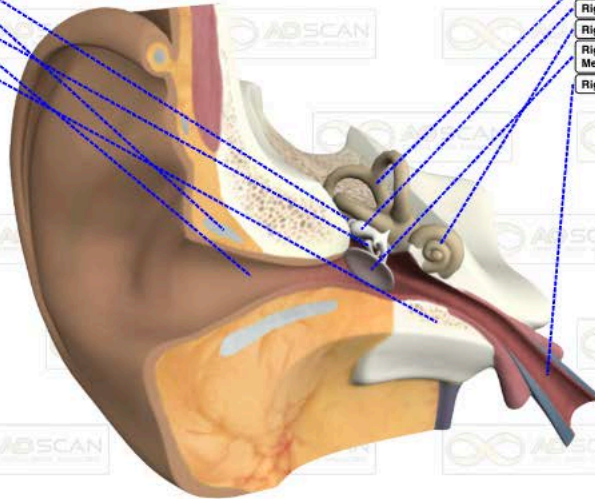


Left Semicircular Canals	6	9
Left Malleus	6	4
Left Cochlea	7	9
Left Tympanic Membrane	4	2
Left Nasopharynx	5	5

Left Incus	4	6
Left Cartilage	5	4
Left Stapes	6	1
Left Ear Canal	2	4
Left Mastoid Bone	7	9

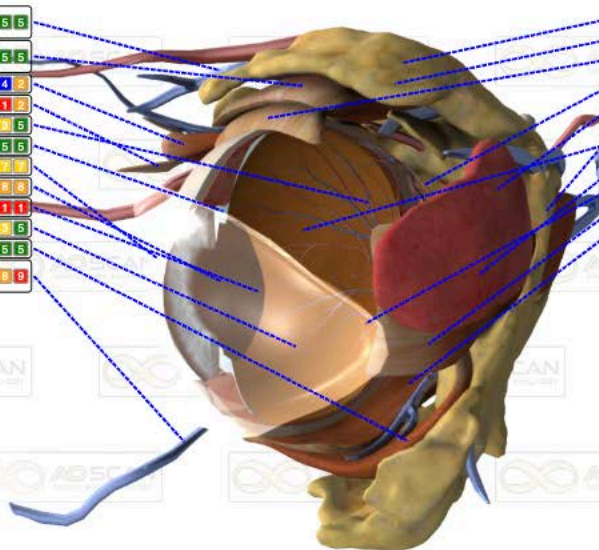


Right Incus	5	4
Right Cartilage	5	4
Right Stapes	5	1
Right Ear Canal	6	5
Right Mastoid Bone	5	8



Right Semicircular Canals	5	5
Right Malleus	5	8
Right Cochlea	4	2
Right Tympanic Membrane	5	1
Right Nasopharynx	5	8

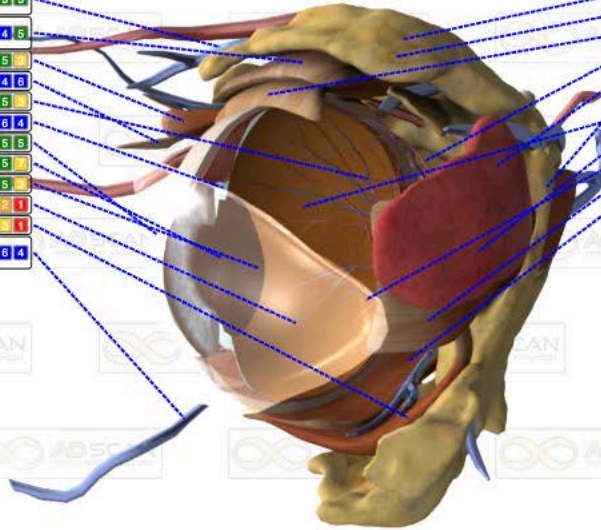
Left Superior Ophthalmic Vein	5	5
Left Levator Palpebrae Superioris	5	5
Left Superior Oblique	4	2
Left Trochlea	1	2
Left Retinal Veins	5	5
Left Fibers	5	5
Left Cornea	7	7
Left Lens	5	5
Left Sclera	1	1
Left Conjunctiva	5	5
Left Inferior Oblique	5	5
Left Inferior Ophthalmic Vein	5	8



Left Fat	4	8
Left Ophthalmic Artery	4	8
Left Superior Rectus	5	5
Left Retinal Arteries	2	4
Left Lacrimal Gland	7	5
Left Annular Ring	5	1
Left Retina	4	2
Left Lateral Rectus	4	8
Left Ciliary Body	4	5
Left Medial Rectus	5	5
Left Inferior Rectus	5	7

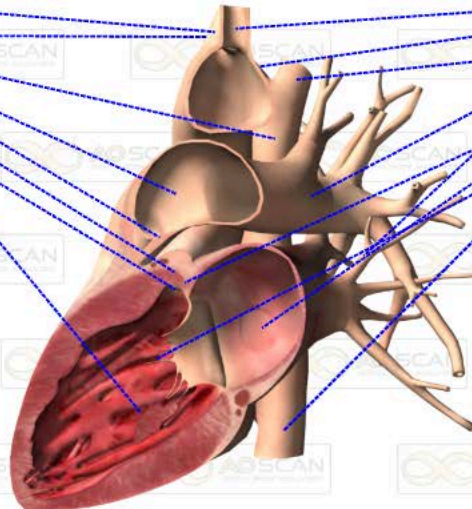
Right Superior Ophthalmic Vein	5	5
Right Levator Palpebrae Superioris	4	5
Right Superior Oblique	5	9
Right Trochlea	4	6
Right Retinal Veins	6	9
Right Fibers	6	4
Right Cornea	5	5
Right Lens	6	9
Right Sclera	5	9
Right Conjunctiva	2	1
Right Inferior Oblique	9	1
Right Inferior Ophthalmic Vein	3	4

Right Fat	4	5
Right Ophthalmic Artery	6	6
Right Superior Rectus	3	4
Right Retinal Arteries	3	4
Right Lacrimal Gland	4	4
Right Annular Ring	6	1
Right Retina	2	4
Right Lateral Rectus	3	4
Right Ciliary Body	3	3
Right Medial Rectus	7	3
Right Inferior Rectus	5	4



Brachiocephalic trunk	9	9
Left Common Carotid Artery	8	5
Superior Vena Cava	8	9
Pulmonary Trunk	7	5
Right Auricle	9	5
Left Semilunar Cusp	5	5
Posterior Semilunar Cusp	8	8
Posterior Papillary Muscle	9	1

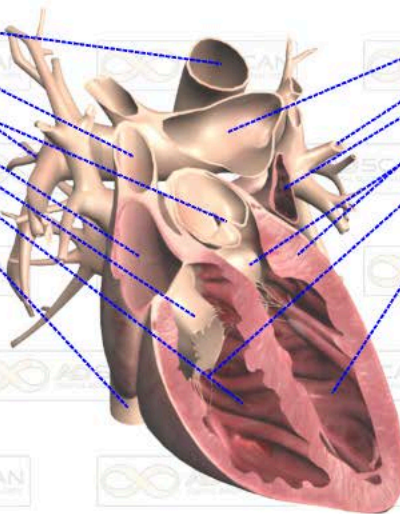
Left Subclavian Vein	5	5
Left Brachiocephalic Vein	5	9
Right Brachiocephalic Vein	9	1
Right Pulmonary Artery	4	4
Right Pulmonary Veins	1	1
Right Semilunar Cusp	9	9
Foramen Ovale	5	4
Chordae Tendineae	7	5
Inferior Vena Cava	9	1





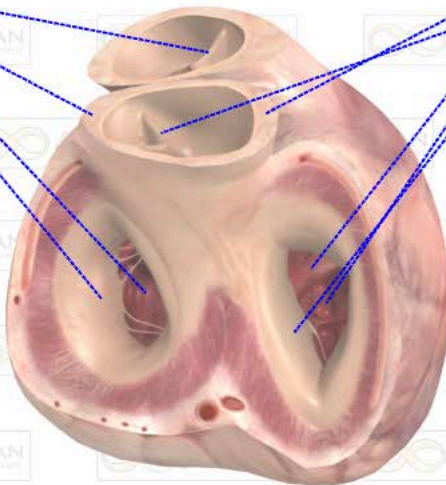
Aorta	5	5
Superior Vena Cava	5	5
Pulmonary Arteries	5	5
Aortic Valve	6	9
Right Atrium	6	6
Right AV Valve	6	9
Right Ventricle	4	2
Inferior Venacava	6	9

Pulmonary Trunk	2	2
Pulmonary Veins	9	9
Left Atrium	6	5
Papillary Muscle	5	5
Left AV Valve	6	6
Chordae Tendineae	7	5
Left Ventricle	9	5



Pulmonary Valve	6	6
Pulmonary Trunk	2	4
Left Ventricle	6	9
Left AV Valve	1	2

Aorta	6	5
Aortic Valve	1	9
Papillary Muscle	9	1
Right Ventricle	5	5
Right AV Valve	7	9






Lymphatic: Arms

% From Ideal: 42

- Right Deltopectoral Lymph Nodes **4 6**
- Right Lateral Axillary Humeral Lymph Nodes **7 5**
- Right Cubital Lymph Nodes **7 5**



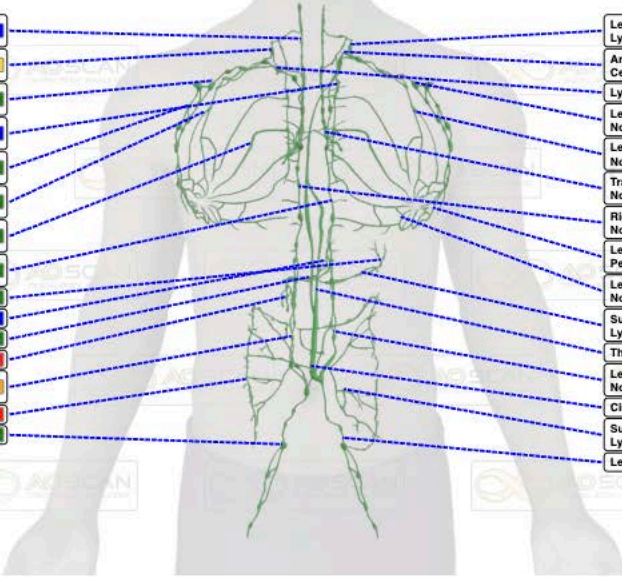
- Left Deltopectoral Lymph Nodes **6 5**
- Left Lateral Axillary Humeral Lymph Nodes **8 7**
- Left Cubital Lymph Nodes **8 1**



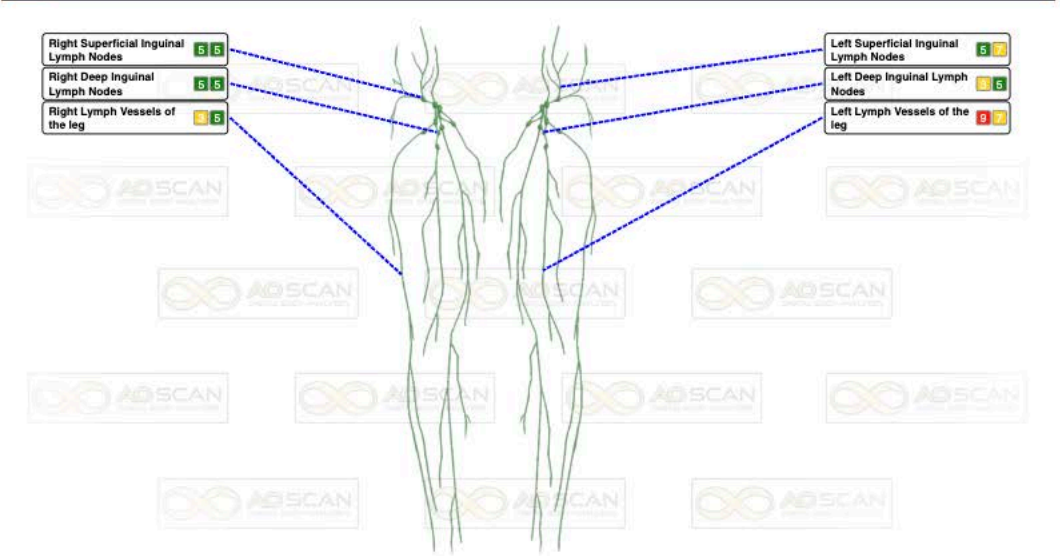
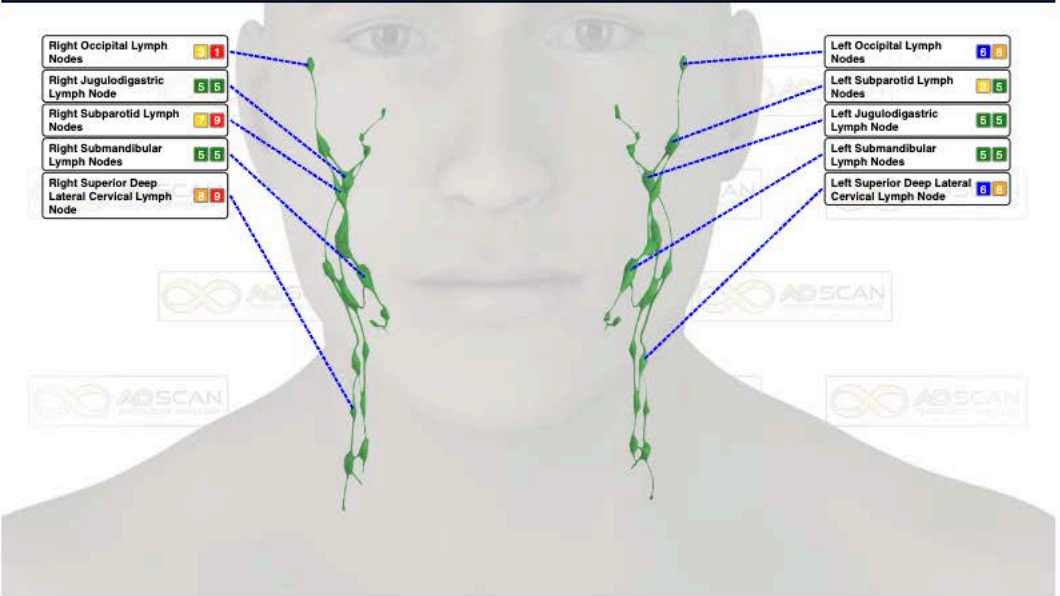
Lymphatic: Body Male

% From Ideal: 32

- Paratracheal Lymph Nodes **5 4**
- Right Juguloomohyoid Lymph Node **4 1**
- Right Apical Axillary Lymph Nodes **5 5**
- Bronchomediastinal Lymph Trunk **5 6**
- Right Anterior Axillary Pectoral Lymph Nodes **4 5**
- Right Interpectoral Lymph Nodes **7 5**
- Right Parasternal Lymph Nodes **7 5**
- Left Intercostal Lymph Nodes **4 5**
- Splenic Lymph Nodes **7 5**
- Gastric Lymph Nodes **6 4**
- Celiac Lymph Node **5 5**
- Pyloric Lymph Nodes **7 9**
- Right Phrenic Lymph Nodes **4 2**
- Paracolic Lymph Nodes **8 1**
- Right Iliac Lymph Nodes **5 5**



- Left Juguloomohyoid Lymph Node **5 5**
- Anterior Superficial Cervical Lymph Nodes **5 5**
- Lymphatic Duct **9 9**
- Left Apical Axillary Lymph Nodes **8 5**
- Left Interpectoral Lymph Nodes **5 5**
- Tracheobronchial Lymph Nodes **4 6**
- Right Intercostal Lymph Nodes **7 8**
- Left Anterior Axillary Pectoral Lymph Nodes **5 5**
- Left Parasternal Lymph Nodes **7 5**
- Superior Pancreatic Lymph Nodes **4 2**
- Thoracic Duct **7 8**
- Left Phrenic Lymph Nodes **5 1**
- Cisterna Chyli **8 1**
- Superior Mesenteric Lymph Nodes **8 1**
- Left Iliac Lymph Nodes **5 5**



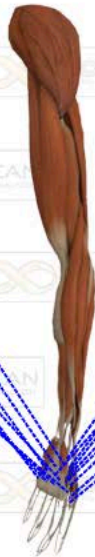

Left Biceps Brachii Long Head	6	6
Left Biceps Brachii Short Head	2	1
Left Triceps Long Head	2	4
Left Triceps Medial Head	4	5
Left Brachioradialis	5	2
Left Bicipital Aponeurosis	5	5
Left Supinator	4	5
Left Flexor Digitorum Superficialis	2	5
Left Flexor Carpi Radialis	6	4
Left Extensor Carpi Radialis Brevis	4	5
Left Abductor Pollicis Longus	2	5
Left Flexor Digitorum Profundus	5	4
Left Extensor Pollicis Brevis	2	1
Left Extensor Indicis	6	5
Left Palmaris Longus	2	1
Left Abductor Digiti Minimi Hand	5	3
Left Palmaris Brevis	6	6
Left Flexor Digiti Minimi Brevis Hand	6	5



Left Deltoid	9	1
Left Triceps Lateral Head	5	5
Left Brachialis	4	9
Left Triceps Tendon Medial Head	5	4
Left Extensor Carpi Radialis Longus	2	4
Left Pronator Teres	5	5
Left Anconeus	6	6
Left Flexor Carpi Ulnaris	9	8
Left Extensor Digiti Minimi	4	5
Left Extensor Digitorum	4	5
Left Extensor Carpi Ulnaris	5	6
Left Flexor Pollicis Longus	2	5
Left Extensor Pollicis Longus	6	3
Left Interosseous Membrane	4	2
Left Pronator Quadratus	5	5
Left Flexor Retinaculum Arm	6	5
Left Opponens Pollicis	4	8
Left Flexor Pollicis Brevis	4	9

Left Dorsal Interosseous 3b	5	5
Left Dorsal Interosseous 4b	4	5
Left Palmar Interosseous 3	6	1
Left Opponens Digiti Minimi	6	4
Left Palmar Interosseous 2	5	5
Left Lumbrical 4	5	5
Left Lumbrical 3	5	4
Left Dorsal Interosseous 2b	2	5



Left Abductor Pollicis Brevis	5	5
Left Adductor Pollicis	6	5
Left Palmar Interosseous 1	4	2
Left Dorsal Interosseous 4a	4	4
Left Dorsal Interosseous 3a	3	1
Left Lumbrical 2	6	5
Left Dorsal Interosseous 5	5	4
Left Dorsal Interosseous 2a	2	5
Left Lumbrical 1	4	1

Right Deltoid	6 5
Right Triceps Lateral Head	7 5
Right Triceps Long Head	5 5
Right Triceps Tendon Medial Head	5 5
Right Brachioradialis	5 4
Right Anconeus	1 1
Right Extensor Carpi Radialis Brevis	7 9
Right Supinator	5 1
Right Pronator Teres	7 5
Right Extensor Digitorum Ulnaris	5 5
Right Extensor Pollicis Longus	4 5
Right Extensor Pollicis Brevis	6 5
Right Extensor Indicis	5 5
Right Extensor Digiti Minimi	5 6
Right Opponens Pollicis	5 1
Right Flexor Pollicis Brevis	7 7
Right Abductor Pollicis Brevis	2 1

Right Biceps Brachii Long Head	6 4
Right Biceps Brachii Short Head	5 3
Right Brachialis	5 5
Right Triceps Medial Head	6 8
Right Bicipital Aponeurosis	5 6
Right Extensor Carpi Radialis Longus	7 8
Right Flexor Carpi Radialis	6 8
Right Flexor Carpi Ulnaris	5 5
Right Flexor Digitorum Superficialis	5 5
Right Abductor Pollicis Longus	7 5
Right Interosseous Membrane	5 5
Right Flexor Digitorum Profundus	5 8
Right Flexor Pollicis Longus	5 8
Right Pronator Quadratus	6 8
Right Palmaris Brevis	1 1
Right Flexor Retinaculum Arm	2 4

Right Opponens Digiti Minimi	6 7
Right Dorsal Interosseous 4a	4 6
Right Adductor Pollicis	5 3
Right Palmar Interosseous 1	5 5
Right Dorsal Interosseous 2a	4 5
Right Dorsal Interosseous 4	4 5
Right Lumbrical 2	6 4
Right Dorsal Interosseous 3a	5 5
Right Lumbrical 3	5 4
Right Lumbrical 1	6 8

Right Abductor Digiti Minimi Hand	6 5
Right Flexor Digiti Minimi Brevis Hand	6 8
Right Dorsal Interosseous 3b	3 2
Right Dorsal Interosseous 4b	6 5
Right Palmar Interosseous 2	3 1
Right Palmar Interosseous 3	4 5
Right Lumbrical 4	3 1
Right Dorsal Interosseous 2b	1 1
Right Palmaris Longus	6 9

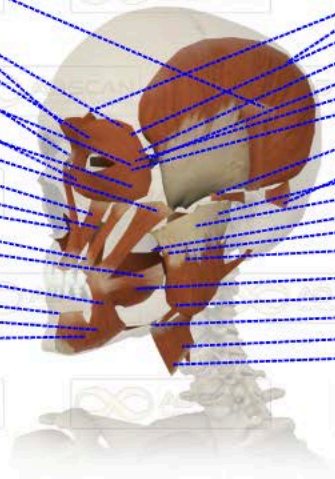


## Muscles: Head Left

% From Ideal: 20

Left Auricularis Superior	5	9
Left Depressor Supercilii	5	8
Left Levator Palpebrae	4	8
Left Trochlea	5	9
Left Levator Labii Superioris Alaeque Nasi	7	9
Left Medial Rectus	5	9
Left Orbicularis Oculi	5	1
Left Inferior Rectus	5	5
Left Zygomaticus Major	5	1
Left Levator Labii Superioris	5	7
Left Levator Anguli Oris	5	4
Left Nasalis Alar	7	5
Left Zygomaticus Minor	5	4
Left Risorius	5	5
Left Depressor Anguli Oris	6	4
Left Mentalis	5	5
Left Digastric	4	5
Left Depressor Labii Inferioris	7	9

Left Temporalis	5	4
Left Corrugator Supercilii	7	1
Left Superior Rectus	7	9
Left Superior Oblique	5	7
Left Common Tendinous Ring	5	9
Left Lateral Rectus	5	7
Left Inferior Oblique	7	9
Left Auricularis Anterior	5	9
Left Auricularis Posterior	5	1
Left Lateral Pterygoid Muscle	5	7
Left Masseter Deep	5	5
Left Levator Veli Palatini	6	9
Left Masseter Superior	5	1
Left Medial Pterygoid Muscle	5	5
Left Buccinator	7	5
Left Stylohyoid	5	4
F Fibrous Loop	5	4
Left Stylopharyngeus	7	8
Left Thyrohyoid	6	8

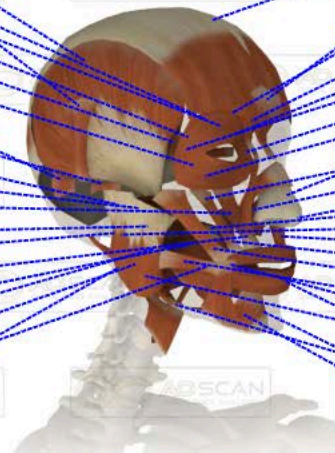


## Muscles: Head Right

% From Ideal: 33

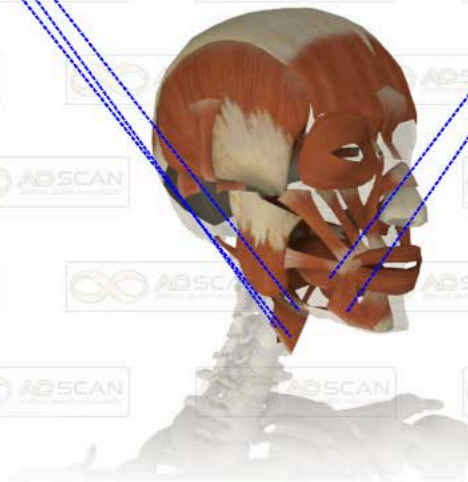Right Temporalis	6	4
Right Auricularis Superior	4	2
Right Levator Palpebrae	5	4
Right Superior Rectus	7	9
Right Superior Oblique	8	3
Right Common Tendinous Ring	7	5
Right Inferior Oblique	9	9
Right Auricularis Posterior	7	5
Right Auricularis Anterior	5	3
Right Lateral Pterygoid Muscle	3	1
Right Levator Veli Palatini	4	5
Right Levator Labii Superioris	5	5
Right Masseter Superior	7	5
Right Stylohyoid	5	5
Right Levator Labii Superioris Alaeque Nasi	6	4
Uvula muscle	5	1
Superior Constrictor	7	5
Right Medial Pterygoid Muscle	6	5
Right Buccinator	6	9
Right Digastric	7	9

Frontalis	9	5
Procerus	4	2
Right Corrugator Supercilii	5	5
Right Depressor Supercilii	5	8
Right Trochlea	5	9
Right Lateral Rectus	7	4
Right Orbicularis Oculi	6	9
Right Inferior Rectus	5	7
Nasalis Transverse	5	5
Right Zygomaticus Minor	5	5
Right Nasalis Alar	7	5
Nasal Cartilage	9	1
Palatine Aponeurosis	5	5
Right Masseter Deep	5	7
Depressor Septi Nasi	5	3
Right Levator Anguli Oris	9	9
Right Zygomaticus Major	5	1
Right Risorius	5	8
Palatoglossus	5	9
Medial Constrictor	5	9
Orbicularis Oris	9	1
Right Fibrous Loop	9	9
Right Mentalis	4	5
Right Depressor Labii Inferioris	6	4



Palatopharyngeal	5	5
Right Stylopharyngeus	7	5
Right Thyrohyoid	9	9

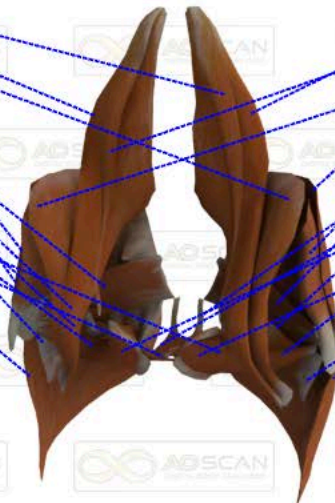
Genioglossus	8	8
Right Depressor Anguli Oris	5	5



 Muscles: Hips % From Ideal: 98

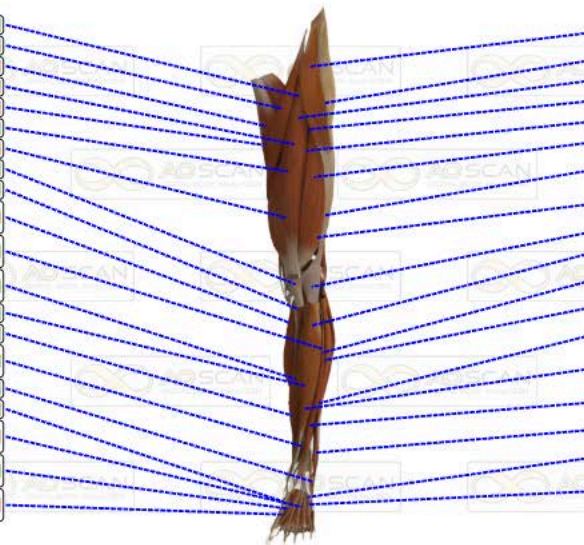
Left Psoas Minor	9	8
Right Psoas Major	5	4
Left Iliacus	8	9
Right Gluteus Medius	7	9
Right Gluteus Minimus	9	9
Right Piriformis	5	5
Right Superior Gemellus	4	5
Right Obturator Internus	5	5
Right Quadratus Femoris	4	9
Right Inferior Gemellus	5	5
Left Obturator Internus	5	5
Right Puborectalis	9	9
Right Gluteus Maximus	9	9

Left Psoas Major	7	9
Right Psoas Minor	9	5
Left Gluteus Medius	9	1
Right Iliacus	5	4
Left Gluteus Minimus	5	5
Left Piriformis	7	5
Left Pubococcygeus	5	5
Left Superior Gemellus	5	5
Right Pubococcygeus	6	9
Right Obturator Externus	7	9
Left Inferior Gemellus	7	9
Left Obturator Externus	7	9
Left Gluteus Maximus	4	5
Left Quadratus Femoris	7	5





Left Rectus Femoris	4	5
Left Sartorius	5	5
Left Adductor Longus	9	9
Left Adductor Brevis	4	5
Left Gracilis	7	9
Left Vastus Medialis	5	5
Left Semimembranosus	9	9
Left Patellar Ligament	4	5
Left Popliteus	5	5
Left Gastrocnemius Medial Head	8	8
Left Gastrocnemius Lateral Head	5	5
Left Flexor Digitorum Longus	4	5
Left Tibialis Anterior	7	5
Left Soleus	6	6
Left Interosseous Membrane Leg	4	5
Left Peroneus Tertius	4	5
Left Abductor Hallucis	4	5
Left Flexor Digitorum Brevis	8	1
Left Extensor Hallucis Brevis	5	5
Left Flexor Hallucis Brevis	9	9



Left Iliotibial Band Tensor Fascia Lata	5	8
Left Vastus Lateralis	5	5
Left Pectineus	7	5
Left Vastus Intermedius	5	5
Left Adductor Magnus	5	5
Left Semitendinosus	4	8
Left Biceps Femoris Long Head	8	1
Left Biceps Femoris Short Head	5	1
Left Plantaris	9	1
Left Tibialis Posterior	7	9
Left Extensor Digitorum Longus	7	5
Left Peroneus Longus	4	2
Left Calcaneal Achilles Tendon	5	7
Left Extensor Hallucis Longus	7	5
Left Flexor Hallucis Longus	4	5
Left Peroneus Brevis	5	5
Left Extensor Digitorum Brevis	8	8
Left Abductor Digiti Minimi Foot	7	5

Left Quadratus Plantae	5	9
Left Lumbrical	8	8
Left Interosseous Plantar	5	1



Left Interosseous Dorsal	5	5
Left Flexor Digiti Minimi Brevis	5	5
Left Abductor Hallucis	9	2



Right Iliotibial Band	5	7
Tensor Fascia Lata	5	7
Right Rectus Femoris	5	5
Right Vastus Lateralis	5	5
Right Vastus Intermedius	5	5
Right Adductor Longus	3	1
Right Semitendinosus	5	5
Right Biceps Femoris Long Head	7	9
Right Semimembranosus	7	5
Right Plantaris	4	2
Right Gastrocnemius Medial Head	4	2
Right Gastrocnemius Lateral Head	7	5
Right Extensor Digitorum Longus	7	5
Right Tibialis Anterior	7	9
Right Soleus	6	4
Right Peroneus Brevis	4	5
Right Peroneus Tertius	5	6
Right Extensor Hallucis Brevis	8	9
Right Quadratus Plantae	5	6
Right Extensor Digitorum Brevis	5	5

Right Sartorius	7	5
Right Pectineus	9	6
Right Adductor Brevis	6	6
Right Gracilis	6	6
Right Adductor Magnus	5	5
Right Vastus Medialis	5	5
Right Biceps Femoris Short Head	9	1
Right Patellar Ligament	6	7
Right Popliteus	9	6
Right Tibialis Posterior	5	6
Right Peroneus Longus	5	5
Right Flexor Digitorum Longus	9	1
Right Calcaneal Achilles Tendon	7	8
Right Flexor Hallucis Longus	5	4
Right Interosseous Membrane Leg	5	6
Right Extensor Hallucis Longus	5	5
Right Abductor Hallucis	5	6
Right Flexor Digitorum Brevis	6	6
Right Interosseous Dorsal	2	4

Right Abductor Digiti Minimi Foot	7	5
Right Lumbrical	5	6
Right Flexor Digiti Minimi Brevis	9	8

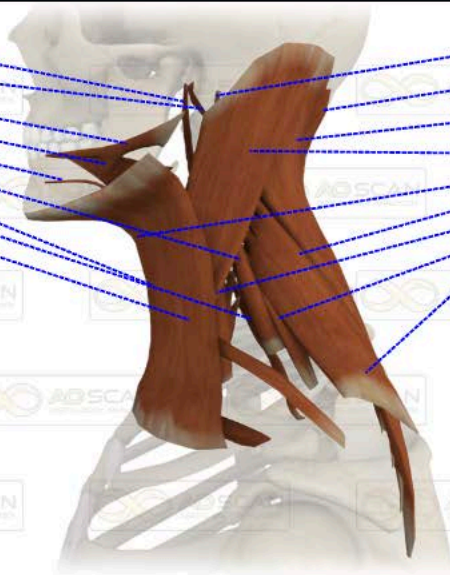Right Flexor Hallucis Brevis	9	1
Right Adductor Hallucis	4	2
Right Interosseous Plantar	6	5

## Muscles: Neck Left

% From Ideal: 32

Left Longus Capitis	6	9
Left Rectus Capitis Anterior	8	9
Left Styloglossus	5	5
Left Hyoglossus	8	5
Left Geniohyoid	4	5
Left Scalene Middle	5	5
Left Sternohyoid	7	5
Left Longus Colli	5	7
Left Omohyoid	7	9

Left Rectus Capitis Lateralis	4	2
Left Rectus Capitis Posterior Minor	1	1
Left Rectus Capitis Posterior Major	4	5
Left Obliquus Superior Capitis	3	5
Left Sternohyoid	6	9
Left Spinalis Cervicis	7	5
Left Scalene Anterior	4	5
Left Scalene Posterior	6	9
Left Longissimus Cervicis	5	5

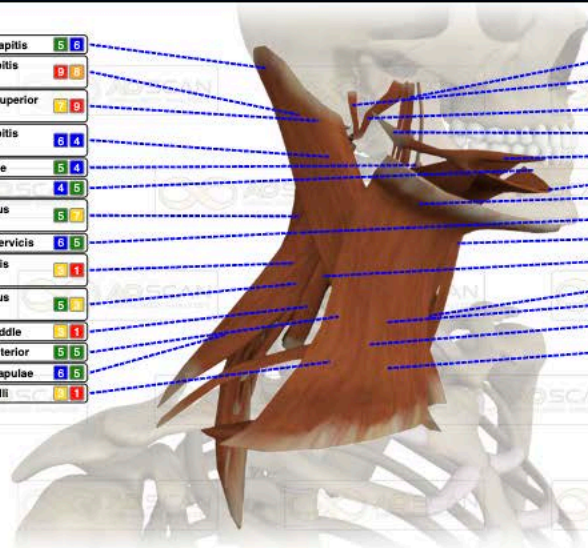


## Muscles: Neck Right

% From Ideal: 25

Right Splenius Capitis	5	5
Right Rectus Capitis Posterior Minor	9	9
Right Obliquus Superior Capitis	7	9
Right Rectus Capitis Posterior Major	3	4
Pharyngeal Raphe	5	4
Mylohyoid	4	5
Right Longissimus Capitis	5	7
Right Splenius Cervicis	6	5
Right Semispinalis Capitis	5	1
Right Longissimus Cervicis	5	7
Right Scalene Middle	5	1
Right Scalene Anterior	5	5
Right Levator Scapulae	6	5
Right Longus Colli	4	1

Right Longus Capitis	5	5
Right Rectus Capitis Lateralis	4	2
Right Rectus Capitis Anterior	4	6
Right Styloglossus	6	1
Right Hyoglossus	5	5
Right Geniohyoid	5	4
Inferior Constrictor	3	4
Right Spinalis Cervicis	5	5
Right Sternohyoid	7	9
Right Scalene Posterior	5	1
Right Sternothyroid	5	5
Right Omohyoid	4	2
Right Platysma	4	5
Right Sternocleidomastoid	5	5

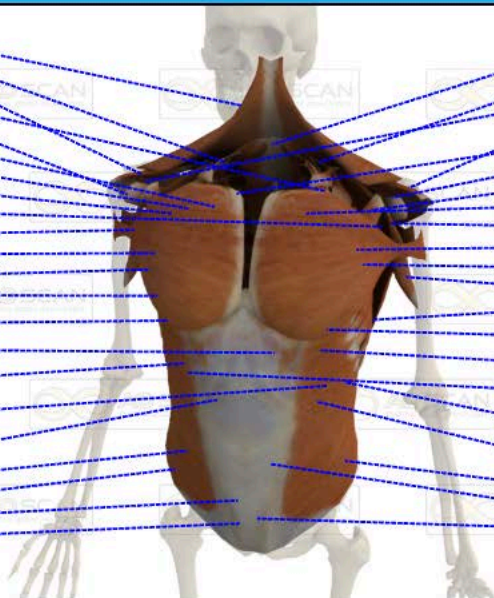




## Muscles: Torso

% From Ideal: 32

Trapezius	4	2
Right Rhomboid Minor	4	2
Right Supraspinatus	5	5
Left Rhomboid Major	6	8
Right Teres Minor	7	9
Right Pectoralis Major	7	5
Right Supscapularis	7	9
Right Teres Major	4	5
Left Teres Minor	6	4
Right Coracobrachialis	6	6
Right Pectoralis Minor	5	5
Right Latissimus Dorsi	6	4
Right Serratus Anterior	6	5
Right Innermost Intercostal Muscles	6	5
Serratus Posterior Inferior	7	9
Right Internal Intercostal Muscles	7	5
Left External Intercostal Muscles	5	5
Right Quadratus Lumborum	6	8
Transversus Abdominis	6	8
Right Internal Oblique	5	1
Coccygeus	5	4
Iliococcygeus	2	4



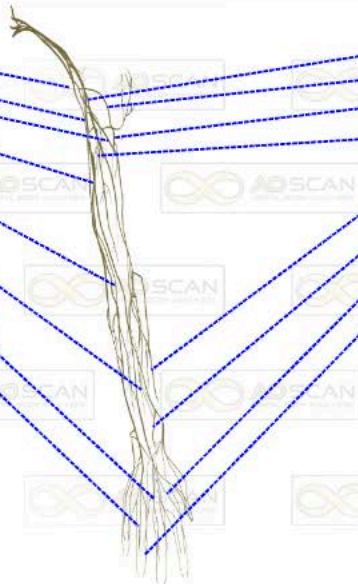
Serratus Posterior Superior	8	5
Left Rhomboid Minor	6	5
Right Infraspinatus	4	2
Left Supraspinatus	5	5
Right Rhomboid Major	5	8
Left Subscapularis	7	5
Left Infraspinatus	7	9
Left Pectoralis Major	5	6
Left Teres Major	4	5
Left Pectoralis Minor	5	5
Left Serratus Anterior	6	4
Left Coracobrachialis	5	5
Left Latissimus Dorsi	5	8
Left Innermost Intercostal Muscles	4	2
Diaphragm	7	5
Right External Intercostal Muscles	5	1
Left Internal Intercostal Muscles	1	1
Left Quadratus Lumborum	7	9
Left Internal Oblique	7	8
Right External Oblique	7	5
Rectus Abdominis	2	2



## Nerves: Arm Left

% From Ideal: 28

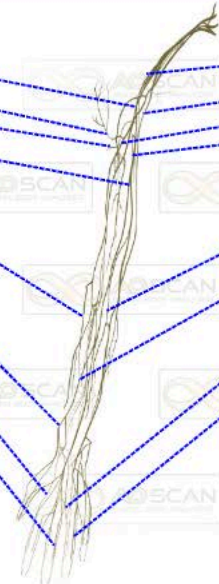
Left Suprascapular Nerve	4	2
Left Ulnar Nerve	6	4
Left Radial Nerve	6	4
Left Median Nerve	5	7
Left Medial Antebrachial Cutaneous	5	7
Left Deep Branch Radial Nerve	4	2
Left Dorsal Digital Branches Radial	4	5
Left Palmar Branch Ulnar Nerve	4	6



Left Musculocutaneous Nerve	7	5
Left Axillary Nerve	7	5
Left Posterior Brachial Cutaneous	4	2
Left Medial Brachial Cutaneous	8	5
Left Lateral Antebrachial Cutaneous	6	5
Left Superficial Branch Radial	7	5
Left Common Palmar Digital Branches Median	7	5
Left Proper Palmar Digital Branches Median	6	5

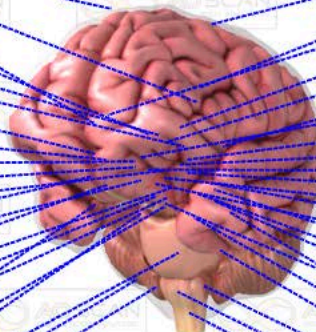
Right Musculocutaneous Nerve	9	9
Right Axillary Nerve	7	9
Right Posterior Brachial Cutaneous	7	9
Right Median Nerve	5	4
Right Lateral Antebrachial Cutaneous	4	4
Right Superficial Branch Radial	6	4
Right Dorsal Digital Branches Radial	6	5
Right Proper Palmar Digital Branches Median	7	5

Right Suprascapular Nerve	4	2
Right Ulnar Nerve	5	3
Right Radial Nerve	6	6
Right Medial Brachial Cutaneous	5	2
Right Medial Antebrachial Cutaneous	7	9
Right Deep Branch Radial Nerve	6	4
Right Common Palmar Digital Branches Median	5	6
Right Palmar Branch Ulnar Nerve	7	9



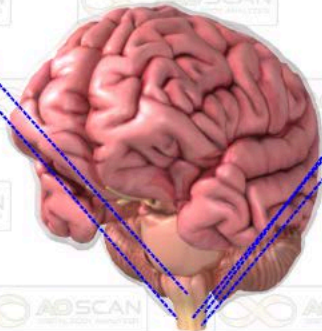
Outer Dura	7	9
Left Lateral Ventricle	4	2
Right Putamen	5	5
Right Interventricular Foramen	2	5
Left Caudate Nucleus	7	9
Left Putamen	7	5
Right Lateral Globus Pallidus	7	5
Right Medial Globus Pallidus	5	5
Right Fornix Crura	7	5
Right Thalamus	5	5
Left Fornix Columns	6	5
Right Amygdaloid Body	5	5
Right Hypothalamus	5	5
Right Caudate Nucleus	4	5
Left Mammillary Body	4	2
Right Mammillary Body	5	1
Left Subthalamic Nucleus	4	5
Right Hippocampus	6	6
Right Substantia Nigra	5	5
Pituitary Gland	5	2
Fourth Ventricle	6	5
Cerebellum	5	2
Right Olive	4	5

Cerebrum	5	1
Corpus Callosum	5	5
Right Lateral Ventricle	5	5
Left Fornix Body	4	2
Left Interventricular Foramen	6	5
Left Fornix Crura	6	4
Right Fornix Columns	5	6
Left Medial Globus Pallidus	4	5
Left Thalamus	5	6
Third Ventricle	5	6
Pineal Gland	6	6
Left Amygdaloid Body	4	1
Left Superior Colliculus	5	2
Left Hypothalamus	4	2
Right Superior Colliculus	3	5
Left Substantia Nigra	5	5
Left Inferior Colliculus	5	5
Right Inferior Colliculus	5	5
Left Hippocampus	6	4
Cerebral Aqueduct	7	9
Pons	5	2
Left Olive	6	2
Right Cuneate	5	5
Gracile Tubercle	6	2



Pyramid 2 5  
Right Medulla Oblongata 6 8

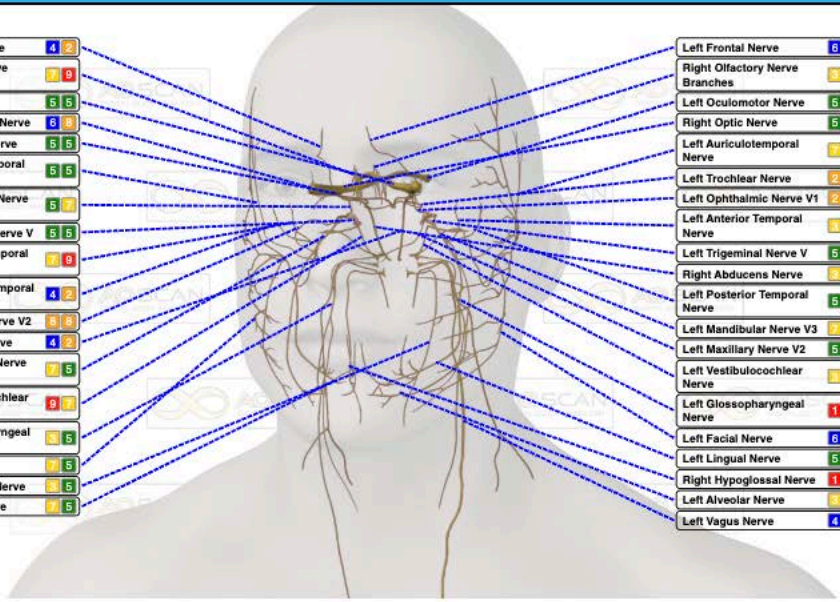
Left Cuneate 8 5  
Brain Stem Center 4 6  
Left Medulla Oblongata 1 5





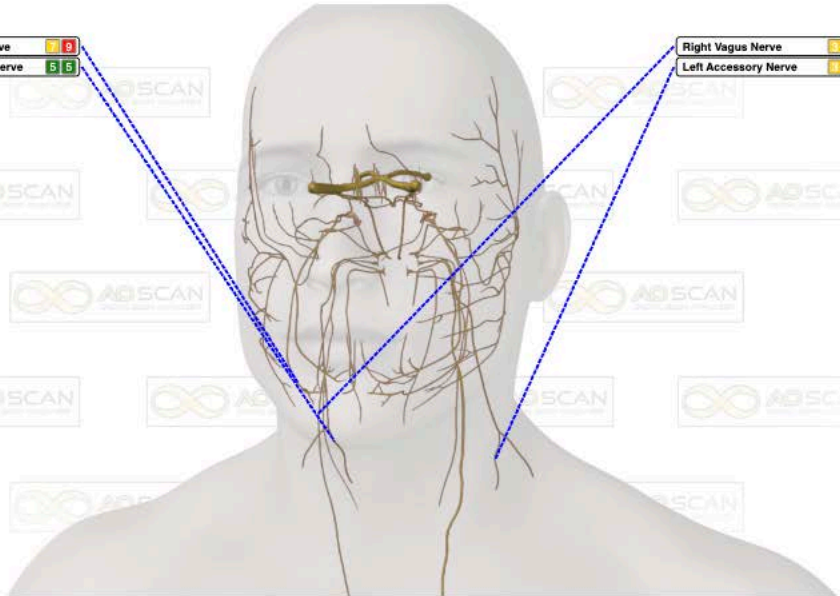
- Right Frontal Nerve 4 2
- Left Olfactory Nerve Branches 7 9
- Left Optic Nerve 5 5
- Right Oculomotor Nerve 5 5
- Right Trochlear Nerve 5 5
- Right Auriculotemporal Nerve 5 5
- Right Ophthalmic Nerve V1 5 7
- Right Trigeminal Nerve V 5 5
- Right Anterior Temporal Nerve 7 9
- Right Posterior Temporal Nerve 4 2
- Right Maxillary Nerve V2 6 8
- Left Abducens Nerve 4 2
- Right Mandibular Nerve V3 7 5
- Right Vestibulocochlear Nerve 9 7
- Right Glossopharyngeal Nerve 5 5
- Right Facial Nerve 7 5
- Left Hypoglossal Nerve 5 5
- Right Lingual Nerve 7 5

- Left Frontal Nerve 6 5
- Right Olfactory Nerve Branches 9 5
- Left Oculomotor Nerve 5 5
- Right Optic Nerve 5 5
- Left Auriculotemporal Nerve 7 5
- Left Trochlear Nerve 2 1
- Left Ophthalmic Nerve V1 2 4
- Left Anterior Temporal Nerve 8 1
- Left Trigeminal Nerve V 5 5
- Right Abducens Nerve 8 1
- Left Posterior Temporal Nerve 5 3
- Left Mandibular Nerve V3 7 5
- Left Maxillary Nerve V2 5 5
- Left Vestibulocochlear Nerve 9 1
- Left Glossopharyngeal Nerve 1 2
- Left Facial Nerve 6 5
- Left Lingual Nerve 5 7
- Right Hypoglossal Nerve 1 1
- Left Alveolar Nerve 5 1
- Left Vagus Nerve 4 2



- Right Alveolar Nerve 7 9
- Right Accessory Nerve 5 5

- Right Vagus Nerve 5 5
- Left Accessory Nerve 8 1



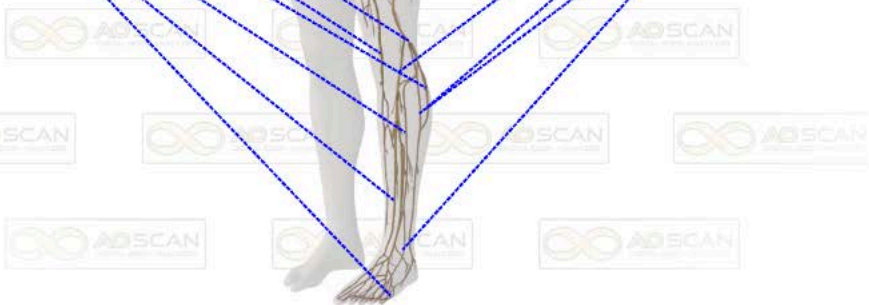


## Nerves: Leg Left

% From Ideal: 37

Left Obturator Nerve	5	1
Left Femoral Nerve	5	4
Left Common Peroneal Nerve	6	4
Left Saphenous Nerve	5	4
Left Lateral Sural Cutaneous	5	5
Left Superficial Peroneal Nerve	5	1
Left Deep Peroneal Nerve	2	6
Left Plantar Nerve	6	5

Left Lateral Femoral Cutaneous	5	1
Left Sciatic Nerve	2	1
Left Posterior Femoral Cutaneous	4	6
Left Tibial Nerve	5	1
Left Sural Communicating Branch	4	5
Left Medial Sural Nerve	5	5
Left Intermediate Dorsal Cutaneous	5	6

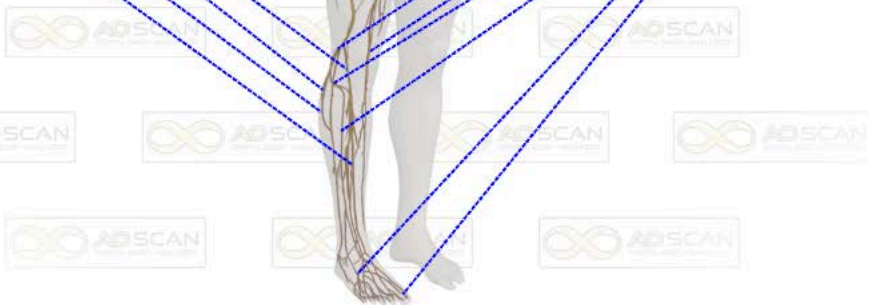


## Nerves: Leg Right

% From Ideal: 17

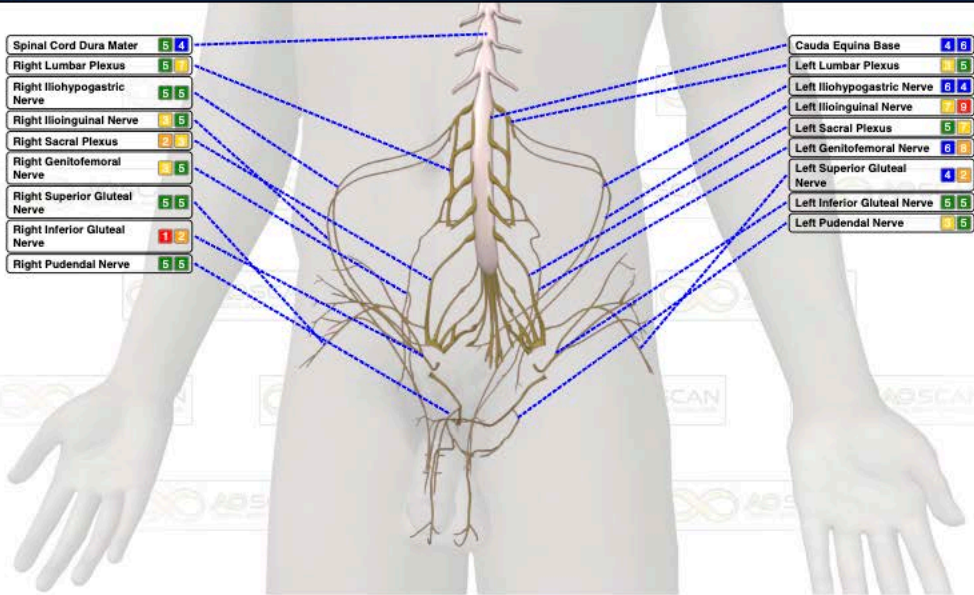
Right Lateral Femoral Cutaneous	6	6
Right Sciatic Nerve	4	5
Right Posterior Femoral Cutaneous	4	5
Right Tibial Nerve	5	1
Right Lateral Sural Cutaneous	5	5
Right Sural Communicating Branch	5	5
Right Superficial Peroneal Nerve	5	5
Right Deep Peroneal Nerve	6	5

Right Obturator Nerve	5	5
Right Femoral Nerve	5	6
Right Common Peroneal Nerve	4	5
Right Saphenous Nerve	5	5
Right Medial Sural Nerve	5	5
Right Superficial Peroneal Nerve	5	5
Right Intermediate Dorsal Cutaneous	6	5
Right Plantar Nerve	7	6



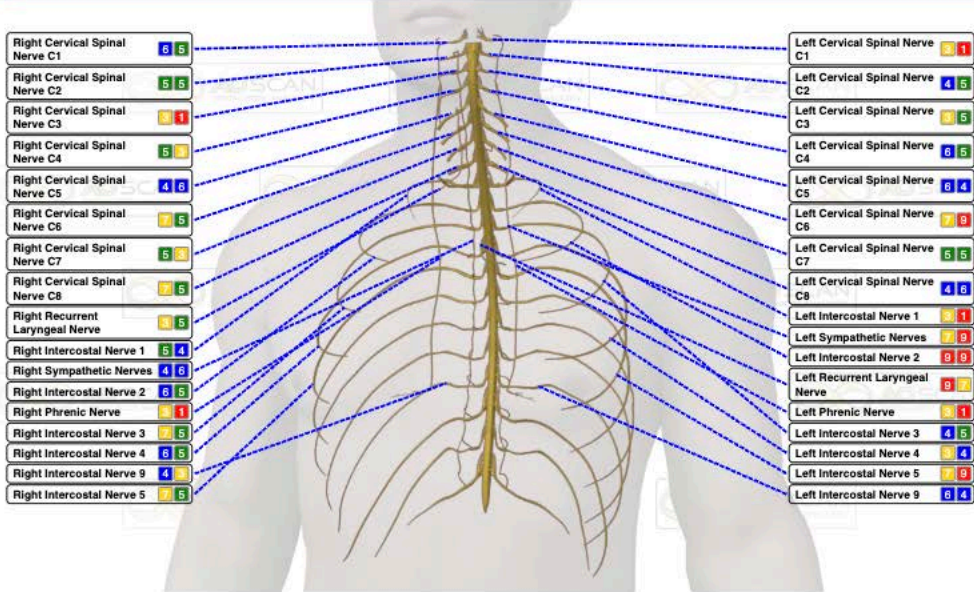
Spinal Cord Dura Mater	5	4
Right Lumbar Plexus	5	1
Right Iliohypogastric Nerve	5	5
Right Ilioinguinal Nerve	9	5
Right Sacral Plexus	2	9
Right Genitofemoral Nerve	9	5
Right Superior Gluteal Nerve	5	5
Right Inferior Gluteal Nerve	1	2
Right Pudendal Nerve	5	5

Cauda Equina Base	4	5
Left Lumbar Plexus	9	5
Left Iliohypogastric Nerve	6	4
Left Ilioinguinal Nerve	7	9
Left Sacral Plexus	5	7
Left Genitofemoral Nerve	8	8
Left Superior Gluteal Nerve	4	2
Left Inferior Gluteal Nerve	5	5
Left Pudendal Nerve	9	5



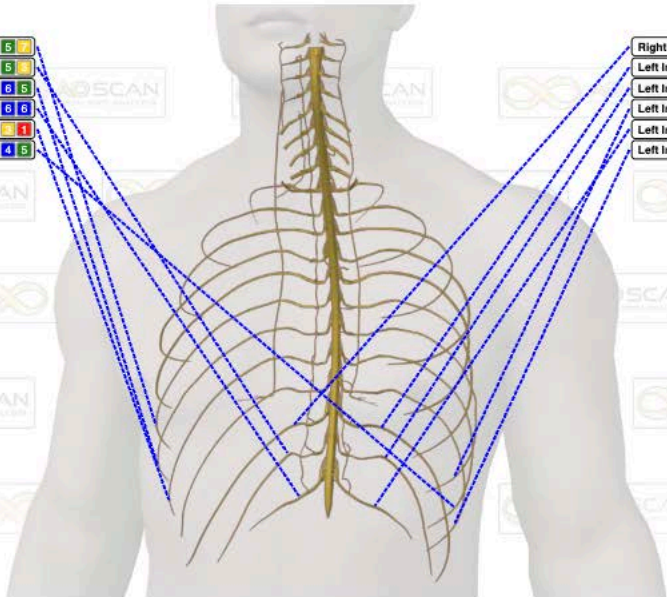
Right Cervical Spinal Nerve C1	6	5
Right Cervical Spinal Nerve C2	5	5
Right Cervical Spinal Nerve C3	9	1
Right Cervical Spinal Nerve C4	5	1
Right Cervical Spinal Nerve C5	4	6
Right Cervical Spinal Nerve C6	7	5
Right Cervical Spinal Nerve C7	5	2
Right Cervical Spinal Nerve C8	7	5
Right Recurrent Laryngeal Nerve	4	5
Right Intercostal Nerve 1	5	4
Right Sympathetic Nerves	4	6
Right Intercostal Nerve 2	6	5
Right Phrenic Nerve	9	1
Right Intercostal Nerve 3	7	5
Right Intercostal Nerve 4	6	5
Right Intercostal Nerve 5	4	9
Right Intercostal Nerve 5	7	5

Left Cervical Spinal Nerve C1	9	1
Left Cervical Spinal Nerve C2	4	5
Left Cervical Spinal Nerve C3	9	5
Left Cervical Spinal Nerve C4	6	5
Left Cervical Spinal Nerve C5	6	4
Left Cervical Spinal Nerve C6	7	6
Left Cervical Spinal Nerve C7	5	5
Left Cervical Spinal Nerve C8	4	6
Left Intercostal Nerve 1	9	1
Left Sympathetic Nerves	7	9
Left Intercostal Nerve 2	9	9
Left Recurrent Laryngeal Nerve	9	7
Left Phrenic Nerve	9	1
Left Intercostal Nerve 3	4	5
Left Intercostal Nerve 4	9	4
Left Intercostal Nerve 5	7	9
Left Intercostal Nerve 9	6	4



- Right Intercostal Nerve 6 5 7
- Right Intercostal Nerve 11 5 7
- Right Intercostal Nerve 7 8 5
- Right Intercostal Nerve 12 6 6
- Right Intercostal Nerve 8 9 1
- Left Intercostal Nerve 7 4 5

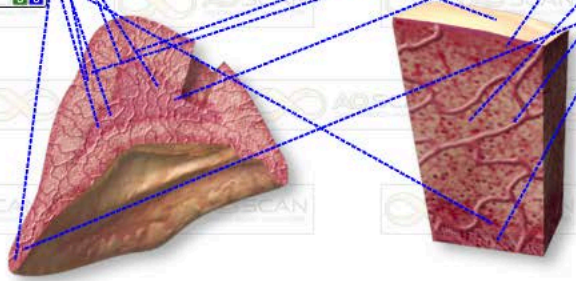
- Right Intercostal Nerve 10 5 8
- Left Intercostal Nerve 10 7 9
- Left Intercostal Nerve 11 7 5
- Left Intercostal Nerve 6 5 5
- Left Intercostal Nerve 12 8 4
- Left Intercostal Nerve 8 5 5



Organs: Adrenal Cross Section % From Ideal: 98

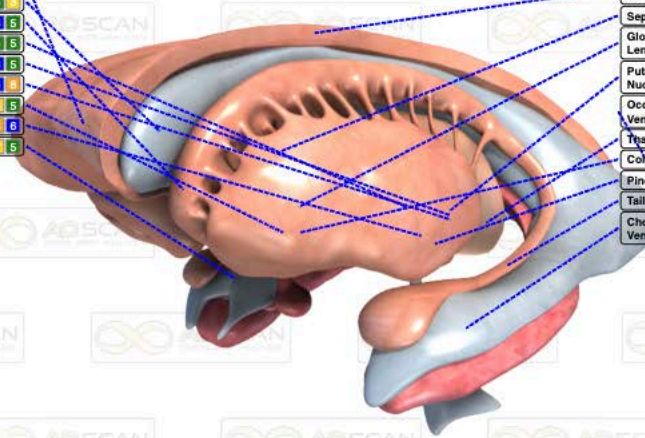
- Capsule 8 5
- Testosterone 4 9
- Cortisone 6 8
- Epinephrine 6 8
- Somatostatin 5 5
- Substance P 6 5
- Zona Reticularis 6 4
- Corticosterone 5 8

- Zona Glomerulosa 8 1
- Estrogen 9 5
- Cortisol 5 4
- Norepinephrine 6 5
- Zona Fasciculata 5 7
- Blood Vessels 6 5
- Medulla 9 5
- Aldosterone 1 1



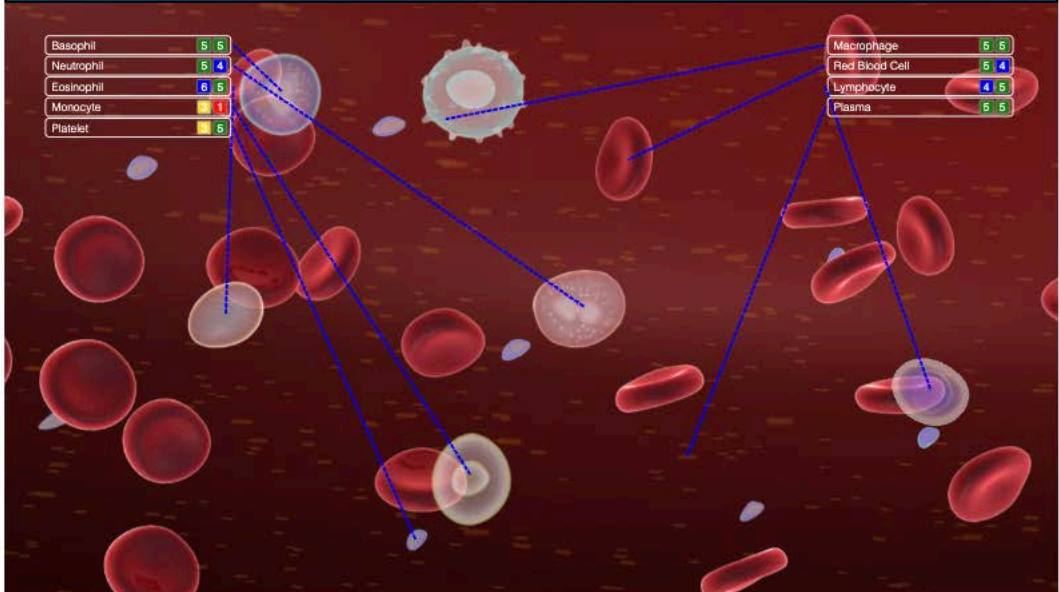
Genu of Corpus Callosum	9	9
Lateral Ventricle	5	9
Head of Caudate Nucleus	6	5
Interthalamic Adhesion	5	5
Clastrum	6	5
Insula (Island of Reil)	6	9
Hippocampus and Fornix	9	5
Habenula	8	6
3rd Ventricle	7	5

Splenium of Corpus Callosum	7	9
Septum Pellucidum	7	5
Globus Pallidus of Lentiform Nucleus	9	9
Putamen of Lentiform Nucleus	5	9
Occipital Horn of Lateral Ventricle	5	5
Thalamus	7	5
Column of Fornix	8	1
Pineal Body	6	4
Tail of Caudate Nucleus	6	4
Choroid Plexus of Lateral Ventricle	5	5



Basophil	5	5
Neutrophil	5	4
Eosinophil	6	5
Monocyte	9	1
Platelet	9	5

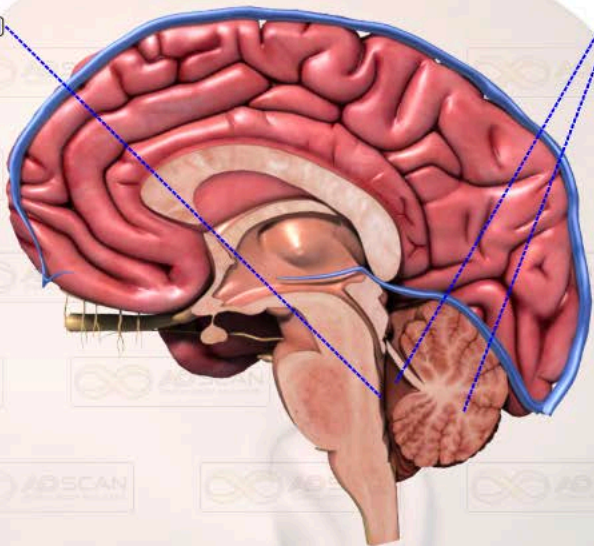
Macrophage	5	5
Red Blood Cell	5	4
Lymphocyte	4	5
Plasma	5	5





Superior Sagittal Sinus	1 1
Cingulate Gyrus	6 6
Medial Frontal Gyrus	6 9
Sulcus of Corpus Callosum	5 6
Corpus Callosum	6 4
Septum Pellucidum	6 6
Fornix	5 6
Subcallosal (perolfactory) Area	4 5
Paraterminal Gyrus	5 6
Thalamus (3rd ventricle)	6 9
Hypthalamic Sulcus	7 9
Lamina Terminalis	4 2
Pineal Body	6 1
Posterior Commissure	4 4
Optic Recess	6 6
Optic Chiasm	6 1
Mamillary Body	6 5
Inferior Colliculus	6 4
Tuber Cinereum	4 5
Hypophysis (pituitary gland)	7 5
Medulla Oblongata	5 5
Pons	6 5
Superior Medullary Velum	6 6

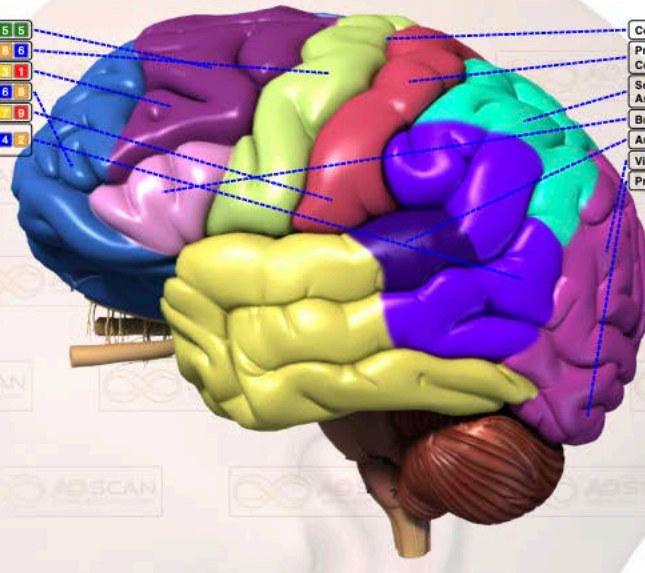
Paracentral Sulcus	7 5
Central Sulcus (of Rolando)	7 5
Cingulate Sulcus	4 2
Precuneus	7 9
Parietooccipital Sulcus	5 4
Stria Medullaris of Thalamus	8 6
Choroid Plexus of 3rd Ventricle	5 5
Interventricular Foramen	5 5
Anterior Commissure	5 1
Interthalamic Adhesion	5 5
Cuneus	6 4
Habenuar Commissure	6 6
Calcarine Sulcus	1 1
Superior Colliculus	5 5
Great Cerebral Vein (of Galen)	4 5
Cerebral Peduncle	7 9
Cerebral Aqueduct (of Sylvius)	5 5
Straight Sinus in Tentorium	6 4
Quadrigeminal (tectal) Lamina	4 6



Inferior Medullary Velum	6 4
--------------------------	-----

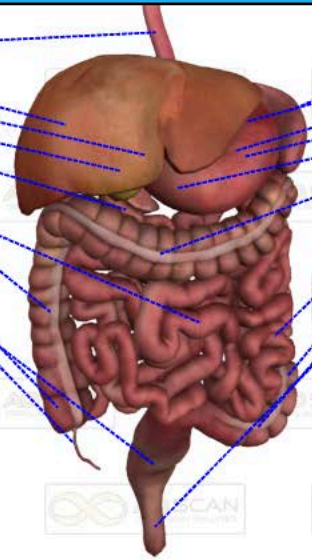
4th Ventricle and Choroid Plexus	5 1
Cerebellum	4 6

- Premotor Cortex 5 5
- Primary Motor Cortex 4 6
- Frontal Eye Field 8 1
- Prefrontal Cortex 8 8
- Primary Auditory Cortex 9 9
- Gustatory Cortex  
Wernicke's Area 4 2



- Central Sulcus 5 5
- Primary Somatosensory Cortex 7 9
- Somatosensory Association Cortex 4 2
- Broca's Area 7 9
- Auditory Association Area 5 4
- Visual Association Area 9 9
- Primary Visual Cortex 7 6

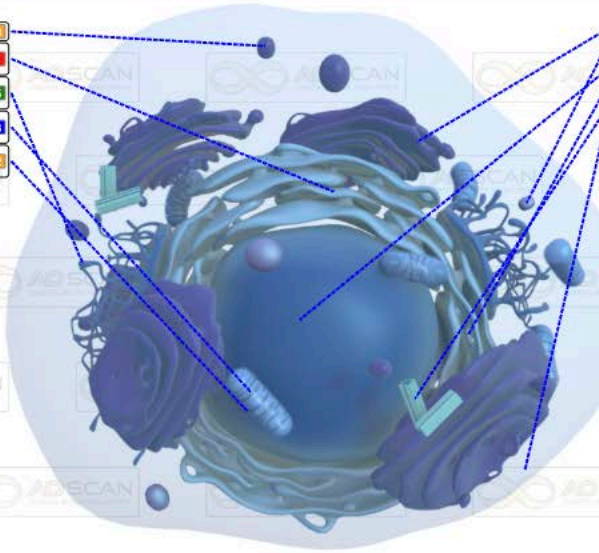
- Esophagus 4 2
- Liver 4 6
- Bile Duct 8 2
- Gallbladder 4 1
- Stomach Duodenum 5 6
- Ascending Colon 7 5
- Ilium 5 5
- Cecum 4 2
- Appendix 5 5
- Rectum 2 2



- Spleen 5 5
- Stomach Fundus 5 8
- Stomach Body 7 5
- Pancreas 7 5
- Stomach Pyloric 7 5
- Transverse Colon 7 5
- Jejunum 9 5
- Descending Colon 6 4
- Sigmoid Colon 5 9
- Anus 2 1

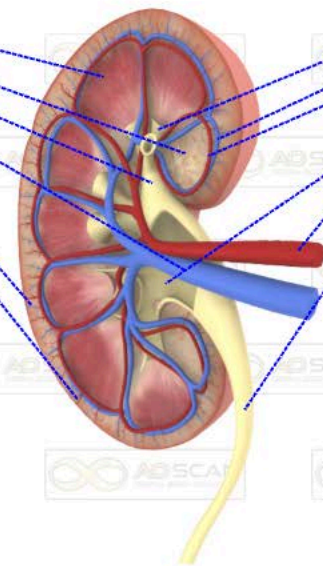
- Vacuole 6 3
- Rough Endoplasmic Reticulum 9 1
- Smooth Endoplasmic Reticulum 6 5
- Mitochondria Inner Membrane 6 6
- Mitochondria Outer Membrane 4 2

- Golgi Complex 5 4
- Lysosome 6 6
- Nucleus 7 5
- Ribosomes 4 3
- Centriole 5 5
- Plasma Membrane 9 8



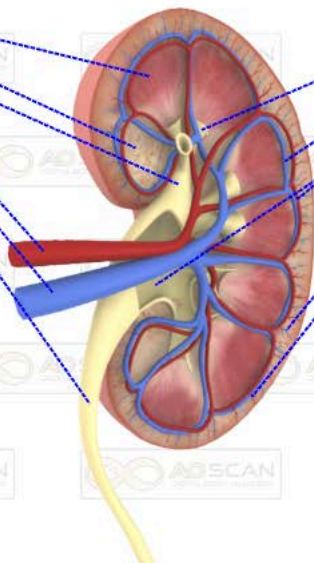
- Left Medulla 8 5
- Left Cortex 4 6
- Left Major Calyces 9 11
- Left Renal Vein 9 9
- Left Arcuate Vein 4 4
- Left Arcuate Arteries 6 9

- Left Minor Calyces 7 5
- Left Interlobular Veins 9 5
- Left Interlobular Arteries 4 5
- Left Renal Artery 6 5
- Left Renal Pelvis 7 9
- Left Ureter 6 9





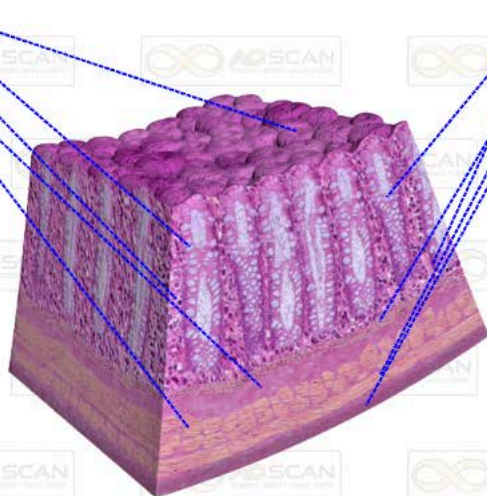
Right Medulla	5	6
Right Cortex	4	1
Right Major Calyces	2	4
Right Renal Artery	6	2
Right Renal Vein	7	5
Right Ureter	4	1



Right Minor Calyces	5	5
Right Interlobular Veins	7	5
Right Interlobular Arteries	8	5
Right Renal Pelvis	5	4
Right Arcuate Veins	4	2
Right Arcuate Arteries	6	2



Openings of Crypts	7	5
Goblet Cells	6	6
Simple Columnar Epithelium	8	4
Submucosa	4	2
Circular Muscle	1	1

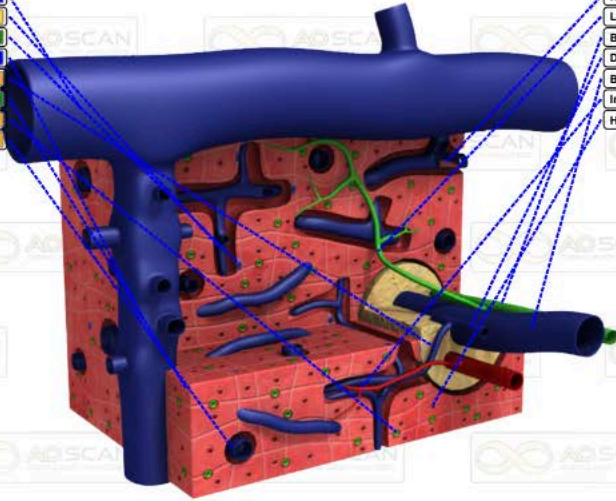


Crypts	5	5
Mucosa	7	9
Muscularis Mucosae	5	5
Longitudinal Muscle	4	6
Serosa	1	2



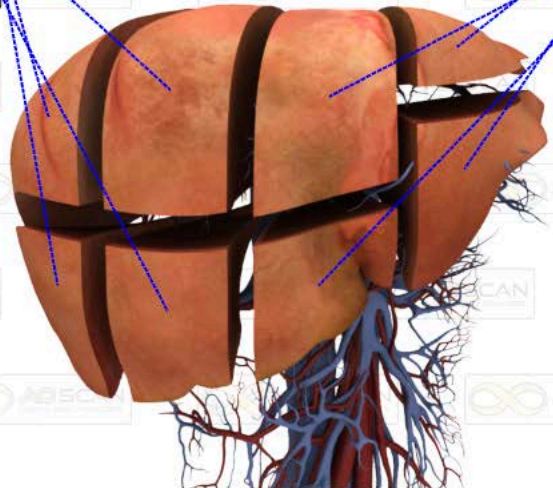
- Branch of Hepatic Vein 5 6
- Sinusoids 5 9
- Stellate Cells 4 5
- Central Vein 4 6
- Inlet Venule 1 2
- Liver Cell Plates 7 5
- Canaliculi 6 8
- Dise Spaces 7 8

- Kupffer Cells 6 8
- Lymph Vessel 9 7
- Bile Duct 5 5
- Distributing Vein 4 2
- Branch of Portal Vein 6 5
- Intralobular Arteriole 1 2
- Hepatocyte 5 5



- Right Lobe Segment 1 8 9
- Right Lobe Segment 2 7 6
- Right Lobe Segment 3 9 9
- Right Lobe Segment 4 5 5

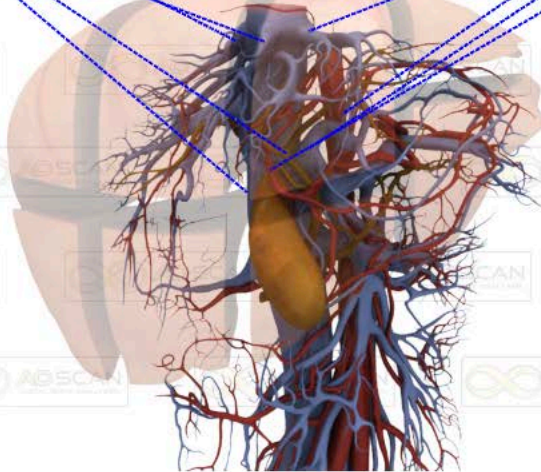
- Left Lobe Segment 2 9 1
- Left Lobe Segment 1 8 6
- Left Lobe Segment 3 9 9
- Left Lobe Segment 4 9 1





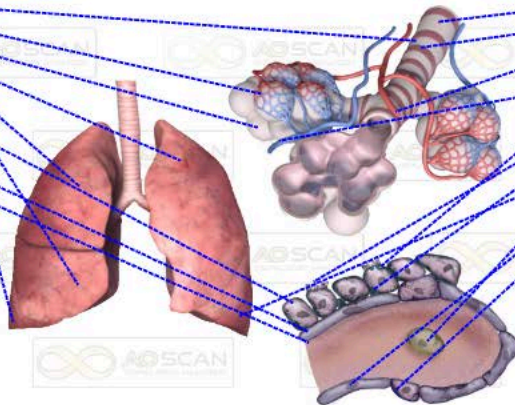
Left Hepatic Vein	5	5
Middle Hepatic Vein	7	9
Hepatic Duct	5	5
Inferior Venacava	4	5

Right Hepatic Vein	5	5
Umbilical Vein	6	1
Portal Vein	4	4
Hepatic Artery	2	4



Cartilage	4	2
Capillaries	6	4
Aveolar Sac	4	5
Left Superior Lobe	7	9
Right Superior Lobe	7	9
Right Middle Lobe	4	5
Goblet Cell	5	5
Right Inferior Lobe	4	2
Interstitial	6	5
Basement Membrane	7	5

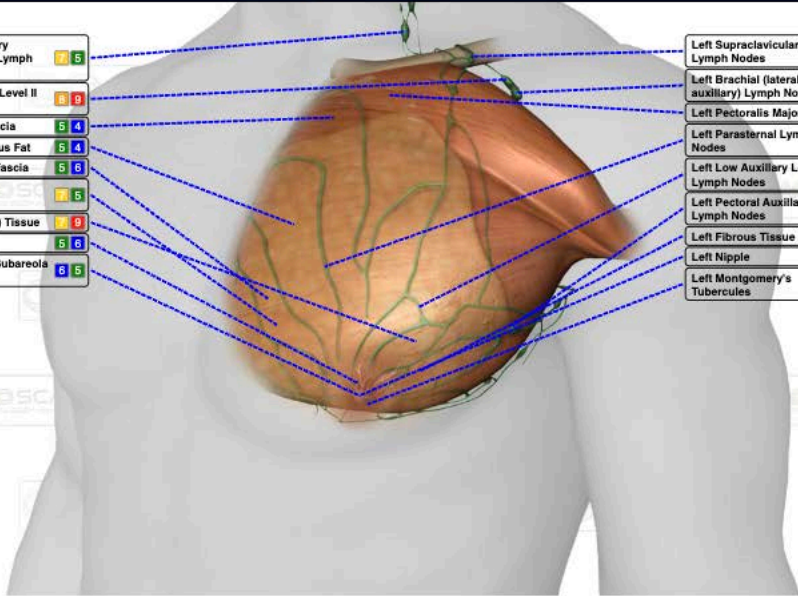
Bronchiole	5	5
Smooth Muscle	1	2
Branch Of pulmonary Artery	7	9
Branch Of Pulmonary Vein	7	9
Mucin Secretion	4	5
Ciliated Columnar Cell	6	1
Basal Cell	5	5
Left Inferior Lobe	4	6
Free Alveolar Macrophage	4	5
Type I Pneumocyte	6	5
Type II Pneumocyte	6	5





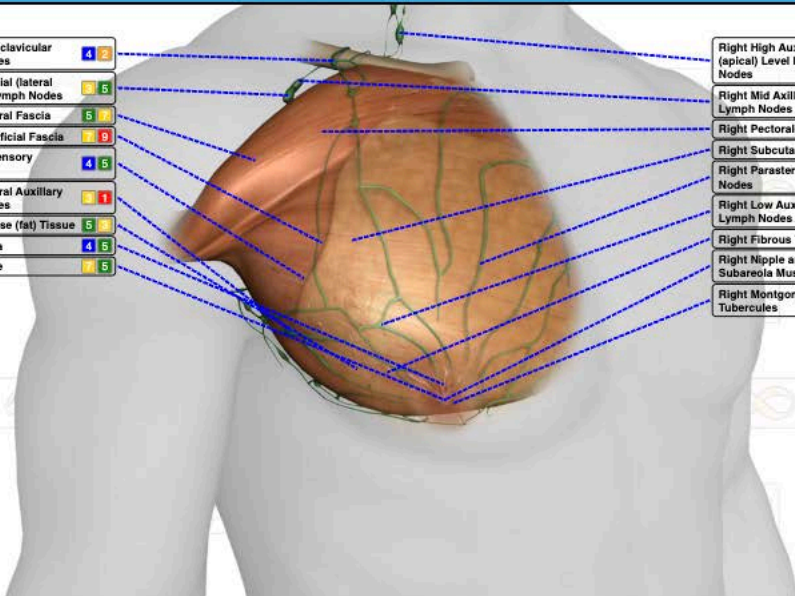
Left High Axillary (apical) Level III Lymph Nodes	7	5
Left Mid Axillary Level II Lymph Nodes	6	9
Left Pectoral Fascia	5	4
Left Subcutaneous Fat	6	4
Left Superficial Fascia	5	6
Left Suspensory Ligaments	7	5
Left Adipose (fat) Tissue	7	9
Left Areola	6	6
Left Nipple and Subareola Musculature	6	5

Left Supraclavicular Lymph Nodes	4	5
Left Brachial (lateral axillary) Lymph Nodes	9	8
Left Pectoralis Major	7	9
Left Parasternal Lymph Nodes	7	9
Left Low Axillary Level Lymph Nodes	5	5
Left Pectoral Axillary Lymph Nodes	4	2
Left Fibrous Tissue	6	6
Left Nipple	4	2
Left Montgomery's Tubercles	5	5



Right Supraclavicular Lymph Nodes	4	2
Right Brachial (lateral axillary) Lymph Nodes	9	5
Right Pectoral Fascia	6	6
Right Superficial Fascia	7	9
Right Suspensory Ligaments	4	5
Right Pectoral Axillary Lymph Nodes	9	1
Right Adipose (fat) Tissue	5	6
Right Areola	4	5
Right Nipple	7	5

Right High Axillary (apical) Level III Lymph Nodes	4	6
Right Mid Axillary Level II Lymph Nodes	7	9
Right Pectoralis Major	6	9
Right Subcutaneous Fat	6	8
Right Parasternal Lymph Nodes	5	5
Right Low Axillary Level Lymph Nodes	5	1
Right Fibrous Tissue	6	9
Right Nipple and Subareola Musculature	9	1
Right Montgomery's Tubercles	5	5

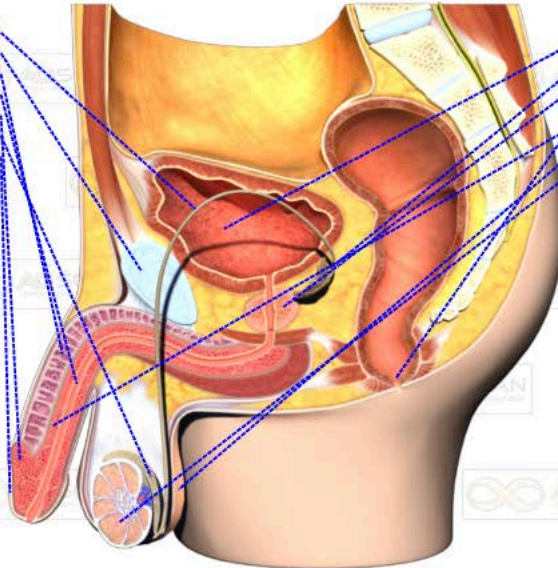




### Organs: Male Sagittal

% From Ideal: 32

Ductus Deferens	5	7
Symphysis Pubis	8	8
Corpora Caverosa	5	1
Urethra	4	2
Glans Penis	2	1
Epididymis	7	9
Prepuce	5	5



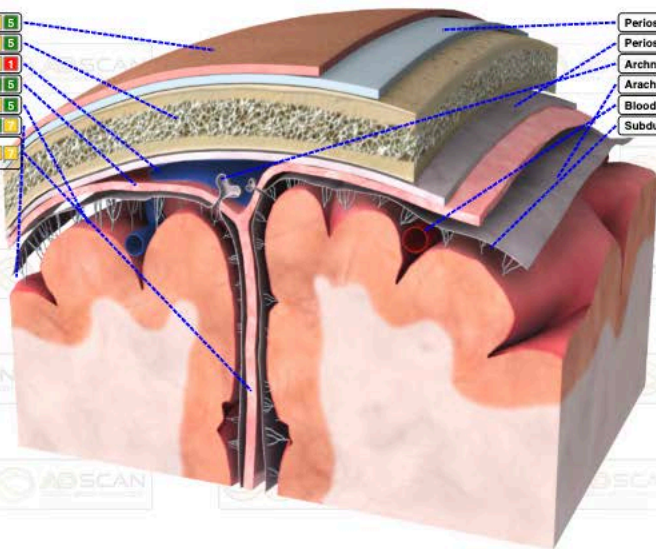
Urinary Bladder	7	8
Ampulla	8	5
Prostate Gland	7	8
Anus	4	2
Corpora Spongiosum	8	4
Scrotum	5	5
Testis	4	5



### Organs: Meninges Cross Section

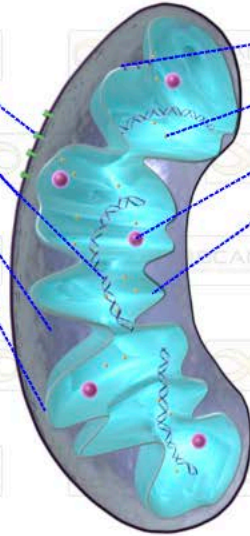
% From Ideal: 25

Skin of Scalp	7	5
Bone of Skull	7	5
Superior Sagittal Sinus	2	1
Meningeal	5	5
Pia Matter	7	5
Subarachnoid Space	5	7
Falx Cerebri (longitudinal tissue only)	7	7



Periosteum	8	5
Periosteal	5	5
Arachnoid Villus	5	5
Arachnoid Matter	5	5
Blood Vessel	5	5
Subdural Space	4	5

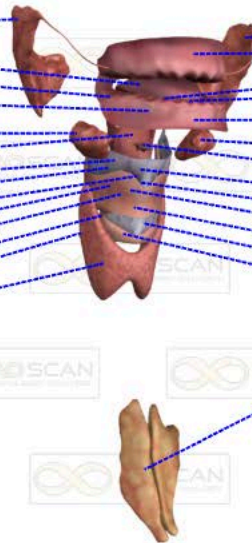
Porins	5	9
Outer Membrane	5	5
DNA	5	5
Inner Membrane Space	4	5
Inner Membrane	6	6



ATP Synthase	5	5
Ribosomes	4	9
Granules	4	5
Matrix	6	9



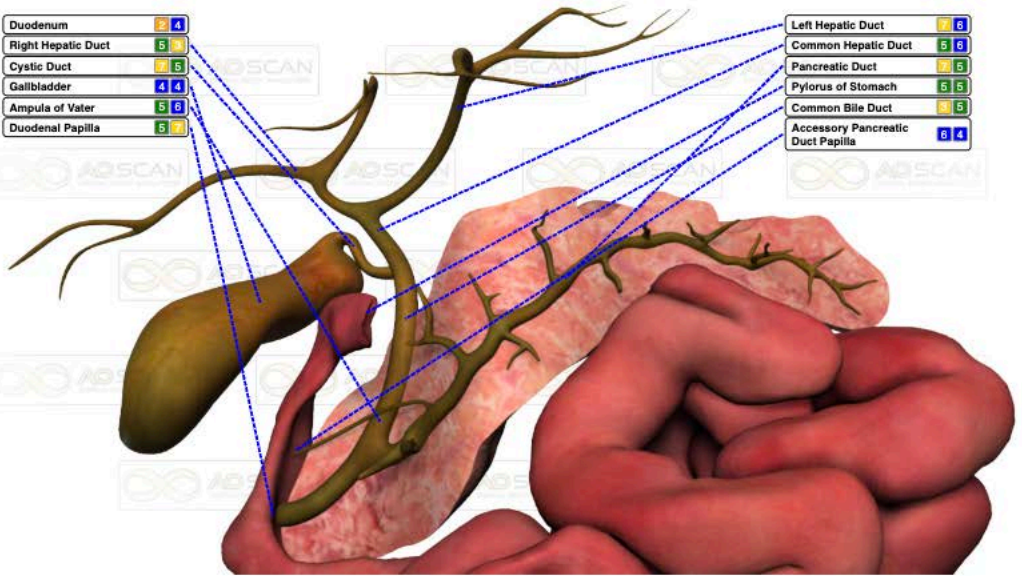
Right Parotid Salivary Gland	7	5
Uvula	4	9
Right Palatine Tonsil	9	9
Right Sublingual Salivary Gland	7	5
Right Submandibular Salivary Gland	5	4
Epiglottis	5	4
Thyroid Membrane	6	1
Left Corniculate	5	5
Thyroepiglottic Ligament	5	5
Right Arytenoid Cartilage	6	8
Larynx	5	5
Fan Ligament	7	9
Parathyroid Gland	5	1
Thyroid Gland	4	9



Left Parotid Salivary Gland	8	4
Mouth	7	5
Left Palatine Tonsil	8	8
Tongue	5	5
Left Sublingual Salivary Gland	5	5
Left Submandibular Salivary Gland	4	5
Hyoepiglottic Ligament	6	9
Right Corniculate	9	9
Left Arytenoid Cartilage	4	5
Vocal Ligament	8	5
Thyroid Cartilage	5	9
Cricothyroid Ligament	9	1
Cricoid Cartilage	5	9
Thymus	5	5

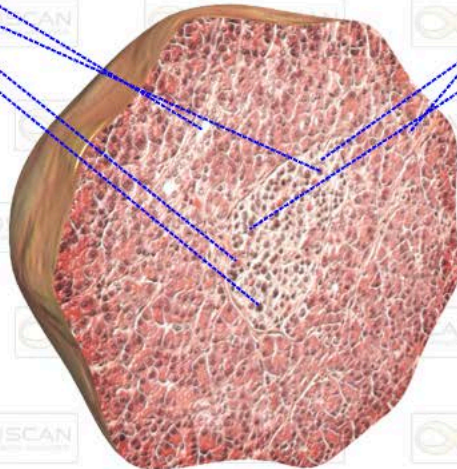
Duodenum	2	4
Right Hepatic Duct	5	9
Cystic Duct	7	5
Gallbladder	4	4
Ampulla of Vater	5	3
Duodenal Papilla	5	7

Left Hepatic Duct	7	3
Common Hepatic Duct	5	6
Pancreatic Duct	7	5
Pylorus of Stomach	5	5
Common Bile Duct	5	5
Accessory Pancreatic Duct Papilla	6	4



Pancreatic Duct	9	9
Glucagon -Producing a Cell	3	1
Blood Capillary	6	1
Insulin-Producing b Cell	6	1

Exocrine Acinar Cells	3	5
Pancreatic polypeptide -producing PP cell	7	9
Somatostatin -producing d Cell	4	6



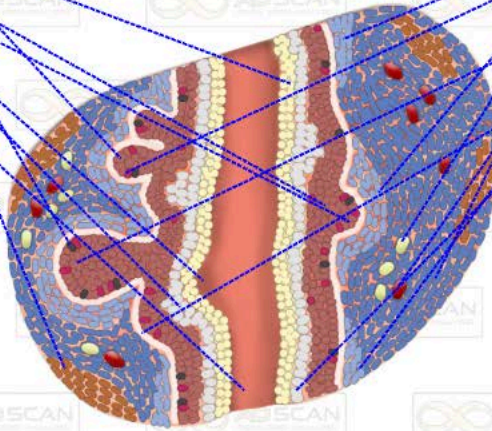


## Organs: Prostate Cross Section

% From Ideal: 30

Urothelial Cells	5	5
Dorsal Prostatic Buds	8	5
Basal Epithelial Cells	7	9
Ventral Prostatic Bud	4	4
Stem/Progenitor Cells	7	5
Sinus	4	2
Other Epithelial Cells	5	5
Smooth Muscle Cells	6	8
Urethra	5	5

Peri-Prostatic UGM Cells	6	4
Transit Amplifying Cells	9	8
Other UGM Cells	4	2
Nerves	5	7
Anterior Prostatic Buds	4	8
VMP Cells	5	7
Vasculature	6	5
Basement Membrane	7	5
UGM Cells	2	4
UGE Cells	5	5

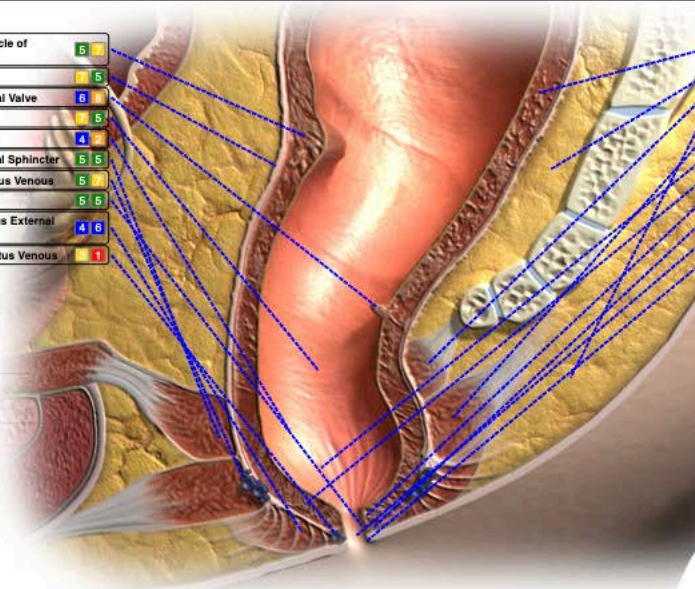


## Organs: Rectum Cross Section Male

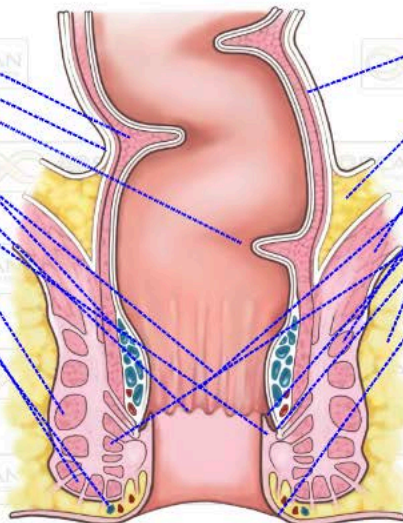
% From Ideal: 23

Circular Muscle of Rectum	5	7
Peritoneum	7	5
Inferior Rectal Valve	8	8
Anal Sinus	7	5
Anal Column	4	2
Deep External Sphincter	5	5
Internal Rectus Venous	5	7
Anal Valve	5	5
Subcutaneous External Sphincter	4	8
External Rectus Venous	8	1

Longitudinal Muscle of Rectum	8	8
Pelviorectal Space	5	5
Levator Ani Muscle	8	1
Ischioanal Fossa	5	7
Puborectalis Muscle	5	5
Pectinate Line	5	8
Internal Sphincter	5	5
Anal Crypt	5	5
Anal Gland	5	5
Anus	7	5
Anal Verge	7	5



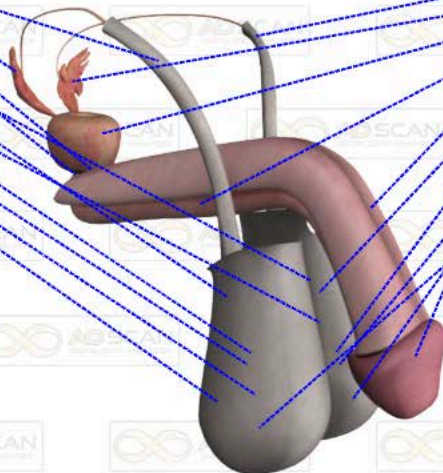
Circular Muscle of Rectum	5	1
Peritoneum	7	5
Inferior Rectal Valve	7	5
Internal Rectus Venous	6	3
Anal Sinus	5	5
Pectinate Line	5	5
Deep External Sphincter	5	5
Anal Valve	7	5
Subcutaneous External Sphincter	4	5
External Rectus Venous	5	5



Longitudinal Muscle of Rectum	5	5
Pelvirectal Space	5	5
Levator Ani Muscle	2	2
Ischiorectal Fossa	7	5
Puborectalis Muscle	7	3
Anal Column	6	4
Anal Crypt	6	1
Anal Gland	7	5
Internal Sphincter	7	5
Anal Verge	6	5



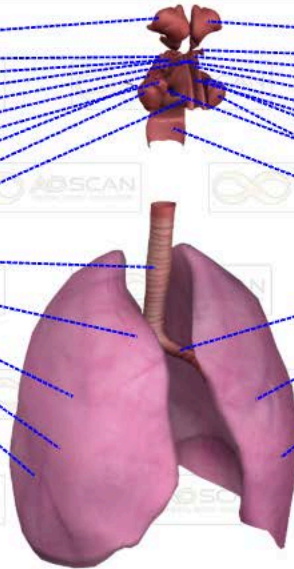
Left Vas Deferens	5	5
Right Seminal Vesicle	6	5
Left Bulbourethral Gland	4	2
Right Bulbourethral Gland	7	5
Left Cremasteric Muscle	4	2
Right Cremasteric Muscle	7	5
Left Epididymis	5	5
Right Epididymis	5	5
Right Tunica Albuginea	2	1
R Testis	6	3
Right Spermatic Fascia	5	5



Right Vas Deferens	4	5
Left Seminal Vesicle	6	5
Prostate	5	5
Corpus Spongiosum	6	3
Corpus Cavernosum	6	1
Left Superficial Fascia of Scrotum	5	5
Left Testis	6	2
Glans Penis	4	5
Left Tunica Albuginea	6	6
Left Spermatic Fascia	6	4
Right Superficial Fascia of Scrotum	6	6

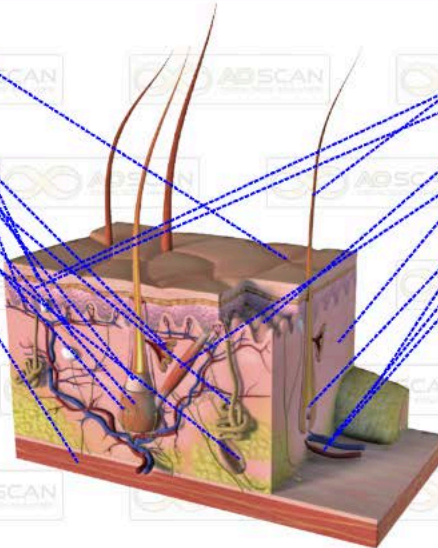
Right Frontal Sinus	9	1
Right Ethmoid Aircells 4	8	7
Right Ethmoid Aircells 1	8	2
Right Ethmoid Aircells 3	8	1
Left Ethmoid Aircells 4	8	4
Right Sphenoid Sinus	5	5
Right Eustachian Tube	8	1
Right Maxillary Sinus Duct	3	7
Right Maxillary Sinus	5	5
Nasopharynx	4	5
Trachea	4	5
Right Bronchus	5	4
Bronchial Tree	7	9
Right Lung	8	1
Right Plura	5	8

Left Frontal Sinus	5	3
Left Ethmoid Aircells 1	7	5
Left Ethmoid Aircells 2	5	5
Right Ethmoid Aircells 2	7	8
Left Ethmoid Aircells 3	7	9
Left Maxillary Sinus Duct	1	8
Left Eustachian Tube	8	5
Left Sphenoid Sinus	9	5
Adenoids	5	9
Left Maxillary Sinus	4	5
Pharynx	5	5
Left Bronchus	8	5
Left Lung	6	5
Left Plura	6	8



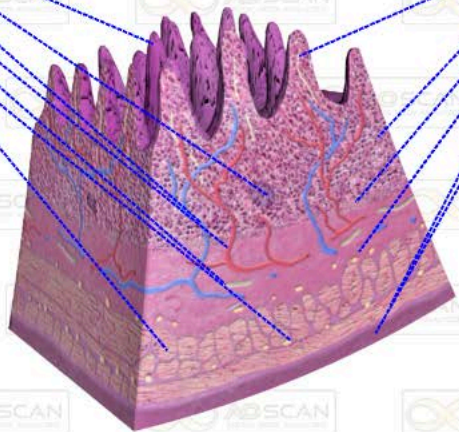
Sweat Gland Pore	5	4
Stratum Granulosum	7	5
Blood Capillary	8	6
Sensory Nerve Fiber	8	4
Sebaceous Oil Gland	2	1
Hair Root	7	5
Eccrine Sweat Gland	5	5
Hair Follicle	4	5
Hair Follicle Receptor	4	5
Pavlinian Corpuscle	5	8
Muscle	5	8

Hair Shaft	5	8
Stratum Corneum	7	5
Stratum Spinosum	5	5
Dermal Papilla	5	5
Dermis	8	5
Arrector Pili Muscle	7	9
Fat Tissue	4	5
Papillary of Hair	6	5
Vein	5	5
Artery	5	1





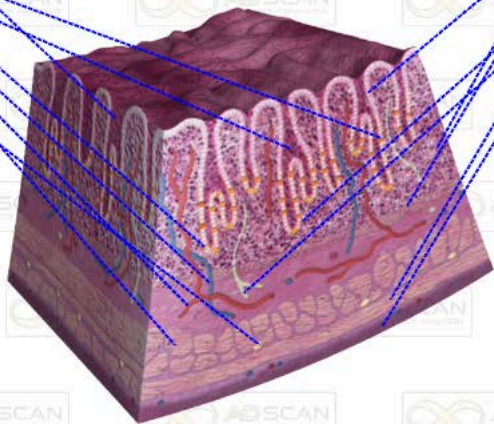
Villi	5	5
Lymphoid Nodule	5	5
Submucosal Vein	4	2
Submucosal Artery	7	9
Lymphatic Vessel	5	1
Myenteric Plexus	5	5
Circular Muscle	7	5



Lacteal	5	5
Mucosa	7	9
Muscularis Mucosae	2	3
Submucosal Plexus	5	5
Longitudinal Muscle	5	4
Serosa	4	5



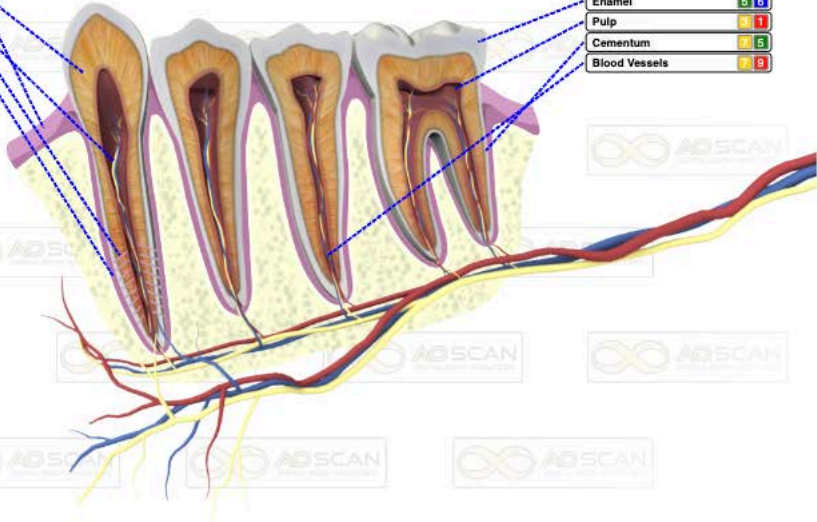
Gastric Pit	8	9
Parietal Cells	8	9
Gastric Gland	9	9
Enteroendocrine Cell	6	6
Submucosal Vein	4	6
Submucosal Artery	5	9
Circular Muscle	9	4
Myenteric Plexus	4	5



Mucous Cells	3	5
Lamina Propria	7	9
Muscularis Mucosae	4	5
Chief Cell	5	9
Lymphatic Vessel	7	5
Longitudinal Muscle	4	9
Serosa	5	9

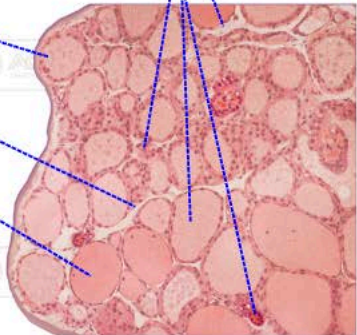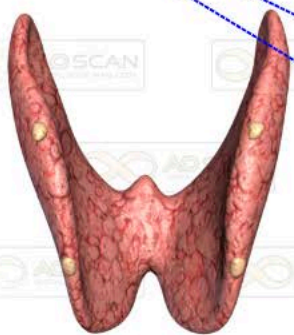- Dentin 5 2
- Gingiva 7 9
- Nerve 7 5
- Lateral Canals 5 5
- Periodontal Ligament 4 2

- Enamel 5 4
- Pulp 7 1
- Cementum 7 5
- Blood Vessels 7 9



- Follicular Cells 5 4
- Interfollicular Connective Tissue 7 5
- Colloid 6 4

- Connective Tissue 7 9
- Parafollicular Cells 7 5
- Thyroid Follicle 4 4
- Blood Vessels 6 4



Right Adrenal Gland	5	1
Right Kidney	5	5
Left Ureter Tube	6	4
Bladder	5	5

Left Adrenal Gland	4	5
Left Kidney	5	5
Right Ureter Tube	4	5
Urethra	5	5



Right Scapula	5	4
Right Clavicle	4	4
Right Humerus	5	5
Right Radius	5	5
Right Ulna	5	5

Left Scapula	5	5
Left Clavicle	5	1
Left Humerus	5	5
Left Radius	5	5
Left Ulna	5	5

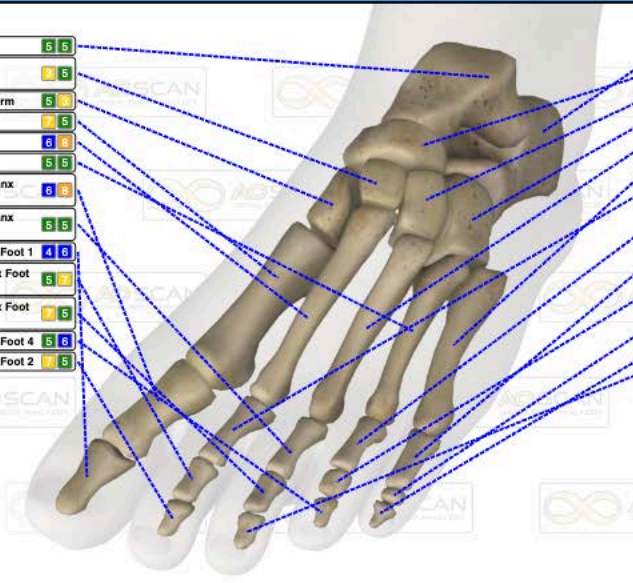


## Skeleton: Foot Left

% From Ideal: 15

Left Talus	5	5
Left Intermediate Cuneiform	9	5
Left Medial Cuneiform	5	9
Left Metatarsal 1	7	5
Left Metatarsal 2	8	9
Left Metatarsal 4	5	5
Left Proximal Phalanx Foot 1	6	9
Left Proximal Phalanx Foot 3	5	5
Left Distal Phalanx Foot 1	4	8
Left Middle Phalanx Foot 2	6	7
Left Middle Phalanx Foot 3	7	5
Left Distal Phalanx Foot 4	5	8
Left Distal Phalanx Foot 2	7	8

Left Calcaneus	5	8
Left Navicular	8	8
Left Lateral Cuneiform	8	7
Left Cuboid	5	5
Left Metatarsal 3	5	5
Left Metatarsal 5	6	7
Left Proximal Phalanx Foot 2	4	2
Left Proximal Phalanx Foot 4	5	5
Left Proximal Phalanx Foot 5	4	2
Left Middle Phalanx Foot 4	5	5
Left Middle Phalanx Foot 5	6	7
Left Distal Phalanx Foot 5	5	7
Left Distal Phalanx Foot 3	7	8

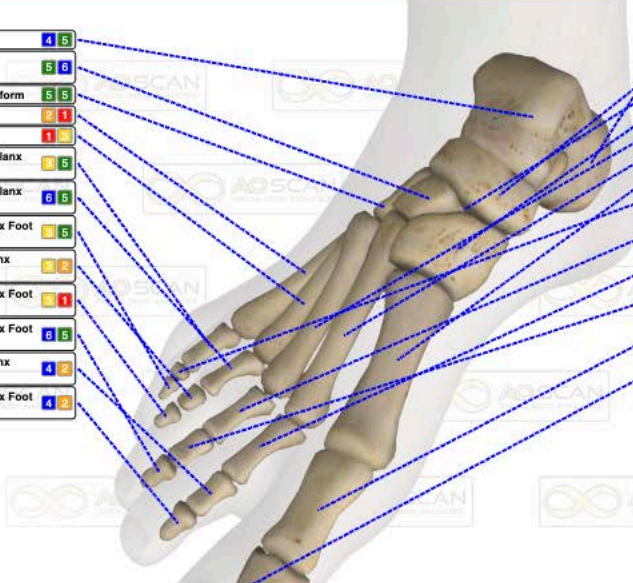


## Skeleton: Foot Right

% From Ideal: 38

Right Talus	4	5
Right Intermediate Cuneiform	5	6
Right Lateral Cuneiform	5	5
Right Metatarsal 5	2	1
Right Metatarsal 4	1	2
Right Proximal Phalanx Foot 5	5	5
Right Proximal Phalanx Foot 4	6	6
Right Distal Phalanx Foot 5	4	6
Right Middle Phalanx Foot 4	3	2
Right Distal Phalanx Foot 4	3	1
Right Distal Phalanx Foot 3	6	5
Right Middle Phalanx Foot 2	4	2
Right Distal Phalanx Foot 2	4	2

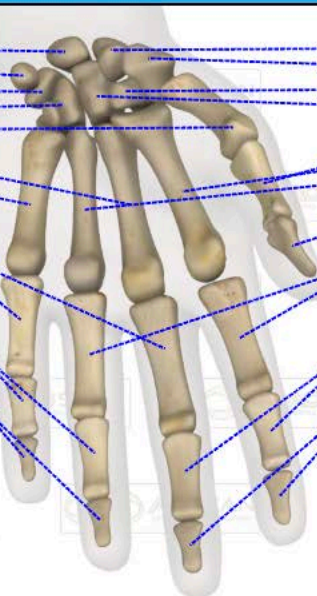
Right Calcaneus	8	5
Right Navicular	7	7
Right Cuboid	7	5
Right Medial Cuneiform	4	8
Right Metatarsal 3	4	5
Right Metatarsal 2	9	1
Right Metatarsal 1	5	7
Right Middle Phalanx Foot 5	6	3
Right Proximal Phalanx Foot 3	5	5
Right Proximal Phalanx Foot 2	4	5
Right Middle Phalanx Foot 3	7	6
Right Proximal Phalanx Foot 1	3	1
Right Distal Phalanx Foot 1	4	2





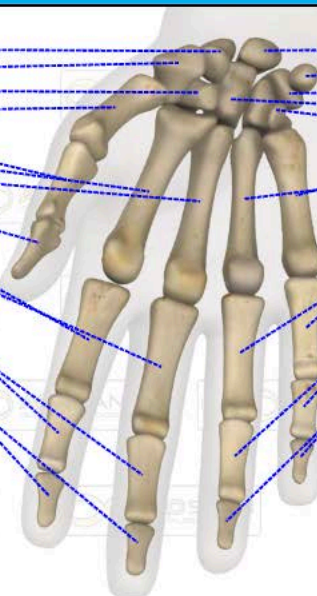Left Lunate	5	9
Left Pisiform	8	1
Left Triquetrum	8	8
Left Hamate	5	9
Left Metacarpal 1	4	5
Left Metacarpal 3	2	2
Left Metacarpal 5	8	5
Left Proximal Phalanx 5	4	5
Left Proximal Phalanx 3	7	9
Left Middle Phalanx 5	8	1
Left Middle Phalanx 4	8	1
Left Distal Phalanx 5	1	2
Left Distal Phalanx 4	5	9

Left Scaphoid	5	5
Left Trapezium	5	5
Left Trapezoid	7	9
Left Capitate	5	5
Left Proximal Phalanx 1	4	5
Left Metacarpal 2	2	4
Left Metacarpal 4	5	9
Left Distal Phalanx 1	9	9
Left Proximal Phalanx 2	5	9
Left Proximal Phalanx 4	1	2
Left Middle Phalanx 2	4	5
Left Middle Phalanx 3	4	5
Left Distal Phalanx 2	5	9
Left Distal Phalanx 3	8	5



Right Scaphoid	7	9
Right Trapezium	7	9
Right Trapezoid	5	1
Right Metacarpal 1	6	8
Right Proximal Phalanx 1	4	5
Right Metacarpal 2	5	7
Right Metacarpal 3	5	8
Right Distal Phalanx 1	5	8
Right Proximal Phalanx 5	5	5
Right Proximal Phalanx 3	6	8
Right Middle Phalanx 2	8	1
Right Middle Phalanx 3	7	5
Right Distal Phalanx 2	5	5
Right Distal Phalanx 3	6	5

Right Lunate	8	5
Right Pisiform	5	5
Right Triquetrum	5	5
Right Capitate	6	8
Right Hamate	5	1
Right Metacarpal 5	7	9
Right Metacarpal 4	6	5
Right Proximal Phalanx 5	7	5
Right Proximal Phalanx 4	6	6
Right Middle Phalanx 5	5	5
Right Middle Phalanx 4	7	9
Right Distal Phalanx 5	4	5
Right Distal Phalanx 4	1	1





## Skeleton: Legs

% From Ideal: 98

Right Femur	7	8
Right Patella	6	5
Right Tibia	6	1
Right Fibula	4	5

Left Femur	4	5
Left Patella	9	1
Left Tibia	4	5
Left Fibula	6	9

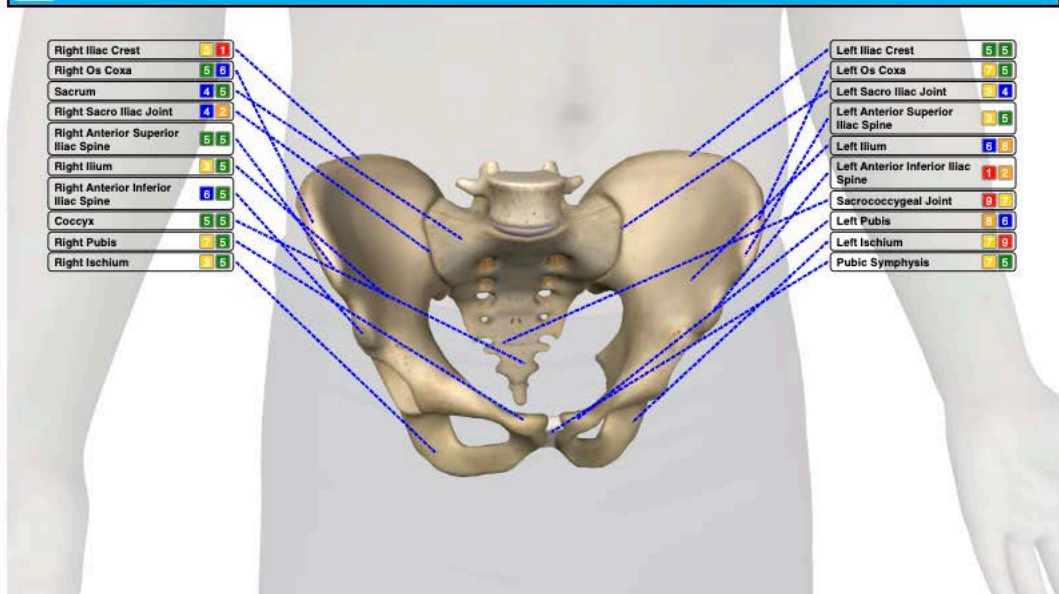


## Skeleton: Pelvis Sacrum

% From Ideal: 41

Right Iliac Crest	9	1
Right Os Coxa	5	8
Sacrum	4	5
Right Sacro Iliac Joint	4	9
Right Anterior Superior Iliac Spine	5	5
Right Ilium	8	5
Right Anterior Inferior Iliac Spine	6	5
Coccyx	5	5
Right Pubis	7	5
Right Ischium	8	5

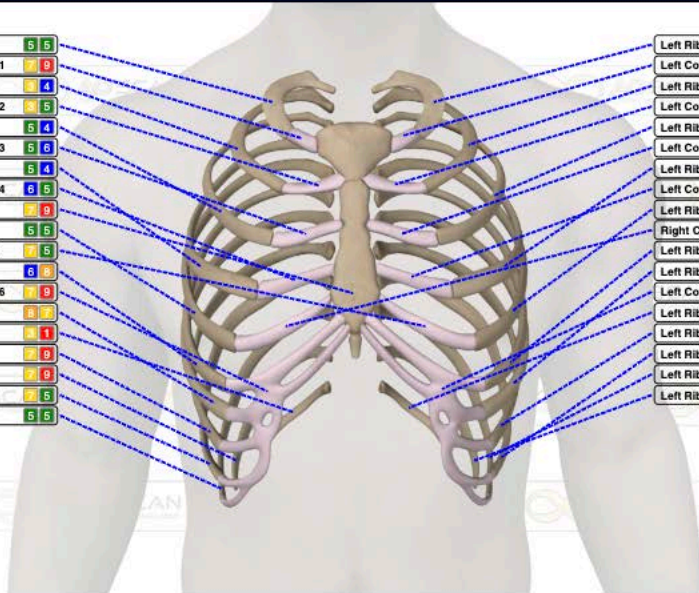
Left Iliac Crest	5	5
Left Os Coxa	7	5
Left Sacro Iliac Joint	9	4
Left Anterior Superior Iliac Spine	3	5
Left Ilium	6	9
Left Anterior Inferior Iliac Spine	1	2
Sacrococcygeal Joint	9	9
Left Pubis	8	5
Left Ischium	7	9
Pubic Symphysis	7	5





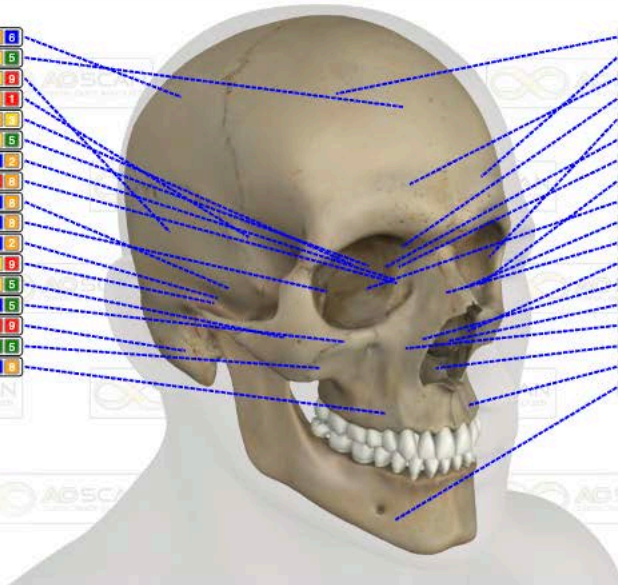
Right Rib 1	5	5
Right Costal Cartilage 1	7	9
Right Rib 2	5	4
Right Costal Cartilage 2	4	5
Right Rib 3	5	4
Right Costal Cartilage 3	5	6
Right Rib 4	5	4
Right Costal Cartilage 4	5	5
Right Sternum	7	9
Right Rib 5	5	5
Left Costal Cartilage 5	7	5
Right Rib 6	6	5
Right Costal Cartilage 6	7	9
Right Rib 7	6	5
Right Rib 12	6	1
Right Rib 8	7	9
Right Rib 11	7	9
Right Rib 9	7	5
Right Rib 10	5	5

Left Rib 1	7	5
Left Costal Cartilage 1	5	5
Left Rib 2	5	5
Left Costal Cartilage 2	5	5
Left Rib 3	5	6
Left Costal Cartilage 3	5	6
Left Rib 4	1	1
Left Costal Cartilage 4	7	5
Left Rib 5	5	7
Right Costal Cartilage 5	8	9
Left Rib 6	7	9
Left Rib 7	7	9
Left Costal Cartilage 6	6	5
Left Rib 12	6	1
Left Rib 8	5	4
Left Rib 9	5	6
Left Rib 10	5	5
Left Rib 11	5	5

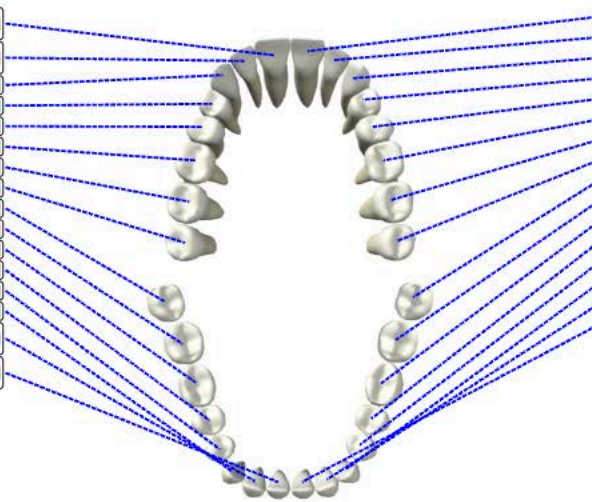


Right Parietal Bone	6	6
Frontal Bone	7	5
Occipital Bone	7	9
Sphenoid Bone	2	1
Ethmoid Bone	2	2
Right Ethmoidal Sinus	5	5
Left Malleus	4	2
Right Lacrimal Bone	9	6
Right Stapes	6	2
Right Sphenoid Sinus	6	9
Left Incus	4	2
Right Malleus	7	9
Right Zygomatic Bone	5	5
Right Maxillary Sinus	6	5
Right Temporal Bone	9	9
Right Palatine Bone	5	5
Right Maxillary Bone	6	6

Left Parietal Bone	9	1
Left Frontal Sinus	4	1
Right Frontal Sinus	5	5
Left Ethmoid Sinus	6	4
Left Zygomatic Bone	7	9
Left Stapes	7	5
Left Incus	5	3
Left Temporal Bone	5	5
Left Sphenoid Sinus	5	1
Right Nasal Bone	4	2
Left Lacrimal Bone	9	6
Left Maxillary Sinus	7	9
Left Nasal Concha	5	5
Left Nasal Bone	5	3
Right Nasal Concha	4	2
Vomer Bone	5	5
Left Maxillary Bone	7	5
Mandible	6	9

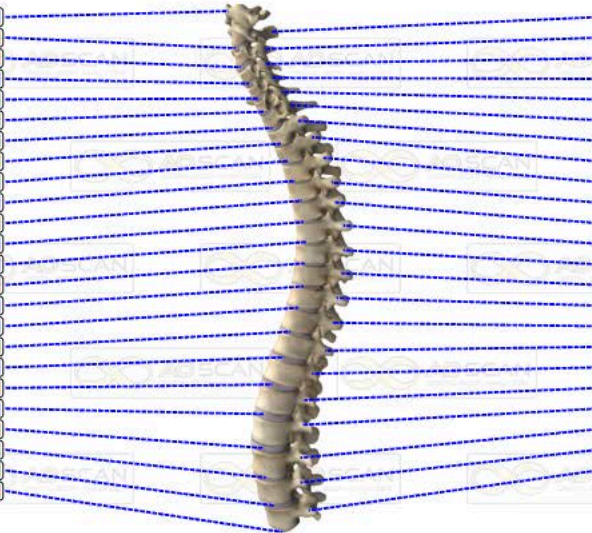


Upper Right Central Incisor	5	5
Upper Right Lateral Incisor	5	4
Upper Right Cuspid	5	5
Upper Right 1st Bicuspid	5	5
Upper Right 2nd Bicuspid	7	5
Upper Right 1st Molar	4	5
Upper Right 2nd Molar	6	7
Upper Right 3rd Molar	5	6
Lower Right 3rd Molar	2	1
Lower Right 2nd Molar	5	4
Lower Right 1st Molar	5	4
Lower Right 2nd Bicuspid	6	4
Lower Right 1st Bicuspid	6	5
Lower Right Cuspid	5	5
Lower Right Lateral Incisor	4	6
Lower Right Central Incisor	7	5



Upper Left Central Incisor	5	5
Upper Left Lateral Incisor	5	5
Upper Left Cuspid	5	5
Upper Left 1st Bicuspid	5	6
Upper Left 2nd Bicuspid	7	8
Upper Left 1st Molar	5	5
Upper Left 2nd Molar	5	7
Upper Left 3rd Molar	5	5
Lower Left 3rd Molar	5	5
Lower Left 2nd Molar	3	5
Lower Left 1st Molar	7	6
Lower Left 2nd Bicuspid	5	5
Lower Left 1st Bicuspid	4	2
Lower Left Cuspid	6	5
Lower Left Lateral Incisor	3	1
Lower Left Central Incisor	8	1

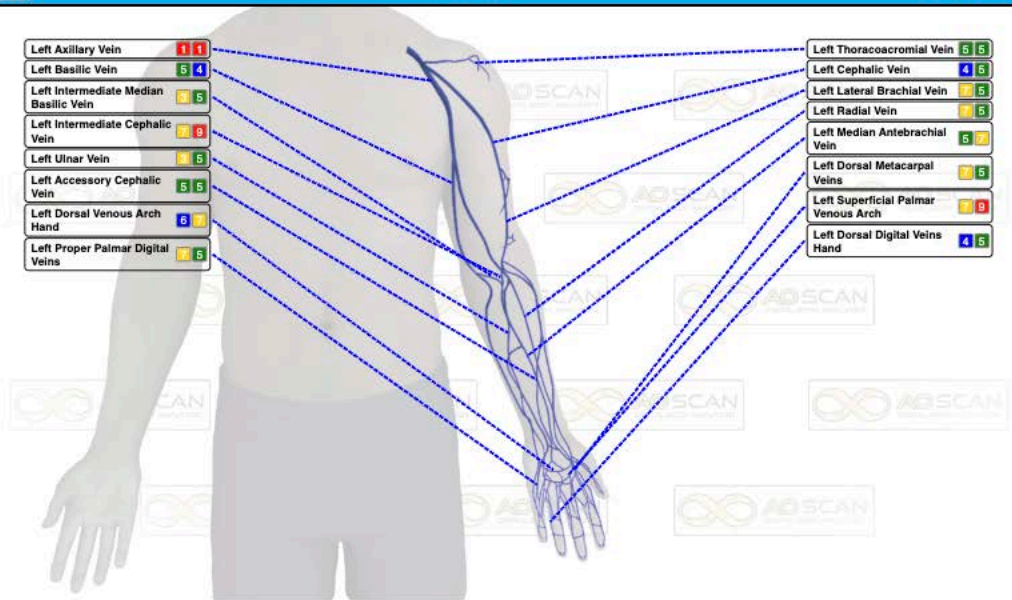
Atlas Vertebra C1	5	6
Cervical Disc C2	6	8
Cervical Disc C3	9	9
Cervical Disc C4	5	4
Cervical Disc C5	4	5
Cervical Disc C6	5	5
Cervical Disc C7	5	5
Thoracic Disc T1	5	3
Thoracic Disc T2	7	5
Thoracic Disc T3	5	6
Thoracic Disc T4	9	7
Thoracic Disc T5	7	6
Thoracic Disc T6	8	8
Thoracic Disc T7	4	4
Thoracic Disc T8	5	4
Thoracic Disc T9	5	6
Thoracic Disc T10	5	5
Thoracic Disc T11	5	5
Thoracic Disc T12	6	8
Lumbar Disc L1	5	8
Lumbar Disc L2	5	5
Lumbar Disc L3	7	5
Lumbar Disc L4	5	5
Lumbar Disc L5	7	9



Axis Vertebra C2	5	5
Cervical Vertebra C3	8	5
Cervical Vertebra C4	5	8
Cervical Vertebra C5	6	4
Cervical Vertebra C6	4	2
Cervical Vertebra C7	5	5
Thoracic Vertebra T1	5	5
Thoracic Vertebra T2	4	5
Thoracic Vertebra T3	7	8
Thoracic Vertebra T4	8	9
Thoracic Vertebra T5	9	4
Thoracic Vertebra T6	5	3
Thoracic Vertebra T7	8	5
Thoracic Vertebra T8	2	1
Thoracic Vertebra T9	5	5
Thoracic Vertebra T10	7	8
Thoracic Vertebra T11	6	4
Thoracic Vertebra T12	8	9
Lumbar Vertebra L1	6	5
Lumbar Vertebra L2	7	5
Lumbar Vertebra L3	5	7
Lumbar Vertebra L4	2	4
Lumbar Vertebra L5	5	3

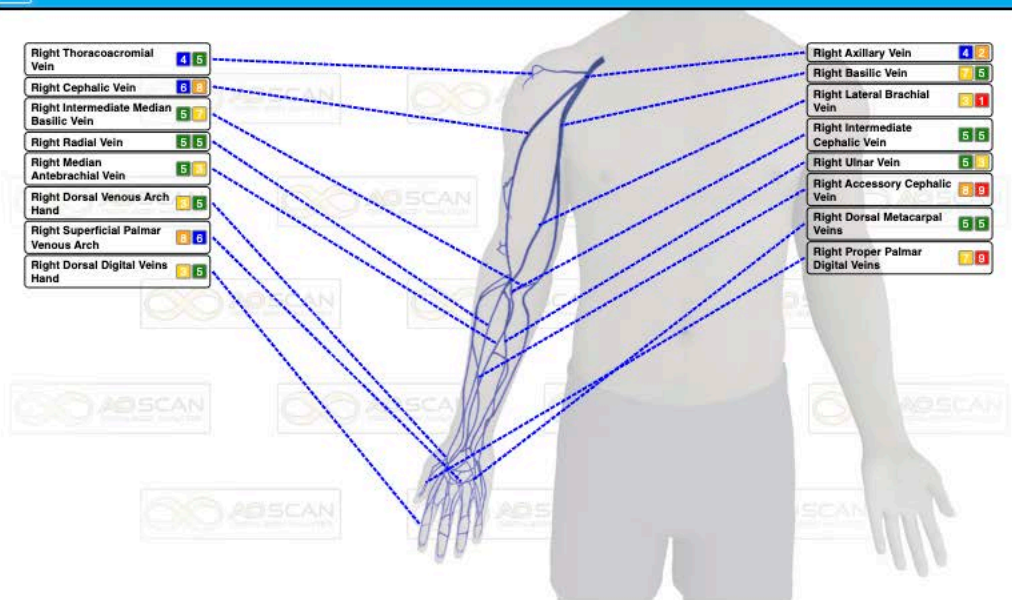
Left Axillary Vein	1	1
Left Basilic Vein	5	4
Left Intermediate Median Basilic Vein	2	5
Left Intermediate Cephalic Vein	7	9
Left Ulnar Vein	4	5
Left Accessory Cephalic Vein	5	5
Left Dorsal Venous Arch Hand	6	7
Left Proper Palmar Digital Veins	7	5

Left Thoracoacromial Vein	5	5
Left Cephalic Vein	4	5
Left Lateral Brachial Vein	7	5
Left Radial Vein	7	5
Left Median Antebrachial Vein	5	7
Left Dorsal Metacarpal Veins	7	5
Left Superficial Palmar Venous Arch	7	9
Left Dorsal Digital Veins Hand	4	5



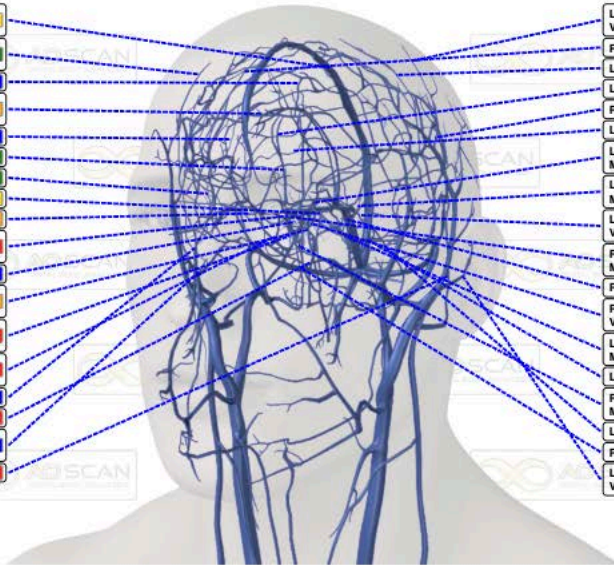
Right Thoracoacromial Vein	4	5
Right Cephalic Vein	6	8
Right Intermediate Median Basilic Vein	5	7
Right Radial Vein	5	5
Right Median Antebrachial Vein	5	3
Right Dorsal Venous Arch Hand	7	5
Right Superficial Palmar Venous Arch	4	6
Right Dorsal Digital Veins Hand	4	5

Right Axillary Vein	4	2
Right Basilic Vein	7	5
Right Lateral Brachial Vein	3	1
Right Intermediate Cephalic Vein	5	5
Right Ulnar Vein	5	3
Right Accessory Cephalic Vein	3	9
Right Dorsal Metacarpal Veins	5	5
Right Proper Palmar Digital Veins	7	8



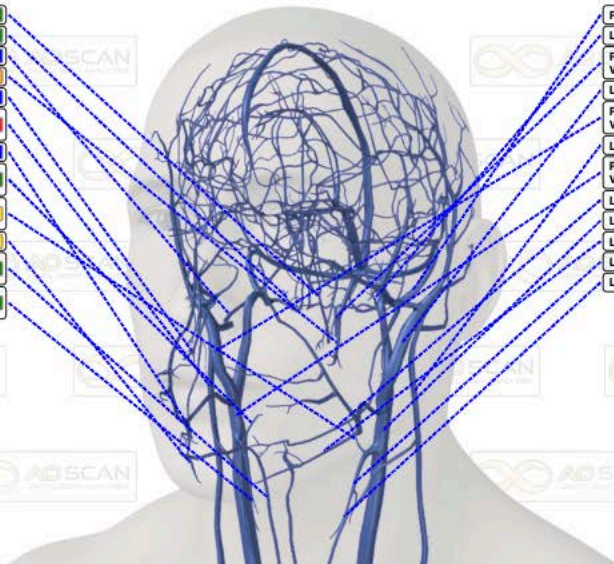
Right Superior Sagittal Sinus	5	1
Right Superior Temporal Vein	5	5
Right Cerebral Veins	5	4
Right Inferior Sagittal Sinus	6	2
Left Angular Vein	4	4
Right Basal Vein	7	5
Right Eye Veins	5	5
Right Cavernous Sinus	5	3
Right Ophthalmic Vein	4	2
Right Intercavernous Sinus	7	9
Left Eye Veins	5	4
Right Superior Petrosal Sinus	4	2
Right Lateral Mesencephalic Vein	7	9
Right Lateral Brachial Vein	7	9
Right Deep Temporal Vein	5	5
Right Vermian Vein	7	9
Right Posterior Auricular Vein	5	5
Left Occipital Vein	7	9

Left Superior Temporal Vein	5	1
Right Meningeal Vein	4	2
Left Meningeal Vein	4	2
Left Basal Vein	6	5
Right Angular Vein	4	2
Left Ophthalmic Vein	7	9
Left Anterior Ponto Mesencephalic	5	4
Left Posterior Mesencephalic Vein	5	5
Left Superior Cerebellar Vein	7	5
Right Posterior Mesencephalic Vein	5	5
Right Straight Sinus	5	5
Right Superior Cerebellar Vein	1	9
Left Lateral Mesencephalic Vein	5	5
Left Lateral Brachial Vein	5	9
Right Anterior Ponto Mesencephalic	4	6
Left Vermian Vein	7	9
Right Transverse Sinus	7	5
Left Posterior Auricular Vein	7	5



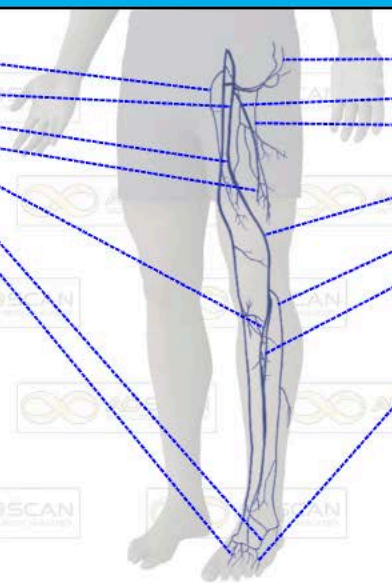
Right Anterior Spinal Vein	5	5
Right Retrotonsillar Vein	5	5
Right Occipital Vein	5	6
Left Maxillary Vein	7	9
Right Maxillary Vein	6	4
Right External Jugular Vein	7	9
Right Alveolar Vein	2	4
Right Superior Laryngeal Vein	5	5
Left Superior Laryngeal Vein	6	7
Right Facial Vein	5	9
Right Anterior Jugular Vein	7	5
Right Superior Thyroid Vein	7	5

Right Sigmoid Sinus	6	5
Left Retrotonsillar Vein	7	9
Right Posterior Spinal Vein	7	5
Left Retromandibular Vein	7	9
Right Retromandibular Vein	8	9
Left External Jugular Vein	7	5
Right Internal Jugular Vein	5	5
Left Alveolar Vein	7	5
Left Internal Jugular Vein	4	5
Left Facial Vein	5	5
Left Superior Thyroid Vein	7	9
Left Anterior Jugular Vein	8	9



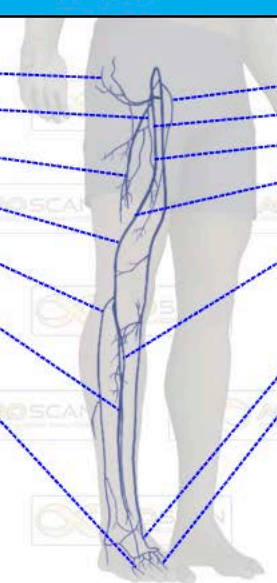
Left Medial Accessory Saphenous Vein	5	1
Left Great Saphenous Vein	4	5
Left Femoral Vein	7	5
Left Deep Femoral Vein	9	1
Left Posterior Tibial Vein	7	9
Left Dorsal Venous Foot Arch	1	1
Left Dorsal Digital Veins	7	5

Left Medial Circumflex Femoral Vein	4	6
Left Lat. Accessory Saphenous Vein	7	9
Left Lat. Circumflex Femoral Vein	5	5
Left Popliteal Vein	9	5
Left Lesser Saphenous Vein	5	9
Left Anterior Tibial Vein	9	1
Left Lateral Dorsal Digital Vein	9	9



Right Medial Circumflex Femoral Vein	4	2
Right Lat. Accessory Saphenous Vein	4	6
Right Lat Circumflex Femoral Vein	8	9
Right Popliteal Vein	5	5
Right Lesser Saphenous Vein	6	9
Right Anterior Tibial Vein	5	5
Right Lateral Dorsal Digital Vein	6	4

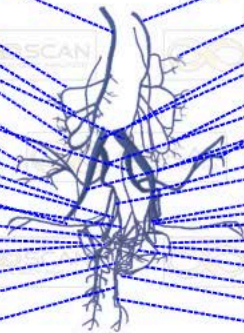
Right Medial Accessory Saphenous Vein	6	4
Right Great Saphenous Vein	8	8
Right Femoral Vein	8	8
Right Deep Femoral Vein	7	9
Right Posterior Tibial Vein	5	5
Right Dorsal Venous Foot Arch	6	8
Right Dorsal Digital Veins	6	1





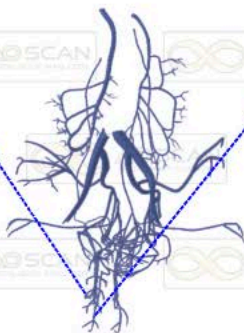
Right Superior Mesenteric Vein	6	8
Right Colic Vein	5	7
Right ileocolic Vein	6	8
Right Anterior Cecal Vein	6	8
Left Common Iliac Vein	5	5
Right Posterior Cecal Vein	4	5
Right Superior Gluteal Vein	7	5
Left Internal Iliac Vein	9	1
Right Appendicular Vein	5	7
Right Testicular Vein	7	5
Right Umbilical Vein	4	8
Right Inferior Gluteal Vein	5	7
Right Middle Rectal Vein	5	7
Right Prostatic Vesical Venous Plexus	2	1
Right Obturator Vein	7	5
Right Internal Pudendal Vein	4	2
Right Pampiniform Venous Plexus	7	5
Right Perimuscular Rectal Plexus	7	5
Left Pampiniform Venous Plexus	4	4

Right Inferior Mesenteric Vein	7	5
Left Colic Vein	5	5
Right Superior Rectal Vein	8	2
Right Common Iliac Vein	8	5
Right Sigmoid Veins	7	5
Left Superior Gluteal Vein	5	4
Right Internal Iliac Vein	5	4
Left Testicular Vein	7	5
Right External Iliac Vein	5	5
Left External Iliac Vein	7	5
Right Ductus Deferens Vein	2	5
Left Umbilical Vein	9	9
Left Ductus Deferens Vein	9	1
Left Inferior Gluteal Vein	4	2
Left Obturator Vein	5	5
Left Internal Pudendal Vein	4	8
Left Middle Rectal Vein	4	2
Right Gastroepiploic Vein	7	5
Right Inferior Rectal Vein	5	5
Left Perineal Vein	8	8



Right Deep Dorsal Vein of Penis	8	8
---------------------------------	---	---

Right Perineal Vein	8	8
---------------------	---	---





Right Inferior Thyroid Vein	7	9
Right Subclavian Vein	3	1
Right Brachiocephalic Vein	7	5
Right Intercostal Veins	9	5
Right Azygos Vein	6	8
Right Hepatic Portal Vein	5	5
Right Vena Cava	2	1
Right Great Pancreatic Vein	5	5
Right Ant. Sup. Pancreaticoduodenal	5	7
Right Ant. Inf. Pancreaticoduodenal	4	4
Right Middle Colic Vein	2	1

Left Inferior Thyroid Vein	5	5
Left Subclavian Vein	9	5
Left Brachiocephalic Vein	3	1
Left Intercostal Veins	5	5
Right Hemiazygos Vein	7	5
Right Hepatic Veins	8	6
Right Gastric Vein	7	9
Right Splenic Vein	5	7
Left Renal Vein	3	1
Right Gastroepiploic Vein	9	8
Right Renal Vein	4	2

