


Lung Sonography

Giovanni Volpicelli, MD, FCCP

 Article includes CME test

 Videos online at www.jultrasoundmed.org

Lung sonography represents an emerging and useful technique in the management of some pulmonary diseases. For many years, sonography of the thorax was limited to the study of pleural effusion and thoracic superficial masses because alveolar air and bones of the thoracic cage limit the propagation of the ultrasound beam. Only recently has it been highlighted that lung sonography is highly sensitive to variations of the pulmonary content and balance between air and fluids, like a real lung densitometer. Dynamic and static analysis of a combination of sonographic artifacts and real images makes accurate diagnosis of many lung disorders possible, particularly when lung sonography is applied in the emergency and critical care settings. Sonography is useful in the diagnosis of lung diseases in which the alveolar air content is impaired and interstitial and alveolar fluids are increased and also when air or fluids are collected in the pleural space. This article analyzes the basic principles of lung ultrasonography and all of the supposed limitations to its diagnostic usefulness. Moreover, the article reviews the three main fields of lung sonography application: interstitial, alveolar, and pleural syndromes.

Key Words—chest sonography; critical sonography; emergency sonography; lung sonography

Sonography is an effective technique that uses ultrasound waves to create images of the body for diagnostic purposes and for guiding invasive procedures. Medical use of sonography was developed during the second half of the past century, and nowadays it is widespread. It is based on a transducer emitting a brief pulse of high-frequency sound penetrating the tissues. In the human body, the ultrasound beam propagates at different velocities, depending on the attenuation effect due to the acoustic impedance of the structures and tissues passed through. The beam is partly reflected back to the transducer at tissue boundaries and interfaces. The angle of incidence also influences the penetration or reflection of the ultrasound beam. As a result of these phenomena, there are different intensities of reflections that are transformed into pixels on the screen to create images corresponding to the organs and tissues crossed by the beam. However, attenuation values for normal tissues show considerable variation. The attenuating effect of air and bones is much greater than that of other tissues. For this reason, air and bones represent limitations to the usefulness of sonography. On the contrary, fluids have low attenuation values and are easily crossed by the ultrasound beam. Interfaces of common tissues and fluids with bones and particularly with air cause complete reflection of the ultrasound beam and prevent a faithful reconstruction of the

Received March 16, 2012, from the Department of Emergency Medicine, San Luigi Gonzaga University Hospital, Torino, Italy. Revision requested April 4, 2012. Revised manuscript accepted for publication June 20, 2012.

Address correspondence to Giovanni Volpicelli, MD, FCCP, Department of Emergency Medicine, San Luigi Gonzaga University Hospital, 10043 Orbassano, Torino, Italy.

E-mail: gio.volpicelli@tin.it

morphologic characteristics of the organ, and artifacts are created. Traditionally, optimal applications of medical sonography are the study of segments and organs of the human body devoid of air and bones, such as parenchymatous abdominal organs and the heart.

For many years, these considerations prevented the use of sonography for the study of lung diseases. The lungs are wide organs filled with air and surrounded by the bones of the thoracic cage. As a consequence, thoracic sonography was originally limited to the study of superficial pleural conditions, such as tumors and effusions, and to guide invasive procedures.¹ However, two considerations contributed to change this conventional wisdom in the last decade.

The first is that “point-of-care sonography” has gained broader acceptance as a clinical tool in the hands of the clinician,² which has led to several new applications at the bedside based on the interpretation of sonographic studies in real time. These applications are no longer exclusively targeted to an optimal reconstruction of the morphologic characteristics of organs and tissues. The resolution of the real-time dynamic images used by the clinician may be poor, but the images are strictly correlated to the patient’s symptoms and signs. In this author’s opinion, when clinicians perform and interpret their own sonographic examinations, they are better able to correlate findings with the clinical presentation, whereas such a correlation is harder for conventional consultative sonography. Thus, the diagnostic process may gain in both safety and accuracy.

The second consideration relates to the central role of the lung in the clinical evaluation of most diseases. Of course, we cannot imagine a general examination of any patient without careful auscultation of the lung, which has a fundamental impact on the overall assessment of not only the respiratory but also the hemodynamic status. For this reason, the intensivist who began to handle the point-of-care sonography especially felt a particular need to look also into the lung. This consideration stimulated some scientists to analyze and interpret the artifacts created by lung insonation, thus reconsidering those that had always been considered definitive limitations of lung sonography.

Limitations of Lung Sonography

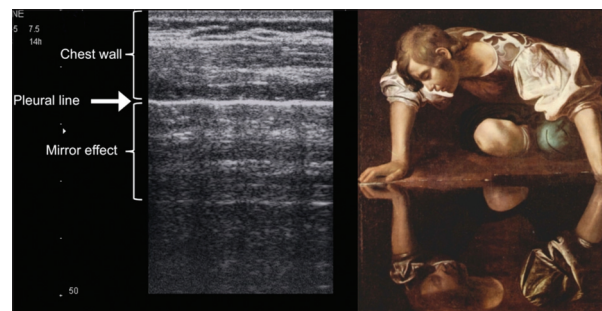
Alveolar Air

All of the limitations of the technique become obvious when observing a sonogram of a normal lung. The chest wall, with all of the layers lying between the probe and the lung, is accurately imaged, whereas the region under the pleural line appears simply as a uniform background pattern finely sparkling with some linear echogenic horizontal lines (Fig-

ure 1, left panel, and Video 1). The large difference in acoustic impedances of soft tissues and air-filled alveoli prevents the reconstruction of a real image of the organ while generating multiple artifacts. Looking more closely at the image, we see that the region of artifacts is nothing but a reflection of the chest wall below the pleural line. Therefore, the pleura acts as the mirror of the lung, thus hindering the organ. We could compare this phenomenon to a wonderful Italian painting by Caravaggio from the late 15th century, depicting the myth of Narcissus (Figure 1, right panel). Unlike Narcissus, we need to see under the water surface.

Observing another lung scan (Figure 2 and Video 2), we can deduce that the pleura does not always work like a mirror. Under some conditions, sonography allows a faithful and detailed reconstruction of the image of the lung. What is the difference between the two lungs? It is simply a different balance between the air and the fluid content of the lung. Figure 1 shows a lung with normal aeration, which generates the mirror effect, whereas Figure 2 shows consolidation of the lung characterized by highly reduced air due to a massive increase in fluids and cellularity. The mirror effect disappears when the air content of the lung drops and the fluids increase. When acoustic impedances of soft tissues and the alveolar content are close to one other, which happens in the case of fluid-filled alveoli, sound can easily propagate and generate a real image. This phenomenon occurs in most lung diseases, all of which are conditions that can be studied by sonography. On the contrary, sonography cannot be used to study emphysema or alveolar overdistension due to excessive mechanical ventilation, because in these conditions, the air content of the lung is increased, and the mirror effect is not distinguishable from that obtained in a case of normal aeration.

Figure 1. Sonogram of a normally aerated lung. Left panel, The pleural line divides the image into two parts: the top part is the real reconstruction of the chest wall, and the bottom part is the reflection of the chest wall (artifact image; Video 1). Right panel, The sonographic mirror effect can be compared to the reflection on the water surface painted by Caravaggio in *Narciso* in 1499.



The condition imaged in Figure 3, left panel (Video 3), is halfway between the normal aerated lung and the consolidated lung. The alveolar air is slightly decreased, and fluids are slightly increased but not enough to generate a consolidation. There is still enough air in the lung to prevent the reproduction of a real image but not so much to create the mirror effect. The underlying condition is interstitial syndrome. The increase in the fluid contents causes thickening of the interlobular septa and the lung interstitium. Given the spatial resolution power of sonography, the subpleural end of the septa are too small for visualization as real structures.³ However, their thickening and the subsequent change in the balance between air and fluids create some reverberation vertical artifacts named B-lines.^{3,4} These artifacts cause the mirror effect to vanish and can be imagined as the rippling effect obtained by the launch of a stone on a still water surface, which makes the image of Narcissus disappear (Figure 3, right panel).

Therefore, although air limits the reconstruction of a real image of the normal lung, the alteration in the balance between air and fluids of the diseased lung substantially modifies the normal sonographic pattern. This alteration can happen both in a case of deflation of the lung with maintenance of a constant weight and also when the weight of the lung increases because of an increase in fluids, cells, connective tissue, or blood content. In other words, whether the cause is simple deflation or an increase in fluids and the cellularity of the lung, sonography is highly sensitive to variations in organ density, as deduced by studies on

phantoms, animal models, and humans.^{5–8} The diagnostic potential of lung sonography is even increased by the fact that it is a dynamic technique, which allows for the analysis of lung movement in real time. The three conditions shown in Figures 1–3 are the basis for the interpretation of the modern lung sonography. All three scans are highly diagnostic of different degrees of lung density and aeration. The pattern imaged in Figure 1 and Video 1, ie, the mirror effect that slides or pulses with respiration and cardiac activity, allows exclusion of conditions characterized by loss of alveolar air such as consolidations and interstitial syndromes, with negative predictive values ranging from 95% to 100% in some studies.^{9–12} This pattern also rules out the presence of air and fluids in the interpleural space, with a negative predictive value of 100% for pneumothorax and sensitivity of 92% for effusion.^{13–17} The other two scans, the interstitial and the consolidated (or alveolar) patterns, respectively allow diagnosis of interstitial diseases, such as edema and fibrosis, with positive predictive values ranging from 87% to 95%,^{9,10} and consolidations due to pneumonia, infarctions, contusions, and atelectasis, with positive predictive values ranging from 83% to 100% in different studies.^{9,18–21}

Bones of the Thoracic Cage

Bones cannot be crossed by the ultrasound beam. When we put the probe on a rib, we reproduce on the screen a shadow that obscures the image below it. As a consequence, the lung surface is only partially visible on sonography. However, it has been estimated that more than 70% of the pleural surface is still visible on sonography.^{22,23} Moreover,

Figure 2. Sonogram of a consolidated lung in a case of pneumonia. The reconstruction of the tissuelike image of the consolidation under the pleura is made possible by the loss of air. Some tree-shaped bronchograms due to air trapped in the bronchi are clearly visible in the echo texture of the consolidation (Video 2). Reproduced with permission from Gebhard Mathis, MD (Praxis, Rankwell, Austria).

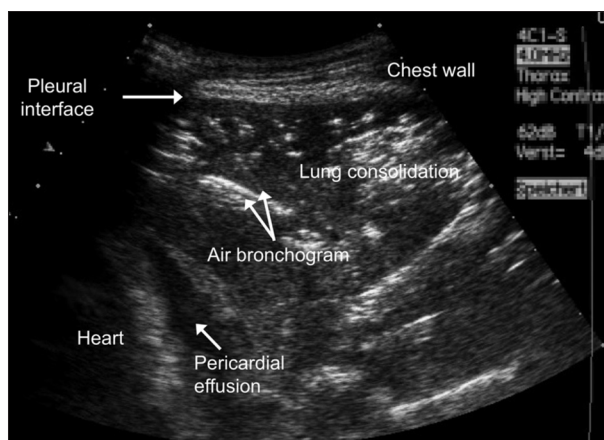
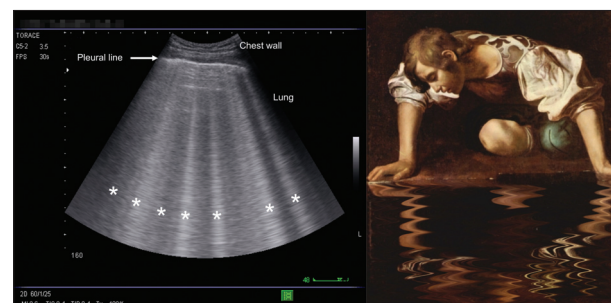


Figure 3. Sonogram in a case of cardiogenic pulmonary edema. Left panel, Multiple vertical echogenic artifacts (asterisks), named B-lines, prevent the mirror effect. This pattern is diagnostic of interstitial syndrome and is due to reverberation of the ultrasound beam between the alveolar air and the interstitial fluids (Video 3). Right panel, the phenomenon may be imagined as the rippled water surface that reduces gradually until it makes the mirror effect disappear and hides the reflection of the image of Narcissus.



the intercostal view of the lung can be extended when the probe is turned along the space to obtain an oblique scan. This view allows maximum extension of the visible pleura and lung. Indeed, a limited view of the lung surface is large enough for diagnosing diffuse diseases, particularly in the emergency and critical care settings, even if some conditions may have patchy geographic variations in severity.

Surface Imaging

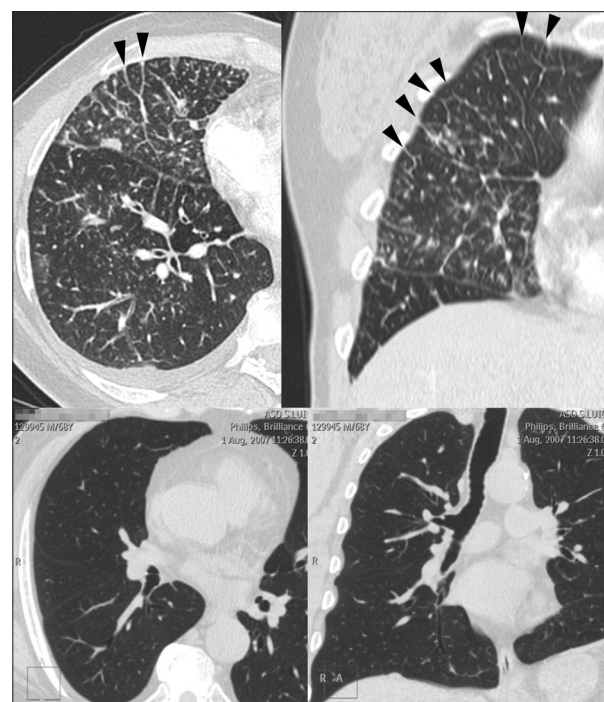
Sonography is a surface-imaging technique that cannot visualize any lesion located deeply in the lung. If there is some normally aerated lung between the probe and the lesion, we still have a mirror image on the screen that is false-negative finding. Lung sonography is useful only when the lesion reaches the lung surface. However, most of the lung conditions observed in critically ill and emergency situations are characterized by lesions that reach the lung surface. Why? For anatomic reasons. The secondary pulmonary lobule is the fundamental unit of the lung structure. In different pulmonary regions, the lobule is variably surrounded by the interlobular septa, which are connective structures that envelope the lung like a network and contain pulmonary veins and lymphatic vessels.²⁴ Secondary pulmonary lobules in the periphery are relatively large and are marginated by interlobular septa that are thicker than in other parts of the lung (Figure 4).²⁵ Alterations of the most peripheral septa can be studied by lung sonography. This feature also reflects the spatial distribution of most pulmonary consolidations. One study showed that in the critically ill, more than 98% of the consolidations due to pneumonia reached the lung surface.²⁶

Interstitial Syndrome

Interstitial syndrome is a condition in which alveolar air is impaired due to an increase in fluids in the interstitium, but some lung aeration is still preserved. The potential of lung sonography for the diagnosis of interstitial syndrome has been shown in studies on critically ill patients and in patients in the emergency department.^{3,10} The sonographic technique is based on the visualization of some vertical reverberation artifacts, the B-lines, that prevent the mirror effect and are expressions of high impedance discontinuities due to a close opposition between alveolar air and increased interstitial fluids.⁴ Even if a simple observation of the B-line pattern cannot differentiate between cardiogenic edema, acute respiratory distress syndrome, and pulmonary fibrosis, this simple bedside technique has an immediate effect on the real-time diagnostic process of critically ill and dyspneic patients. The use of a simplified lung sonographic pro-

ocol was more accurate than the conventional tools in the initial diagnoses of acute respiratory failure during the first 2 hours, showing a better immediate effect and yielding correct prompt diagnoses in 90.5% of patients.⁹ In the evaluation of patients with acute respiratory failure, the B-line pattern allows for a differentiation between a cardiogenic and a respiratory origin of the disorder because exacerbations of chronic obstructive pulmonary disease, pulmonary embolism, pneumonia, and pneumothorax yield a noninterstitial sonographic pattern.^{9,27–30} In select patients with acute decompensated heart failure or end-stage renal failure, B-lines represent a sign of extravascular lung water, which allows monitoring of pulmonary congestion by simply observing its clearance on repeated lung sonographic examinations.^{31–33} In patients with acute respiratory distress syndrome who receive invasive ventilation with positive pressure, sonographic evaluation for B-lines allows monitoring of re-aeration and can be used to guide therapeutic maneuvers.³⁴

Figure 4. Interlobular septa on computed tomography. Top panels, Transverse thin-section (left) and coronal (right) computed tomograms from a case of lymphangitic spread of carcinoma showing smooth interlobular septa thickening (arrowheads) that surrounds peripheral secondary pulmonary lobules, which are clearly visible at the lung surface. Bottom panels, Similar computed tomograms from a normal lung with regular interlobular septa.



Alveolar Syndrome

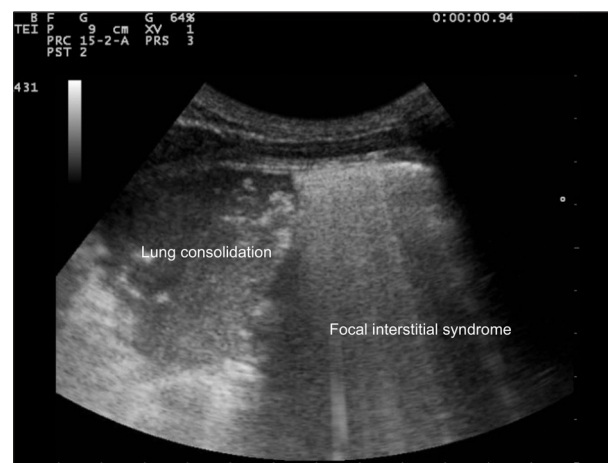Massive loss of air and increases in fluids cause lung consolidation: this syndrome is indicated as the alveolar as opposed to the interstitial type, in which alveoli still contain air. When the consolidation reaches the pleura and no aerated lung interposes under the probe, the lesion can be visualized on sonography as a hypoechoic region or a tissue-like echo texture, which differs visually from the surrounding aerated pattern.^{19,26,35–37} Very often, a sonogram of a consolidated lung with complete loss of air is imaged on the screen at a resolution close to that of a more advanced imaging technique, such as computed tomography or magnetic resonance. Even more, a sonographic examination of the lung has the advantage of being a real-time dynamic technique allowing analysis of respiratory movements.³⁸ Analysis of the shape, margin, distribution, vascularization, and some peculiar characteristics such as air and fluid bronchograms often allows for a differential diagnosis between different types of consolidation (ie, pneumonia, infarctions in pulmonary embolism, contusions, and obstructive and compressive atelectasis).^{12,18,26,38,39} The repeatability of sonographic examinations in critically ill patients with pneumonia allows monitoring of the effect of antibiotic and ventilation therapies.^{19,34,40} Reaeration can be followed by observing the change in the sonographic aspect of the lung, from the alveolar pattern of the consolidated lung to the interstitial pattern, which improves with a decreasing density and number of B-lines, to the final step of the mirror pattern sign of normal aeration. This principle was tested experimentally by observing the change in the sonographic lung pattern in real time during bronchoalveolar lavage of 7 patients treated for alveolar proteinosis.⁴¹ Deaeration of the treated lung due to fluid injection yielded a progression the sonograms from the mirror effect to the interstitial and consolidation patterns, whereas the same path in the opposite direction was observed during reaeration by removal of fluids.⁴¹ Another interesting aspect is that the interstitial and alveolar patterns can often coexist in the same condition, representing sonographic signs of different degrees of aeration of the affected lung (Figure 5 and Video 4).

Pleural Syndrome

Topics discussed to this point apply to the study of lung parenchyma and represent new applications of lung sonography. On the contrary, the use of lung sonography in the study of the pleural effusions can be considered a conventional application with well-recognized potential in the first diagnosis and in the quantification of even limited effusion.^{42–44}

However, a newly discovered potential of lung sonography is the ability to diagnose pneumothorax. In this condition, air interposes between the chest wall and the lung. For many years, sonography was considered unreliable for the study of pneumothorax because air cannot be visualized. However, air in the pleural space has many visible effects on the sonographic pattern. The most important is a dynamic effect. When air interposes between the parietal and visceral pleurae, the movement of the lung, both respiratory horizontal sliding and vertical cardiac pulsation transmitted by the heart, and the B-lines cannot be visualized. The presence of some sonographic signs, such as lung sliding, lung pulsation, or even a single B-line, predicts with certainty the absence of pneumothorax.^{13,45} Indeed, ruling in pneumothorax is possible when the “mirror image” of the lung is motionless and, in some point on the chest wall, regular sliding is again visualized. This point is known as the “lung point,” which represents the projection on the chest wall of the point where the lung adheres again to the parietal pleura, ie, the edge of the intrapleural air layer.⁴⁶ The potential of lung sonography in the diagnosis of pneumothorax is crucial, particularly in patients with cardiac arrest and unstable patients.^{14,47} In these extreme conditions, lung sonography represents a safe and accurate bedside method for guiding life-saving procedures. Moreover, the superiority over bedside chest radiography makes lung sonography the method of choice for the first evaluation of trauma patients and after invasive procedures.^{16,48–50}

Figure 5. Sonogram in a case of pneumonia. This scan shows coexistence of lung consolidation and interstitial syndrome (Video 4). The area of lung consolidation usually does not border normal parenchyma directly but is surrounded by focal interstitial involvement. Coexistence of these two patterns is the effect of different degrees of aeration in different zones of the same lung and shows that the alveolar and interstitial patterns are not two separate sonographic entities.



Conclusions

Alveolar air and the bones of the thoracic cage do not prevent the usefulness of sonography in the study of lung diseases. Although the use of this method has been neglected for many years, we can now consider bedside lung sonography a reliable modality for the study of many lung diseases, particularly in the emergency and critical care settings.¹⁵

References

- Manaker S, Weinberger SE. Diagnostic procedures in respiratory diseases. In: Fauci A, Braunwald E, Kasper DL, Hauser SL, Longo DL, Jameson LJ, Loscalzo J (eds). *Harrison's Principles of Internal Medicine*. 17th ed. New York, NY: McGraw-Hill; 2008:1593–1595.
- Moore CL, Copel JA. Point-of-care ultrasonography. *N Engl J Med* 2011; 364:749–757.
- Lichtenstein D, Mezière G, Biderman P, Gepner A, Barre O. The comet-tail artifact: an ultrasound sign of alveolar-interstitial syndrome. *Am J Respir Crit Care Med* 1997; 156:1640–1646.
- Soldati G, Copetti R, Sher S. Sonographic interstitial syndrome: the sound of lung water. *J Ultrasound Med* 2009; 28:163–174.
- Oelze ML, Miller RJ, Blue JP Jr, Zachary JF, O'Brien WD Jr. Estimation of the acoustic impedance of lung versus level of inflation for different species and ages of animals. *J Acoust Soc Am* 2008; 124:2340–2352.
- Soldati G, Giunta V, Sher S, Melosi F, Dini C. "Synthetic" comets: a new look at lung sonography. *Ultrasound Med Biol* 2011; 37:1762–1770.
- Baldi G, Gargani L, Abramo A, et al. Lung water assessment by lung ultrasonography in intensive care: a pilot study. *Intensive Care Med* 2013; 39:74–84.
- Soldati G, Inchingolo R, Smargiassi A, et al. Ex vivo lung sonography: morphologic-ultrasound relationship. *Ultrasound Med Biol* 2012; 38:1169–1179.
- Lichtenstein DA, Mezière GA. Relevance of lung ultrasound in the diagnosis of acute respiratory failure: the BLUE protocol. *Chest* 2008; 134:117–125.
- Volpicelli G, Mussa A, Garofalo G, et al. Bedside lung ultrasound in the assessment of alveolar-interstitial syndrome. *Am J Emerg Med* 2006; 24:689–696.
- Barskova T, Gargani L, Guiducci S, et al. Lung ultrasound for the screening of interstitial lung disease in very early systemic sclerosis [published online ahead of print May 15, 2012]. *Ann Rheum Dis*. doi:10.1136/annrheumdis-2011-201072.
- Volpicelli G, Caramello V, Cardinale L, Cravino M. Diagnosis of radio-ocult pulmonary conditions by real-time chest ultrasonography in patients with pleuritic pain. *Ultrasound Med Biol* 2008; 34:1717–1723.
- Lichtenstein DA, Menu Y. A bedside ultrasound sign ruling out pneumothorax in the critically ill: lung sliding. *Chest* 1995; 108:1345–1348.
- Volpicelli G. Sonographic diagnosis of pneumothorax. *Intensive Care Med* 2011; 37:224–232.
- Volpicelli G, Elbarbary M, Blaivas M, et al. International evidence-based recommendations for point-of-care lung ultrasound. *Intensive Care Med* 2012; 38:577–591.
- Lichtenstein DA, Mezière G, Lascols N, et al. Ultrasound diagnosis of occult pneumothorax. *Crit Care Med* 2005; 33:1231–1238.
- Lichtenstein D, Goldstein I, Mourgeon E, Cluzel P, Grenier P, Rouby JJ. Comparative diagnostic performances of auscultation, chest radiography, and lung ultrasonography in acute respiratory distress syndrome. *Anesthesiology* 2004; 100:9–15.
- Mathis G, Blank W, Reissig A, et al. Thoracic ultrasound for diagnosing pulmonary embolism: a prospective multicenter study of 352 patients. *Chest* 2005; 128:1531–1538.
- Reissig A, Copetti R, Mathis G, et al. Lung ultrasound in the diagnosis and follow-up of community-acquired pneumonia: a prospective multicentre diagnostic accuracy study. *Chest* 2012; 142:965–972.
- Soldati G, Testa A, Silva FR, Carbone L, Portale G, Silveri NG. Chest ultrasonography in lung contusion. *Chest* 2006; 130:533–538.
- Cortellaro F, Colombo S, Coen D, Duca PG. Lung ultrasound is an accurate diagnostic tool for the diagnosis of pneumonia in the emergency department. *Emerg Med J* 2012; 29:19–23.
- Mayo PH, Doelken P. Pleural ultrasonography. *Clin Chest Med* 2006; 27:215–227.
- Reuss J. Sonographic imaging of the pleura: nearly 30 years experience. *Eur J Ultrasound* 1996; 3:125–139.
- Webb WR. Thin-section CT of the secondary pulmonary lobule: anatomy and the image—the 2004 Fleischner lecture. *Radiology* 2006; 239:322–338.
- Heitzman ER, Markarian B, Berger I, Dailey E. The secondary pulmonary lobule: a practical concept for interpretation of chest radiographs. I. Roentgen anatomy of the normal secondary pulmonary lobule. *Radiology* 1969; 93:507–512.
- Lichtenstein DA, Lascols N, Mezière GA, Gepner A. Ultrasound diagnosis of alveolar consolidation in the critically ill. *Intensive Care Med* 2004; 30:276–281.
- Liteplo AS, Marill KA, Villen T, et al. Emergency thoracic ultrasound in the differentiation of the etiology of shortness of breath (ETUDES): sonographic B-lines and N-terminal pro-brain-type natriuretic peptide in diagnosing congestive heart failure. *Acad Emerg Med* 2009; 16:201–210.
- Zanobetti M, Poggioni C, Pini R. Can chest ultrasonography replace standard chest radiography for evaluation of acute dyspnea in the ED? *Chest* 2011; 139:1140–1147.
- Gargani L, Frassi F, Soldati G, Tesorio P, Gheorghide M, Picano E. Ultrasound lung comets for the differential diagnosis of acute cardiogenic dyspnoea: a comparison with natriuretic peptides. *Eur J Heart Fail* 2008; 10:70–77.
- Lichtenstein DA, Mezière G. A lung ultrasound sign allowing bedside distinction between pulmonary edema and COPD: the comet-tail artifact. *Intensive Care Med* 1998; 24:1331–1334.
- Mallamaci F, Benedetto FA, Tripepi R, et al. Detection of pulmonary congestion by chest ultrasound in dialysis patients. *JACC Cardiovasc Imaging* 2010; 3:586–594.

32. Noble VE, Murray AF, Capp R, Sylvia-Reardon MH, Steele DJ, Liteplo A. Ultrasound assessment for extravascular lung water in patients undergoing hemodialysis: time course for resolution. *Chest* 2009; 135:1433–1439.
33. Volpicelli G, Caramello V, Cardinale L, Mussa A, Bar F, Frascisco MF. Bedside ultrasound of the lung for the monitoring of acute decompensated heart failure. *Am J Emerg Med* 2008; 26:585–591.
34. Bouhemad B, Brisson H, Le-Guen M, Arbelot C, Lu Q, Rouby JJ. Bedside ultrasound assessment of positive end-expiratory pressure-induced lung recruitment. *Am J Respir Crit Care Med* 2011; 183:341–347.
35. Gehmacher O, Mathis G, Kopf A, Scheier M. Ultrasound imaging of pneumonia. *Ultrasound Med Biol* 1995; 21:1119–1122.
36. Mathis G, Beckh S, Gorg C. Subpleural lung consolidations. In: Mathis G (ed). *Chest Sonography*. 2nd ed. Berlin, Germany: Springer-Verlag; 2008:47–106.
37. Parlamento S, Copetti R, Di Bartolomeo S. Evaluation of lung ultrasound for the diagnosis of pneumonia in the ED. *Am J Emerg Med* 2009; 27:379–384.
38. Lichtenstein D, Mezière G, Seitz J. The dynamic air bronchogram: a lung ultrasound sign of alveolar consolidation ruling out atelectasis. *Chest* 2009; 135:1421–1425.
39. Reissig A, Heyne JP, Kroegel C. Sonography of lung and pleura in pulmonary embolism: sonomorphologic characterization and comparison with spiral CT scanning. *Chest* 2001; 120:1977–1983.
40. Bouhemad B, Liu ZH, Arbelot C, et al. Ultrasound assessment of antibiotic-induced pulmonary re-aeration in ventilator-associated pneumonia. *Crit Care Med* 2010; 38:84–92.
41. Via G, Lichtenstein D, Mojoli F, et al. Whole lung lavage: a unique model for ultrasound assessment of lung aeration changes. *Intensive Care Med* 2010; 36:999–1007.
42. Kocijancic I, Vidmar K, Ivanovi-Herceg Z. Chest sonography versus lateral decubitus radiography in the diagnosis of small pleural effusions. *J Clin Ultrasound* 2003; 31:69–74.
43. Remerand F, Dellamonica J, Mao Z, et al. Multiplane ultrasound approach to quantify pleural effusion at the bedside. *Intensive Care Med* 2010; 36:656–664.
44. Yang PC, Luh KT, Chang DB, Wu HD, Yu CJ, Kuo SH. Value of sonography in determining the nature of pleural effusion: analysis of 320 cases. *AJR Am J Roentgenol* 1992; 159:29–33.
45. Lichtenstein D, Mezière G, Biderman P, Gepner A. The comet-tail artifact: an ultrasound sign ruling out pneumothorax. *Intensive Care Med* 1999; 25:383–388.
46. Lichtenstein D, Mezière G, Biderman P, Gepner A. The “lung point”: an ultrasound sign specific to pneumothorax. *Intensive Care Med* 2000; 26:1434–1440.
47. Kirkpatrick AW, Sirois M, Laupland KB, et al. Hand-held thoracic sonography for detecting post-traumatic pneumothoraces: the extended focused assessment with sonography for trauma (EFAST). *J Trauma* 2004; 57:288–295.
48. Reissig A, Kroegel C. Accuracy of transthoracic sonography in excluding post-interventional pneumothorax and hydropneumothorax: comparison to chest radiography. *Eur J Radiol* 2005; 53:463–470.
49. Sartori S, Tombesi P, Trevisani L, Nielsen I, Tassinari D, Abbasciano V. Accuracy of transthoracic sonography in detection of pneumothorax after sonographically guided lung biopsy: prospective comparison with chest radiography. *AJR Am J Roentgenol* 2007; 188:37–41.
50. Soldati G, Testa A, Sher S, Pignataro G, La Sala M, Silveri NG. Occult traumatic pneumothorax: diagnostic accuracy of lung ultrasonography in the emergency department. *Chest* 2008; 133:204–211.