

Safe and effective alternatives to sinus elevation in the atrophic posterior maxilla

Part II—A master thesis

Author_Dr Adel A Chidiac, Kuwait

Fig. 1 Diagram of implant insertion in the maxilla.
 a_Conventional straight vertical position
 b_Mesio-distal angulations of the implants permitting longer implants posterior as well as better distal support of the denture.

Fig. 2 Sagittal cross-section reconstructed perpendicular to the alveolar crest. From the 4-mm level (1), the distance to the bottom of the maxillary sinus and the nasal cavity (2) can be determined.

Fig. 3 Presurgical radiography.

_Maxillary sinus elevation and bone augmentation are acceptable techniques that may provide sufficient bone quantity and quality for implant support in the posterior atrophic maxilla (Wallace SS et al. 2003). Yet, given the morbidity risk plus cost and time consuming effects, these techniques are to be reconsidered. Simpler and safer protocols are therefore required for the posterior maxilla where bone resorption, deficient posterior alveolar ridge, and increased pneumatization of the sinus all result in a minimal hard tissue bed thus render implant placement difficult (Frank R et al. 2005).

Part I of this publication reported about the aim of the master thesis and materials and methods. Part II follows up with the surgical techniques, dis-

cussion and conclusions avoiding a sinus lift procedure.

_Surgical techniques

Tilted implants

The standard procedure is to install the implant, totally covered with bone, in a vertical position. This requires the bone volume in the maxillary alveolar crest to be at least 10 mm vertically and 4 mm horizontally. The success rates of implant treatments as per such procedure are 95 to 99 % (Triplett RG et al. 2000). In case of less bone volume, bone grafting is one of several procedures to reach the required bone volume. An alternative, however, was presented for severely resorbed alveolar crest (CI IV, V) in which im-

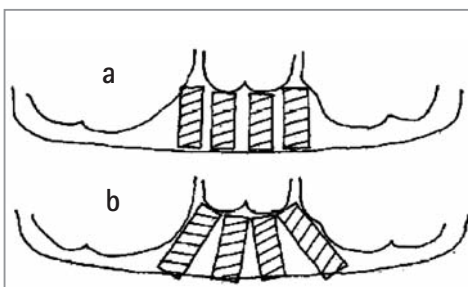


Fig. 1

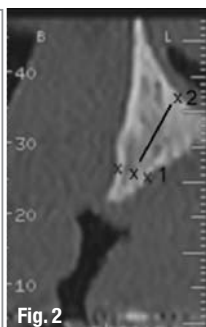


Fig. 2

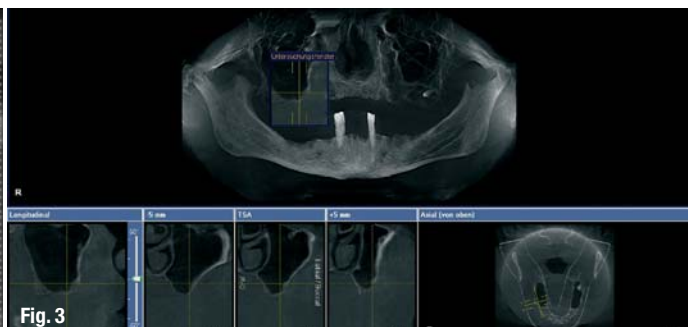


Fig. 3




Fig. 4a

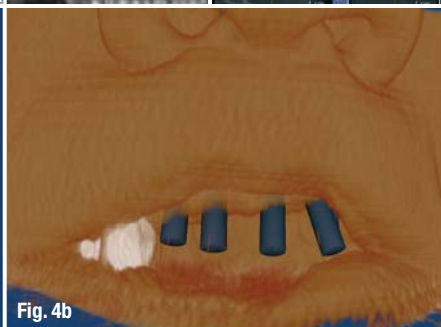


Fig. 4b

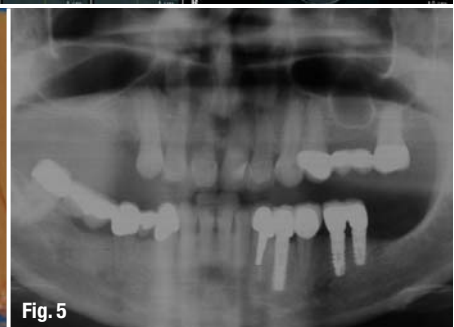


Fig. 5

plants were placed without bone grafting (Mattsson T et al. 1999). Theoretically, tilted implants in the residual crestal bone lead to (Aparicio et al. 2001):

- (a) Placement of longer implants that increases implant-to-bone contact area and implant primary stability;
- (b) Longer distance between implants that allows the elimination of cantilevers in the prosthesis thus improving load distribution;
- (c) Placement of implants in residual bone that avoids further complex techniques such as sinus lifting or bone grafting.

Clinically, the anatomy of the bone within the margins of the nasal cavity, the maxillary sinuses, and the alveolar crest margin all allow alternative mesio-distal angulations of implants. The height at the 4 mm width of an alveolar crest, being the measure to describe the available bone volume for total coverage of the implant, is often not enough for implant installation in severely resorbed maxillae.

Mesio-distal angulations of the implant thus provides better primary stability than conventional straight vertical positioning as it permits the use of a longer implant. A surgical technique was developed to make use of the maximum amount of available bone and to allow the installation of longer implants as indicated from computed tomography parasagittal reconstructions (Fig. 1; Mattsson T et al. 1999).

Mattsson et al. described a surgical technique to visualize the total amount of maxillary bone and to place posterior implants at a more than 30 degree

angle to the horizontal plane. By this technique the fixed bridge can be extended to at least the first molar position without previous bone grafting.

Presurgical examinations include a panoramic radiograph. Yet, in most cases, the extension of the maxillary sinus or the nasal cavity and the volume and density of the remaining bone are evaluated by maxillary computed tomography (Fig. 2). The estimation of bone quantity and bone quality is based on presurgical radiography and computer aided planning (Figs. 3 & 4) as well as on the resistance of bone to drilling during surgery (Kerkmanov et al. 2000).

Significantly, tilted implants can be anchored in the bone pyramid anterior to the maxillary sinus where anatomic vital structures, such as arteries or nerves, are absent. Multiunit implantation thus allows the extension of prosthetic support posteriorly and reduces cantilever arms. The results of biomechanical analyses and animal study indicate that tilting implants has no adverse effect on bone resorption (Gotfredsen K et al. 2001).

This alternative is in fact less time-consuming for the patient and the dentist; scientific investigations support the concept of immediate and early function as a modern therapeutic option (Testori T et al. 2004). Table 1 shows different degrees of angulations

Number of implants per angulation		
Inclination	15-30°	>30°
Mesiodistal	0	23
Distomesial	4	0

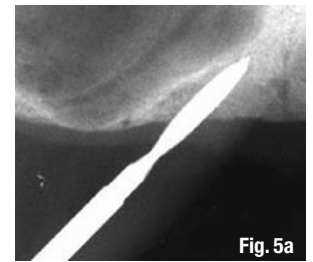


Fig. 4a Presurgical computer aided planning (IMPLA 3D).

Fig. 4b Presurgical soft tissue appearance (IMPLA 3D).

Fig. 5 Situation pre operation (Courtesy Dr R. & M. Vollmer).

Fig. 5a Drilling of the tilted implant site. Placing mesial axial implants before tilted ones. Intraoperative radiographs or navigation are necessary to assess the precise drilling direction.

Fig. 5b After the pilot drilling for the tilted implant osteotomes are used for enlargement and final preparation of the implant site. First the axial implant was inserted.

Fig. 5c Tilted implant insertion following the direction of the initial hole.

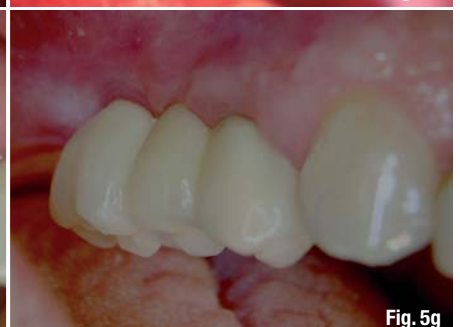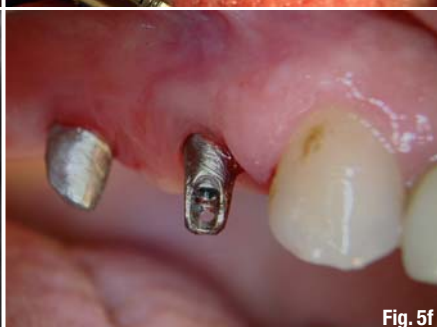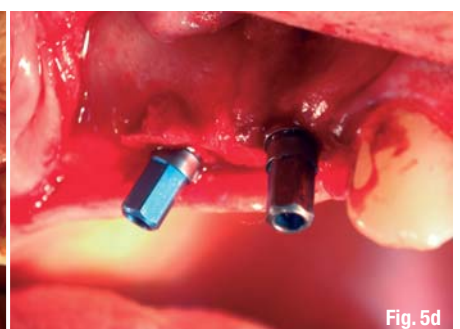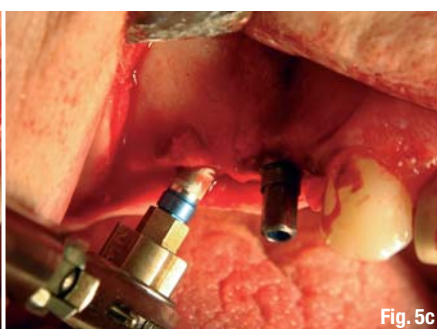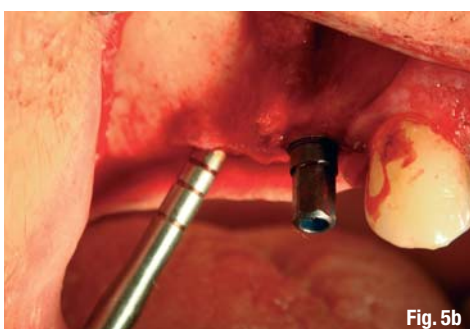
Fig. 5d Tilted implant in site.

Fig. 5e Radiograph after insertion.

Fig. 5f Exposure and insertion of the abutments.

Fig. 5g Final result.

Table 1 Degrees of angulations of tilted implants.



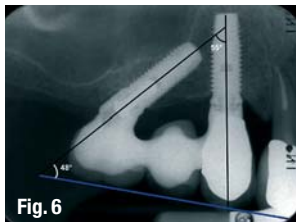


Fig. 6 Surgical placement of an axial implant following the anterior wall of the maxillary sinus is shown. The mesial axial implant will be the guide for the orientation of the tilted implant.

Fig. 7 Implant inserted in the tuberosity.

Fig. 8 Situation pre surgery with a small sinus situation.

Fig. 9 Osteotomes.

Fig. 10 Modified osteotomes (Zepf) for bone harvesting and condensing.

Fig. 11a Insertion of modified osteotomes (Zepf acc. to Vollmer and Valentin).

Fig. 11b Implants in site (IMPLA 3D, Schütz).

Fig. 11c Fixation of the angulated abutment.

of tilted implants. Figure 5 (Vollmer R et al. 2008, Candiello R et al. 2005), and Figure 6 illustrate the insertion of tilted implants (Aparicio C et al. 2001).

Tuberosity implants

Recently the maxillary tuberosity region has been increasingly utilized in preprosthetic implantation surgery especially when sinus floor elevation and bone grafting are rejected by patients due to high cost, longer healing time and increased risk of intra-operative complications. Implants, however, can be inserted in the maxillary tuberosity region as an alternative to sinus floor elevation (Fig. 7; Regeev E et al. 1995).

Osteotomy during the implantation in the maxillary tuberosity is most likely performed by an expansive and bone condensing technique with almost no bone removal like in the clinical case (Figs. 8 & 11a-e). Such osteotomy is certainly achieved in Type D IV bone acc. to the C. E. Misch classification in the tuberosity by avoiding drilling and thus reducing complications mainly hemorrhage from the palatine artery (Fernandez V. 1997).

Efficient in the maxillary tuberosity, Summers Osteotomes favor osseointegration by minimizing bone heating, dilating and compacting spongy bone, and maintaining the remaining maxillary bone (White GE 1993; Fig. 9). Summers osteotomes were modified to improve the access in the challenging areas through a double shaft design involving less pressure and less tension on the labial commissural. These modified

osteotomes allow obtaining best handling of the implant receiving site (Fig. 10; Valentin, Vollmer & Vollmer, 2002). Figures 11a-e demonstrate the final clinical case (Courtesy of Dr R. Vollmer & Dr M. Vollmer and Dr R. Valentin).

Disk implants

Disk Implant or basal osseointegrated implant can be installed where the vertical bone supply is reduced. This applies to the posterior areas of the maxilla (Ihde S et al. 2004). The insertion of the disk-design implant is laterally performed. The technique is less invasive than bone grafting and allows a tricortical or multicortical anchorage (Bocklage R. 2001).



Fig. 10

_Discussion

Short implants

Implantation in the atrophic posterior area of the maxilla is a challenge. The placement of short implants in this area is yet another alternative to sinus elevation and bone augmentation. The use of short implants (10 mm) has been a source of debate in the past decade. Some studies report higher failure rates with short implants; others report comparable results to longer implants (Buser D et al. 2000). Frequently affected by minimized bone volume, edentulous sites in the posterior maxilla prevent the placement of 10 mm implants without sinus augmentation. If shorter implants are used nevertheless, the need for more extensive sinus floor elevation is diminished and both treatment duration and morbidity are reduced (Toffler M. 2006).

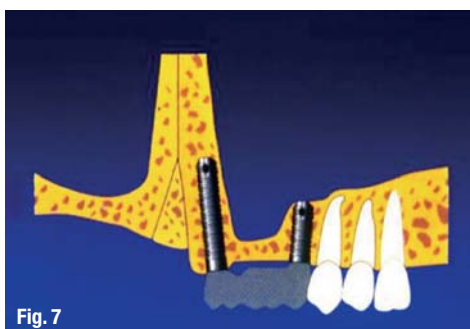


Fig. 7

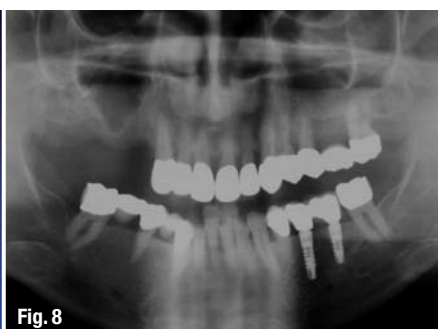

Fig. 8



Fig. 9

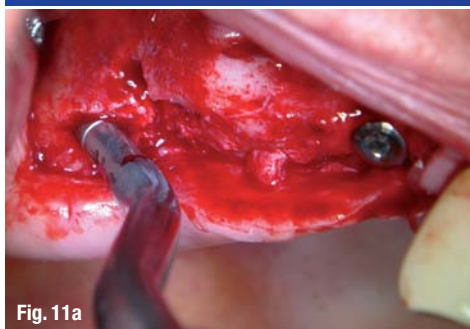


Fig. 11a

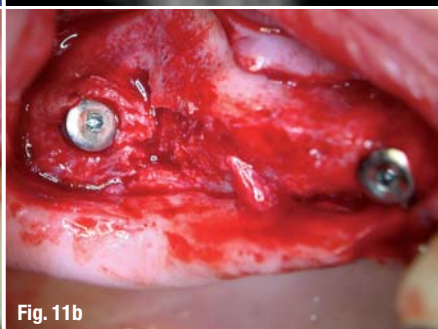


Fig. 11b

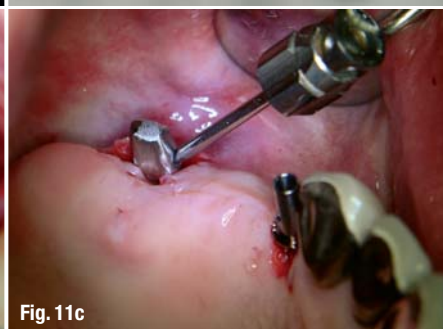

Fig. 11c

cosmetic

dentistry _ beauty & science

With the reduced amounts of bone, the use of long implants would be a difficult option. Although several studies in the literature have shown that short implants have risk factors therefore higher failure rate (Winkler S et al. 2005), the recent studies prove the good long term prognosis of short implants (Tawil G et al. 2006).

A review of the results displayed above show a range of success between 92% and 96% approximately. Failure rates were minimized by using the short implants due to several variables, including among others, change in implant design, splinting implants together, absence of cantilevers in the prosthesis, and additional methods to decrease stress to the implant interface. According to the same results, it is possible to use short implants to support fixed restorations in the atrophic posterior maxilla (Misch et al. 2006).

Implant sizes did not appear to compromise the effectiveness (Romeo E et al. 2006), and the short length was not associated with reduced survival rates (Arlin ML 2006). Researchers using finite elemental analysis (FEA) demonstrated that vertical and horizontal occlusal forces placed on implants were distributed primarily in the crestal bone rather than along the implant/bone interface. The group of Lum concludes that short implants serve as well as longer ones. Short implants show a survival rate exceeding five years and crestal bone level maintenance similar to longer implants. They can be successfully used in maxilla with limited bone length (Venuelo C et al. 2008).

Tilted implants

The results of applying the technique of using posterior tilted implants are comparable with the more resource demanding techniques applying bone grafting which often necessitates general anesthesia and hospitalization and could often lead to the following implications, including but not limited to, postoperative infection problems with the graft or maxillary sinusitis, host morbidity, lower implant success rates, and higher cost of treatment (Yerit KC et al. 2004). In fact, by tilting the posterior implants in the maxilla, the compromised bone of the sinus antrum could be circumvented with the clinical advantage of avoiding cantilever arms and using fewer implants (Calandriello R et al. 2005).

Mattsson et al. were the first to report well functioning fixed prostheses with no symptoms after treatment with the tilted implant technique (Annika R et al 2007). The success rate for the patients included in the study was 97%. Krekmanov et al also demonstrate that biomechanical measurements in tilting implants showed no negative effects on load



One issue free of charge!



Subscribe now!

*Prices include shipping and VAT

- I hereby agree to receive a free trial subscription of **cosmetic dentistry** (4 issues per year). I would like to subscribe to **cosmetic dentistry** for € 44* for German customers, € 46* for customers outside Germany, unless a written cancellation is sent within 14 days of the receipt of the trial subscription. The subscription will be renewed automatically every year until a written cancellation is sent to OEMUS MEDIA AG, Holbeinstr. 29, 04229 Leipzig, Germany, six weeks prior to the renewal date.

▶ **Reply** per Fax +49-(0) 3 41/4 84 74-2 90 to OEMUS MEDIA AG or per E-mail to grasse@oemus-media.de

IM 1/10

Last Name, First Name

Company

Street

ZIP/City/Country

E-mail

Signature

Notice of revocation: I am able to revoke the subscription within 14 days after my order by sending a written cancellation to OEMUS MEDIA AG, Holbeinstr. 29, 04229 Leipzig, Germany.

Signature

OEMUS MEDIA AG Holbeinstr. 29, 04229 Leipzig, Germany

Tel.: +49-(0) 3 41/4 84 74-0, Fax: +49-(0) 3 41/4 84 74-2 90, E-Mail: grasse@oemus-media.de



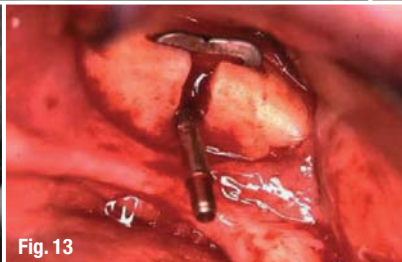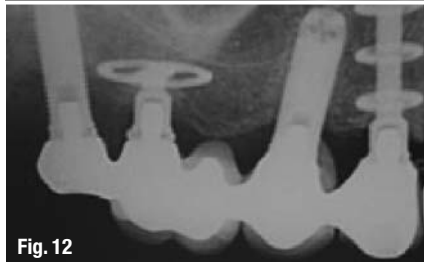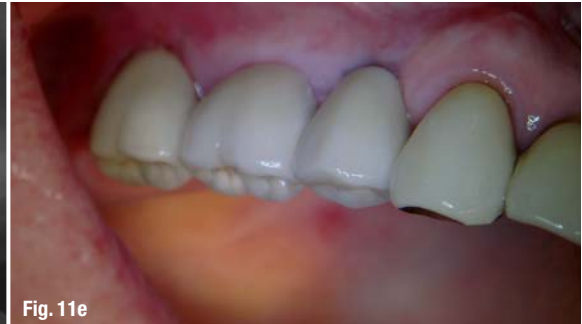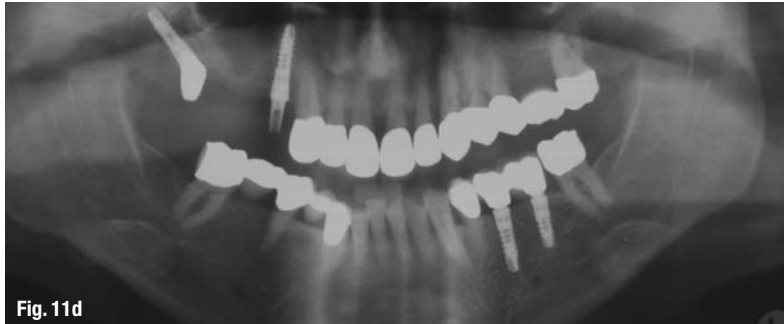


Fig. 11d Situation post surgery. Perfect seating of the individually casted angulated abutment.

Fig. 11e Final prosthetics.

Fig. 12 Disk Implant X-Ray.

(Martin Schweppe 2007 Wikipedia).

Fig. 13 Lateral insertion of a disk implant.

distribution in fixed prosthetic constructions. The different follow up studies prove that patients with severely resorbed maxillae can be treated successfully with conventional implant treatment (Kerkmanow L et al. 2000).

Relatively easy to be applied, the implant tilting technique decreases the treatment time compared with bone grafting and more extensive procedures such as zygoma implants. The need for other more resource demanding techniques is sometimes overestimated. However, bone augmentation may be still necessary in case bone volume is severely limited (Annika R et al. 2007).

Tuberosity implants

The few studies on implantation in the tuberosity show high percentage of success rate on condition that strict protocols and careful handling are applied to preserve the soft bone in this area (Venturelli A 1996). In combination with tilting the implants the indications for this therapy concept even increase.

Disk implants

Despite the shortage of clinical studies in the literature, the use of disk implant may be an alternative to bone augmentation in both moderately and severely resorbed posterior maxillae. The initial multicortical anchorage provided by the disk-design implant, coupled with biomechanical splinting through a rigid prosthesis, permits a one stage predictable alternative offering rapid restoration of masticatory function (Scortecchi G 1999).

_ Conclusion

The thesis highlights alternatives to sinus elevation and bone augmentation in the atrophic poste-

rior maxilla. These alternatives prove to be (a) safer than, and (b) as effective as, maxillary sinus elevation and bone augmentation techniques. The overall results show high rate of success: 90 % and above.

Short implants, tilted implants and tuberosity implants involve mainly less morbidity and less invasive surgeries. Patients are likely to be less reluctant compared to sinus elevation and bone grafting. Disk implants are worth considering despite the more invasive procedure and the shortage of high level evidence based studies. Further data, however, are required to elaborate on the safety and effectiveness of this alternative.

Recently practiced, the three dimensional implant planning software for computed tomographic (CT) scan (e.g. Schütz IMPLA-3D Navigation; Merli M et al. 2008) is becoming of benefit as it may help evaluate the exact remaining bone in the maxilla. Such planning allows the application of the most convenient implant like fshort implant, tilted implant or tuberosity implant or a combination of both. Interestingly, to avoid a sinus elevation and bone augmentation to the most possible, the examined alternatives in this thesis may be applied in sole or in either combination to rehabilitate the posterior atrophic maxilla.

I would like to thank:

Prof. Nabil Barakat , Lebanese University, Beirut, Lebanon; Dr. Mazen Tamimi, Private Practice, Amman, Jordan; Dr. Rainer Valentin, Private practice, Cologne, Germany; Dr. R. & M. Vollmer, Private practices, Wissen, Germany, for their support.

Editorial note: The literature list can be requested from the author.

_contact	implants
<p>Dr Adel Chidiac International Clinic P.O. Box 6649 Salmiya 22077 Kuwait E-Mail: adelchidiac10@hotmail.com</p>	