

Navigated Implantation for anodontia 12 and 22

An illustrated case study

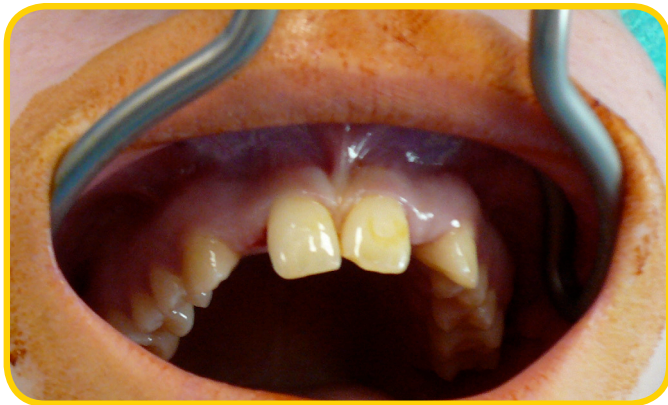by Dr. med. dent. Hans-Jürgen Werdecker, Staufenberg/Germany

Clinical situation:

A 19 year-old, female patient with anodontia in both her lateral incisors (12 and 22). Orthodontic treatment was performed prior to this treatment.

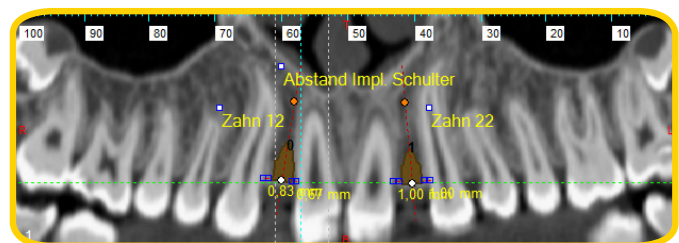
An implantation using a two-stage 3.3 mm implant was not possible in this case due to the lack of space available. This is why I chose to work with the IMPLA Mini-conetop which is my preference when dealing with limited space cases.

After the DVT scan, a template was digitally milled using CAD/CAM technology.



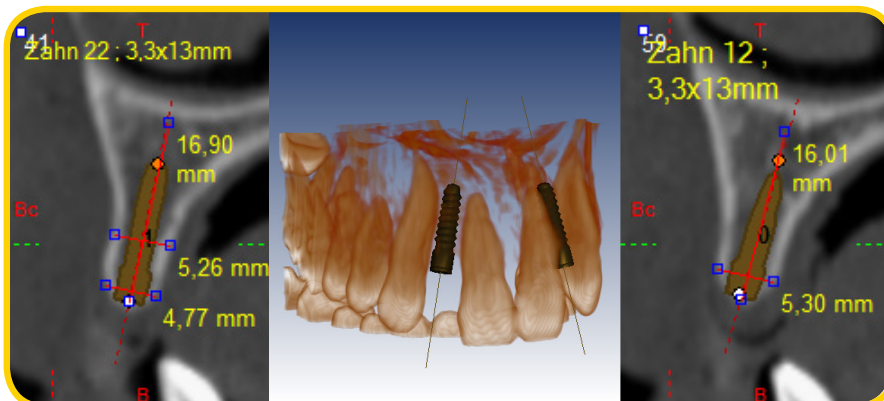
Oral situation before the surgery

3D x-ray data

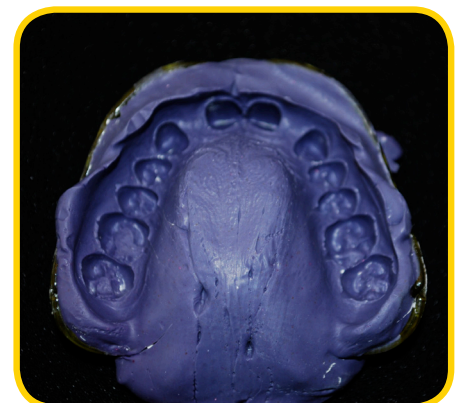


Panorama view of the oral situation

Volume histogram and cross sections



Measurements of the horizontal and vertical available bone



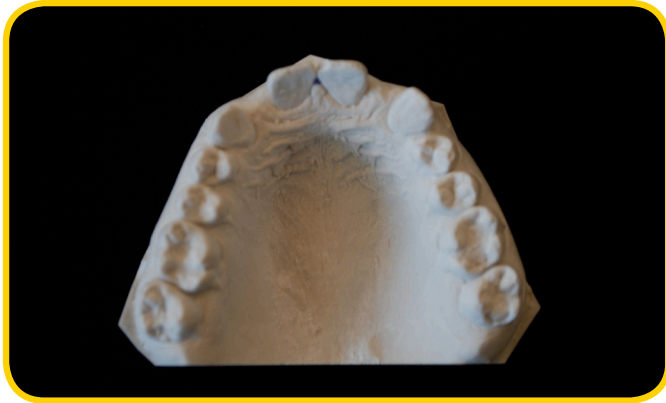
Impression of the situation

Navigated Implantation for anodontia 12 and 22

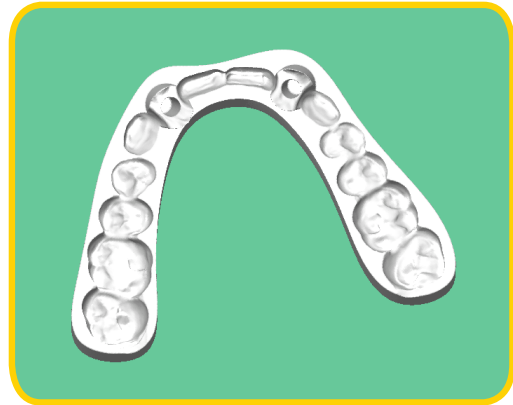An illustrated case study

by Dr. med. dent. Hans-Jürgen Werdecker, Staufenberg/Germany

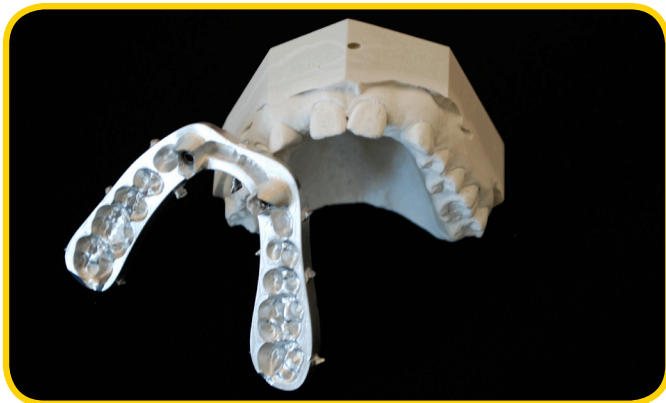
The master model was scanned using a model scanner. The data from the x-ray was compared virtually with the data from the model scan.



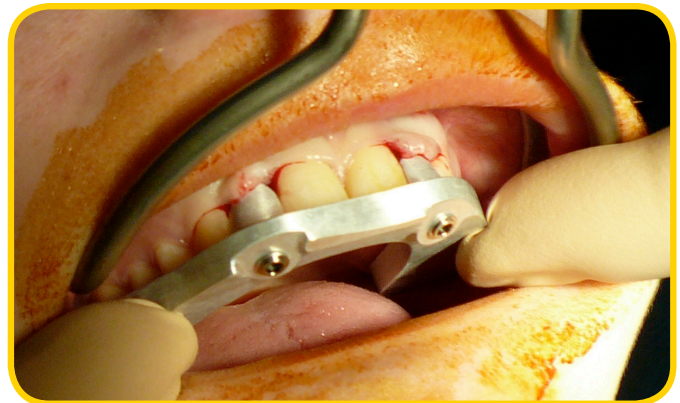Virtual framework of the drilling template



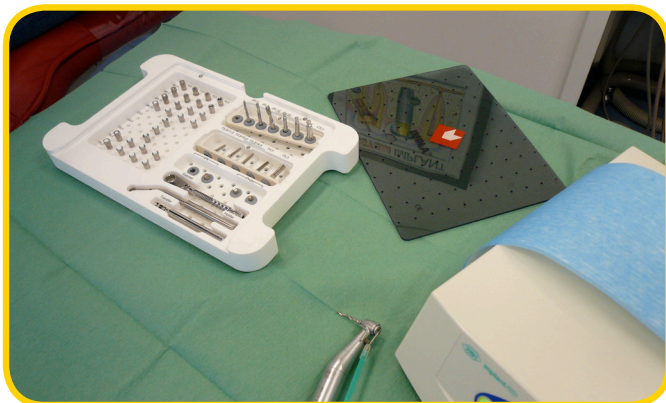Milled CAD/CAM template for navigated surgery



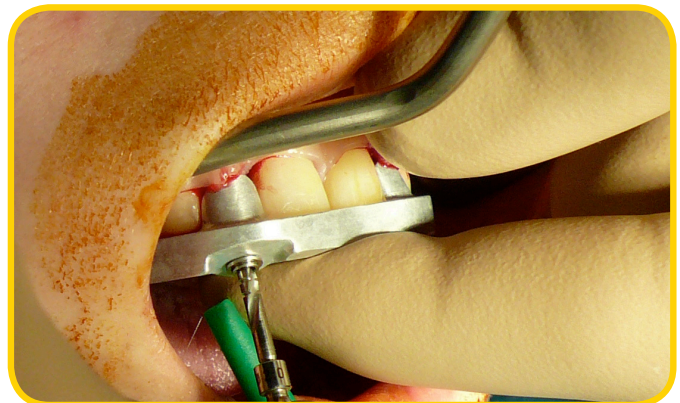Checking the precise fit against the master model.



Positioning the milled template locally



IMPLA 3D surgical tray

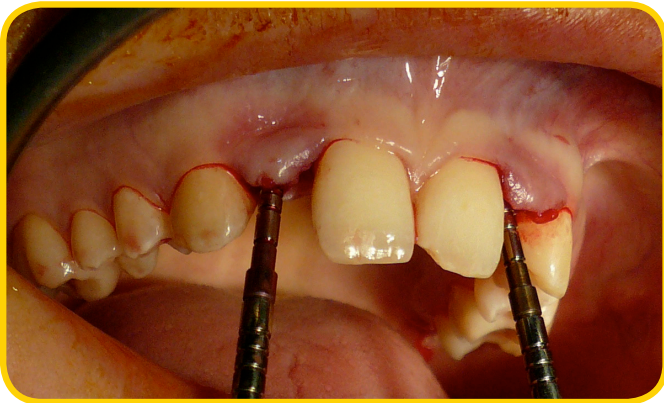

Fully guided drilling of the implant bed

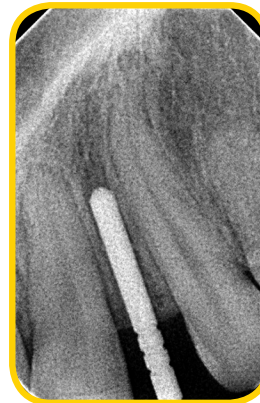Navigated Implantation for anodontia 12 and 22

An illustrated case study

by Dr. med. dent. Hans-Jürgen Werdecker, Staufenberg/Germany



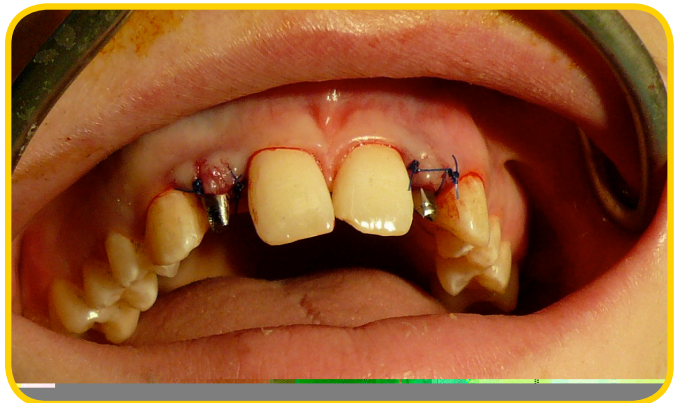Depth gauges for the control x-ray before insertion



Control x-ray



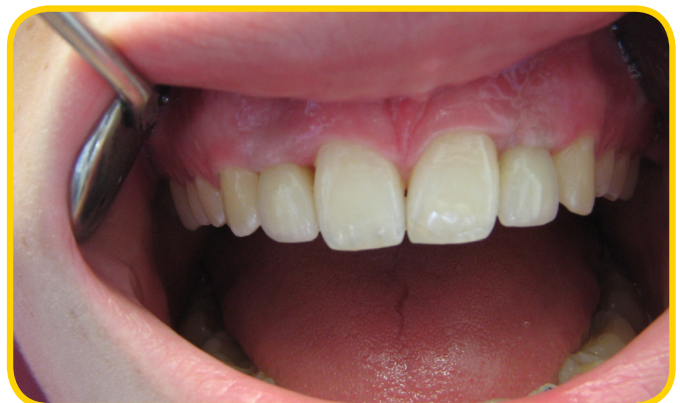The IMPLA Mini-conetop
3.0 mm/13 mm implant to be inserted



Clinical situation directly after the surgery with prepared, one-piece implants (IMPLA Mini-conetop 3.0 mm)



After surgery: protecting the implants with a temporary orthodontic tray



Situation directly after the crowns have been fitted (6 months after the surgery)

Please note: This report is not a user-manual. Please take strict note of the instructions for this system. The responsibility lies with the user.

Navigated Implantation for anodontia 12 and 22

An illustrated case study

by Dr. med. dent. Hans-Jürgen Werdecker, Staufenberg/Germany

This patient was treated by:

Dr. med. dent. Hans-Jürgen Werdecker
Rathausstraße 20
35460 Staufenberg/Germany



Would you like to report your cases to us?
Then simply get in touch:

Telephone
+49 6003 814-365
or
e-mail
export@schuetz-dental.de

We look forward to hearing from you!