

Original Article

Efficacy of a Polyethylene Oxide–Sodium Carboxymethylcellulose Gel in Prevention of Intrauterine Adhesions After Hysteroscopic Surgery

Attilio Di Spiezio Sardo, MD, PhD*, Marialuigia Spinelli, MD, Silvia Bramante, MD, Marianna Scognamiglio, MD, Elena Greco, MD, Maurizio Guida, MD, Vito Cela, MD, and Carmine Nappi, MD

From the Department of Gynaecology and Obstetrics, and Pathophysiology of Human Reproduction (Drs. Di Spiezio, Spinelli, Bramante, Scognamiglio, Greco, Guida, and Nappi), University of Naples "Federico II," Naples, Italy, and Department of Reproductive Medicine and Child Development (Dr. Cela), Division of Obstetrics and Gynecology, University of Pisa, Pisa, Italy.

ABSTRACT **Study Objectives:** To assess the efficacy of a polyethylene oxide–sodium carboxymethylcellulose gel (Intercoat; Gynecare, division of Ethicon, Inc., Somerville, NJ) in preventing the development of de novo intrauterine adhesions (IUAs) after hysteroscopic surgery and to rate the patency of the internal uterine ostium at 1-month follow-up diagnostic hysteroscopy.

Design: Randomized controlled study (Canadian Task Force classification I).

Setting: University hospital.

Patients: One hundred ten patients diagnosed during office hysteroscopy as having single or multiple lesions suitable for surgical treatment or resistant dysfunctional uterine bleeding requiring endometrial ablation.

Interventions: Patients were randomized to 2 groups. Group 1 underwent hysteroscopic surgery plus intrauterine application of Intercoat gel, and group 2 underwent hysteroscopic surgery only (control group). Follow-up office hysteroscopy was performed at 1 month after surgery to assess the rate and severity of IUA formation and to rate the patency of the internal uterine ostium after the surgical intervention.

Measurements and Main Results: Compared with the group 2, group 1 demonstrated a significant reduction in the incidence (6% vs 22%; $p < .05$) of de-novo IUAs. Application of the gel seemed to reduce the severity of IUAs, with fewer moderate and severe IUAs at follow-up in group 1 in comparison with group 2 (33% vs 92%). Furthermore, group 1 demonstrated significant improvement in the degree of patency of the internal uterine ostium (41.9% of cases) in comparison with diagnostic office hysteroscopy performed at enrollment ($p < .05$). In contrast, in group 2, worsening of patency of the internal uterine ostium was recorded in 18.2% of cases ($p < .05$).

Conclusions: Intercoat gel seems to prevent de novo formation of IUAs and to improve the patency of the internal uterine ostium at follow-up hysteroscopy. However, larger studies are needed to confirm these findings. Journal of Minimally Invasive Gynecology (2011) 18, 462–469 © 2011 AAGL. All rights reserved.

Keywords: Barrier agent; Cervical patency; Hysteroscopic surgery; Intrauterine adhesions; Prevention

DISCUSS You can discuss this article with its authors and with other AAGL members at <http://www.AAGL.org/jmig-18-4-1676>



Use your Smartphone to scan this QR code and connect to the discussion forum for this article now*

* Download a free QR Code scanner by searching for "QR scanner" in your smartphone's app store or app marketplace.

The authors have no commercial, proprietary, or financial interest in the products or companies described in this article.

Corresponding author: Attilio Di Spiezio Sardo, MD, PhD, Department of Gynecology and Obstetrics, and Pathophysiology of Human Reproduction, University of Naples "Federico II," Via Pansini 5, Naples 80131, Italy. E-mail: cdispie@tin.it

Submitted February 5, 2011. Accepted for publication April 22, 2011. Available at www.sciencedirect.com and www.jmig.org

Intrauterine adhesions (IUAs) are fibrous intrauterine bands on opposing walls of the uterus. The primary factors that may trigger IUA formation include curettage after abortion or postpartum, when the uterus is more prone to injury; infections; prolonged retention of an intrauterine device; and operative hysteroscopy [1–4].

Recent developments in technique and technology have encouraged the rapid widespread use of hysteroscopic

surgery while reducing the need for traditional curettage. Therefore, as the number of operative hysteroscopic procedures has increased, the rate of postsurgical IUAs has also become higher, currently representing the major long-term complication of operative hysteroscopy [3,5,6].

The frequency of postsurgical IUAs varies according to the indication for surgery, severity of the condition, patient age, and type of surgical procedure [1,7]. Few articles reporting the incidence of postsurgical IUAs (6%; single myomectomy, 33%; and multiple myomectomy, 45%) have demonstrated that the complexity of the hysteroscopic surgery is one of the primary determinants of IUA formation metroplasty [1,3,8,9].

Intrauterine adhesions can be classified as *de novo* when they develop at sites that did not have adhesions initially, and as re-formed when they redevelop at sites where adhesiolysis had been previously performed [2]. They can be also classified by the degree of obliteration of the uterine cavity. Over time, several scoring systems have been described to classify the severity of IUAs [8–14]. However, the American Fertility Society classification system is used by most of the gynecologic community [10].

Intrauterine adhesions are important clinically because they may result in infertility, recurrent miscarriage, and irregular cycles with dysmenorrhea and pelvic pain [9–18]. Furthermore, an IUA that either partially or completely obstructs the isthmus or the internal uterine ostium may cause hematometra, severe cramping pelvic pain, and difficulties in accessing the uterine cavity during office hysteroscopy.

Adherence to appropriate hysteroscopic surgical techniques may minimize the risk of postoperative IUAs. General recommendations include preventing trauma to healthy endometrium and myometrium surrounding the lesions to be removed; reducing the use of electrosurgery when possible [19], especially during removal of myomas with extensive intramural involvement [20]; and averting forced cervical manipulation [21].

Several strategies have been developed in an attempt to minimize the risk of postsurgical IUAs [22–24] including administration of pharmacologic agents such as antibiotics [25], gonadotropin-releasing hormone analogues [1], and postoperative conjugated estrogens [26]; use of barrier methods such as a Foley catheter or an intrauterine device [27–29]; and application of gel [3,6]. However, at present, no single method has proved unequivocally effective in preventing postoperative IUAs [21].

Intercoat Absorbable Adhesion Barrier Gel (Gynecare, division of Ethicon, Inc., Somerville, NJ) is a viscoelastic gel formulated for laparoscopic application. It is composed of polyethylene oxide and sodium carboxymethylcellulose stabilized with calcium chloride, and has high tissue adherence and persistence sufficient to prevent adhesion formation [30–32].

The objective of this prospective, randomized, controlled study was to assess the efficacy of Intercoat gel in preventing postsurgical *de novo* adhesions after hysteroscopic surgery

and in improving the patency of the internal uterine ostium at 1-month-follow-up hysteroscopy.

Materials and Methods

The protocol of this study was approved by our institutional review board, and the study was performed according to the guidelines of the 1975 Declaration of Helsinki on human experimentation.

All premenopausal women diagnosed at office diagnostic hysteroscopy as having single or multiple lesions suitable for surgical treatment or with resistant dysfunctional uterine bleeding requiring endometrial ablation were invited to participate in the study. Between September 2008 and June 2009, 110 premenopausal women were enrolled in the study. Before enrollment, the objectives of the study were explained clearly to all patients, and written consent was obtained.

Exclusion criteria were body mass index greater than 30, menopause (follicle-stimulating hormone concentration >40 mIU/mL and 17 β -estradiol <20 pg/mL) or pregnancy (positive beta-human chorionic gonadotropin test results), uterovaginal prolapse, and severe urinary symptoms, malignancy, or other serious concurrent condition (e.g., coagulative disorders, systemic disease, and severe cardiac disease). Pre-existing IUAs were considered an exclusion criteria because evaluation of re-formed IUAs was not the focus of the study.

Office diagnostic hysteroscopy was performed using a 5-mm-diameter continuous-flow hysteroscope with oval profile, a 30-degree fore-oblique telescope, and a 5F operating channel (Karl Storz GmbH & Co. KG, Tuttlingen, Germany). Saline solution was used as distention medium (0.9% NaCl), and was administered using an electronic system of irrigation/aspiration (Endomat; Karl Storz GmbH & Co. KG). A stable intrauterine pressure of approximately 40 mm Hg was obtained by setting the flow rate at 220 to 350 mL/min, negative pressure suction at 0.2 bar, and irrigation pressure at 100 mm Hg. No analgesic drugs or anesthesia was administered to the patients.

The type and characteristics of pathologic conditions and the patency of internal uterine ostium (Table 1) were thoroughly recorded on a dedicated form. After diagnostic hysteroscopy, patients were randomized via computer-generated randomization list into group 1 (treatment group: operative hysteroscopy plus intrauterine application of Intercoat gel; n = 55) and group 2 (control group: operative hysteroscopy alone; n = 55).

Operative hysteroscopy was performed using a rigid 27F resectoscope with a 30-degree fore-oblique telescope with various bipolar loops and a bipolar energy source (Versa-point; Gynecare, division of Ethicon, Inc.). Normal saline solution (0.9% NaCl) was used as the distention medium. The cervical canal was cautiously and progressively dilated using Hegar dilators before introduction of the resectoscope into the uterine cavity. Polyps were treated by positioning the loop behind the base of the pedicle and pushing from back to front. Depending on the size of the lesion being

Table 1

Classification of patency of internal uterine ostium	
Passage	Procedure
Easy	Hysteroscope passes through the cervix without difficulty
Moderately difficult	Slight cervical adhesions are present and are passed over using 1 of the following techniques: Blunt adhesiolysis with tip of hysteroscope Grasping forceps are inserted within fibrous tissue with jaws closed, then gently opened Scope is rotated 90 degrees on the endoscopic camera to align the main axis of the hysteroscope with the axis of the internal uterine ostium
Very difficult	Dense adhesions are present and are passed over using 1 of the following techniques: Scissors are gently inserted in the fibrous tissue, which is cut at 2 or 3 sites 5F bipolar electrodes are used to make 3 or 4 radial incisions at approximately 3-, 6-, 9-, and 12-o'clock positions on the internal uterine ostium

treated, 1 or several passages of the activated loop were necessary. Myomectomy was performed via resection of the free side of the myoma by moving the activated bipolar loop from back to front until normal myometrium was exposed. When the intramural part of the myoma was removed using the bipolar loop, particular care was used to avert any damage to the underlying myometrium. Metroplasty was performed using a modified 0-degree equatorial loop. Uterine septae were cut in the midline portion from the proximal part to the uterine fundus until a normal fundus shape was achieved. Endometrial ablation was performed by resecting progressively the posterior, anterior, and lateral uterine walls, preserving the isthmic portion, using a 90-degree bipolar loop. Then the fundus and tubal ostia were resected using a modified 0-degree equatorial loop.

After surgery, group 1 underwent intrauterine application of 10 mL Intercoat gel under hysteroscopic guidance through the inflow channel of the resectoscope while the operator gradually moved the resectoscope from the fundus of the uterus back to the external uterine ostium to apply the gel throughout the cavity and the cervical canal (Fig.1). The procedure was considered complete when under hysteroscopic visualization the gel seemed to have replaced all of the liquid medium and the cavity appeared completely filled by the gel from the tubal ostia to the external uterine orifice.

In group 2 (control), only hysteroscopic surgery was performed.

Patients in both groups underwent follow-up office hysteroscopy at 1 month after the surgical procedure (during the early proliferative phase of the following menstrual cycle), during which rate and severity were assessed. At 3 months after hysteroscopic surgery, the menstrual pattern was assessed in all patients. Intrauterine adhesions were defined as mild, moderate, or severe according to the American Fertility Society score (Table 2). In both groups, ease of passage through the cervical canal was assessed as previously described (Table I). Instrumentation and settings at follow-up hysteroscopy were the same as those used during hysteroscopy performed at enrollment.

Both the initial and follow-up diagnostic hysteroscopy were performed by the same surgeon (M.G.), who, blinded to patients' randomized allocation, also evaluated the rate and severity of adhesions in each patient. Operative hysteroscopy and application of the Intercoat gel were performed by another surgeon (A.D.S.S.). To prevent any bias related to the surgical treatment, the surgeon was informed of a patient's allocation immediately after surgical removal of the intrauterine lesion or after endometrial ablation.

Statistical Analysis

The primary outcome was measured by the incidence of de novo IUAs. On the basis of data previously published by our group [3,6], the incidence of adhesions at follow-up in

Fig. 1

The operator gradually moves the resectoscope from the fundus of the uterus back to the external uterine ostium to apply the gel throughout the cavity (A) and the cervical canal (B).

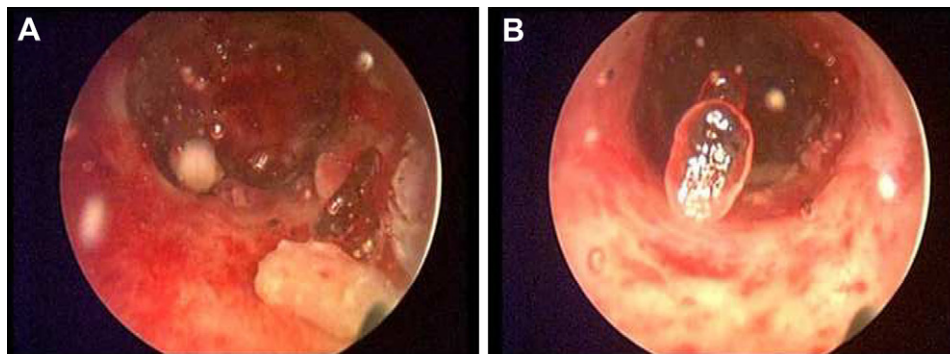


Table 2

Classification of intrauterine adhesions according to AFS guidelines [21]

Variable	Characteristic and AFS Classification		
Extent of cavity involvement	<1/3 1	<1/3 to 2/3 2	>2/3 4
Type of IUAs	Filmy 1	Filmy and dense 2	Dense 4
Menstrual pattern	Normal 0	Hypomenorrhea 2	Amenorrhea 4
Prognostic classification		HSG score ^a	Hysteroscopy score
Stage I, mild	1–4	AF	AF
Stage II, moderate	5–8	AF	AF
Stage III, severe	9–12	AF	AF

AF = additional findings; AFS = American Fertility Society; HSG = hysterosalpingography; IUA = intrauterine adhesion.

^a All adhesions should be considered dense.

patients undergoing hysteroscopic procedures with application of the gel was expected to be 10%, and without the gel to be 28%. These percentages are consistent with the current literature [1,3,6,7], which gives a mean incidence of IUAs of 25% after common resectoscopic procedures (polypectomy, myomectomy, and metroplasty) if adjusted by taking into account that the present study was meant to include more adhesiogenic procedures such as endometrial ablation. For the probability of a type 1 statistical error to be less than .05, it was calculated that a sample of 55 patients per group would provide 80% statistical power. Secondary outcome measures included severity of post-surgical IUAs and patency of the internal uterine ostium at 1-month follow-up hysteroscopy. However, no statistical power analysis was attempted for these latter variables.

Statistical analysis was performed using commercially available software (Statistica for Windows; StatSoft, Inc., Tulsa, OK). The intention-to-treat analytical method was used. Data distribution was performed using the Shapiro-Wilks test. Differences in age, weight, and parity, which exhibited a normal distribution, were compared using the *t* test for unpaired data. The χ^2 test was used to compare the rate and severity of IUAs and the degree of patency of the internal uterine ostium between groups before and after the intervention. Statistical significance was considered at *p* < .05.

Results

Of 26 patients who declined to participate, 8 declined after being explained the study protocol, and 18 were excluded because they were not willing to undergo surgery (Fig. 2). Characteristics of patients enrolled in the study are given in Table 3. At baseline, there were no significant differences in age, weight, uterine size, parity, and clinical symptoms between groups 1 and 2. In addition, there were no significant differences in size and type of lesions between the 2 groups and in the number of patients requiring endometrial ablation (Table 3). All submucous myomas were classified as grade 0, 1, or 2 according to the international classification of uterine myomas [33].

Intention-to-treat was the analysis method used; however, there were no deviations from random allocation. At 1-month follow-up, a significantly lower rate of post-surgical IUAs was observed in group 1 (3 of 55) compared with group 2 (12 of 55) (6% vs 22%; *p* < .05) (Table 4).

The severity of IUAs was lower in group 1 compared with group 2. In particular, the rate of moderate and severe IUAs was lower in group 1 (1 of 3) compared with group 2 (11 of 12) (33% vs 92%) (Table 5).

Patency of the internal uterine ostium was classified on the basis of difficulty of passage through the cervical canal (i.e., easy, moderately difficult, and difficult) (Fig. 3). At baseline hysteroscopy, in group 1, passage of the hysteroscope through the cervical canal was assessed as easy in 29 patients (53%), moderately difficult in 18 patients (32%), and difficult in 8 patients (15%). At follow-up hysteroscopy, passage was assessed as easy in 44 patients (80%), and moderately difficult in the remaining 11 patients (20%). In group 2, passage of the hysteroscope through the cervical canal was assessed as easy in 33 patients (60%), moderately difficult in 17 patients (31%), and difficult in 5

Fig. 2

Patient enrollment and randomized assignment. In group 1, patients underwent hysteroscopy plus application of Intercoat gel. In group 2, patients underwent hysteroscopy alone (control group).

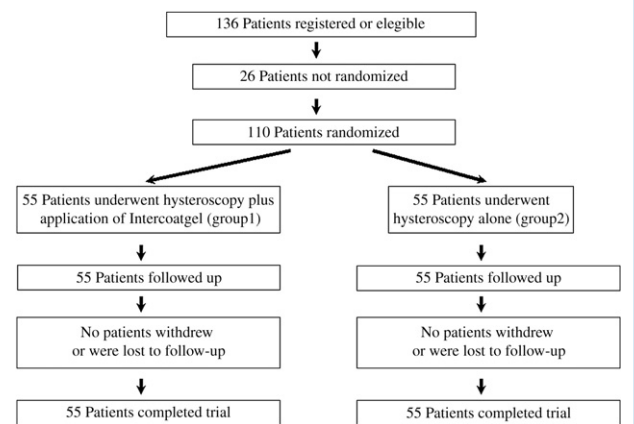


Table 3

Characteristics of enrolled patients ^{a,b}		
Variable	Group 1, ACP Gel (n = 55)	Group 2, Control (n = 55)
Age, yr	37 (3.1)	36 (2.9)
BMI	24.6 (2.8)	24.8 (2.7)
Uterine size at hysteroscopy, cm	7.4 (1.3)	7.3 (2.4)
Parity	1.5 (0.3)	1.6 (0.2)
Indication for hysteroscopy, No. of patients		
AUB	36	38
Infertility	7	5
AUB and infertility	5	4
Other	7	8
Lesion type, No.		
Polyp	22	20
Myoma	16	15
Grade 0	8	6
Grade 1	4	6
Grade 2	4	3
Lesion size, cm		
Polyp	3.2 (0.3)	3.1 (0.4)
Myoma	2.5 (0.4)	2.7 (0.5)
Septae, No.	6	7

AUB = abnormal uterine bleeding; BMI = body mass index; NS = not significant.
^a Unless otherwise indicated, data are given as mean (SD).
^b p = NS for all comparisons.

patients (9%). At follow-up hysteroscopy, passage was assessed as easy in 30 patients (55%), moderately difficult in 14 patients (25%), and difficult in 11 patients (20%).

Overall, compared with baseline, at follow-up hysteroscopy, improvement in the degree of patency of the internal uterine ostium was reported in 23 of 55 patients (41.9%) in group 1. Of these, moderately difficult passage in 15 patients and difficult passage in 8 became easier at follow-up hysteroscopy. In the other 31 patients (56%), no modification in patency of the internal uterine ostium occurred. In 1 patient (2.1%), worsening of patency of the internal uterine ostium was recorded (Fig. 3). In contrast, in group 2, worsening of patency of the internal uterine ostium was reported in 10

patients (18.2%). In the other 42 patients (76%), no patency of the internal uterine ostium occurred. In 3 patients (5.8%), improvement in patency of the internal uterine ostium was recorded (Fig. 3). Improvement in patency of the internal uterine ostium at follow-up hysteroscopy was significantly higher in group 1 (23 of 55) than in group 2 (3 of 55) (41.9% vs 5.8%; $p < .05$). In contrast, worsening of patency at follow-up hysteroscopy was significantly higher in group 2 (10 of 55) in comparison with group 1 (1 of 55) (18.2% vs 2.1%; $p < .05$). No adverse gel-related adverse effects were detected in group 1.

Discussion

Intrauterine adhesions were first described at the end of the 19th century by Heinrich Fritsch, who in 1894 reported IUAs in a patient with amenorrhea after postpartum curettage. In 1950, Joseph Asherman published data from the first large series of IUAs.

The most important causes of IUAs are previous trauma to the uterine cavity [34]. With damage to the basilar layer of the endometrium, granulation tissue on either side of the endometrial cavity can fuse, forming tissue bridges [35–37]. Approximately 90% of severe IUAs are related to curettage performed because of complications of pregnancy [34]; however, adhesions can develop in the non-gravid uterus as a result of endometrial injury from procedures such as operative hysteroscopy [1–3]. Similar to the basalis layer of the endometrium, the endocervical mucosa is also susceptible to iatrogenic damage, the inflammatory response causing bridging connecting the anterior and posterior cervical walls. Adhesions that partially or completely obstruct the internal uterine ostium may result in variable narrowing of the cervical canal.

In clinical practice, we have observed worsening of patency of the internal uterine ostium after operative hysteroscopy, probably related to trauma to the cervical tissue during progressive dilation using Hegar probes that necessarily precedes introduction of a standard 27F resectoscope into the uterine cavity. Other factors that influence development of cervical stenosis include postmenopausal status [38,39], nulliparity [40], and cervical surgery [38,41]. Currently, cervical stenosis is a troublesome clinical

Table 4

Incidence of adhesion formation (at 1 months follow up) in different hysteroscopic procedure subgroups				
Hysteroscopic procedure	Group 1 (n = 55)		Group 2 (n = 55)	
	All patients	No. patients (%) with adhesions at follow-up	All patients	No. patients (%) with adhesions at follow-up
All surgeries	55	3 (5.45)	55	12 (21.81)
Myomectomy	16	1 (1.81)	15	3 (5.45)
Polypectomy	22	0 (0.0)	20	0 (0.0)
Metroplasty	6	0 (0.0)	7	3 (5.45)
Endometrial ablation	11	2 (3.63)	13	6 (10.9)

Table 5

Severity of post-surgery intrauterine adhesions		
Severity	Group 1	Group 2
Mild	2 (1 myomectomy, 1 endometrial ablation)	1 (1 metroplasty)
Moderate	1 (endometrial ablation)	8 (2 myomectomy, 4 endometrial ablation, 2 metroplasty)
Severe	0	3 (1 myomectomy, 2 endometrial ablation)
Total	3	12

problem and is the main cause of failure of office hysteroscopy [42,43].

Strategies for prevention of post-surgical IUAs include a wide variety of adjuvant pharmacologic agents including antibiotics [25], gonadotropin-releasing hormone analogues [1], and estrogenic agents [26]. A new category of adhesion prevention methods is barrier systems that maintain opposing uterine walls apart, averting formation of fibrin bridges and subsequent adhesion formation [3,6,34,44]. Such systems include intrauterine insertion of a Foley catheter or an intrauterine device [27–29, 45], as well as synthetic and natural polymer barriers [46–53].

In 2003, Acunzo et al [6] described the introduction of auto-cross-linked hyaluronic acid (ACP) gel into the uterine cavity at the end of the hysteroscopic surgery, demonstrating that the intrauterine application of ACP gel after hysteroscopic adhesiolysis significantly reduces re-formation of postoperative IUAs. In a further randomized controlled study, Guida et al [3] demonstrated that ACP also significantly reduces both the incidence and severity of de novo formation of IUAs after resectoscopic removal of myomas, polyps, and septae.

One of the most recently developed products is the Intercoat absorbable adhesion barrier gel (Gynecare, division of Ethicon, Inc.), a clear single-use flowable gel that is a sterile

absorbable combination of polyethylene oxide and sodium carboxymethylcellulose. Manufactured as a thin sheet, it was proved effective in a rabbit laparoscopy model [31], and in human beings, it reduces epidural fibrosis and radiculopathy after lumbar surgery [54,55]. The antiadhesive effect of Intercoat is believed to be a consequence of its barrier effect, keeping the traumatized surfaces separated for a sufficient duration [32].

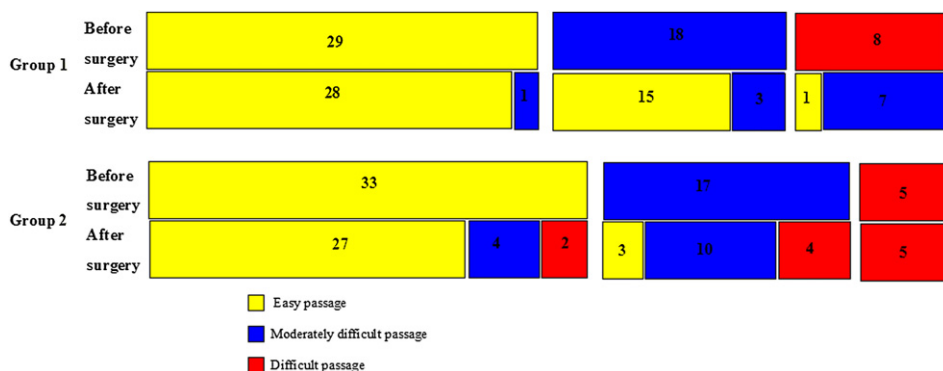
Currently, few studies in the literature have evaluated the efficacy of Intercoat gel in prevention of adhesions in gynecologic laparoscopic and open surgery [56]. However, to our knowledge, no study has investigated the role of Intercoat gel in preventing post-surgical IUAs and obstruction of the internal uterine ostium. The latter issue seems to be of particular interest because it may result in failure of follow-up office hysteroscopy after resectoscopic surgery.

Our randomized controlled trial demonstrated a significant reduction in de novo IUAs in patients treated with intrauterine application of Intercoat gel after hysteroscopic surgery in comparison with patients treated with hysteroscopic surgery alone. In both groups, the incidence of de novo IUAs was slightly lower than expected. This may be explained by increased surgical experience and use of a modern bipolar resectoscope with lower power settings.

Between the 2 groups, a trend in different severity of adhesions was observed. However, because of the small number of cases included, this trend did not reach statistical significance. Because of the paucity of samples, the rate and severity of adhesions was not assessed within individual pathologic subgroups in the presence or absence of Intercoat gel because of loss of statistical power. However, clinical experience and previous studies report that a higher frequency of postoperative adhesions is frequently observed after endometrial ablation resectoscopic myomectomy and metroplasty but not endometrial polypectomy [20]. Our data are consistent with both the current literature and clinical experience, which report a lower incidence of IUAs after polypectomy compared with other procedures including metroplasty, myomectomy, and endometrial ablation (Table 3).

Fig. 3

Graphic representation of degree of difficulty in passage of the hysteroscope through the internal uterine ostium (IUO) at baseline and at follow-up hysteroscopy in groups 1 and 2.



The present study has demonstrated a significant improvement in the degree of patency of the internal uterine ostium at follow-up hysteroscopy in patients treated with intrauterine application of Intercoat gel after hysteroscopic surgery. In contrast, in the control group, significant worsening of patency was recorded in 18.2% of cases. This positive effect of Intercoat gel may be due to the particular technique used to apply the gel in the uterine cavity: the operator gradually moved the resectoscope from the fundus of the uterus to the external uterine ostium to apply the gel throughout the cervical canal. A potential shortcoming of Intercoat gel may be due to incomplete or patchy application of the gel, leaving some parts of the uterine walls without the protective film.

Previous studies that evaluated the efficacy of another viscoelastic gel to prevent post-surgical IUAs reported that the gel should be applied in the uterine cavity but not in the cervix [3,19]. The efficacy of our technique has been confirmed by ultrasonographic data that demonstrate that Intercoat gel was able to keep both uterine and cervical walls separated for at least 24 hours (data not shown).

According to our previous protocol, intention to treat was the chosen analytical method, although strictly speaking, the present study was an explanatory investigation rather than a pragmatic trial for effectiveness. No deviation from random allocation and no dropouts occurred, probably because of short interval before follow-up. The choice to schedule follow-up hysteroscopy at only 1 month was made because the adhesiogenic process starts immediately after endometrial injury, and at 2 to 4 weeks after surgery, IUAs can be evaluated at diagnostic hysteroscopy [57]. In addition, early hysteroscopy provides the opportunity to perform adhesiolysis, if needed, when post-surgical IUAs are still thin and soft [57]. Conversely, IUAs discovered at late hysteroscopy are thicker, more organized, and fibrous [57]. This progression of development over time is well documented in the surgical literature [57–59].

Furthermore, early follow-up hysteroscopy may influence the mechanism of adhesiogenesis after hysteroscopic surgery [57]. For this reason, we decided to not schedule patients for a second late hysteroscopy because the rate and severity of IUAs may have been biased by the earlier surgery. The lack of late follow-up hysteroscopy and the small sample size may be a limitation of this study, and more multicenter trials will be needed to confirm our observations.

No adverse effects occurred in group 1. Intercoat gel and other reabsorbable solid or semisolid barriers seem to be safe, which is not surprising because they are based on natural products. In the few available previous trials, no device-related adverse effects have been reported [31,54,55].

Conclusions

Although not definitive, the present data demonstrate that Intercoat gel seems to prevent de novo formation of intrauterine adhesions and also to improve patency of the internal uterine ostium at follow-up hysteroscopy. This new absorb-

able barrier agent could represent a safe and effective strategy to improve women's health, reducing the need for repeat intervention after hysteroscopic surgery because of postoperative IUA formation and decreasing the failure rate of office hysteroscopy. However, these results need to be confirmed in larger controlled, randomized, multicenter studies.

References

1. Taskin O, Sadik S, Onoglu A, Gokdeniz R, Erturan E, Burak F, Wheeler JM. Role of endometrial suppression on the frequency of intrauterine adhesions after resectoscopic surgery. *J Am Assoc Gynecol Laparosc.* 2000;7:351–354.
2. Diamond MP, Daniell JF, Feste J, Surrey MV, McLaughlin DS, Friedmann S, Vaughn WK, Martin DC. Adhesion reformation and de novo adhesion formation after reproductive pelvic surgery. *Fertil Steril.* 1987;47:864–866.
3. Guida M, Acunzo G, Di Spiezio Sardo A, Bifulco G, Piccoli R, Pellicano M, Cerrota G, Cirillo D, Nappi C. Effectiveness of auto-cross-linked hyaluronic acid gel in the prevention of intrauterine adhesions after hysteroscopic adhesiolysis: a prospective randomized, controlled study. *Hum Reprod.* 2004;19:1461–1464.
4. Al-Inany H. Intrauterine adhesions. *Acta Obstet Gynecol Scand.* 2001;80:986–993.
5. Touboul C, Fernandez H, Deffieux X, Berry R, Frydman R, Gervaise A. Uterine synechiae after bipolar hysteroscopic resection of submucosal myomas in patients with infertility. *Fertil Steril.* 2009;92:1690–1693.
6. Acunzo G, Guida M, Pellicano M, Tommaselli GA, Di Spiezio Sardo A, Bifulco G, Cirillo D, Taylor A, Nappi C. Effectiveness of auto-cross-linked hyaluronic acid gel in the prevention of intrauterine adhesions after hysteroscopic adhesiolysis: a prospective randomized, controlled study. *Hum Reprod.* 2003;18:1918–1921.
7. Liakakos T, Thomakos N, Fine PM, Dervenis C, Young RL. Peritoneal adhesions: etiology, pathophysiology, and clinical significance. *Dig Surg.* 2001;18:260–273.
8. Donnez J, Nisolle M. Hysteroscopic lysis of intrauterine adhesions (Asherman's syndrome). In: Donnez J, editor. *Atlas of Laser Operative Laparoscopy and Hysteroscopy.* London, England: Parthenon Publishers; 1994. p. 305–322.
9. Valle RF, Sciarra JJ. Intrauterine adhesions: hysteroscopic diagnosis, classification, treatment, and reproductive outcome. *Am J Obstet Gynecol.* 1988;158:1459–1470.
10. American Fertility Society. The American Fertility Society classifications of adnexal adhesions, distal tubal occlusion, tubal occlusion secondary to tubal ligation, tubal pregnancies, mullerian anomalies and intrauterine adhesions. *Fertil Steril.* 1988;49:944–955.
11. Asherman JG. Amenorrhea traumatica (atretica). *J Obstet Gynaecol Br Emp.* 1948;55:23–27.
12. Asherman JG. Traumatic intrauterine adhesions. *Br J Obstet Gynaecol.* 1950;57:892–896.
13. Yu D, Wong YM, Cheong Y, Xia E, Li TC. Asherman syndrome: one century later. *Fertil Steril.* 2008;89:759–779.
14. Berman JM. Intrauterine adhesions. *Semin Reprod Med.* 2008;26349–26355.
15. Salzani A, Yela DA, Gabiatti JR, Bedone AJ, Monteiro IM. Prevalence of uterine synechiae after abortion evacuation curettage. *Sao Paulo Med J.* 2007;125:261–264.
16. Deans R, Abbott J. Review of intrauterine adhesions. *J Minim Invasive Gynecol.* 2010;17:555–569.
17. March CM. Asherman's syndrome. *Semin Reprod Med.* 2011;29:83–94.
18. Menzies D. Postoperative adhesions: their treatment and relevance in clinical practice. *Ann R Col Surg.* 1993;75:147–153.
19. Chen FP, Soong YK, Hui YL. Successful treatment of severe uterine synechiae with transcervical resectoscopy combined with laminaria tent. *Hum Reprod.* 1997;12:943–947.

20. Di Spiezio Sardo A, Mazzoni I, Bramante S, Bettocchi S, Bifulco G, Guida M, Nappi C. Hysteroscopic myomectomy: a comprehensive review of surgical techniques. *Hum Reprod Update*. 2008;14:101–119.
21. Nappi C, Di Spiezio Sardo A, Greco E, Guida M, Bettocchi S, Bifulco G. Prevention of adhesions in gynaecological endoscopy [published online ahead of print April 23, 2007]. *Hum Reprod Update*. 2007;13:379–394.
22. Risberg B. Adhesions: preventive strategies. *Eur J Surg Suppl*. 1997;577:32–39.
23. Farquhar C, Vandekerckhove P, Watson A, Vail A, Wiseman D. Barrier agents for preventing adhesions after surgery for subfertility. *Cochrane Database Syst Rev*. 2000;(2):CD000475.
24. Watson A, Vandekerckhove P, Lilford R. Liquid and fluid agents for preventing adhesions after surgery for infertility. *Cochrane Database Syst Rev*. 2000;(2):CD001298.
25. Shenker JG. Etiology of and therapeutic approach to synechiae uteri. *Eur J Obstet Gynecol Reprod Biol*. 1996;65:109–113.
26. Roge P, D'Ercole C, Cravello L, Boublil L, Blanc B. Hysteroscopic management of uterine synechiae: a series of 102 observations. *Eur J Obstet Gynecol Reprod Biol*. 1996;65:189–193.
27. Cominos AC, Zourlas PA. Treatment of uterine adhesions (Asherman's syndrome). *Am J Obstet Gynecol*. 1969;105:862–865.
28. Pabuccu R, Atay V, Orhon E, Urman B, Ergun A. Hysteroscopic treatment of intrauterine adhesions is safe and effective in the restoration of normal menstruation and fertility. *Fertil Steril*. 1997;68:1141–1143.
29. Orhue AAE, Aziken ME, Igbehof JO. A comparison of two adjunctive treatments for intrauterine adhesions following lysis. *Int J Gynecol Obstet*. 2003;82:49–56.
30. Schonman R, Corona R, Bastidas A, De Cicco C, Mailova K, Koninckx PR. Intercoat gel (Oxiplex): efficacy, safety, and tissue response in a laparoscopic mouse model. *J Minim Invasive Gynecol*. 2009;16:188–194.
31. Rodgers KE, Schwartz HE, Roda N, Thornton M, Kobak W, diZerega GS. Effect of Oxiplex* films (PEO/CMC) on adhesion formation and reformation in rabbit models and on peritoneal infection in a rat model. *Fertil Steril*. 2000;73:831–838.
32. Lundorff P, Donnez J, Korell M, Audebert AJ, Block K, diZerega GS. Clinical evaluation of a viscoelastic gel for reduction of adhesions following gynecological surgery by laparoscopy in Europe. *Hum Reprod*. 2005;20:514–520.
33. Wamsteker K, Emanuel MH, de Kruijf JH. Transcervical hysteroscopic resection of submucous fibroids for abnormal uterine bleeding: results regarding the degree of intramural extension. *Obstet Gynecol*. 1993;82:736–740.
34. De Iaco PA, Muzzupapa G, Bovicelli A, Marconi S, Bitti SR, Sansovini M, Bovicelli L. Hyaluronan derivative gel (hyalobarrier gel) in intrauterine adhesion (IUA) prevention after operative hysteroscopy. *Ellipse*. 2003;19:15–18.
35. Hellebrekers BW, Trimbos-Kemper TC, Trimbos JB, Emeis JJ, Kooistra T. Use of fibrinolytic agents in the prevention of postoperative adhesion formation. *Fertil Steril*. 2000;74:203–212.
36. Robinson J, Swedarsky Colimon LM, Isaacson KB. Postoperative adhesiolysis therapy for intrauterine adhesions (Asherman's syndrome) [published online ahead of print June 20, 2008]. *Fertil Steril*. 2008;90:409–414.
37. Panayotidis C, Weyers S, Bosteels J, van Herendaal B. Intrauterine adhesions (IUA): has there been progress in understanding and treatment over the last 20 years? *Gynecol Surg*. 2009;6:197–211.
38. Suh-Burgmann E, Whall-Strojwas D, Chang Y, Hundley D, Goodman A. Risk factors for cervical stenosis after loop electrocautery excision procedure. *Obstet Gynecol*. 2000;96:657–660.
39. Bettocchi S, Pansini N, Porreca MR, Selvaggi L. Anatomic impediments to the performance of hysteroscopy. *J Am Assoc Gynecol Laparosc*. 1996;3(4 suppl):S4.
40. Litta P, Bonora M, Pozzan C, Mrlin F, Sacco G, Fracas M, Capobianco G, Dessole S. Carbon dioxide versus normal saline in outpatient hysteroscopy. *Hum Reprod*. 2003;18:2446–2449.
41. Baldauf JJ, Dreyfus M, Ritter J, Meyer P, Philippe E. Risk of cervical stenosis after large loop excision or laser conization. *Obstet Gynecol*. 1996;88:933–938.
42. Cicinelli E, Parisi C, Galantino P, Pinto V, Barba B, Schonauer S. Reliability, feasibility, and safety of minihysteroscopy with a vaginoscopic approach: experience with 6,000 cases. *Fertil Steril*. 2003;80:199–202.
43. De Angelis Carlo, Perrone G, Santoro G, Nofroni I, Zichella L. Suppression of pelvic pain during hysteroscopy with a transcutaneous electrical nerve stimulation device. *Fertil Steril*. 2003;79:1422–1427.
44. Abbott J, Thomson A, Vancaillie T. SprayGel following surgery for Asherman's syndrome may improve pregnancy outcome. *J Obstet Gynaecol*. 2004;24:710–711.
45. Thomson AJ, Abbott JA, Deans R, Kingston A, Vancaillie TG. The management of intrauterine synechiae. *Curr Opin Obstet Gynecol*. 2009;21:335–341.
46. DeWilde RL, Trew G, on behalf of the Expert Adhesions Working Party of the European Society of Gynaecological Endoscopy (ESGE). Post-operative abdominal adhesions and their prevention in gynecological surgery. Expert consensus position. Part 2: steps to reduce adhesions. *Gynecol Surg*. 2007;4:243–253.
47. Diamond MP, Seprafilm Adhesion Study Group. Reduction of adhesions after uterine myomectomy by Seprafilm membrane (HAL-F): a blinded, prospective, randomized, multicenter clinical study. *Fertil Steril*. 1996;66:904.
48. Brown CB, Luciano AA, Martin D. Adept (icodextrin 4% solution) reduces adhesions after laparoscopic surgery for adhesiolysis: a double-blind, randomized, controlled study. *Fertil Steril*. 2007;88:1413.
49. Dunn R, Lyman MD, Edelman PG. Evaluation of the SprayGel adhesion barrier in the rat cecum abrasion and rabbit uterine horn adhesion models. *Fertil Steril*. 2001;75:411.
50. Frey C, Chanelles O, Poncelet C. How to prevent postoperative intrauterine adhesions? *Gynecol Obstet Fertil*. 2010;38:550–552.
51. Revaux A, Ducarme G, Luton D. Prevention of intrauterine adhesions after hysteroscopic surgery. *Gynecol Obstet Fertil*. 2008;36:311–317.
52. Ducarme G, Davitian C, Zarrouk S, Uzan M, Poncelet C. Interest of auto-cross-linked hyaluronic acid gel in the prevention of intrauterine adhesions after hysteroscopic surgery: a case-control study. *J Gynecol Obstet Biol Reprod*. 2006;35:691–695.
53. Tsapanos VS, Stathopoulou LP, Papathanassopoulou VS, Tzingounis VA. The role of Seprafilm bioresorbable membrane in the prevention and therapy of endometrial synechiae. *J Biomed Mater Res*. 2002;63:10–14.
54. Rodgers KE, Robertson JT, Espinoza T. Reduction of epidural fibrosis in lumbar surgery with Oxiplex adhesion barriers of carboxymethylcellulose and polyethylene oxide. *Spine J*. 2003;3:277–283.
55. Kim KD, Wang JC, Robertson DP. Reduction of radiculopathy and pain with Oxiplex/SP gel after laminectomy, laminotomy, and discectomy: a pilot clinical study. *Spine*. 2003;28:1080–1087.
56. Young P, Johns C, Templeman C, Witz C, Webster B, Ferland R, Diamond MP, Block K, diZerega G. Reduction of postoperative adhesions after laparoscopic gynecological surgery with Oxiplex/AP gel: a pilot study. *Fertil Steril*. 2005;84:1450.
57. Shokeir TA, Fawzy M, Tatongy M. The nature of intrauterine adhesions following reproductive hysteroscopic surgery as determined by early and late follow-up hysteroscopy: clinical implications. *Arch Gynecol Obstet*. 2008;277:423–427.
58. Bradley JM, Michael LB, Montz FJ. Adhesions after extensive gynecologic surgery: clinical significance, etiology, and prevention. *Am J Obstet Gynecol*. 1994;170:1396–1403.
59. Chapman R, Chapman K. The value of two stage laser treatment for severe Asherman's syndrome. *Br J Obstet Gynecol*. 1996;103:1256–1258.