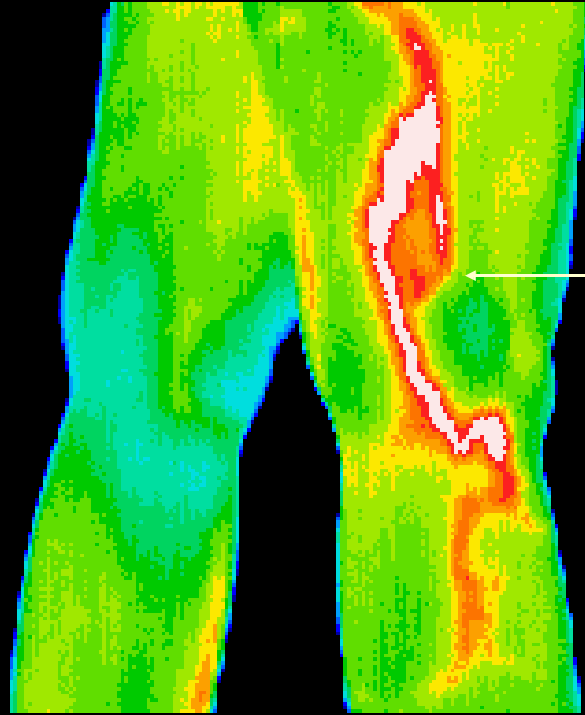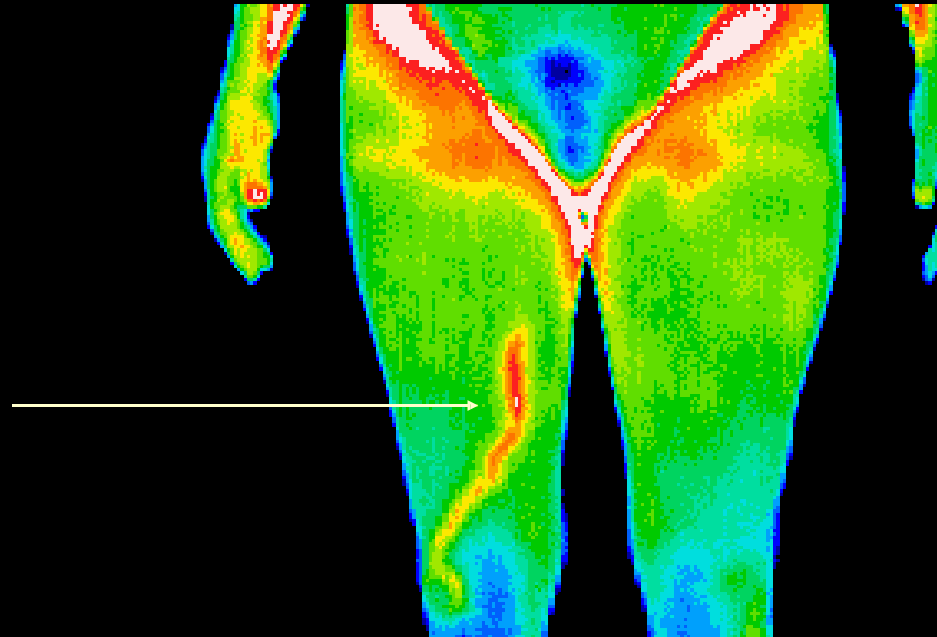
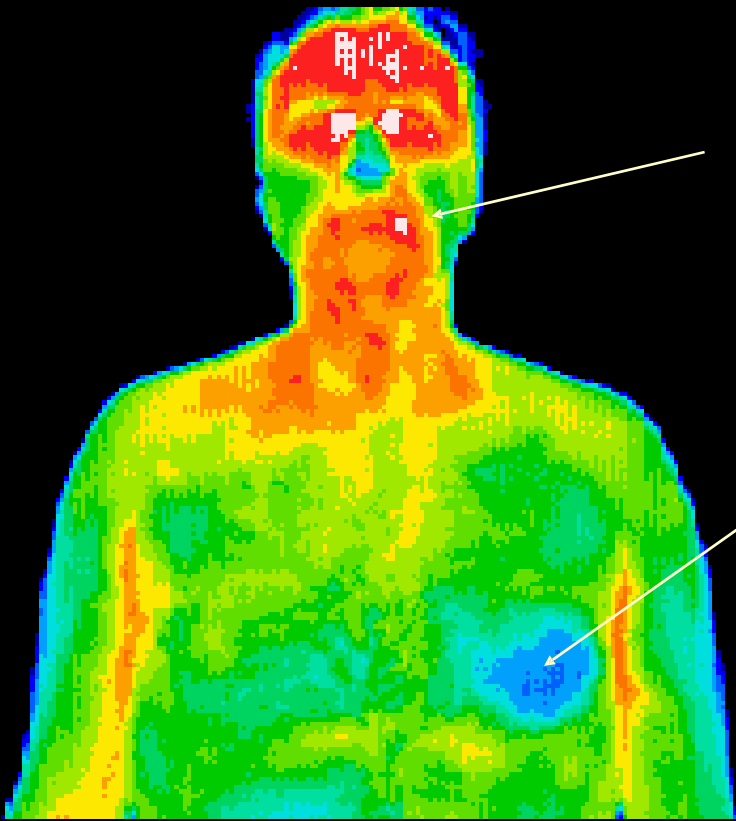


Phlebitis

Varicosity (an enlarged and tortuous vein, artery, or lymphatic vessel) with perforator (Perforator veins are so called because they perforate the deep fascia of muscle, to connect the superficial veins to the deep veins where they drain.)

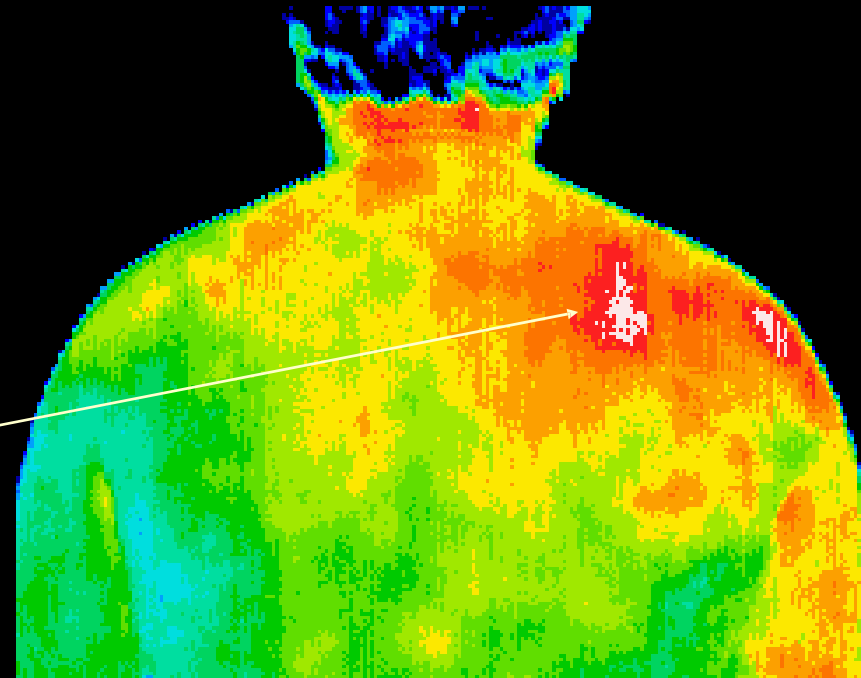


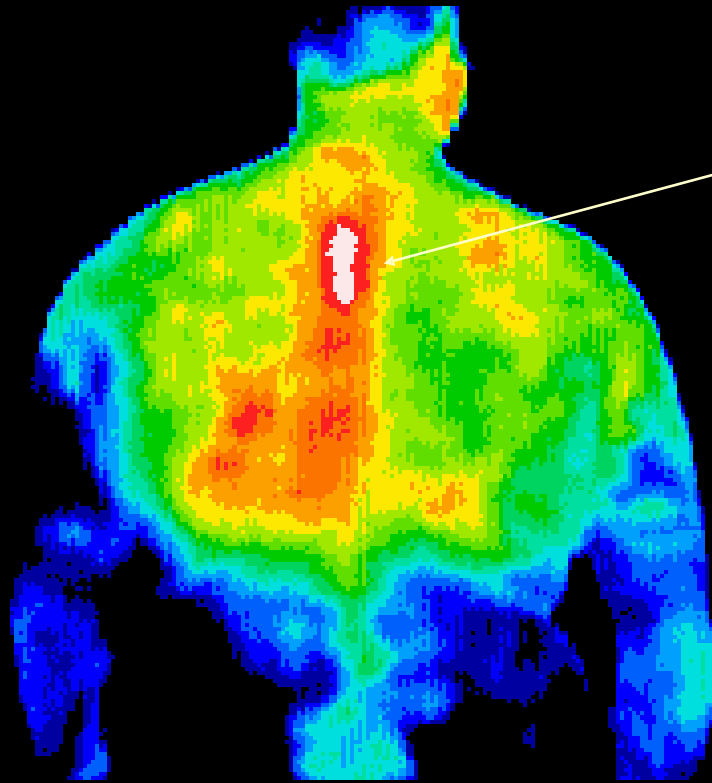


Local dental infection

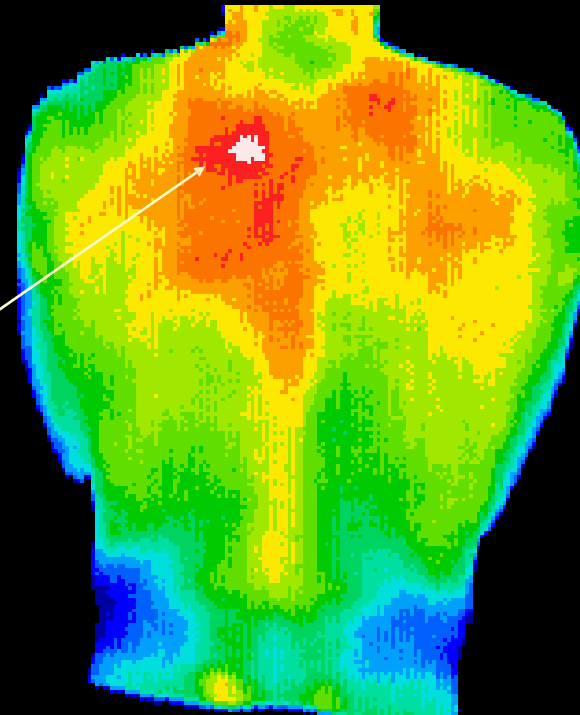
Autonomic pattern relating to
Coronary Artery Disease

Muscular inflammation
infraspinatus and deltoid

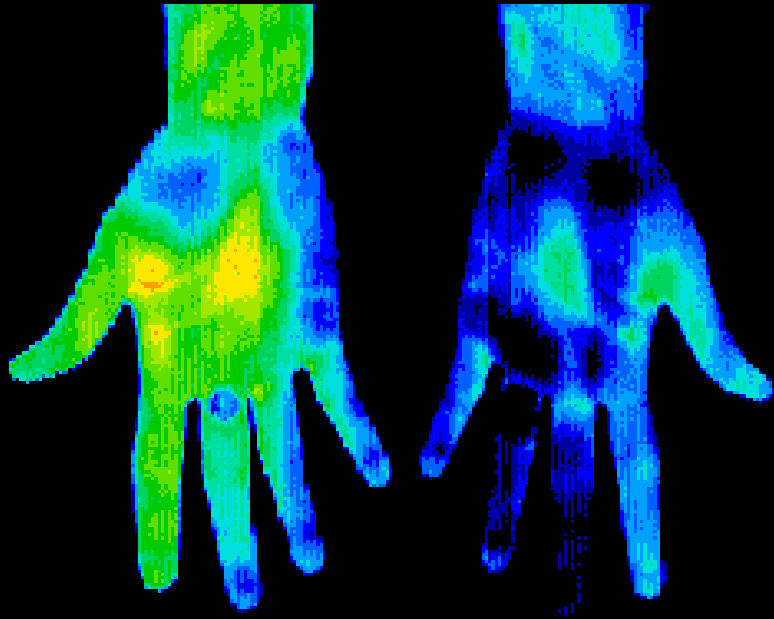




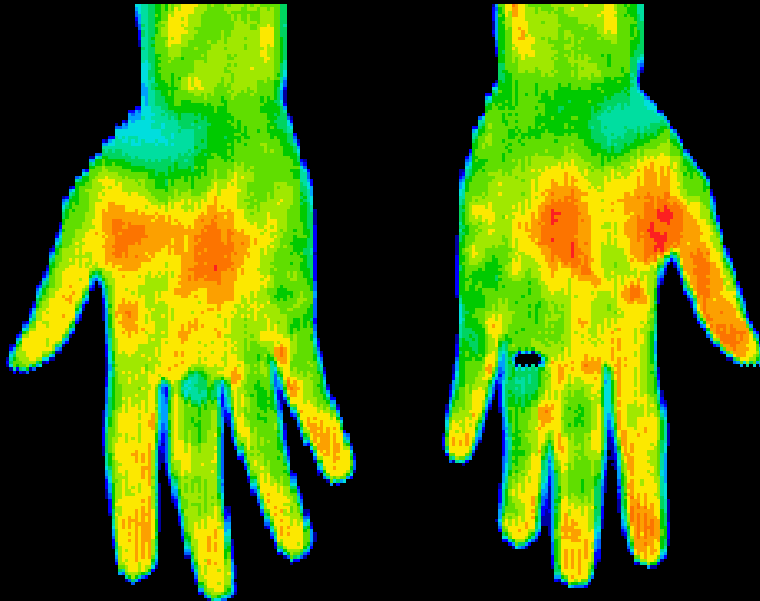
T4 Syndrome



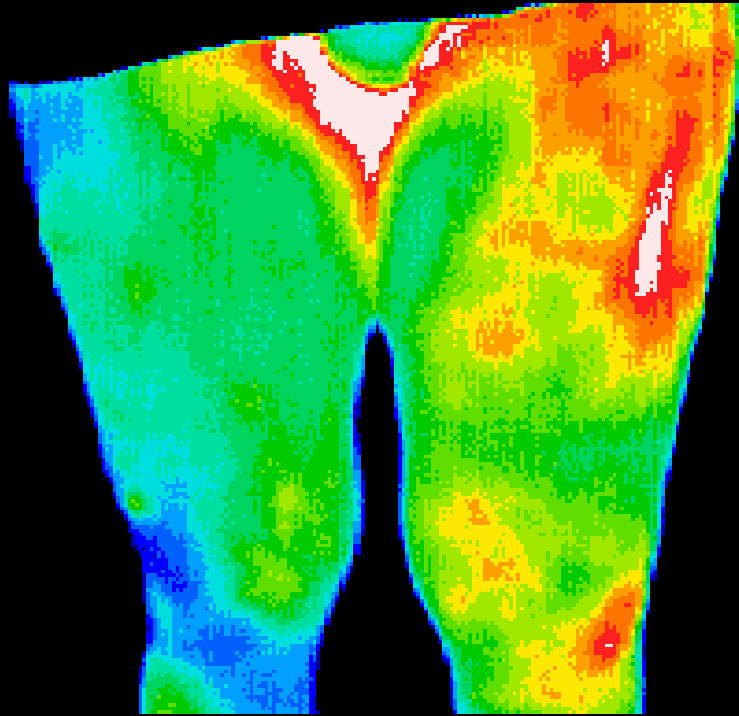
Myofascial trigger point over upper rhomboid (minimus)



RSD/CRPS (Reflex Sympathetic Dystrophy/Complex Regional Pain Syndrome) of the left hand. Glove-like hypothermia.

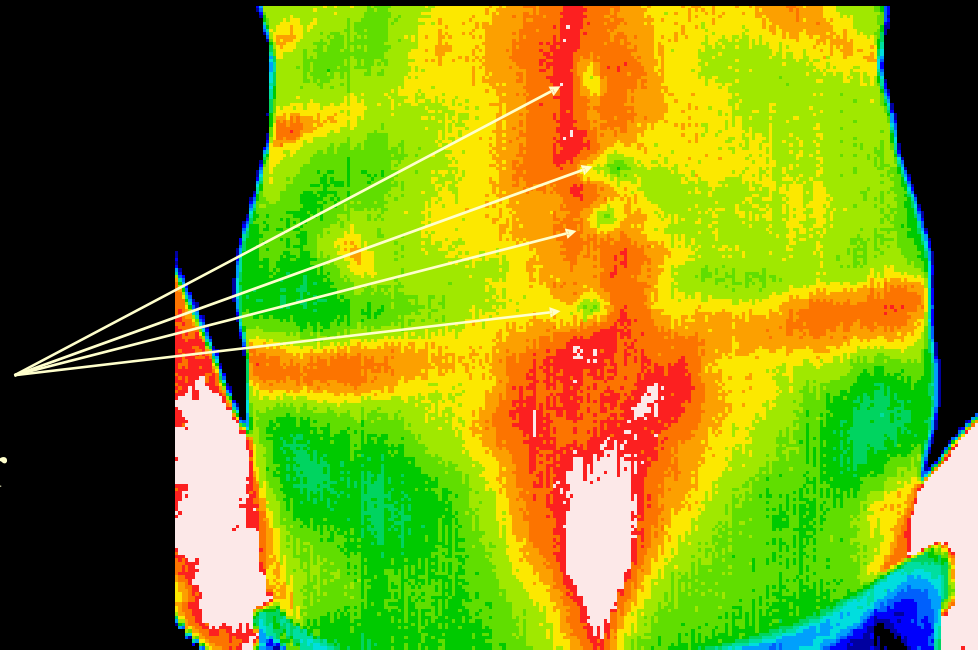


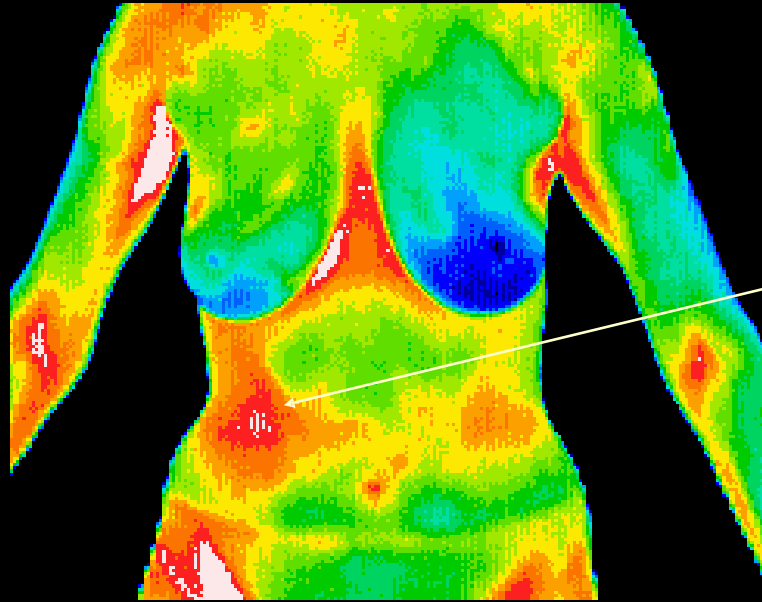
The return of normal sympathetic function after treatment was short term.



This elderly lady had undergone a left hip replacement surgery 3 months previously and her continued leg pain raised a suspicion for DVT. The thermographic findings were not consistent with DVT (Deep Vein Thrombosis), but showed a focal area of inflammation that guided a sonographer to a deep abscess near the bone. This was lanced and successfully treated with antibiotics.

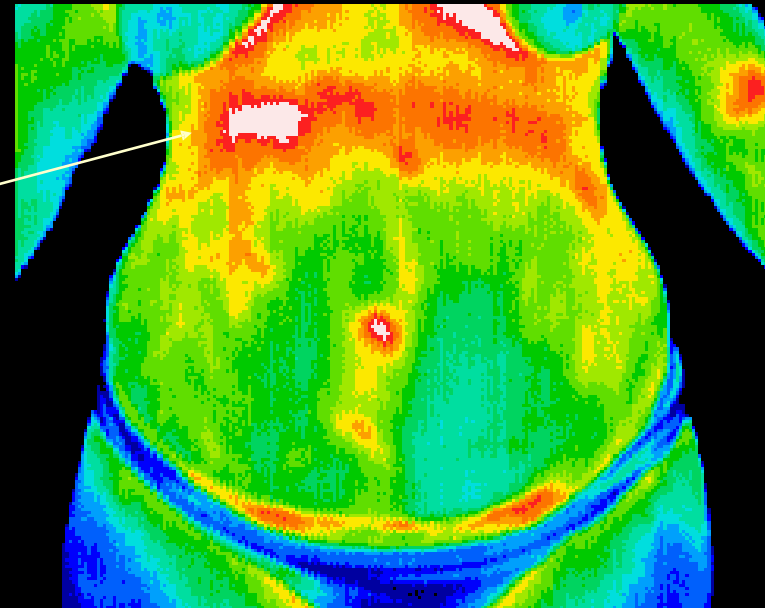
Small metastatic tumors indicated by focal areas of hypothermia over the lumbar spine

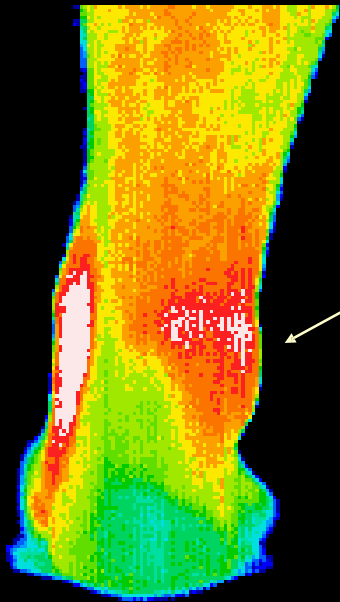
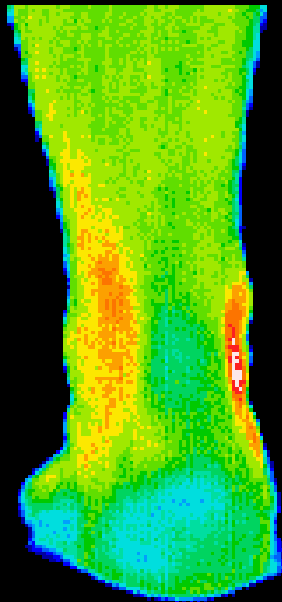





The primary finding here is the local area of hyperthermia over the hepatic flexure of the colon. Diverticulitis was diagnosed after clinical correlation with thermographic findings.

This patient presented with low back pain, there were no thermal findings in the back but the abdomen showed a well defined area of inflammation over the right kidney which could refer pain to the back. Subsequent tests confirmed a kidney infection.

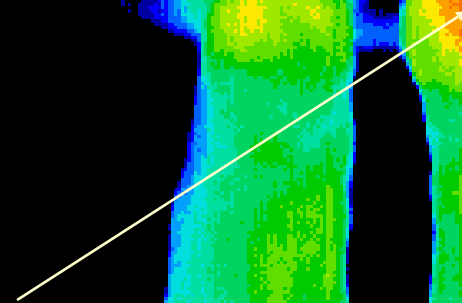
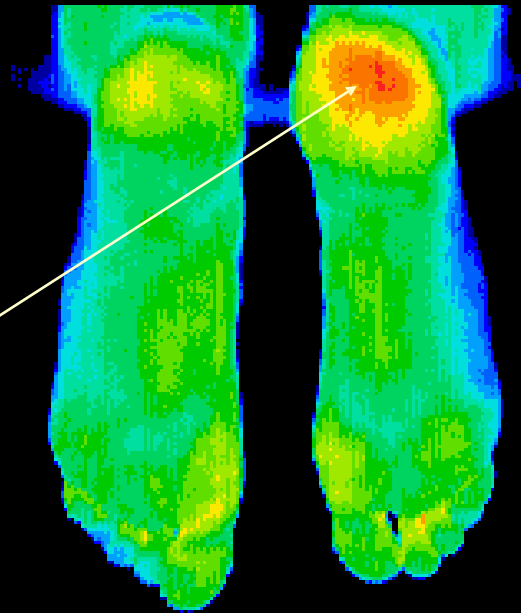


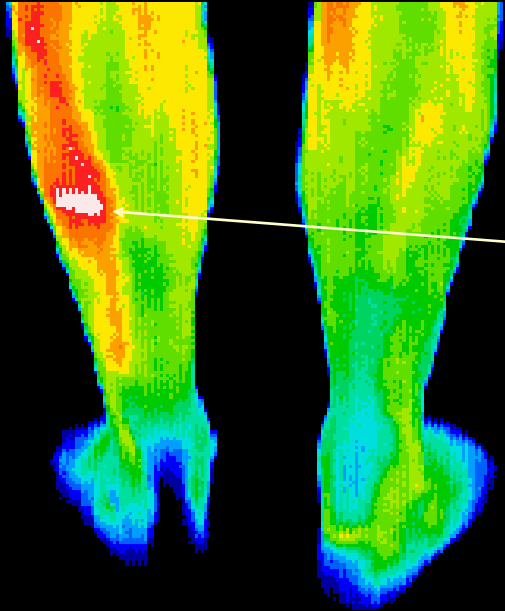


Sprained ankle

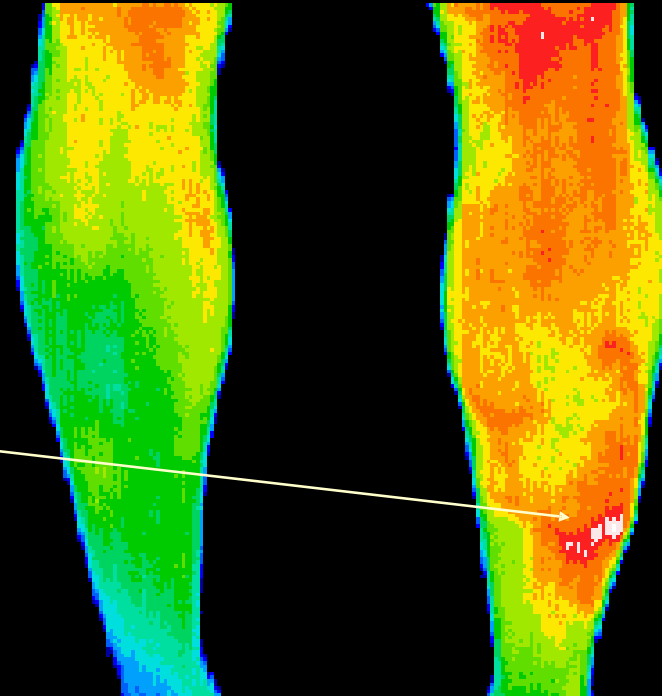


Inflammation from heel spur

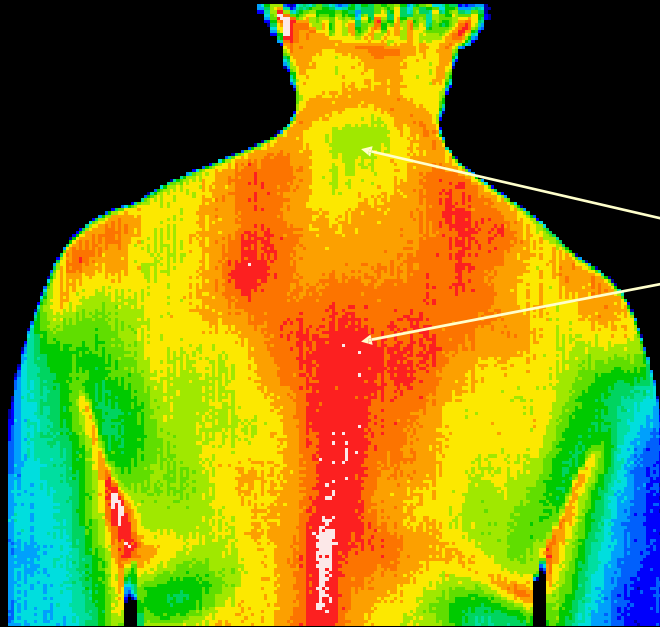




Football player with stress fracture,
confirmed with scintigraphy (diagnostic test in nuclear medicine where radioisotopes attached to drugs that travel to a specific organ or tissue are taken internally and the emitted radiation is captured by external detectors)

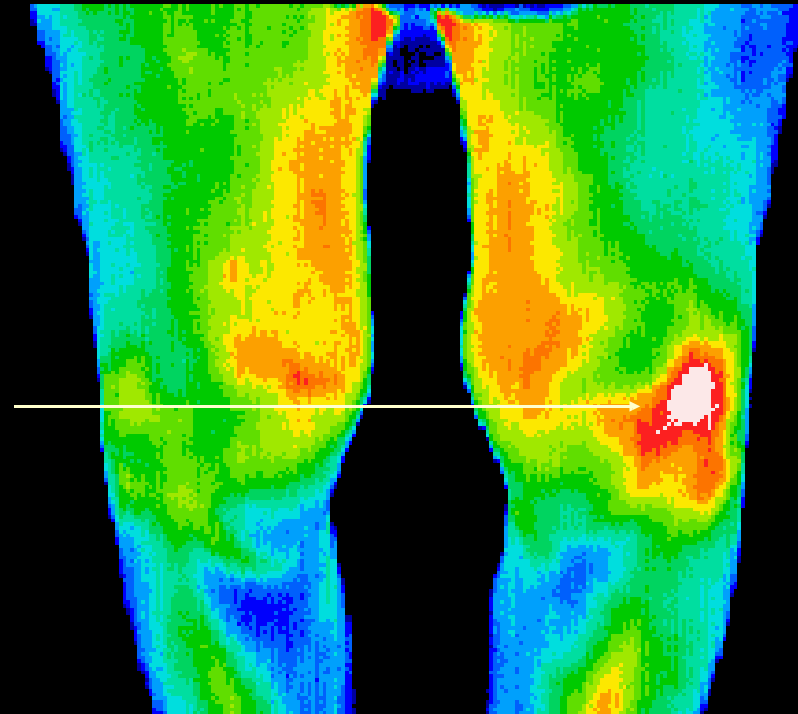


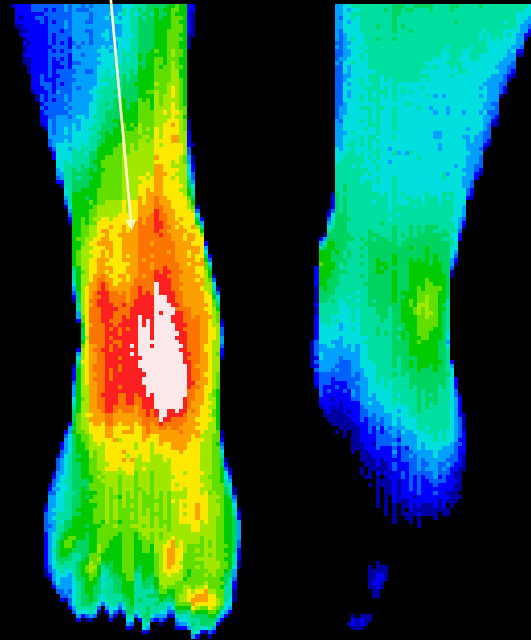
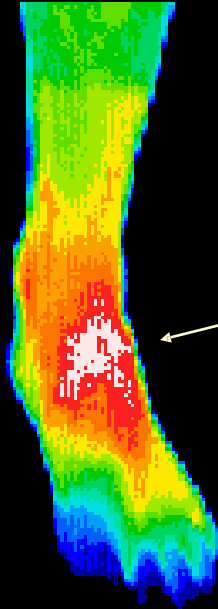
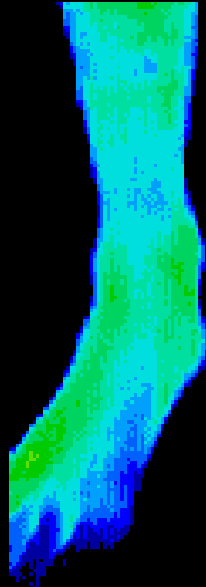
Similar injury in a right leg





Muscular inflammation over trapezius, hypothermia over T2 consistent with fibromyalgia.

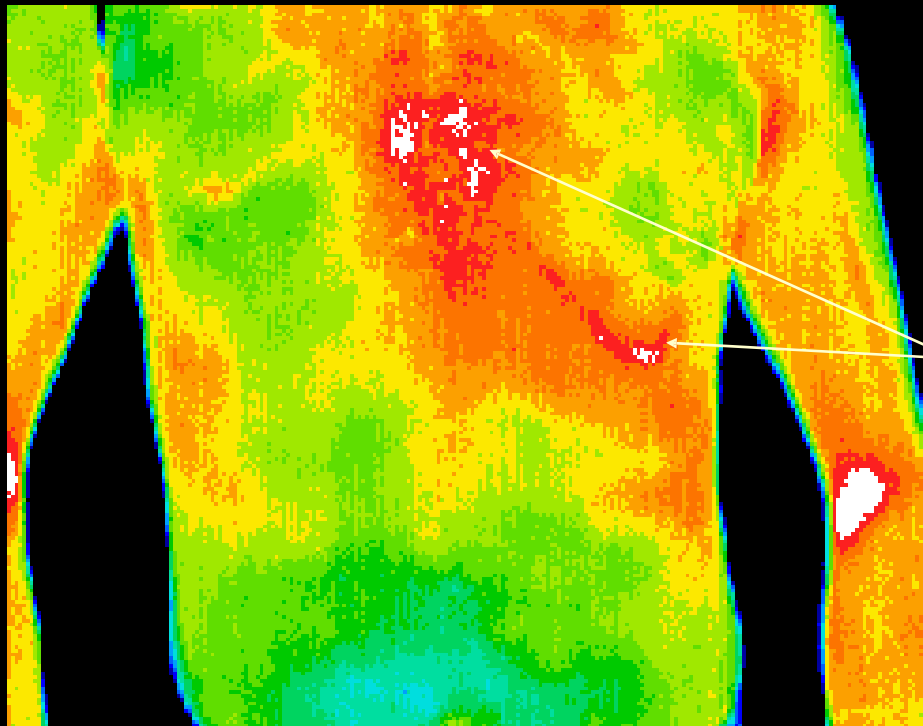
Local inflammation from osteoarthritis





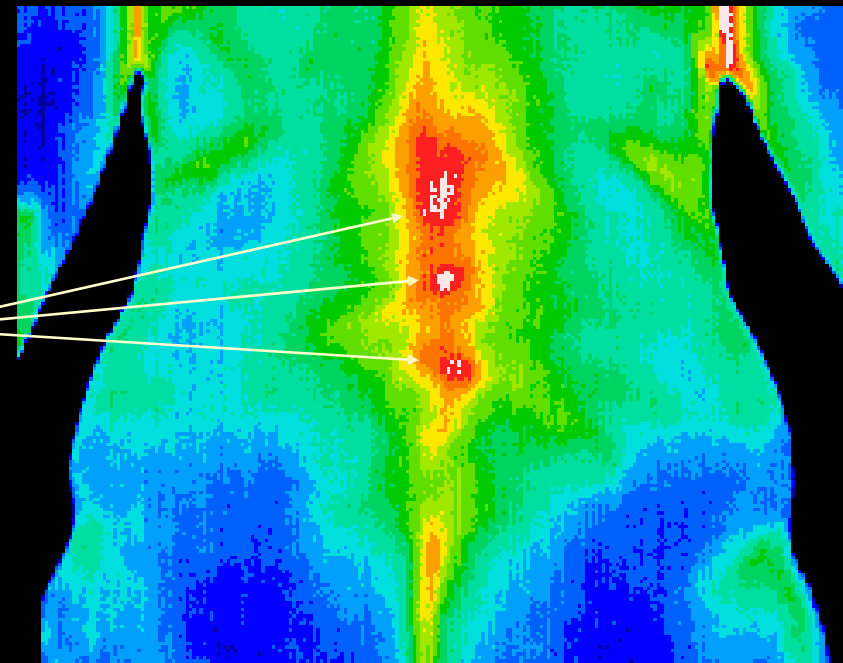
Ankle sprains



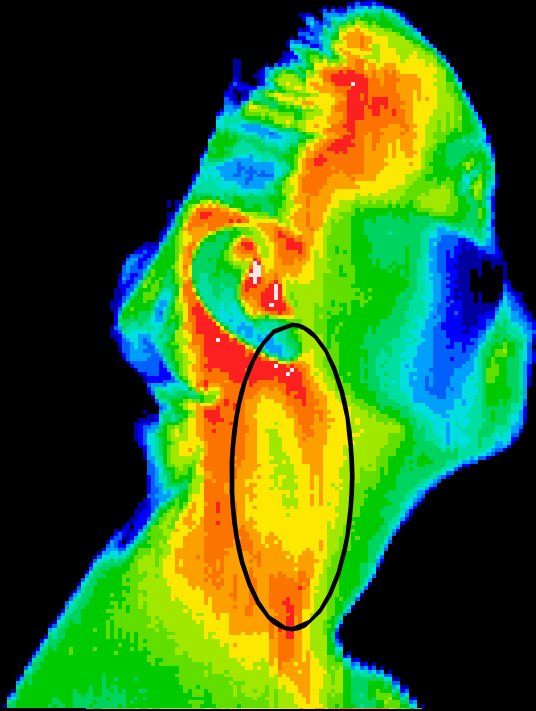


Steering wheel impacted the low chest, subsequent x-ray as a result of thermal findings showed fractures in the low sternum and left last rib.

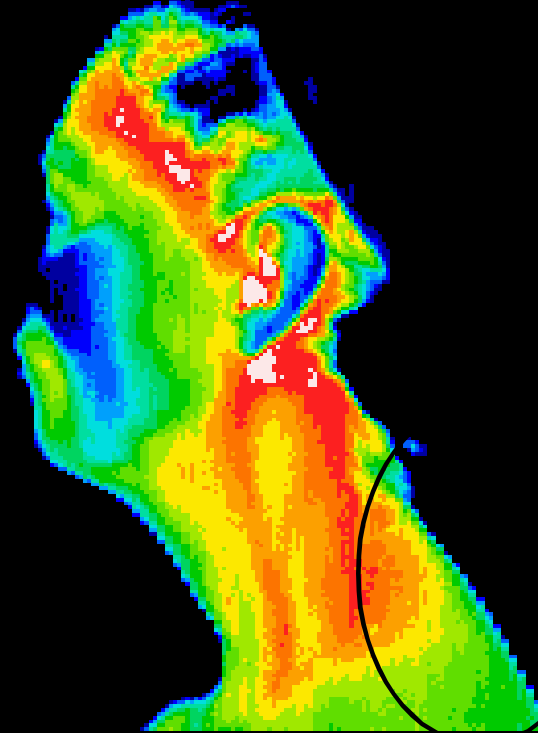
Local inflammation over lumbar joint spaces .



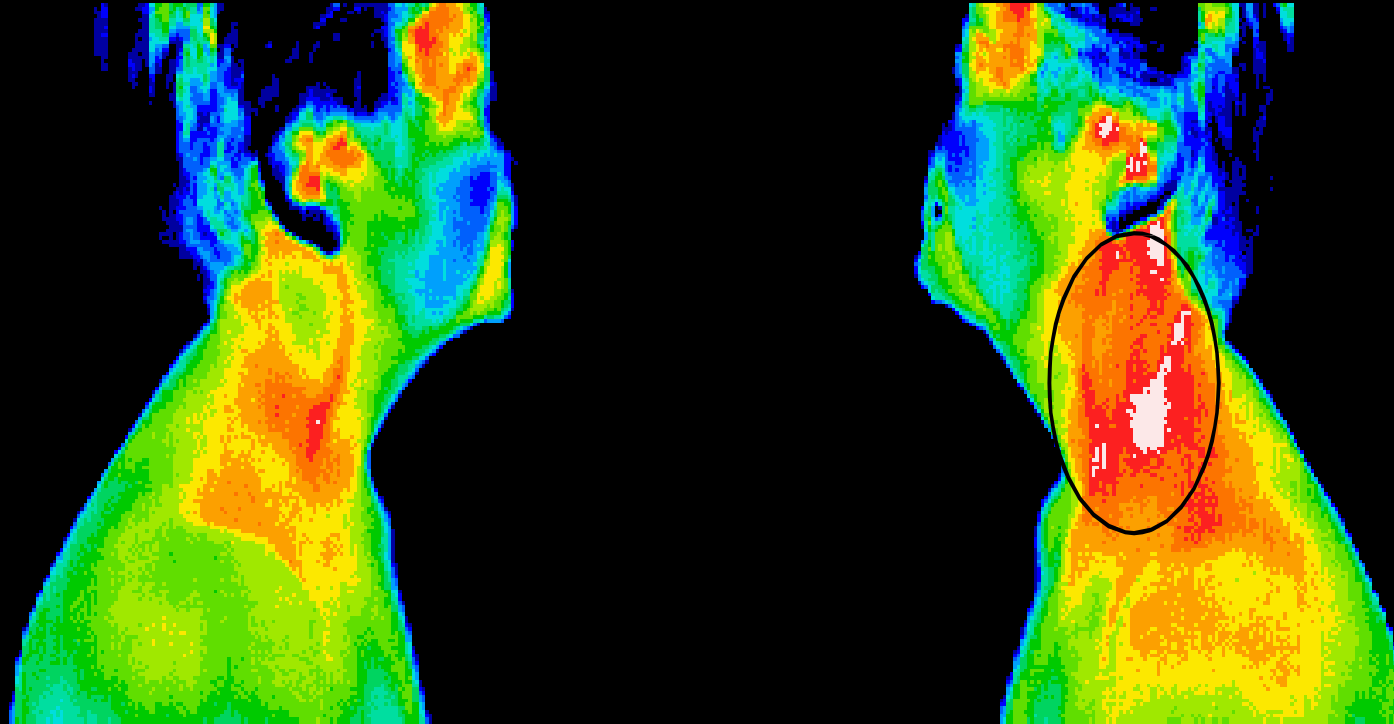
MEDITHERM



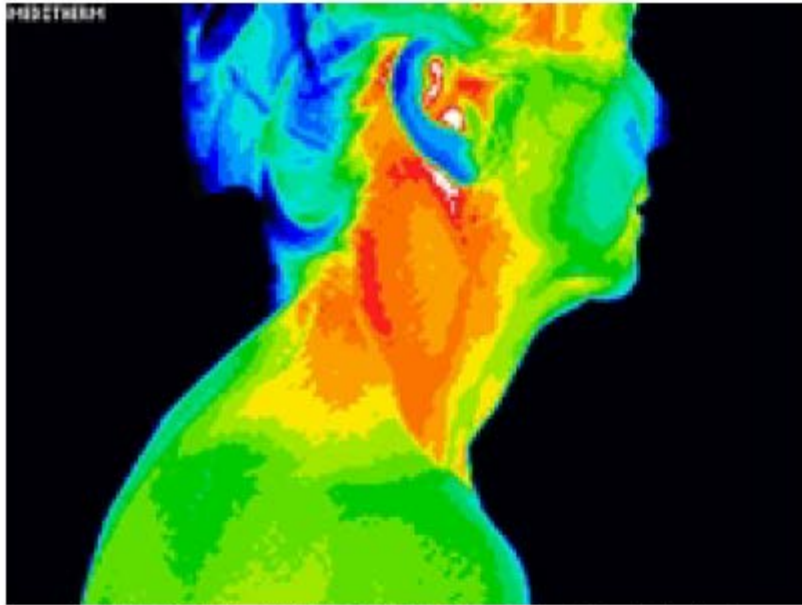
MEDITHERM



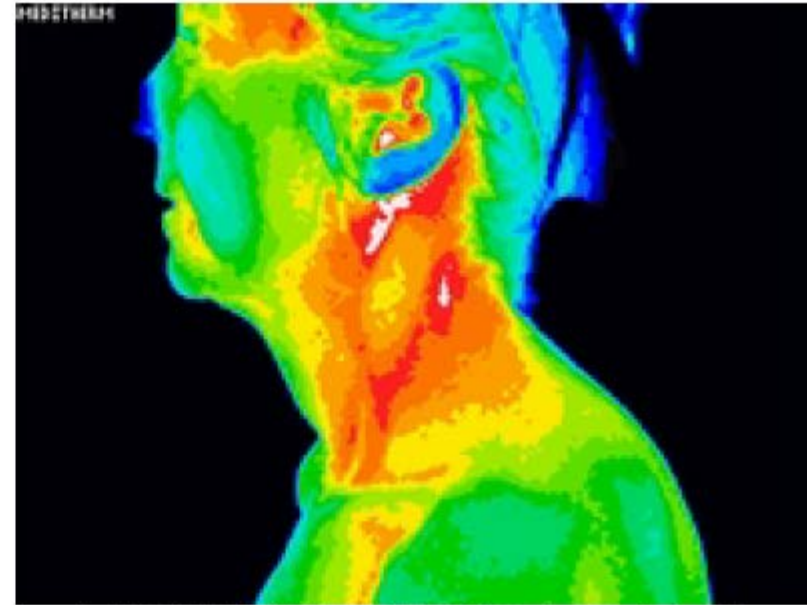
Patient with elevated C-Reactive Protein, an early risk indication for heart disease



Patient with an advanced infection in mitral valve, detected with Thermal Imaging



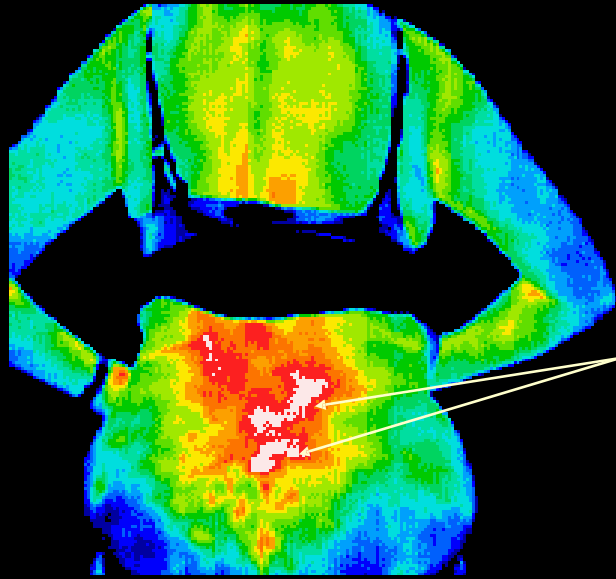
LAI SHE.TIF2016.04.24 09.41.19



LAI SHE.TIF2016.04.24 09.41.43

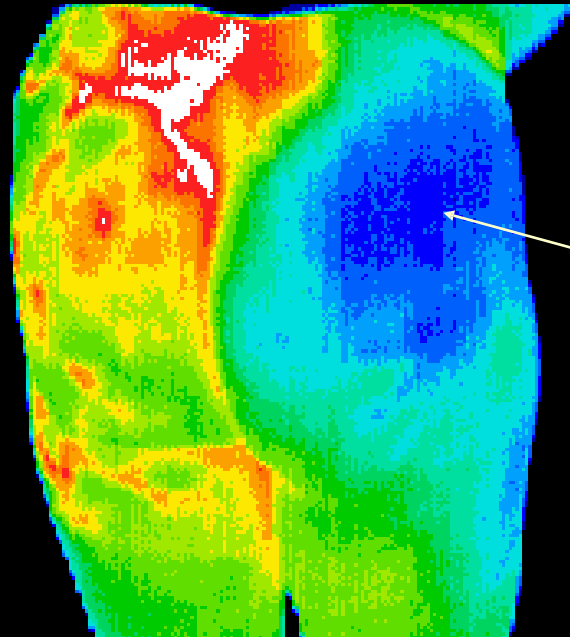
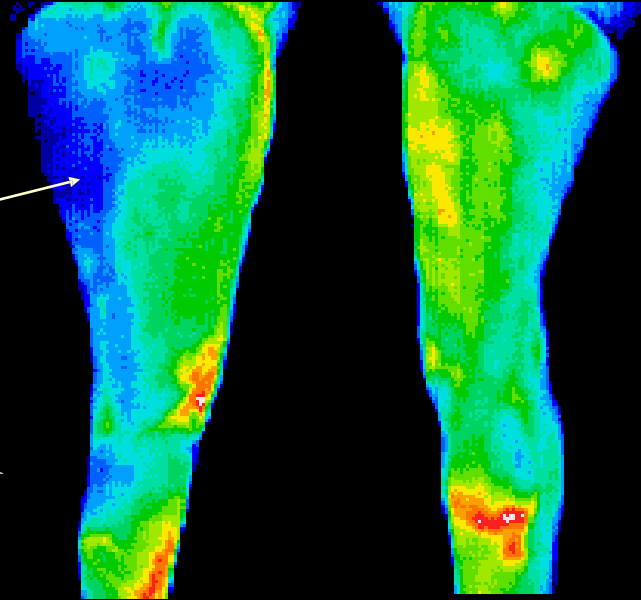
Some accentuation of the carotids is evident suggestive of a degree of systemic inflammation/elevated CRP levels.

Follow up: Suggest clinical correlation of thermal findings with patient's history and symptoms.



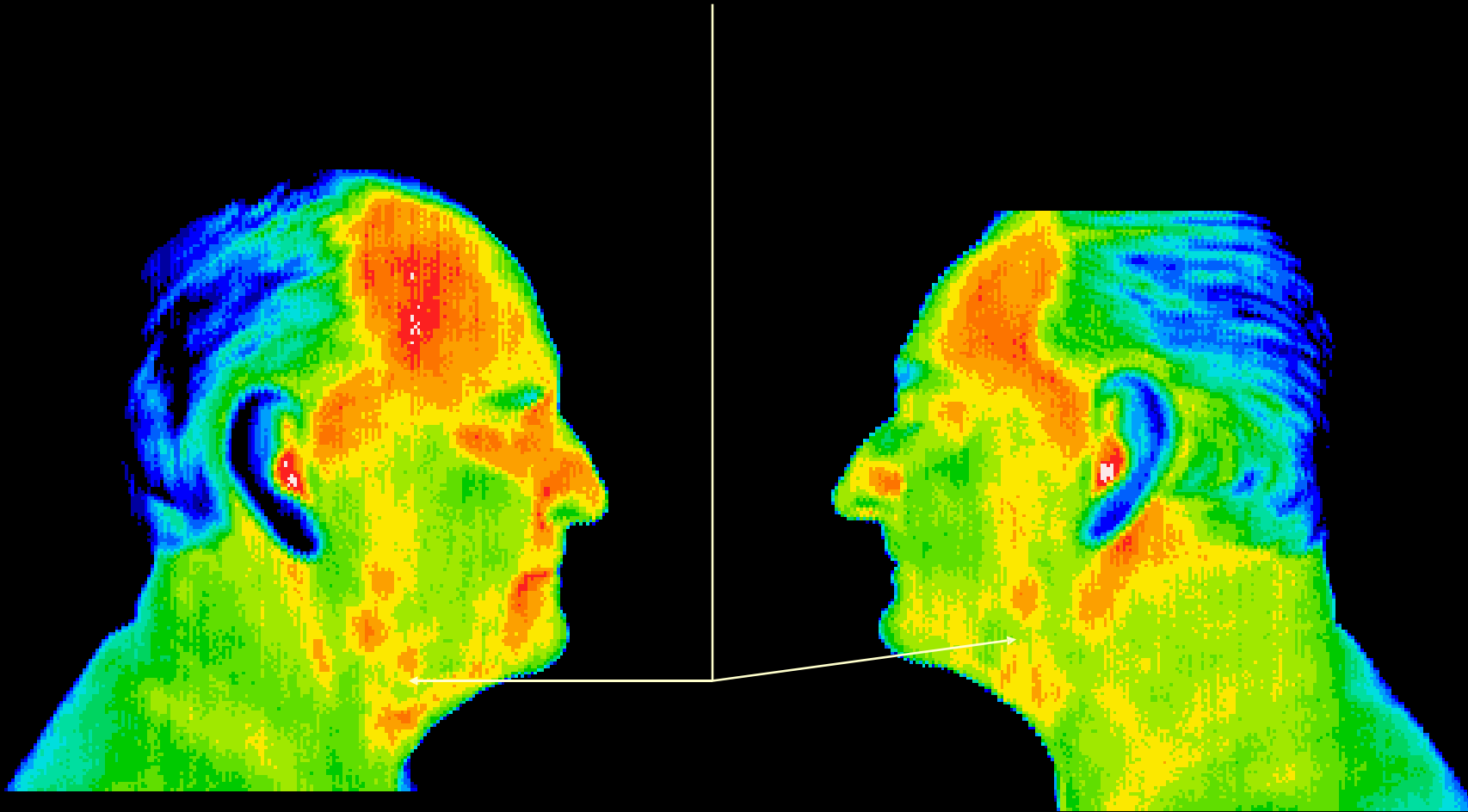
Right side L3 L4

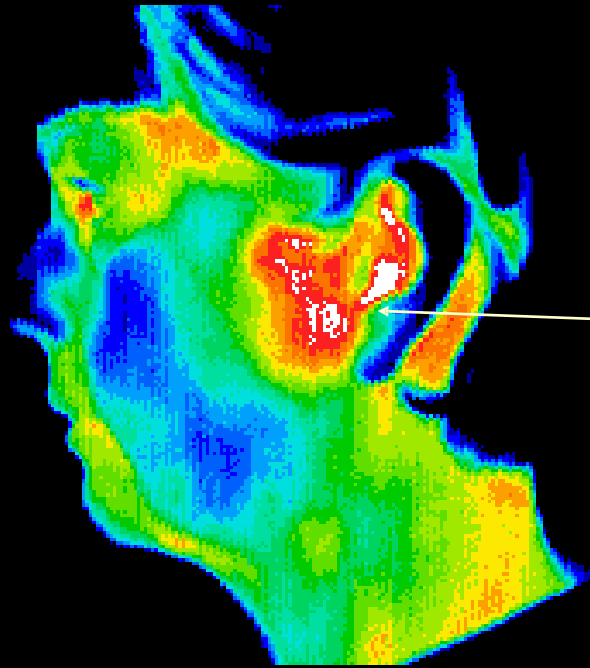
Radiculopathy
(disorder of the spinal
nerve roots)



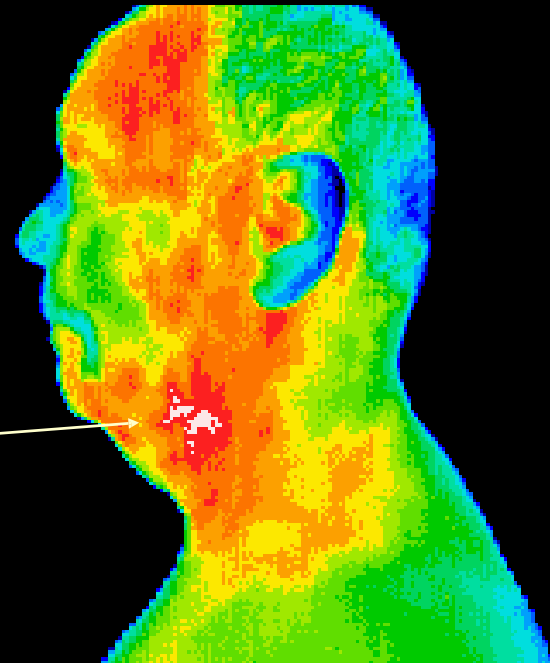
RSD of the right hip. RSD
(Reflex Sympathetic
Dystrophy) is the feeling of
pain associated with
evidence of minor nerve
injury.

Increased lymph node activity in the right digastric triangle

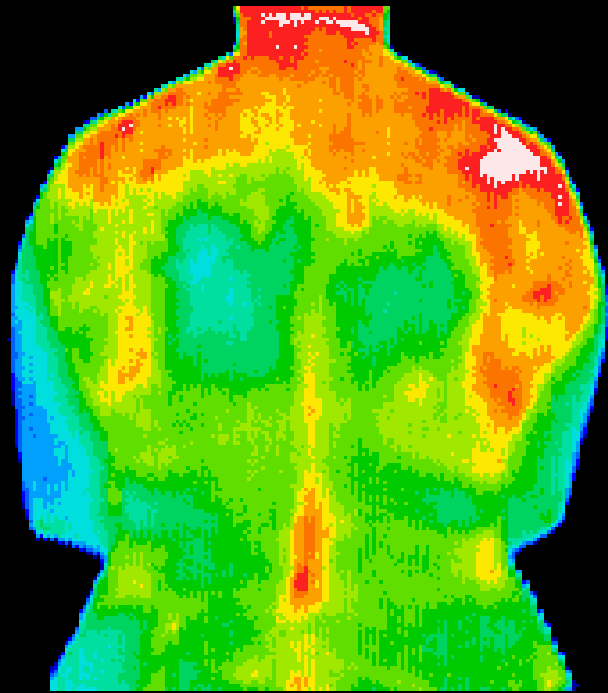




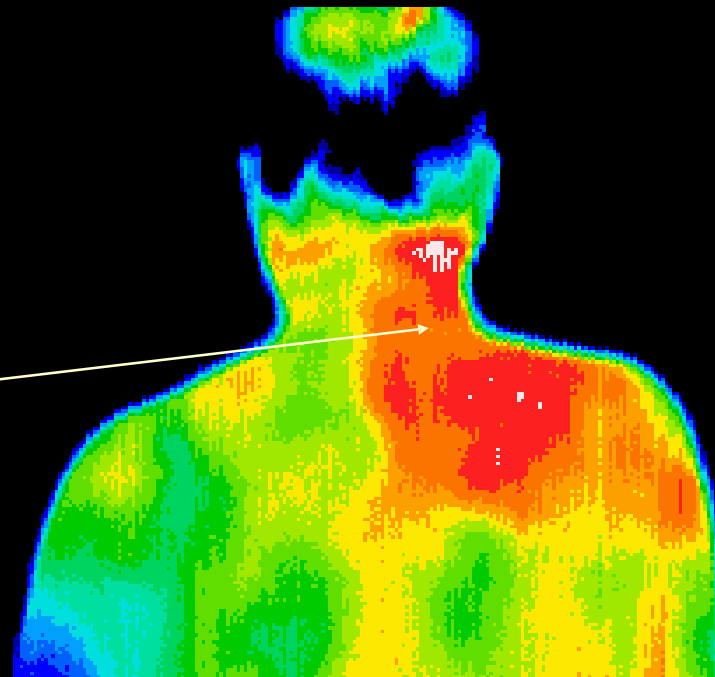
TMJ



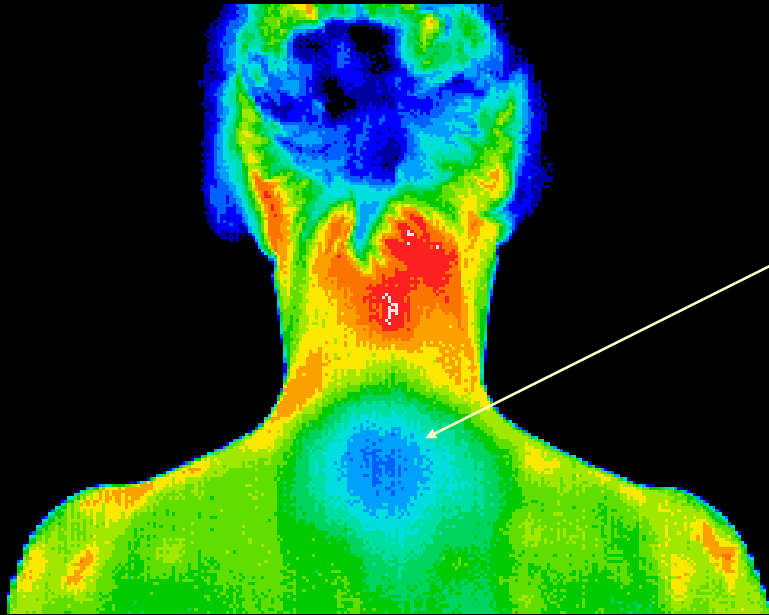
Digastric inflammation



Frozen shoulder

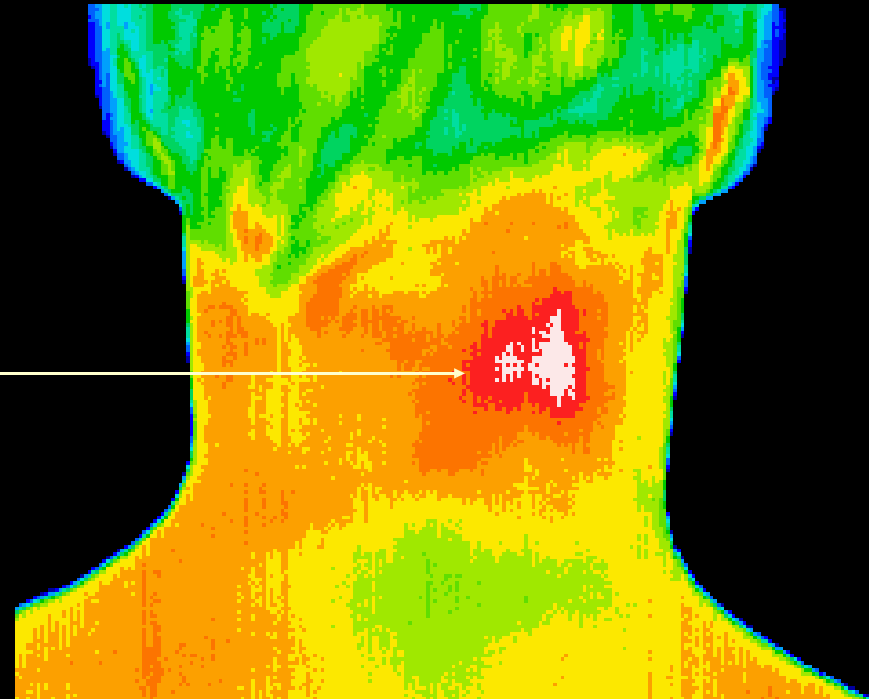


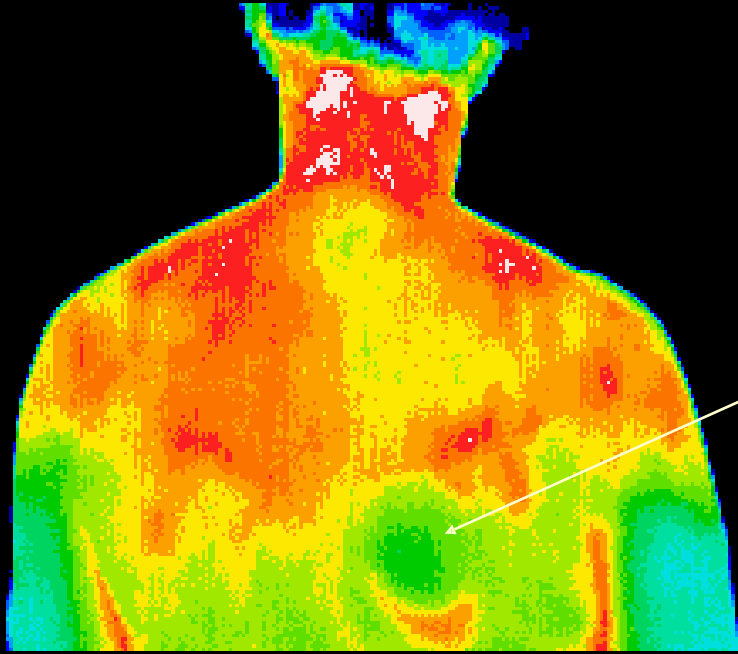
Torticollis
(wry neck)



T2 Hypothermia in a CFS patient

Myofascial inflammation
(splenius)



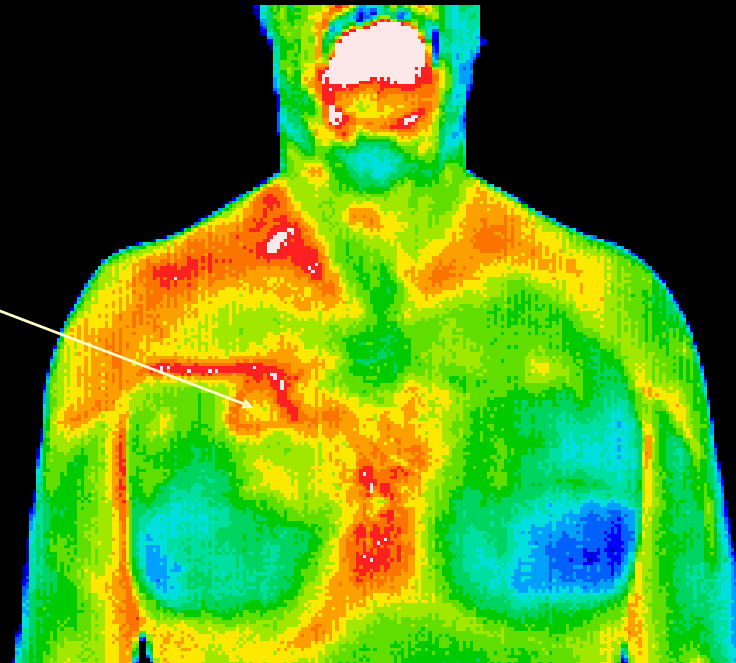


Focal hypothermia relating to a malignant cyst


One per cent of breast cancers are found in men. The survival rate is much lower than in women as most breast cancers in men are only detected in advanced stages.

This tumor was palpable at the time of imaging and there is a well established vascular feed which has even caused increased blood flow at the left brachial plexus. There is also drainage toward the sternum that extends to below the left breast.

Metastasis were later found in other organs and this patient did not survive.

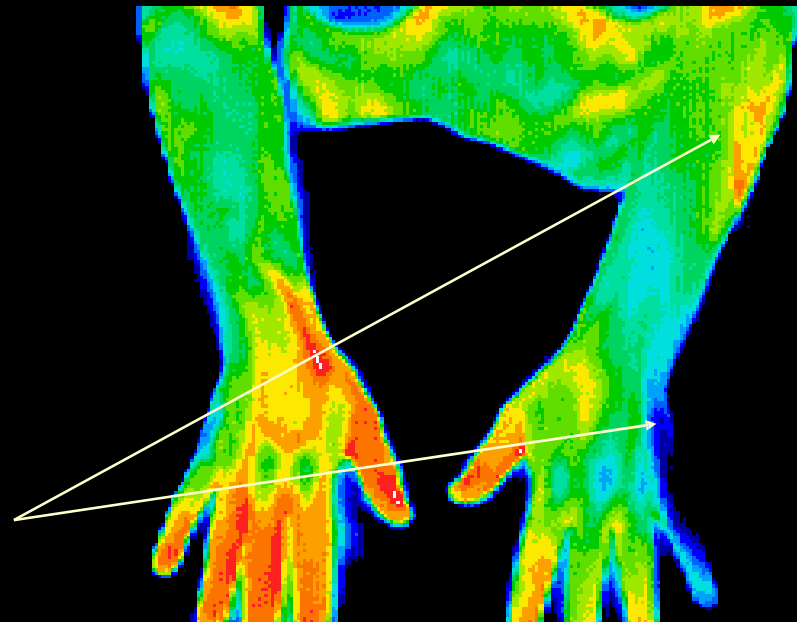
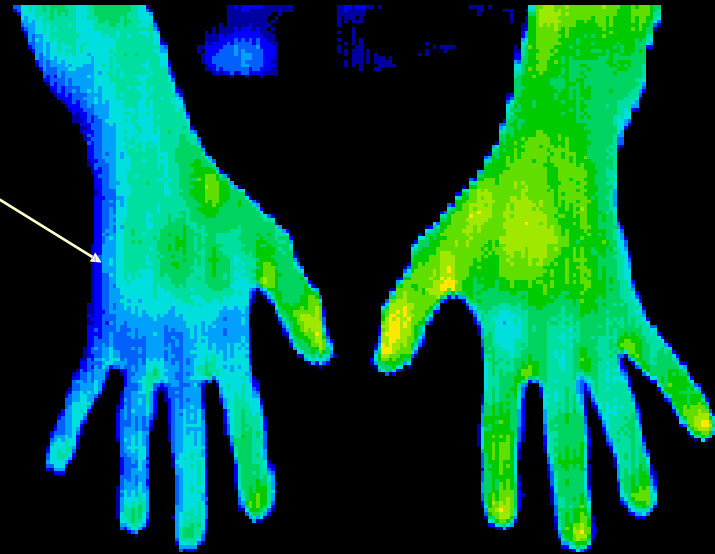


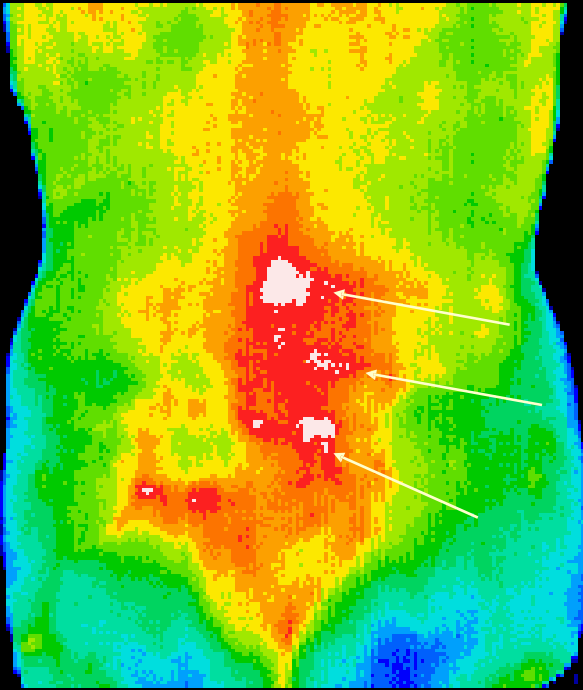
C7 / 8 Radiculopathy.



Carpal Tunnel

Epicondylitis
(painful inflammation of the
muscle and surrounding
tissues of the elbow)

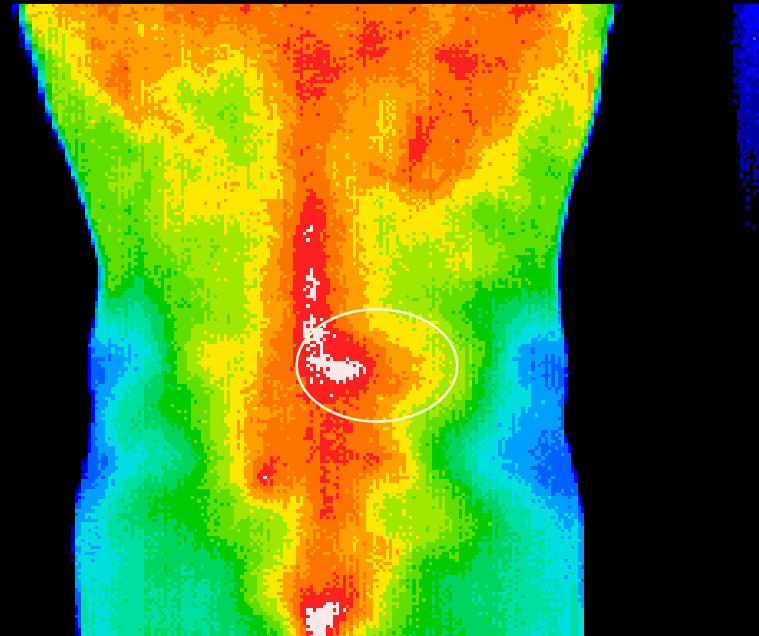


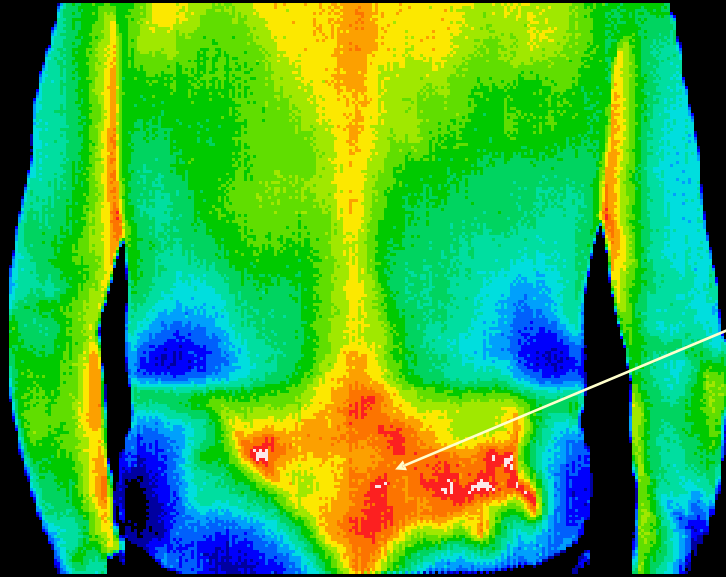


Three stress fractures of the transverse processes of the lumbar spine.

This patient fell from a ladder. X-ray was inconclusive, Scintigraphy showed the fractures.

Mid lumbar disc bulge to the right



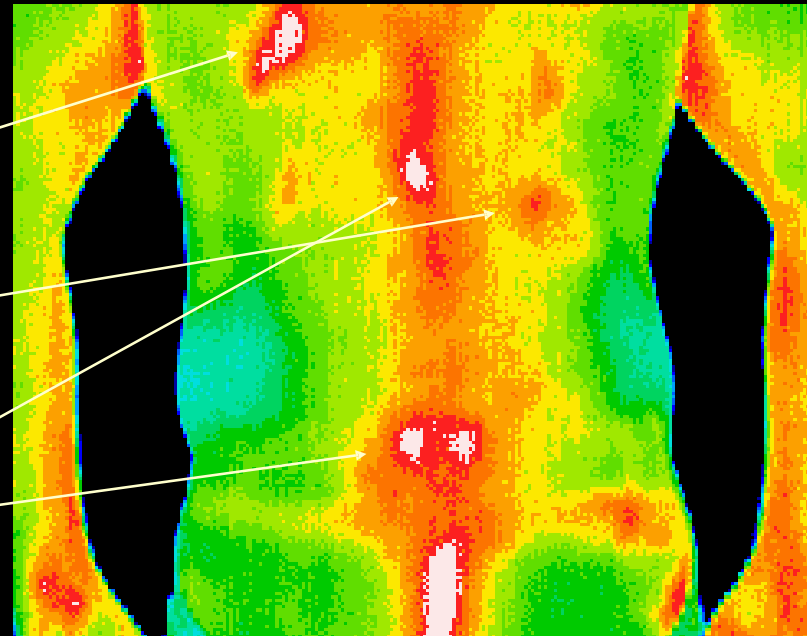


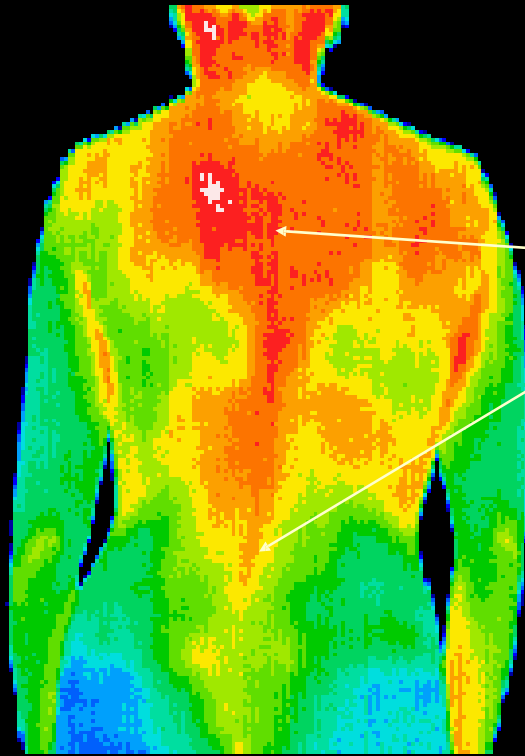
Sacral inflammation R>L

Muscle attachment to scapula

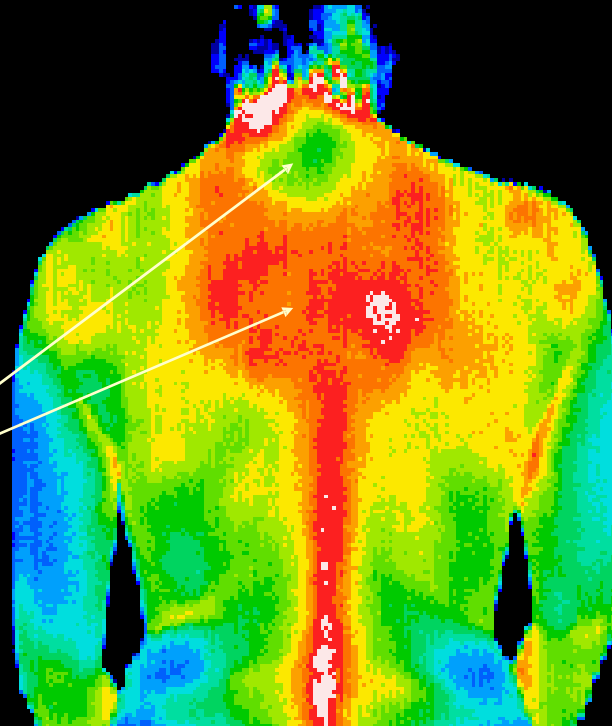
Kidney ?

Spinal inflammation

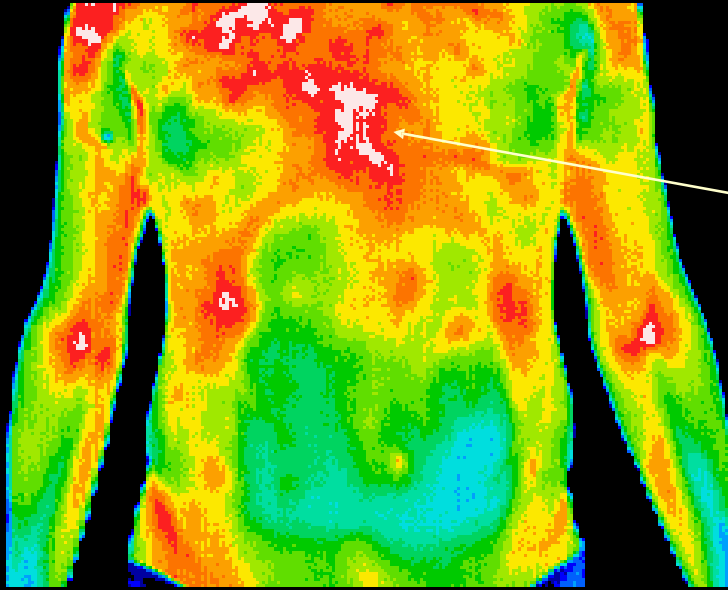




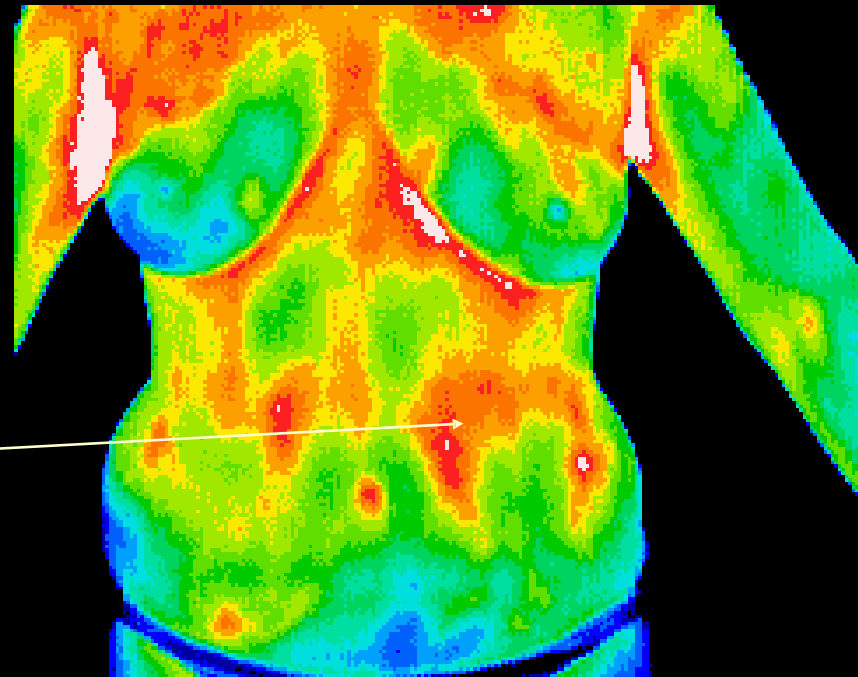
Scoliosis



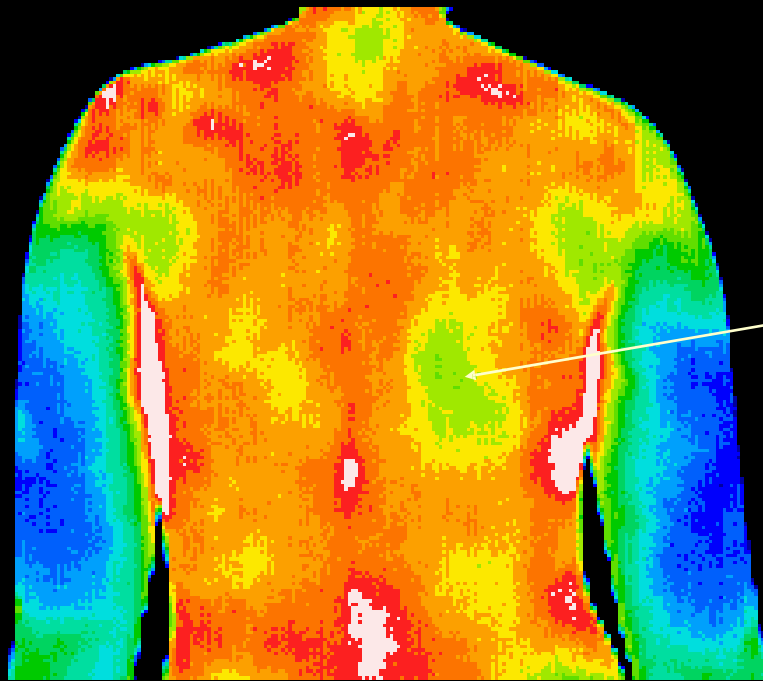
Fibromyalgia



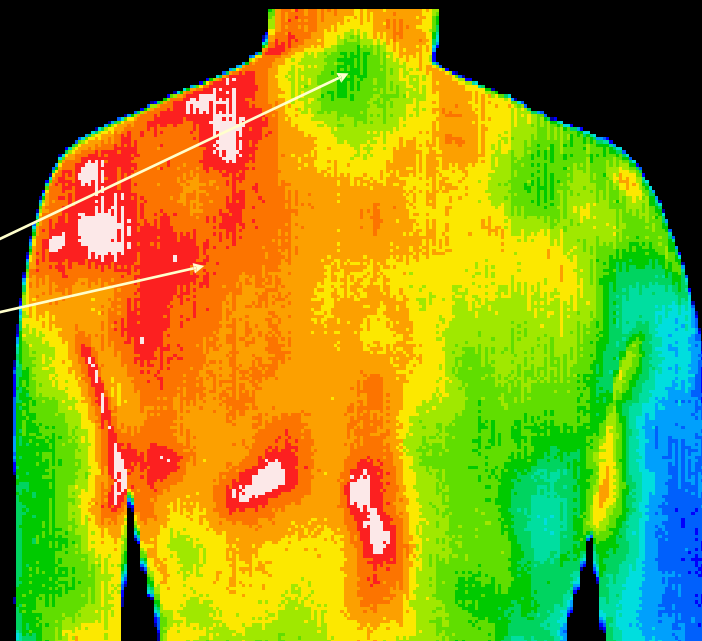
Oesophageal cancer



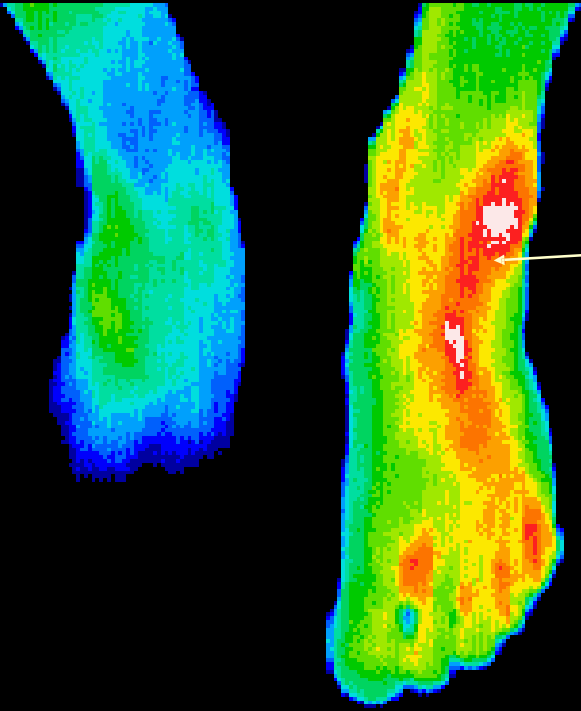
Inflammation caused
by morphine pump



Right Lung Cancer

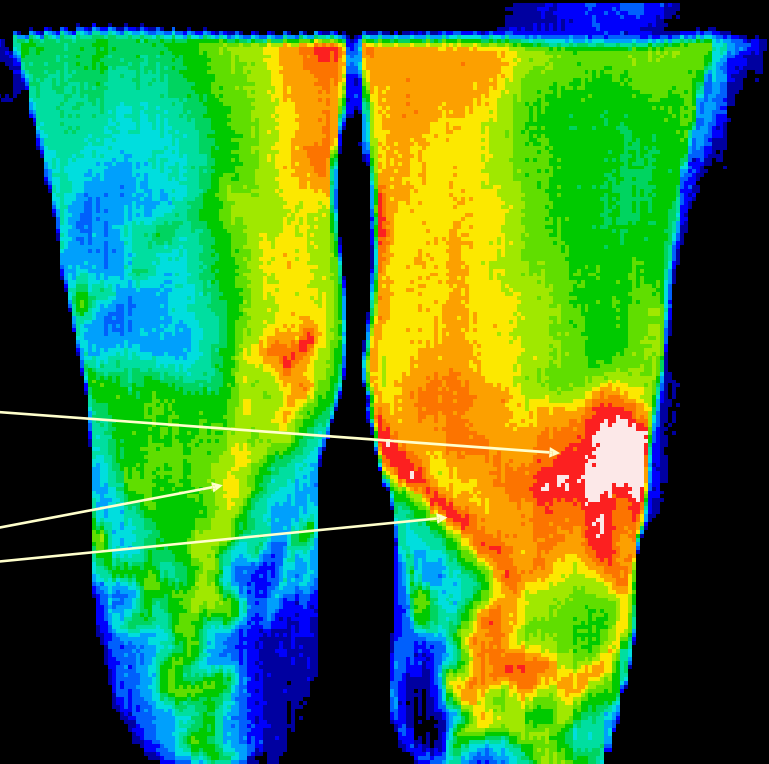


Fibromyalgia

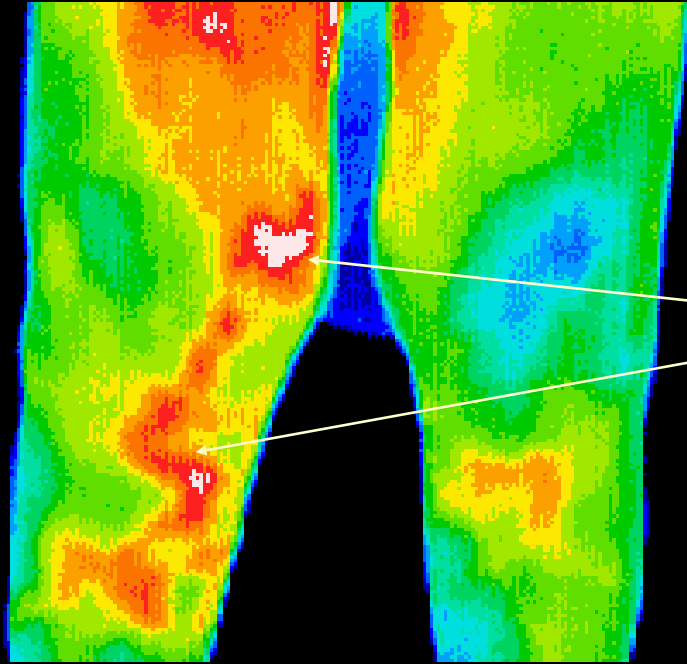


Sprained ankle

Osteoarthritis of the left knee

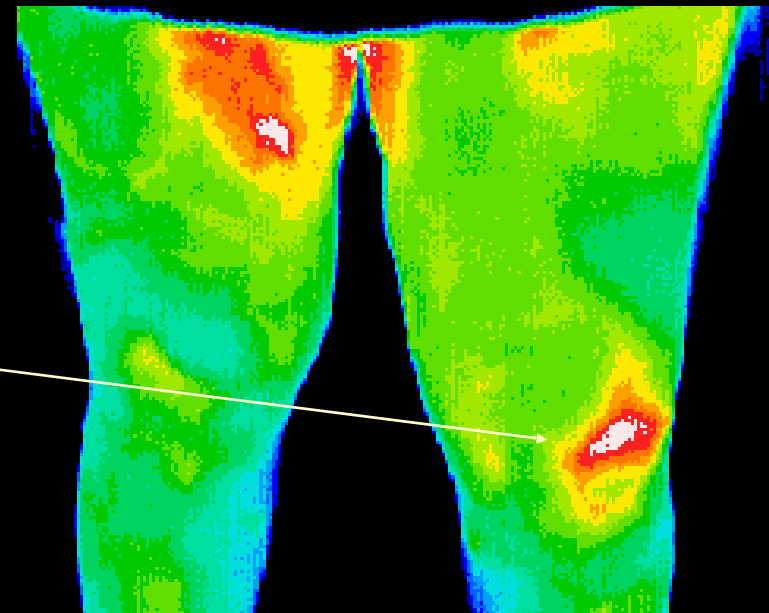


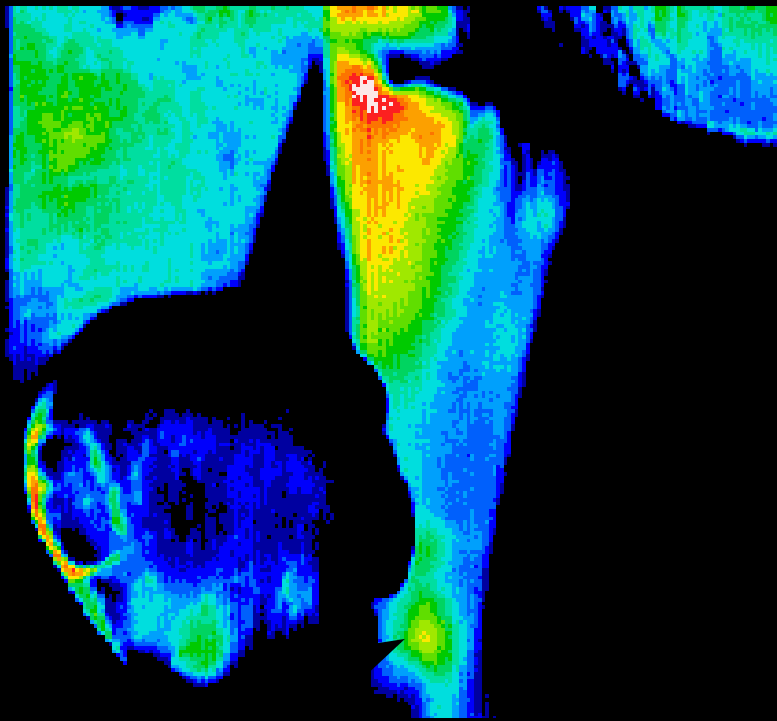
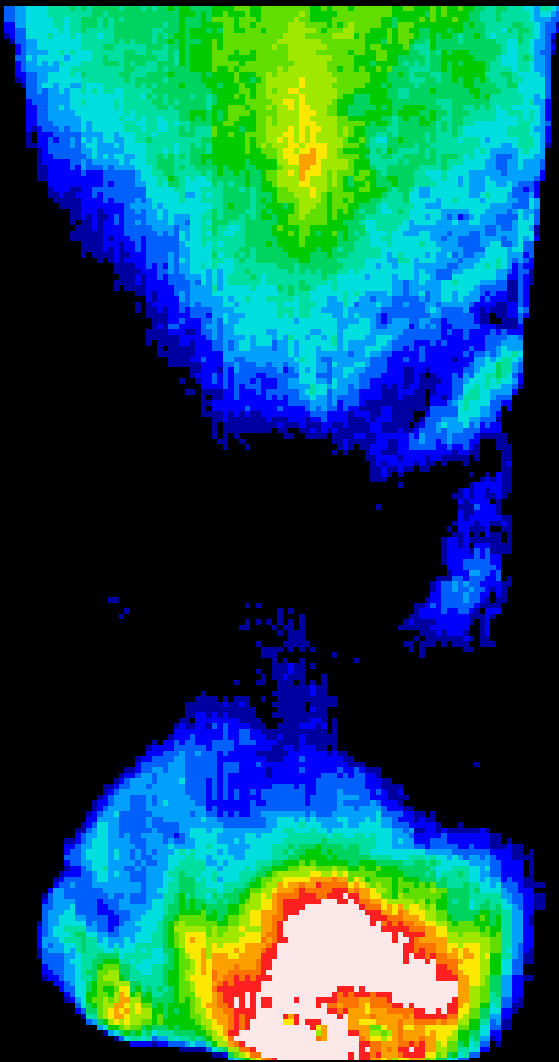
Varicosities



Varicosities and osteoarthritis


Osteoarthritis
left knee





After several clinical examinations by the Zoo vets no cause could be diagnosed for the lameness in the left front foot. Nerve block injections were to be the next test tried.

Thermography clearly identified a localized area of infection which was easily treated once found.



We use examples of animal studies to emphasize that thermography can provide useful information when a patient cannot tell us where it hurts..... Senile dementia, Alzheimer's, unconscious patients, language difficulties, young patients, mental disabilities, and any other reason that a patient cannot give coherent description of symptoms.