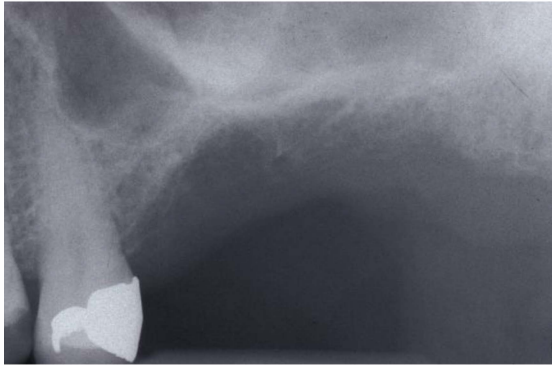




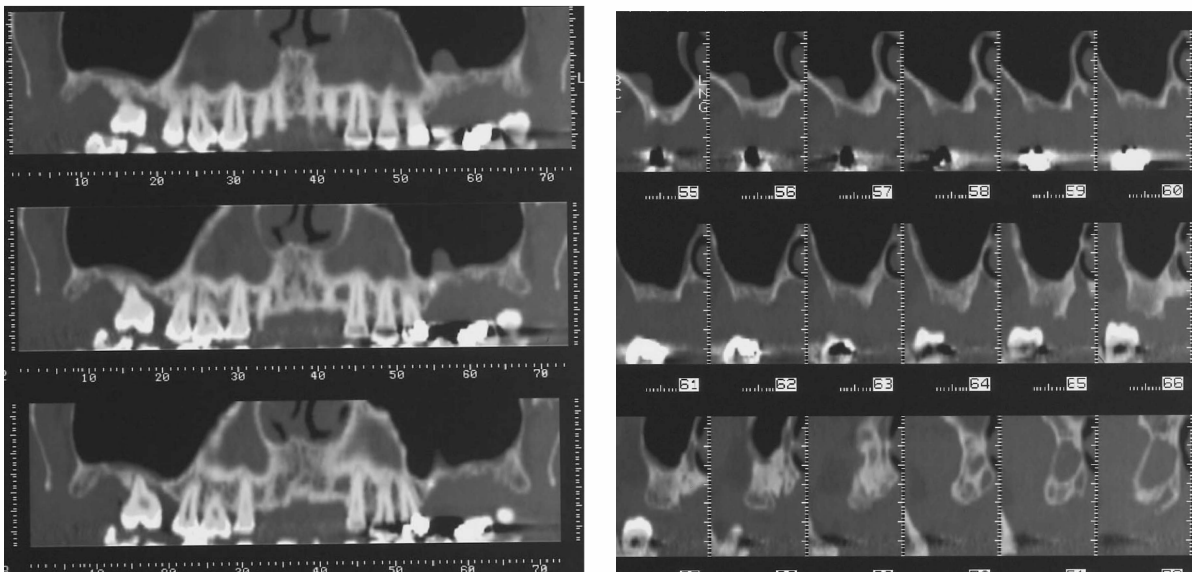
# TRANSCRESTAL SINUS FLOOR ELEVATION

## Surgical Procedure

After establishing the implant position according to the prosthetic treatment planning, the residual bone height is first measured on periapical radiographs as the distance from the bone crest to the sinus floor.

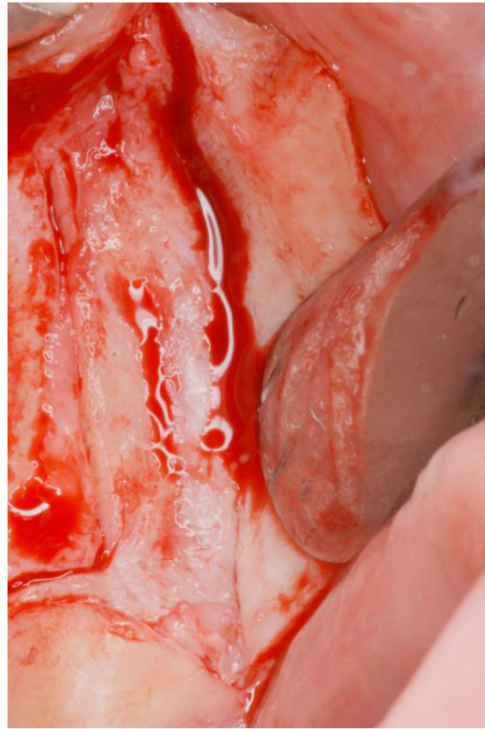
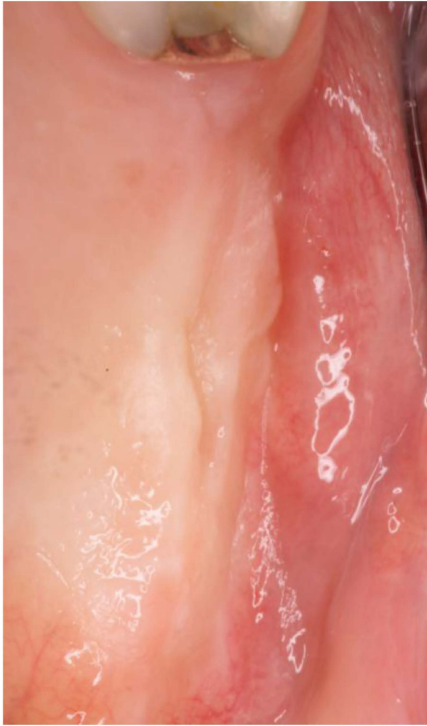

**Fig 1.** The distance between the ridge crest and the floor of the sinus is measured on a preoperative periapical radiograph.



**Fig 2 .** CT Scans.

Bone crest is exposed with a modified partial thickness flap. The first incision starts on the palatal surface of the masticatory mucosa with a long bevel which extends buccally within the supra bony connective tissue and continues over the edentulous crest and towards the fornix. This first incision involves all the masticatory mucosa that covers the occlusal part of the edentulous crest. The second incision is complementary to the first. It begins on the buccal border of the bevel and continues within the connective tissue on the palatal aspect of the ridge.




**Fig 3** (a) Clinical photograph showing the edentulous ridge of the maxilla before surgery. (b) Exposure of the crest with the partial-thickness flap.

A rectangular portion of the edentulous bone crest is performed with the tip of the blade inserted on the Magnetic Mallet, avoiding sinus membrane perforation.

Fig4

Magnetic Mallet is set at FORCE NUMBER 1      **65 daN**      applied in **120 μs**



EXP 3 FA

**Fig 4.** Blade for cut of bone crest.

The edentulous bone crest is covered by the preserved suprabony connective tissue and the underlying periosteum. The tip of the blade is oriented palatally to perform the palatal bone incision, and buccally for the buccal bone incision. The final shape of the crestal bone portion presents a trapezoidal shape, since the external part of the carved bone crest results smaller of the internal one. Fig 5

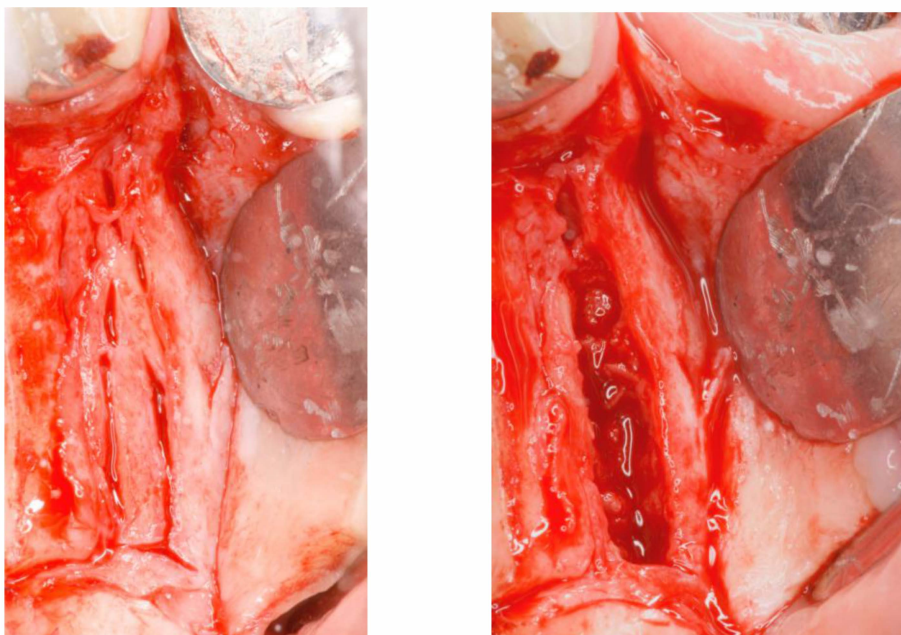


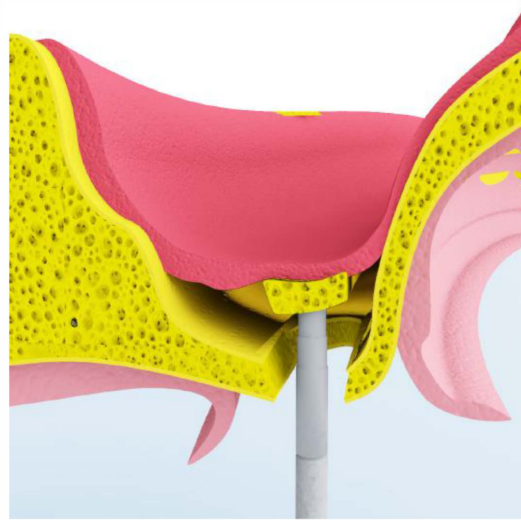Fig 5. (a,b) An intrabony fissure is impressed within the bone crest with a blade, and it is deepened almost to the level of the maxillary sinus floor.

When all the occlusal portion of the edentulous crest is marked, the tip of a bone expander is used. The selected instrument is gently tapped with a Magnetic Mallet to make totally mobile this carved bone crest internally to the sinus cavity. Fig 5

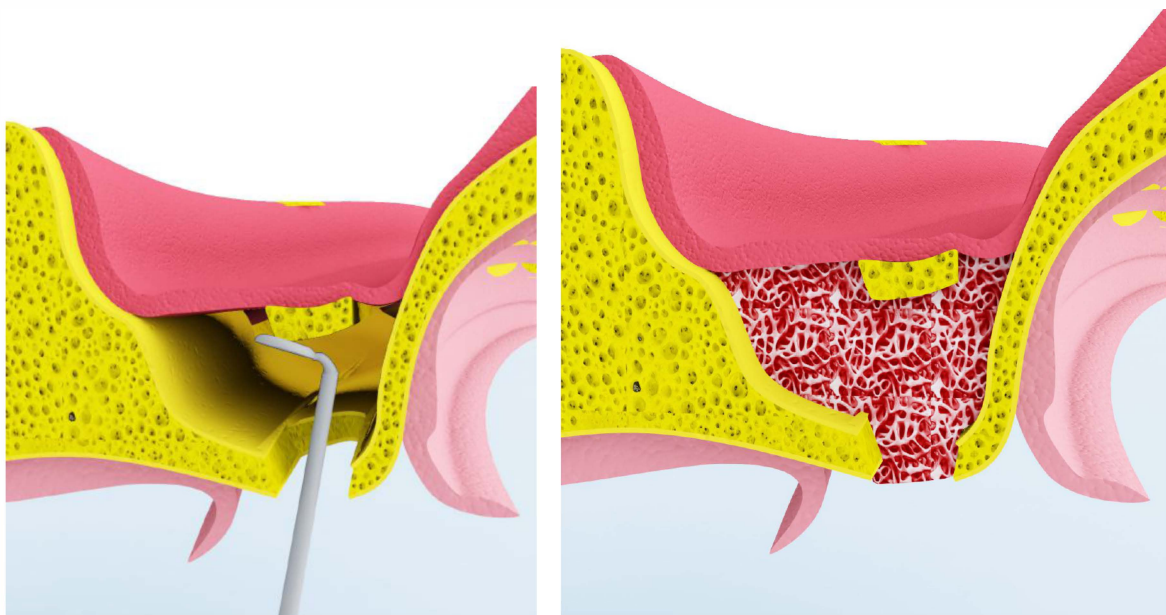
Magnetic Mallet is set at FORCE NUMBER 1      **65 daN**      applied in **120  $\mu$ s**



Fig 5 a



b

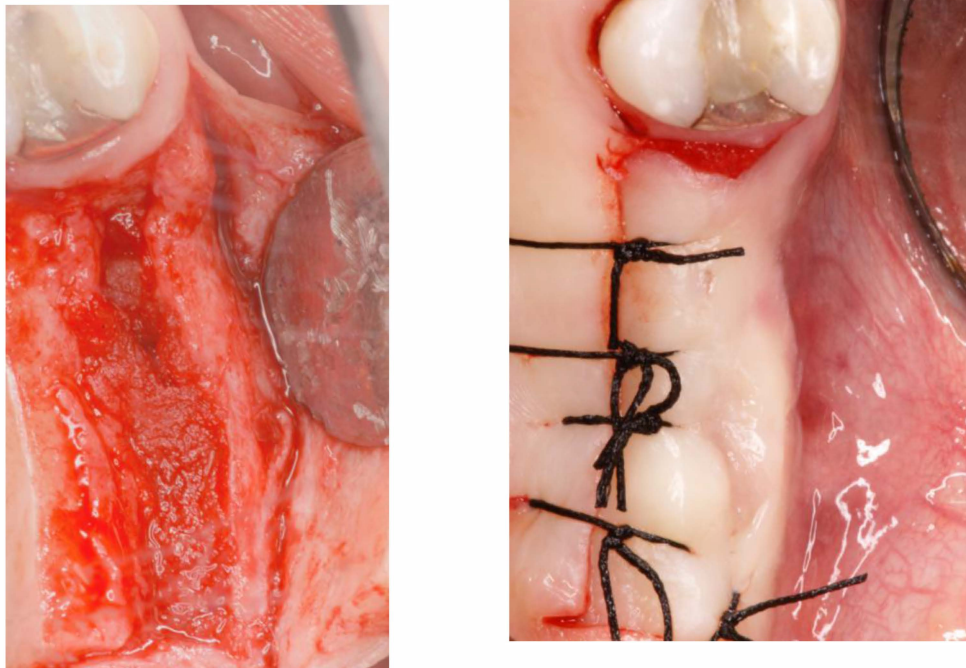


c

**Fig. 5.** Schematic view of bone expander inserted on Magnetic Mallet at force one to make totally mobile this carved bone crest internally to the sinus cavity. Schematic view of gentle detachment of the Schneiderian membrane, using the No. 2 De Marco curette, from the laterals and mesio-distal walls. Collagen sheets are placed in the created cavity to maintain in its position the bone crest apically displaced.



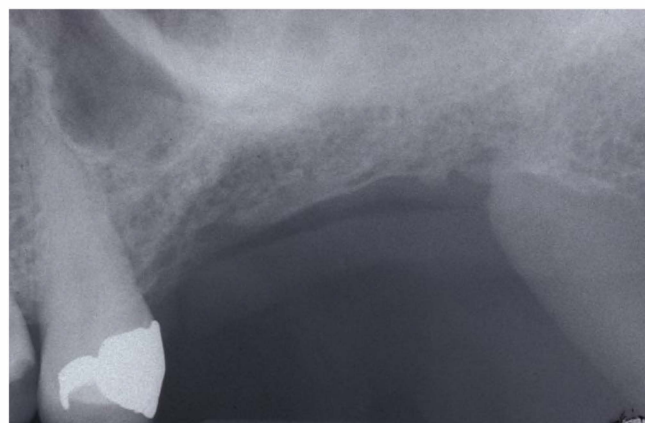
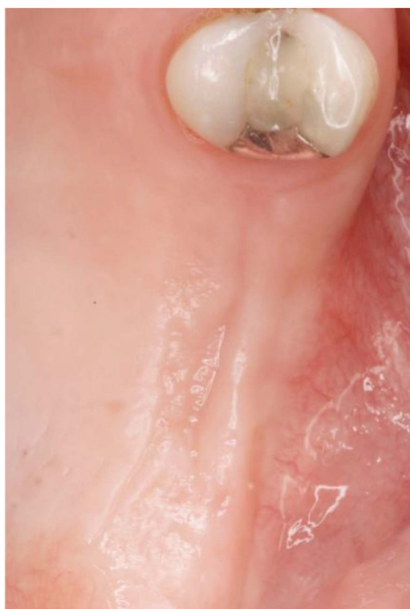The Schneiderian membrane is carefully and totally detached, using the No. 2 De Marco curette, from the lateral and mesio-distal walls to create an empty space height. The result is a creation a new space between the two lateral walls and the mesio-distal as well. Once the space obtained with the probes is sufficient a 1 x 1 cm collagen sheet or other biomaterials are placed in the created cavity to maintain the bone crest apically displaced.



**Fig 6.** Clinical view of surgical procedure with final sutures of gingival margins

Suture are placed obtaining a primary wound closure, and are removed after 1 week. Fig 6.

Three months later, the same surgical procedure is followed for stage-2 (fig. 7).



**Fig. 7.** Postoperative clinical and periapical radiograph 3 months after TSFE procedure. The shadow of the fractured sinus floor can be seen.

The implant site is created expanding the tissue that filled-up the cavity created at the stage-1, both laterally against the preexisting lateral walls and apically moving up and compressing with a progressive series of bone expanders attached and pushed by Magnetic mallet. Fig 8-10.

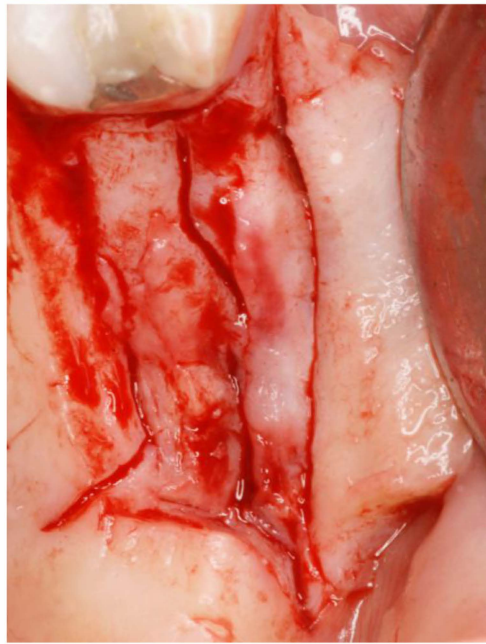
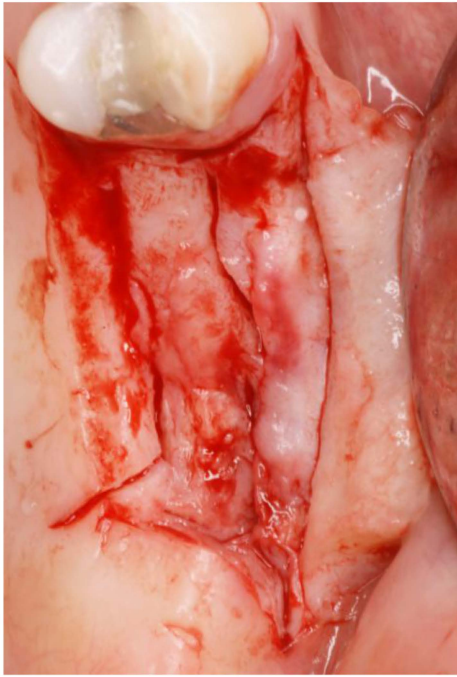
Magnetic Mallet is set to apply different **forces**:

|                |                |                          |
|----------------|----------------|--------------------------|
| FORCE NUMBER 2 | <b>85 daN</b>  | applied in <b>120 μs</b> |
| FORCE NUMBER 3 | <b>120 daN</b> | applied in <b>120 μs</b> |

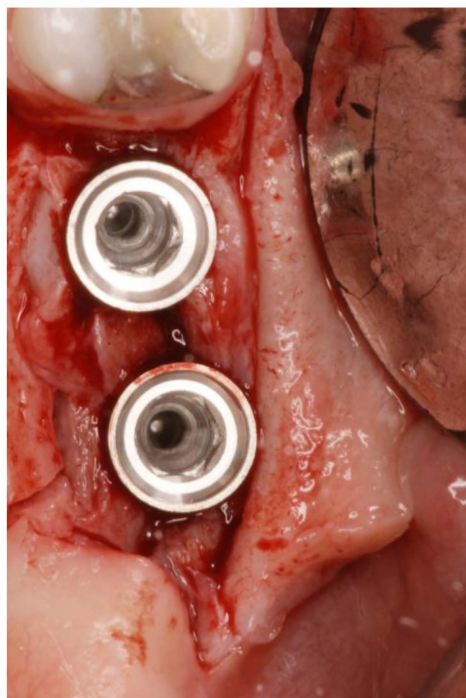
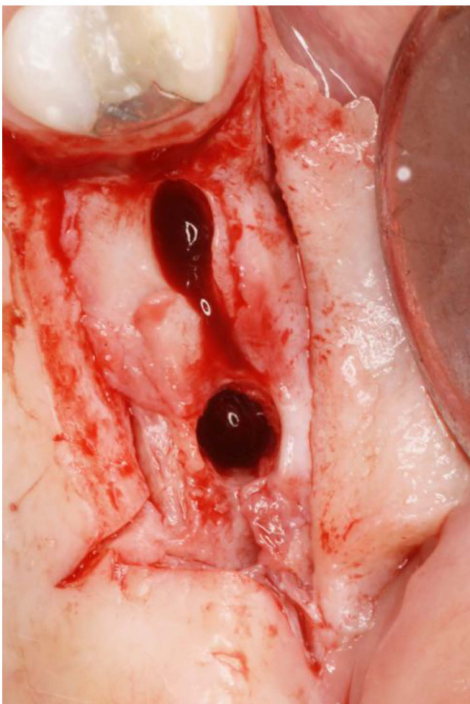


**Fig 8.** Different types of osteotomes are used.

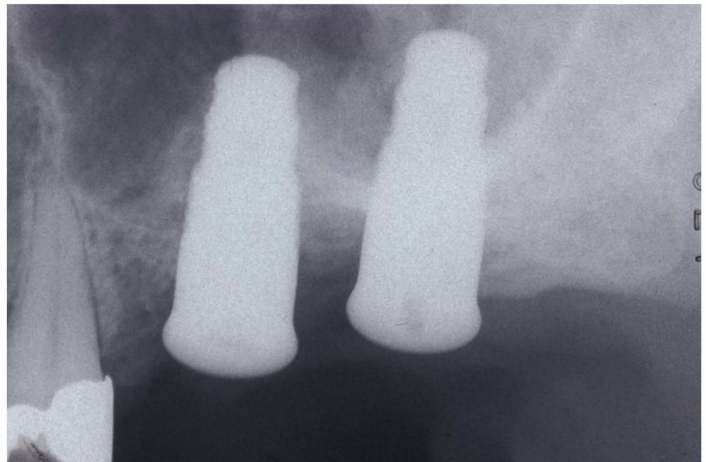
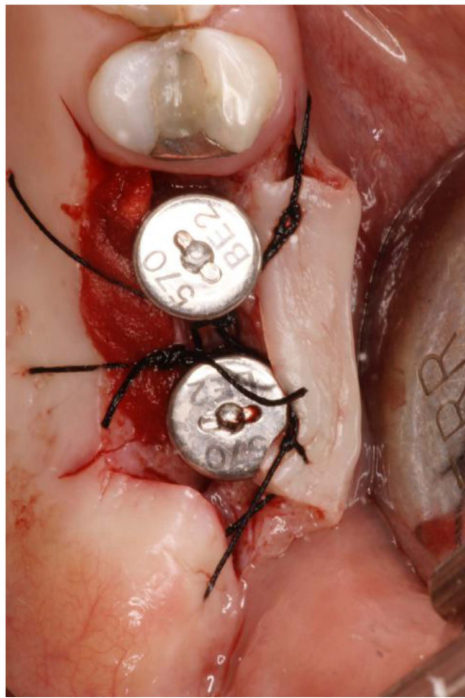
The buccal flap is apically repositioned and stabilized with sutures tied to the margin of the lingual/palatal flap and anchored buccally with a loose loop to the periosteum at the level of the alveolar mucosa. This suture design avoided tissue traction in the repositioned buccal flap. The gap between the superficial margin of the buccally repositioned tissue and lower part of the palatal tissue, heals by secondary intention in order to increase the size of keratinized mucosa.



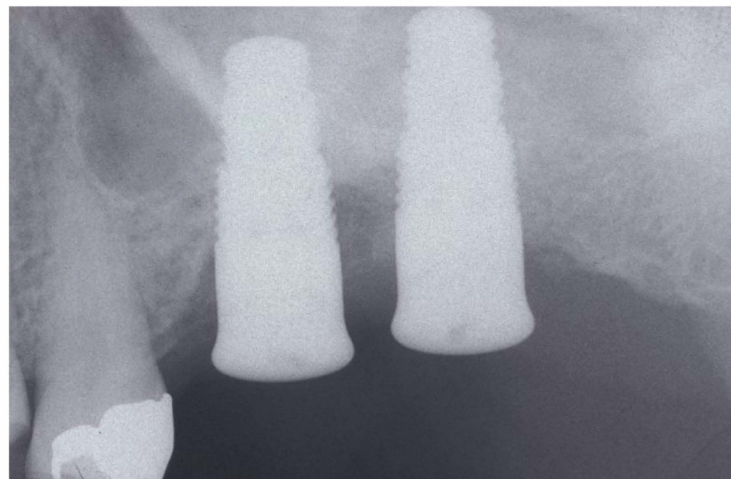
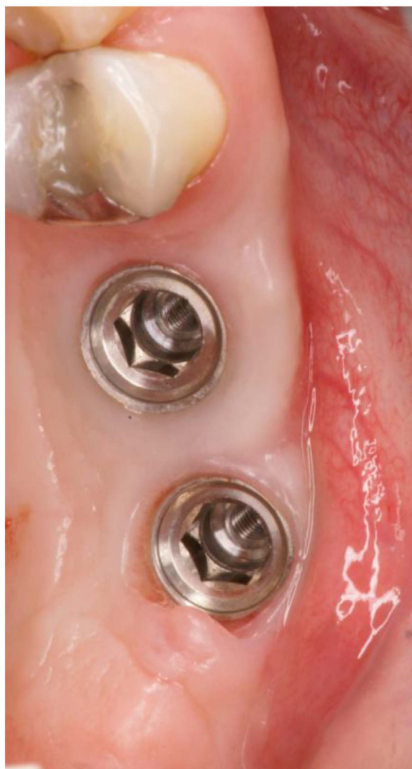**Fig. 9.** An intrabony fissure is impressed within the bone crest with a blade, and it is deepened almost to the level of the maxillary sinus floor.







**Fig 10.** The implant site is created expanding the tissue that filled-up the cavity created with the stage-1 in all directions, means laterally against the preexisting lateral walls and apically moving up and compressing with a series of progressive increase in diameter of bone expanders. The buccal flap is apically repositioned and stabilized with sutures tied to the margin of the lingual/palatal flap and anchored buccally with a loose loop to the periosteum at the level of the alveolar mucosa. Periapical radiograph of implants immediately after surgical procedure.



**Fig 10.** Clinical aspect 4 months later. Periapical radiograph performed as usual 4 months later stage-two surgery. The modified profile or the cortical bone lining the floor of the maxillary sinus can be identified above the implant. The transformation is evident when this radiograph is compared with Fig 1, using the apex of the second bicuspid as a reference point.

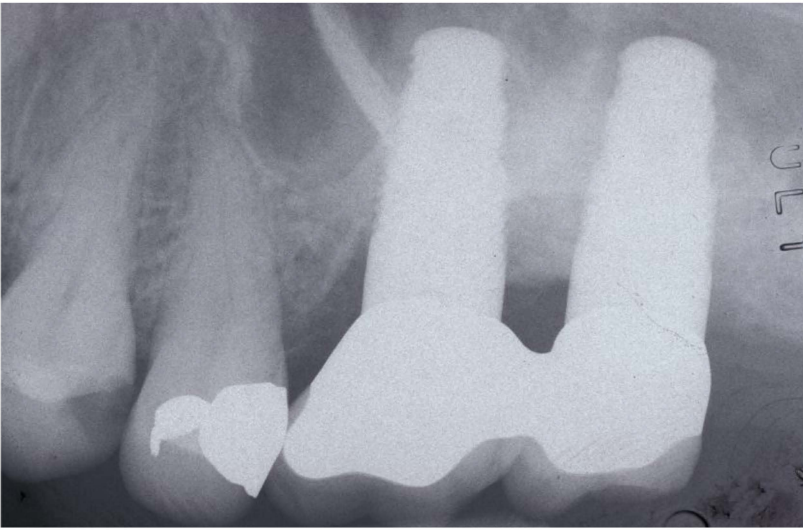


Fig 11. follow-up at 4 years.