

Case report

Medical and surgical management of *Pasteurella canis* infectious keratitis

Ankit Shah*, Mansi Talati, Thomas Mauger

Ohio State University Havener Eye Institute Department of Ophthalmology and Visual Science, USA

ARTICLE INFO

Keywords:

Pasteurella canis

Keratitis

Conjunctival flap

Penetrating keratoplasty

ABSTRACT

Introduction: We describe a case of refractory *Pasteurella Canis* keratitis that initially failed antimicrobial treatment but was successfully treated with a conjunctival flap followed by a penetrating keratoplasty.

Case discussion: A 70-year-old male had persistent corneal edema related to previous herpes zoster keratouveitis with visual acuity of 20/400. An endothelial keratoplasty was performed with improvement in vision to 20/25. Several months after this surgery the patient developed a corneal infiltrate and cultures grew *Pasteurella canis*. The infection persisted despite topical treatment with broad spectrum fortified vancomycin, tobramycin and fluoroquinolones. A conjunctival flap combined with corneal cryotherapy was performed to help mitigate symptoms and to allow the ulcer to heal. A penetrating keratoplasty was done several months later.

Discussion: The patient achieved pain relief immediately after the flap was placed. Medications were tapered off in the following few months after the procedure. A penetrating keratoplasty was performed 4 months later. The patient has remained almost entirely symptom free, and the graft remained clear one year after surgery.

Conclusions: A keratitis caused by *Pasteurella canis* that is resistant to medical therapy can be treated successfully with a conjunctival flap and cryotherapy followed by a penetrating keratoplasty.

1 Introduction

Pasteurella is a genus of facultative anaerobic gram-negative coccobacilli typically found in the oral flora and digestive tract of domestic dogs and cats. These zoonotic species are absent in the normal flora of humans. Several species of *Pasteurella*, including *Pasteurella multocida* and *canis* have been implicated as a cause for soft tissue and skin infection [1]. Specifically, *Pasteurella canis* infection has been reported most commonly in soft tissue, bone, joint, and wound infections after dog bites and scratches [2]. Immunosuppressed patients and those diagnosed with chronic systemic illnesses including diabetes, cirrhosis, rheumatoid arthritis are at greater risk for infection, even in the absence of obvious entry site [3]. Ophthalmic infections attributed to *P. Canis* is extremely rare and currently limited to case reports of conjunctivitis, and post-traumatic ocular surface culture isolates [7,8]. To date, there have not been any described cases of *P. canis* keratitis. Our goal is to share our experience managing a complex corneal ulcer caused by *P. canis* that initially failed medical treatment and ultimately required surgical intervention in hopes to provide insight to providers, ophthalmologists, and infectious disease specialists.

2 Case report

A 70-year-old male with a history of non-insulin dependent Diabetes

Mellitus presented to the clinic with acute on chronic left eye redness, light sensitivity, and blurry vision. He had been followed for a long-standing presumed herpetic disciform keratitis and successfully treated in the past with topical steroids (prednisolone acetate 1% ophthalmic, and difluprednate ophthalmic 0.05%), Valacyclovir, and Dorzolamide hydrochloride/Timolol Maleate ophthalmic solution. Unfortunately, over the course of several months, the patient developed non-clearing stromal and epithelial corneal edema and bullae, keratic precipitates, and elevated intraocular pressures that did not respond to medical treatment. The patient required a Descemet's stripping automated endothelial keratoplasty to treat his herpetic disciform keratitis and was treated postoperatively with topical 1% prednisolone acetate, 0.3% ofloxacin and oral 400 mg Acyclovir twice daily. He had an uneventful postoperative course. His vision improved from count fingers to 20/25 before he was ultimately lost to follow up. At the time of his last visit the patient had been on once daily topical prednisolone acetate, and twice daily oral acyclovir (400 mg).

Approximately 18 months after the transplant, the patient presented to our clinic with acute onset left eye pain, vision loss, photophobia, redness and discharge. Visual acuity had dropped to light perception only. On exam, a new large (6 mm × 6 mm) paracentral purulent infiltrate with diffuse swelling of the cornea, and associated peripheral haze was noted (Fig. 1). Fluorescein staining confirmed a large epithelial defect with moderate stromal thinning (Fig. 2). View of the

* Corresponding author at: Havener Eye Institute, Department of Ophthalmology, The Ohio State University, 915 Olentangy, River Road, Suite 5060, Columbus, OH 43212, USA.
E-mail address: Shah.aa7@gmail.com (A. Shah).

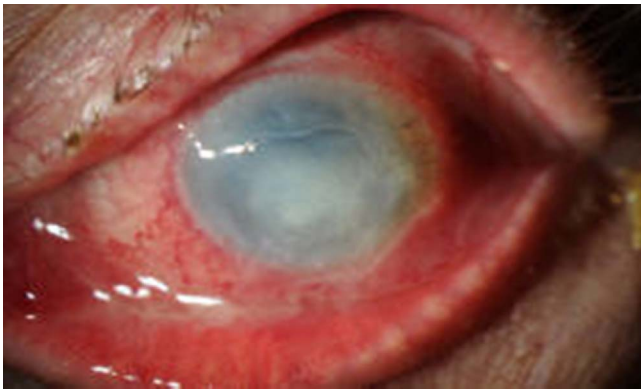

Fig. 1. Large central corneal infiltrate with sharp borders moderate thinning, and an associated epithelial defect.

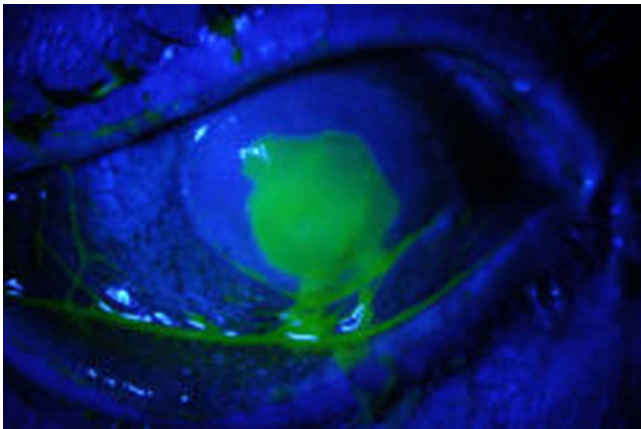


Fig. 2. Fluorescein staining illustrates the extent of the epithelial defect.

anterior chamber and the endothelial graft was severely limited. Gram stains as well as corneal scrapings on blood, chocolate and sabouraud agar, as well as thioglycollate broth were obtained for bacterial(aerobic and anaerobic) and fungal cultures. The patient was initially started on topical fortified vancomycin 50 mg/mL tobramycin 15 mg/mL, and amphotericin 0.15% hourly drops. Oral doxycycline 100 mg twice daily was also started for its anti-inflammatory properties. Cultures from the blood agar and thioglycollate broth grew *Pasteurella canis*. Ofloxacin 0.3% drops and ciprofloxacin 0.3% ointment were later added after antibiotic sensitivities were reviewed and showed susceptibility to fluoroquinolones. Susceptibilities also showed that the organism was sensitive to penicillin and cefazolin (no beta lactamase activity).

Judicious use of topical steroids and NSAIDS did not provide relief for the patient's eye pain and were promptly discontinued to encourage corneal epithelialization and limit melting. The patient's corneal ulcer failed to improve despite directed antimicrobial therapy. The decision was made with the patient to undergo conjunctival flap with cryotherapy treatment to the cornea, corneal culture and biopsy, and tarsorrhaphy to the left eye. Cultures were negative and permanent sections illustrated acute on chronic keratitis.

Immediately following the procedure, the patient noticed a significant improvement in pain, redness, and discharge. His postoperative regimen included ciprofloxacin ointment and ofloxacin drops four times a day, with a gradual taper over a few months following the procedure. The flap continued to heal well and the patient denied any further symptoms or vision loss (Fig. 3). Once the ocular surface was deemed stable, the patient underwent a penetrating keratoplasty and permanent temporal tarsorrhaphy 4 months later.

No microorganisms were isolated in the host corneal button after transplantation. The pathology specimen showed chronic corneal stromal inflammation and neovascularization, and absent epithelium

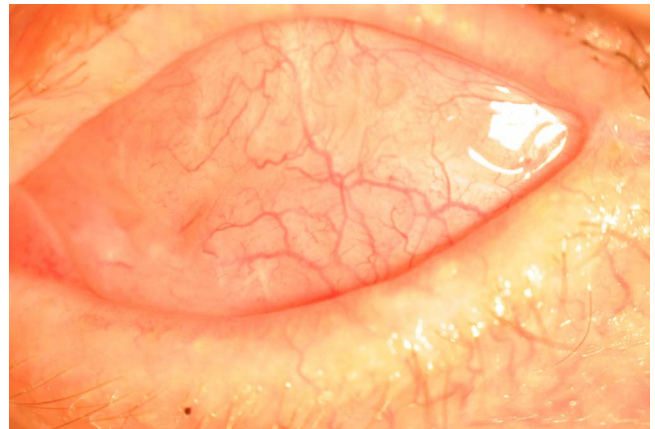


Fig. 3. Clinical slit lamp photo of the eye after conjunctival flap transposition over the corneal ulcer.

and endothelium. Unfortunately, the patient was once again lost to follow up after surgery with the most recent visual acuity documented in this patient being hand motion.

3 Discussion

Pasteurella canis is a gram negative, facultative anaerobic coccobacillus found in the oral and gastrointestinal flora of dogs and cats [4]. This non-motile bacterium is commonly associated with skin and soft tissue infections associated with dog bites and scratches [5]. There are two biotypes of *P. canis* species: biovar 1, which originates from canines and biovar 2 found in bovine animals [6]. In rare cases, especially in immunosuppressed patients, severe life threatening infection such as cellulitis, bacteremia, osteomyelitis, and tenosynovitis have been described. Furthermore, infection in the absence of a penetrating bite or scratch from an animal has also been recognized. We believe that our patient was inoculated with the bacteria through salivary transmission from his pet dog, presumably from repeated licking of his face.

Ocular infection by *P. canis* is extremely rare and the paucity of resources in managing this infection made it difficult to treat. A review of the literature identified several cases of culture positive *P. canis* infections involving the eye, but none involve a fulminant corneal ulcer as seen with our patient. The first case involved a 3-year-old boy who suffered a full thickness conjunctival and scleral perforation after blunt trauma and required urgent repair [7]. Conjunctival cultures around the laceration were positive for *P. canis*, however intra-vitreous cultures remained negative and the patient did not develop endophthalmitis. The second study identified *P. canis* as an important cause of conjunctivitis outbreak that was resistant to empirical treatment in a pediatric agency [8]. Lastly, ocular adnexal infection in the form of *P. canis* dacryocystitis in a human immunodeficiency virus (HIV) positive patient was reported [9]. These cases seem to imply that immune naïve (newborns, and pediatric patients), and immunocompromised patients may be at increased risk for invasive infection.

Treatment of large, vision threatening corneal ulcers requires aggressive broad-spectrum fortified antibiotics, most commonly vancomycin and tobramycin. Antimicrobial therapy is modified based on the results of gram stains, bacterial (aerobic and anaerobic) and/or fungal cultures and sensitivities. *Pasteurella* species are generally susceptible to most antibiotics including penicillin G, amoxicillin/clavulanic acid, piperacillin/tazobactam, doxycycline, fluoroquinolones, third and fourth generation cephalosporins, and carbapenems [4]. On the other hand, macrolides, first generation cephalosporins, and aminoglycosides have poor activity [10]. Rarely, surgical intervention is necessary when medical management fails to control the infection or if there is a delay in diagnosis or treatment. Corneal biopsy is indispensable in isolating the microbe after multiple unsuccessful culture attempts, and

therapeutic corneal transplants are often employed to emergently repair corneal perforations.

The case demonstrates the effectiveness of using a conjunctival flap with cryotherapy for treatment of this rare case of medication-resistant infectious keratitis with *Pasteurella canis*, an organism not typically found in ocular disease. The procedure was first introduced by Gunderson in 1958 as a means to treat chronic infectious keratitis not responding to medical treatment [11]. The conjunctival flap has clear benefits in increasing the vascularity at the site of infection, promoting healing and providing a stable ocular surface [12]. Unfortunately, there are several limitations that prevent this procedure from becoming a popular technique in the surgical management of non-healing corneal ulcers. For instance, a conjunctival flap not only precludes a corneal examination, but it disrupts limbal stem cells, and conjunctiva that may be necessary for glaucoma surgery [12]. Adding cryotherapy to the therapy with the flap may have an additive effect. Cryotherapy treatment of the corneal surface at temperatures of -50 to -60 °C not only denatures proteins and cell walls of the pathogen, but can allow for improved penetration of topical antimicrobials through removal of necrotic tissue [13]. Future considerations could investigate the role of amniotic membrane transplantation in lieu of conjunctiva in the treatment of corneal ulcers. It is unknown whether cryotherapy or the flap alone would have been successful in treating this condition.

Funding

This research did not receive any specific grant from funding agencies in the public, commercial, or not-for-profit sectors.

Conflict of interest statement

The authors declare that they have no conflicts of interest.

References

- [1] Holst E, Roloff J, Larsson L, Nielsen JP. Characterization and distribution of *Pasteurella* species recovered from infected humans. *J Clin Microbiol* 1992;29:84–7.
- [2] Weber DJ, Hansen AR. Infections resulting from animal bites. *Infect Dis Clin North Am* 1991;5:663.
- [3] Hara H, Ochiai T, Morishima T, Arashima Y, Kumasaka K, Kawano K. *Pasteurella canis* osteomyelitis and cutaneous abscess after a domestic dog bite. *J Am Acad Dermatol* 2002;46(5):S151–2.
- [4] Kim B, Pai H, Lee KH, Lee Y. Identification of *Pasteurella canis* in a soft tissue infection caused by a dog bite: the first report in Korea. *Ann Lab Med* 2016;36:617–9.
- [5] Albert TJ, Stevens DL. The first case of *Pasteurella canis* bacteremia: a cirrhotic patient with an open leg wound. *Infection* 2010;38:483–5.
- [6] Bhat S, Acharya P, Biranthabail D, Rangnekar A, Shiragavi S. A case of lower respiratory tract infection with canine-associated *Pasteurella canis* in a patient with chronic obstructive pulmonary disease. *J Clin Diagn Res* 2015;9(8). DD3-DD04.
- [7] Rashid N, Zam Z, MdNoor S, Siti-Raihan I, Azhany Y. *Pasteurella canis* isolation following penetrating eye injury: a case report. *Case Rep Ophthalmol Med* 2012;3:62–9.
- [8] Balikoglu-Yilmaz M, Yilmaz T, Esen AB, Engin KN, Taskapilo M. *Pasteurella Canis* and *Granulicatella adiacens* conjunctivitis outbreak resistant to empirical treatment in a child welfare agency. *J Pediatr Ophthalmol Strabismus* 2012;49(5):314–9.
- [9] Negi SS, Mehta R, Gade N. Unusual Aetiology of *Pasteurella canis* Biovar 2 causing dacryocystitis in HIV patient: a case report and review of literature. *J Clin Diagn Res* 2017;11(2). DD01-DD03.
- [10] Bhat S, Acharya P, Biranthabail D, Rangnekar A, Shiragavi S. A case of lower respiratory tract infection with canine-associated *Pasteurella canis* in a patient with chronic obstructive pulmonary disease. *J Clin Diagn Res* 2015;9(8). DD3-DD04.
- [11] Gunderson T. Conjunctival flaps in the treatment of corneal disease with reference to a new technique of application. *Arch Ophthalmol* 1958;60:880–8.
- [12] Abdulhalim BE, Wagih MM, Gad AA, Boghdadi G, Nagy RR. Amniotic membrane graft to conjunctival flap in treatment of non-viral resistant infectious keratitis: a randomized clinical study. *Br J Ophthalmol* 2015;99(1):59–63.
- [13] Chen Y, Yang W, Gao M, Belin MW, Yu H, Yu J. Experimental study on cryotherapy for fungal ulcer. *BMC Ophthalmol* 2015;15:29.