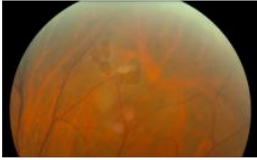


Consults in Retina

Mark T. Dunbar, O.D., F.A.A.O.
 Director of Optometry
 Bascom Palmer Eye Institute
 University of Miami Health System
 Miami, FL 33136



mdunbar@miami.edu

1


Mark Dunbar: Disclosure 2024-2025

- Optometry Consultant/Advisory Board
 - Carl Zeiss
 - Tarsus
 - Orasis
 - Astella
 - Apellis
 - Azura
 - Sun
 - B&L
 - Topcon
 - Visus
 - Sydnexis
 - Cloudbreak
 - Tenpoint

2

Consults in Retina

- Macula problems
 - AMD
 - Retinal vascular disease
 - Occult macular disease
- Peripheral retinal pathology
- Suspicious pigmented lesions
- Unexplained vision loss
- Other



3

Paying attention to the key fundamentals of the eye exam

- Good case history
 - Ocular and medical
- Detailed and organized exam addressing the key elements
 - Skipping any steps can result in missing a key finding
 - Use technology as an adjunct to the exam
 - But do NOT substitute technology for doing the exam
- Make sure the clinical findings explain and fit the “Assessment/Plan”

4

55 yo Caucasian Male

- **Presents with sudden onset of floaters RE**
 - “Feels like I am looking through an oil slick or water”
- BCVA: 20/20 each eye
- CVF: FTFC OU
- Dilated patient with 1% Tropicamide, 2½% Neo
- Examines with 90 D and peripheral retina with BIO and 20 D lens
- Notes Weiss Ring and attached retina

5

55 yo Caucasian Male

- **Diagnosis: PVD**
- Educated regarding signs and symptoms of retinal detachment
- Explains need to **return immediately** if he should see these symptoms
- RTC 1 yr

6

Clinical Decisions...

- Did the OD manage this patient correctly?
- Was there anything else they **should have** done?


7

Clinical Decisions...

- Was he obligated to do scleral depression?
- Should he have referred this patient to a retinal specialist?

8


OPTOMETRIC CLINICAL PRACTICE GUIDELINE



American Optometric Association

Care of the Patient with
**Retinal Detachment
And
Related Peripheral
Vitreoretinal
Disease**

Approved by the AOA Board of Trustees April 27, 1995(1st ed).
Reviewed April 1998, Revised June 1999, Reviewed 2004



American Optometric Association

9

II. CARE PROCESS

This guideline describes the optometric care provided to a patient with a retinal detachment or related peripheral vitreoretinal disease. The components of patient care described are the standards for all clinicians. Professional judgment and individual patient symptoms and findings may have significant impact on the nature, extent, and content of the services provided. Some components of care may be delegated.

A. Diagnosis of Retinal Detachment and Related Peripheral Vitreoretinal Disease

Evaluation of patients with retinal detachment or related peripheral vitreoretinal disease includes the elements of a comprehensive eye and vision examination.* It may include, but is not limited to, the following areas:

1. Patient History

The clinician should review the patient's present and past history of ocular and systemic disease and elicit information regarding:

- Loss of vision
- Sudden, recent onset of floaters
- Flashing lights
- Loss of peripheral visual field
- Family members with loss of vision or history of retinal disease
- History of trauma

2. Ocular Examination

The examination for retinal detachment and related peripheral vitreoretinal disease may include, but is not limited to:

Retinal Detachment

- Best corrected visual acuity
- Pupillary response
- Refraction
- Binocular indirect ophthalmoscopy with scleral indentation if indicated
- Tonometry
- Visual field testing (conventional)
- Retinal imaging or photocoagulation, if indicated

3. Supplemental Testing

The interpretation of data obtained during the examination may indicate the need for additional testing which may include, but is not limited to:

- Fluorescein angiography with fluorescein vein, fluorescein vein, or other peripheral contrast dye
- Ultrasonography
- Fluorescein angiography
- Enface visual field testing

Binocular indirect ophthalmoscopy with scleral indentation is generally necessary for diagnosis of a peripheral retinal break or detachment. During ophthalmoscopy, the underlying choroidal layer is obscured by the detached retina, a bright spot is observed in the presence of a retinal detachment. Scleral indentation may be useful to detect small, asymptomatic peripheral retinal detachments. The hemiretinoscope can be used to search for breaks in detachments using a mirrored fundus contact lens, a hand-held precorneal fundus lens, or a wide-field fundus contact lens. A search for all possible retinal breaks should be performed, and any breaks discovered should be accurately describe the patient's chart or photocoagulated.

The hemiretinoscope examination can also be useful in detecting a detachment retinal detachment or retinal tear within a significant macular detachment by the observation of pigment cells floating in the vitreous vitreous cavity immediately behind the lens (Duffy's sign of "Shower Star"). This pigment cells can originate from the retinotectum.

10

the detached retina, a helpful sign in detecting the presence of a retinal detachment. Scleral depression may be needed to detect small, asymptomatic peripheral retinal detachments. The biomicroscope can be used to search for breaks in detachments using a mirrored fundus contact lens, a hand-held precorneal fundus lens, or a wide-field fundus contact lens. A search for all possible retinal breaks should be performed, and

11

65 yo Caucasian Male PVD

The rest of the story...

- Patient return about 5 weeks later complaining he can't see out of his right eye for th past 4 days
- Has a macula-off RD
- RD repaired but VA 20/200

12

Consults in Retina: Managing the Symptomatic PVD

- Can/should you follow a patient that has symptomatic PVD or should you refer to a retina specialist?
- Depends on skill level with indirect ophthalmoscopy
- Your ability to get a good peripheral retinal exam
 - Can be patient dependent
 - How much dilation
- How much risk you are willing to incur

13

3 Malpractice Cases Associated with Symptomatic PVD

- 1: Sudden floater - Dx PVD but didn't have the pt follow up and not do scleral depression
- 2: Flashes and Floaters – No PVD seen
 - Does everything, documents everything
 - Sees the pt back, only to have the pt return with an RD on the 3rd visit (with retinal specialist)
- 3: Routine exam 5 months ago – all is normal
 - 5 mo later has flashes and floaters -> presents with an RD
 - Pt had lattice that is not noted in the chart

14

Can Imaging substitute for a dilated fundus exam?

15

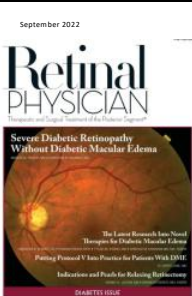
Is UWF Imaging a Substitute for a DFE?

- While UWF imaging can show most of the retina, it will not reveal lesion anterior to the equator

It Should be Used as a Complement to DFE

- One study showed 30% increase in retinal lesion discovery compared to traditional DFE alone

16



September 2022

Retinal PHYSICIAN

Severe Diabetic Retinopathy Without Diabetic Macular Edema

The Latest Research Into Novel Therapies for Diabetic Macular Edema

Putting Preferred V Ret Practices for Patients With DME

Indications and Precautions for Retinal Biopsies

CLARITY ISSUE

The Decision to Dilate
"Not mandatory" does not mean unnecessary or not recommended.

The AAO's Preferred Practice Pattern (PPP) for comprehensive adult medical eye evaluation from 2020 states that "... evaluation of structures situated posterior to the iris is best performed through a dilated pupil."⁴

17

The Decision to Dilate...

The Definition of Eye Exam

Significantly, the definition of an eye exam does not, in any instance, include fundus photography; rather, it mentions ophthalmoscopy — which is dynamic and personally performed by the physician. Going further, extended ophthalmoscopy (92201, 92202) is not imaging.⁹ We conclude therefore that UWF imaging should not be offered solely as a substitute for dilation. **RP**

Binocular indirect ophthalmoscopy (BIO) remains the gold standard.⁶ Therefore, we conclude that UWF imaging should be used only as an adjunct to a DFE that includes careful peripheral retinal examination.

18

The Decision to Dilate...

Insistence on a DFE may also be motivated by potential malpractice litigation against ophthalmologists that is frequently based on missed retinal pathologies due to failure to dilate.

The medicolegal issue may outweigh any other consideration. Anything you would tell a judge about the reason you chose **NOT** DFE pales beside what the patient might lose.

19

The New York Times
By Michelle Crouch
Aug. 20, 2024

Do You Really Need Dilation at Every Eye Exam?

Experts disagree on who needs it and when. Here's what the evidence suggests.

20

The [American Optometric Association](#) recommends that all adults have a dilated eye exam every year, even if they have no vision problems. But the guidance from the American Academy of Ophthalmology is entirely different: That group says most young, healthy adults don't need annual dilated exams.

Instead, the [American Academy of Ophthalmology](#) has said that everyone should have at least one dilated eye exam in their 20s and two in their 30s. When you turn 40, you should get a base line exam that your doctor can use to track changes over time, followed by more frequent dilated checkups according to your provider's advice.

21

Andy Seattle · Sept. 3, 2024
Oh for heaven's sake, it's once a year! Better safe than sorry.
Reply · Recommend · Share · Flag

George Eliot Annapolis, MD · Sept. 2, 2024
"Dr. Andrew Morgenstern, director of the American Optometric Association's clinical resources group."
Boy o boy, it seems to day, every body is a "Dr."
For my money, an ophthalmologist is a "Dr." if someone gets sick on board an airplane, the flight crew is looking for a physician, not a podiatrist or chiropractor.
Let's cut out the quackery.

PNW Native Washington · Sept. 2, 2024
No. If you have what is called an Opti-map of your eyes, dilation is not required.
Reply · Recommend · Share · Flag

Andrea Missouri · Aug. 21, 2024
My annual dilation caught a large melanoma in my right eye. I was 35 and had just had a baby. I will always advocate for dilation. The reasons not to are minimal.

JudyH Florida · Aug. 21, 2024
I had a routine eye exam with dilation when I was 40 and the doctor found a detached retina starting. No symptoms yet. Surgery followed within the week.

Lee Kelly Florida · Aug. 11, 2024
This was a great opportunity for the author to mention podiatrists (and optometrists, who normally do dilation) as well as opticians, optometric assistants, and optometric technicians. It would seem that the author was more than a little biased.

PNW Native Washington · Sept. 2, 2024
The important point for each of you to recognize the signs that a dilated eye exam is needed. It's not an overstatement to say that a dilated eye exam is the only way to catch a detached retina. It's not an overstatement to say that a dilated eye exam is the only way to catch a detached retina. It's not an overstatement to say that a dilated eye exam is the only way to catch a detached retina.

22

48 yo Female – Feb 2025, 1st time visit

- Only wants an updated contact lens prescription
- VA 20/20 in each eye
- Cannot be dilated today – playing golf later

Manifest Refraction				Final Rx						
	Sphere	Cylinder	Axis	Dist VA		Sphere	Cylinder	Axis	VA	Add
Right	-7.00	-0.50	120	20/20	Right	-7.00	-0.50	120	20/20	+1.75
Left	-7.00	Sphere		20/20	Left	-7.00	Sphere		20/20	+1.75

Edited by: Dunbar, Mark T., OD

23

Assessment

- 1) Moderate Myopia with astigmatism and presbyopia
- 2) Atopic dermatitis involving the eyelids
Has periodic exacerbations
Was Rx steroid cream

Plan

- 1) Ed and reassure
- 2) Rx given for specs and CL
Does not seem to need a toric lens in the RE
Will have optical order trials
- 3) Rx for Maxitrol ointment to use as needed for episodes of atopic lids

RTC for DFE
Not able to be dilated today

PT will call
Check IOP at next visit and dilate

24

4/18/2025: Urgent email

- Sudden onset of a cobweb in her vision and has lost half of her vision (while playing golf)

Spots and/or Floaters
 Additional comments: Left eye for 1.5 hours.

Timeline:
 Since 12/2024, noted possible intermittent floater OS. Denies flashing lights
 1 day history of decreased VA OS. Started with a cob web in vision, then rapidly decreased
 Started while playing golf this afternoon
 Now can only see out of the periphery OS

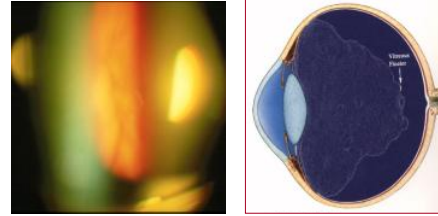
Visual Acuity (Snellen - Linear)

Dist cc	Right	Left
	20/20 -2	E @ 1'

Correction: Contacts

25

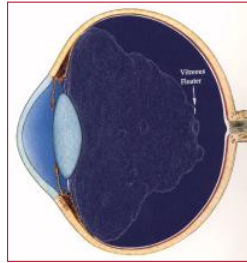
Diagnosis and Management of the Symptomatic PVD



26

PVD

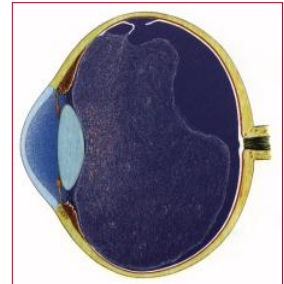- 65% of individuals > 65 have PVD
- More common in women
- More common following intraocular surgery
- More common following inflammation
- More common in aphakes



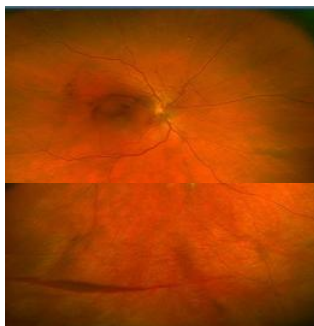
27

PVD

- Retinal tears occur **8-15%** of eyes with symptomatic PVD
 - 90% are superior
- VH occurs in **13-19%** of symptomatic PVD's
- **VH + PVD -> 70% will have a retinal break**
- PVD No VH -> 2-4% will have retinal break



28



29

Exam of a Patient with Symptomatic PVD

- Should have a high suspicion of detecting Weiss ring
- Should have a high index of suspicion of a possible retinal break
- Clinical exam should be conducted with these suspicions

30

Clinical Exam of a Patient with A Symptomatic PVD

- All the testing and procedures that you would normally do with any patient
- Dilated fundus exam
- Look specifically at the anterior vitreous
 - Note presence or absence of pigment or cells in the anterior vitreous
-> tobacco dust, schaffer's sign
- Peripheral extended ophthalmoscopy including scleral depression

31

Symptoms of Flashes... PVD **NOT** Seen

What is your management?

Return with in 3-4 weeks

32

Symptoms of Flashes... PVD **is** Seen

What is your management?
Do you bring him back for follow up?

33

Management of Acute PVD

With Symptoms

- Educate about the Si/Sx of RD
- Return in ~ **4 weeks**, then 3-4 months, then annually

34

Indications for referral

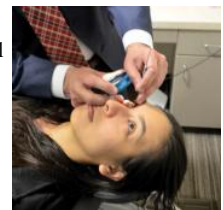- Not comfortable with indirect ophthalmoscopy
- Presence of pigment or blood in the vitreous
 - **If you don't see a retinal tear – go back and look again**
- Layering of blood on the retina
- Presence of a retinal tear
- RD

35

Examining the Retina

The peripheral retina

- It has to be done through a dilated pupil
- Don't substitute imaging for indirect ophthalmoscopy
 - Use Imaging as a compliment, but not substitute
- Be systematic in your examination
- You should be able to see ora on "all" gazes



36

What is the time frame that she needs to be treated before it affects the final visual outcome?

- A. Within 24 hours
- B. Within 3 days
- C. Within 7 days
- D. Within 14 days

37

Predictive Factors for Poor Visual Outcome

Impact of the Time to Surgery on Visual Outcomes for Rhegmatogenous Retinal Detachment Repair: A Meta-Analysis



AJO 2022

AMIRTHAN SOTHIVANNAN, ARSHA ESHTEGHI, ARIAN S. DHOOT, MARKO M. POPOVIC, SUNIL J. GARG, PETER J. KERTES, AND RAHEV H. MEINI

- Initial presenting visual acuity – worse visual acuity
- Duration of the macular detachment
 - Longer the mac-off RD -> worse the visual outcome
- Height of the retinal detachment

38

Timing of Macula-Off RD Surgery

- Best visual outcomes are when the surgery is performed within **7 days** of the macular detachment
- Meta-analysis have shown that a delay of **more than 3 days** was associated with statistically worse final visual outcome
 - Eyes that had surgery within 3 days averaged a final visual acuity of around 20/30
 - Eyes that were operated between 4-7 days averaged a final visual acuity of around 20/70.

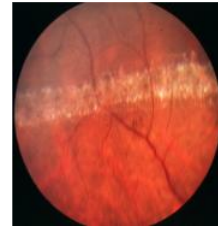
AJO 2022

39

Lattice Degeneration as a Routine Finding?

Is this any cause for concern?

How do you manage it?



40

Lattice Degeneration and Risk of RD

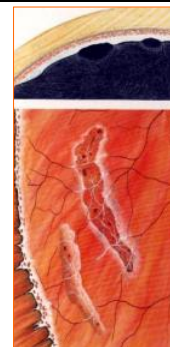- RD develop in **0.7%** of eyes with lattice degeneration followed for 10.8 yrs
- Eyes with lattice that developed tractional retinal tears
 - 40% occurred in areas not associated with lattice...normal-appearing retina

Byer NE. *Ophthalmology*. 1989; 96:1401-1402

41

Lattice Degeneration

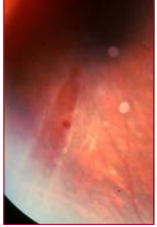
- Present 5-20% of the general population
- Localized area of retinal thinning associated with a fluid pocket in the overlying cortical vitreous



42

Indications for Prophylactic Treatment of Peripheral Retinal Tears and Holes in **Symptomatic** Patients


	<u>Treat</u>
• Horseshoe tears	Yes
• Operculated holes	Rarely
• Atrophic holes	No



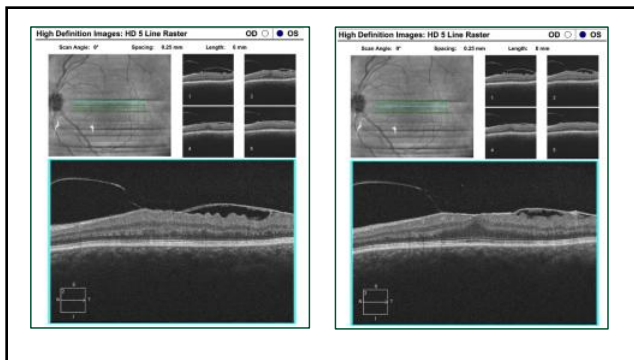
43

58 yo White Male

- Hit in the LE with a tennis ball 2 weeks ago and immediately started to see a floater in the LE
- The floater is now gone
- Hx of RLS (MF IOL's OU)
- Va: RE 20/20; LE 20/25
- No PVD is seen in the LE



44



45

Consults in Retina

- ERM LE – 2025
 - Is this visually significant?
 - Referral to retina?
- No PVD is visible but is also No longer symptomatic...
- What's next?

46

58 yo White Male: Floater after Tennis Ball Injury; Incidental Finding of ERM

Assessment

- 1) New onset floater LE following trauma with a tennis ball
 - No longer sees the floater
 - No PVD seen
 - No break or tear
- 2) ERM LE - likely incidental finding and responsible for 20/25 VA
 - Slight retinal thickening, no IRF o
- 3) Hx of Pseudophakia with I/F IOL OU (for refractive purposes)
- 4) Hx of LPI OU (per pt) - likely PACG suspect
 - Father blind at 30 from GL
 - Normal IOP
 - No ON cupping
- 5) Choroidal folds RE

Plan

- 1) Ed and reassure
- 2) SSRD explained
- 3) RTC - 3-4 mo for retina follow up for ERM LE

47

When is an ERM worthy of a retinal consult?

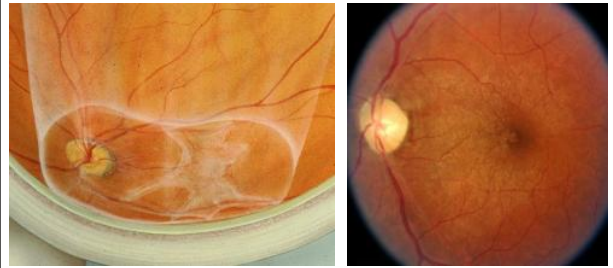
- Intolerable **symptoms**
- IRF/CME

48

What is the OD's Role in Managing Patients with ERM?

- Immediate referral
- Follow for resolution
- When do these patients get treated?

49



50

Epiretinal Membrane (ERM)

- Translucent or semitranslucent, fibrocellular membrane seen on the inner retinal surface
- **80-90% seen with PVD**
- May contract or shrink, producing varying degrees of distortion, intraretinal edema, and degeneration of the underlying retina

51

Epiretinal Membrane (ERM)

- Symptoms: blurred VA, distortion, metamorphopsia
- Cause: poorly understood - PVD ?
- Contraction may produce macular pucker or pseudohole

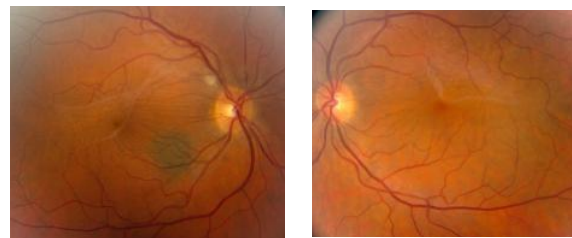
52

Managing ERM

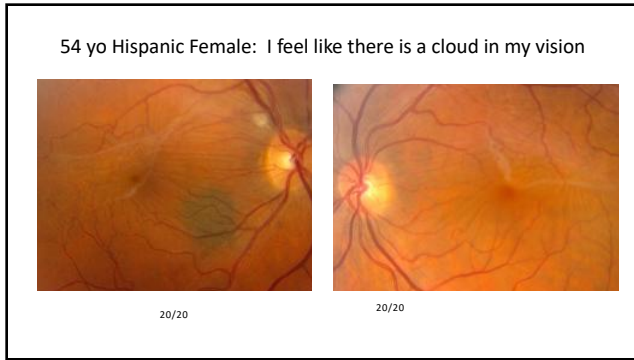
- Determine how symptomatic
- The presence of **metamorphopsia, distortion** is a good gauge for determining when to refer for consideration of vitrectomy
- OCT very helpful in quantifying the amount of retinal thickening
 - The presence of CME

53

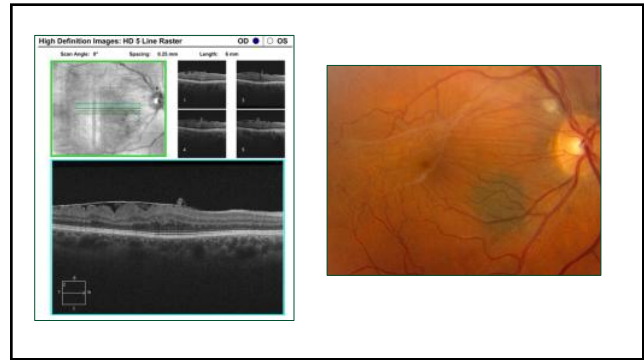
54 yo Hispanic Female: I feel like there is a cloud in my vision



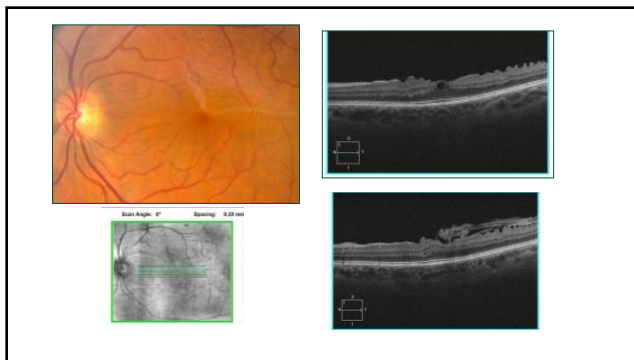
54



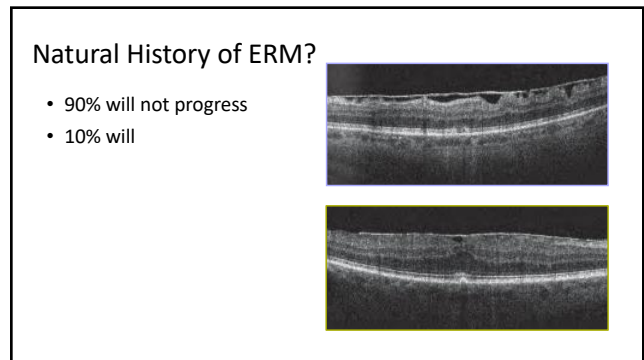55



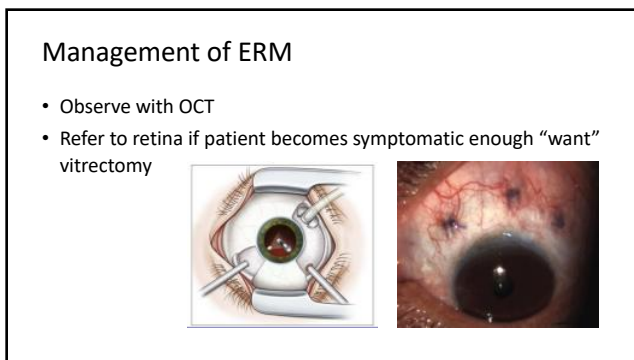
56



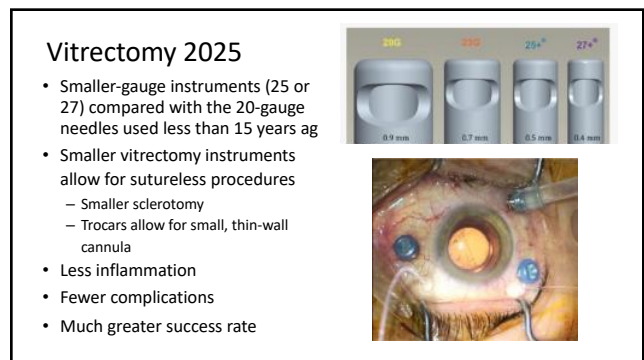
57



58



59



60

Pay Attention to the Vitreoretinal Interface

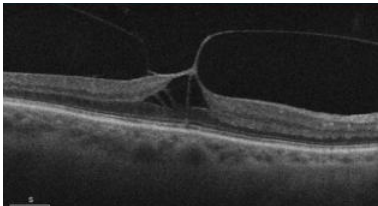
61

5 Diseases Arising from Abnormalities in the Vitreomacular Interface (VMI):

- Epiretinal membrane (ERM)
- Vitreomacular traction (VMT)
- Full Thickness macular hole (FTMH)
- Lamellar macular hole
- Myopic macular schisis

62

Does VMT Require a Retinal Consult?



63

Vitreomacular Traction in the Era of OCT

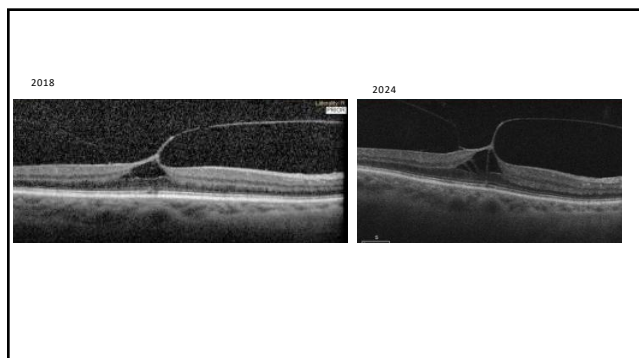
- Not rare!
- A group of disorders caused by incomplete PVD
- Leads to persistent traction on the macula
- Produces in most cases CME and decreased visual acuity
- Can be idiopathic
- Can result in full thickness macular hole formation
- Can occur with ERM

64

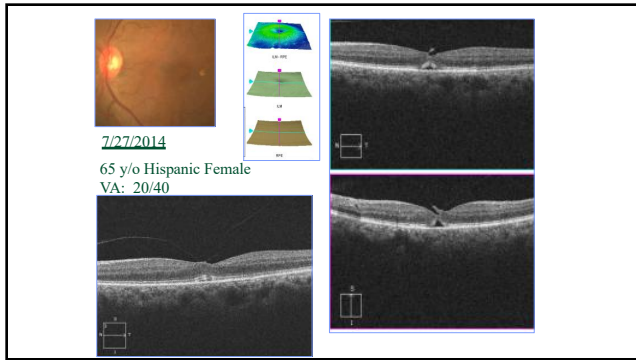
Does VMT Require a Retinal Consult?

- It depends
- Level of Va
- How symptomatic is the patient?

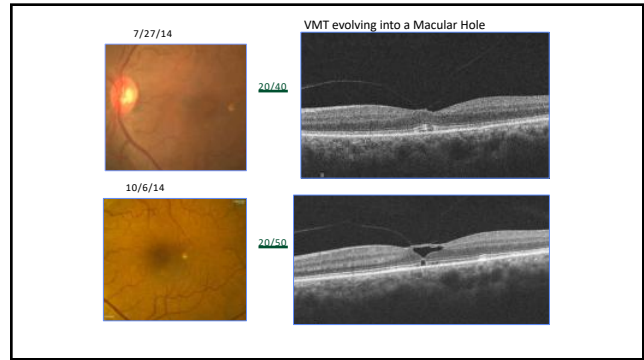
65



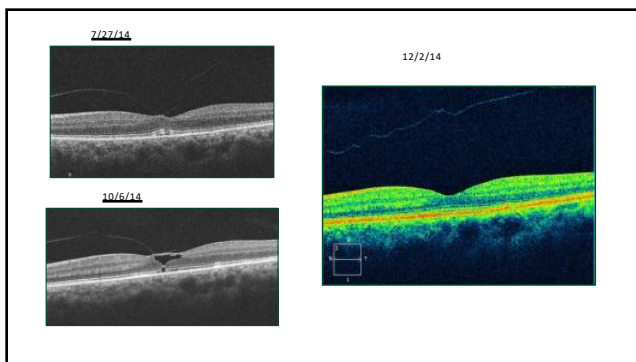
66



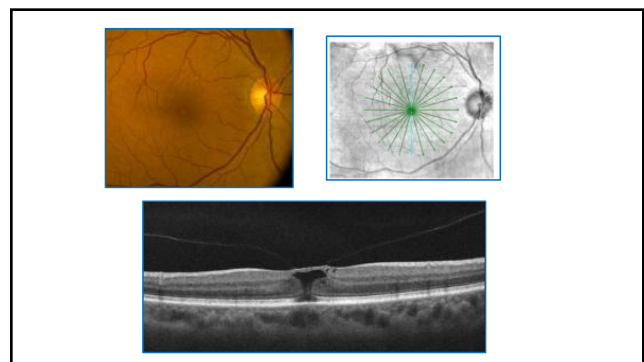
67



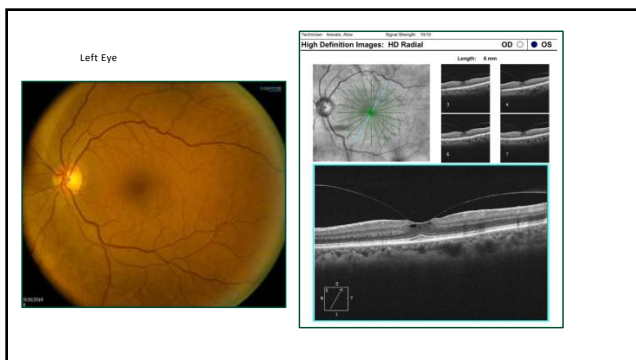
68



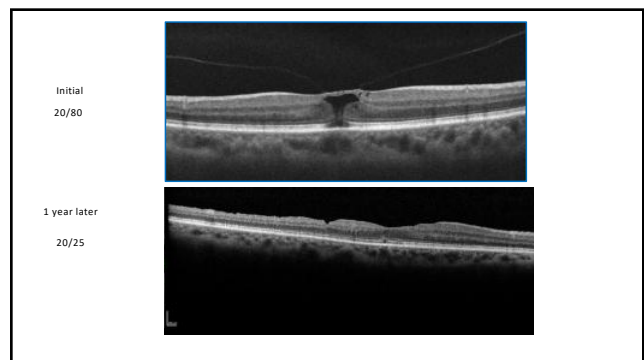
69



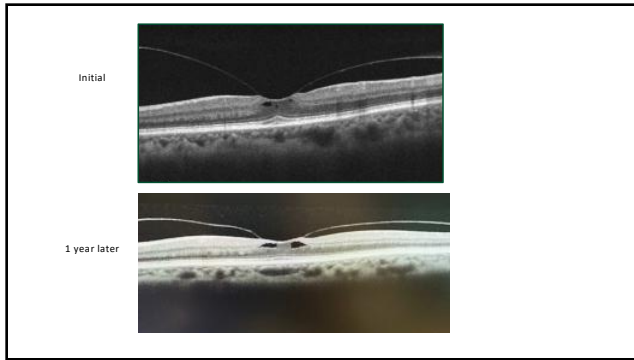
70



71



72



73

VMT

- Seems to be more cases of VMT then ever before
- Likely due to more primary care OD providers have OCT's
 - Being diagnosed more

74

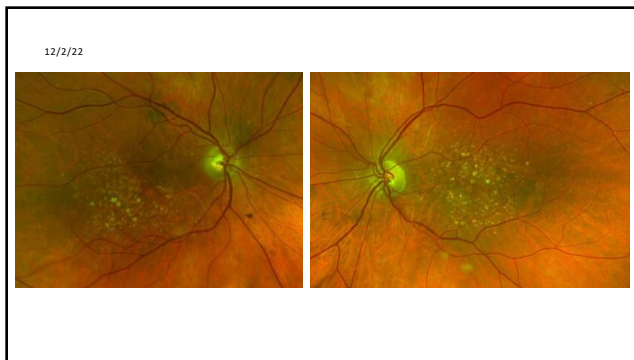
Consults in Retina:
The Macula

75

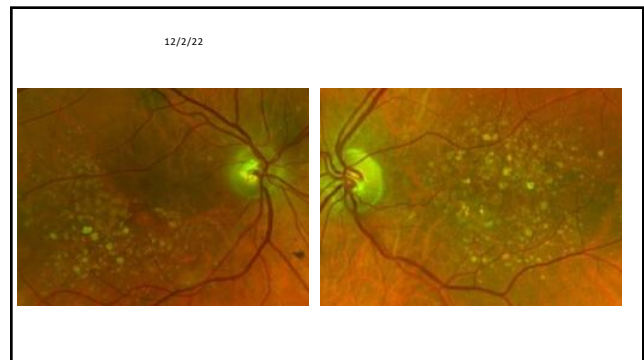Consults in Retina: The Macula

- What is your comfort level in managing (in your office) macular disease?
- When do you refer patients with macular pathology to a retinal specialist?

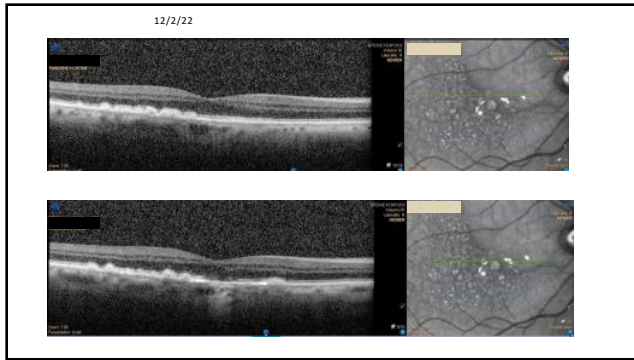
76



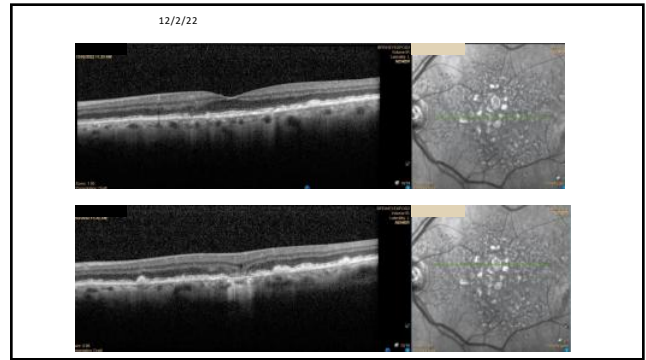
77



78



79



80

Dry AMD

- What stage?
- OCT imaging is essential
 - Though not required especially for early AMD

No AMD	<ul style="list-style-type: none"> • None or few drupelets (small drusen $\leq 63 \mu\text{m}$) • No AMD pigmentary abnormalities
Early AMD	<ul style="list-style-type: none"> • Medium drusen $> 63 \mu\text{m}$ and $\leq 125 \mu\text{m}$ • No AMD pigmentary abnormalities
Intermediate AMD	<ul style="list-style-type: none"> • 1 large drusen $> 125 \mu\text{m}$ and/or • Any AMD pigmentary abnormalities
Advanced AMD	<p>2 forms</p> <div style="display: flex; justify-content: space-around;"> <div style="text-align: center;"> <p>Geographic atrophy</p> </div> <div style="text-align: center;"> <p>Neovascular AMD</p> </div> </div>

81

78 yo White Male: Followed every 6 mo for Intermediate Dry AMD

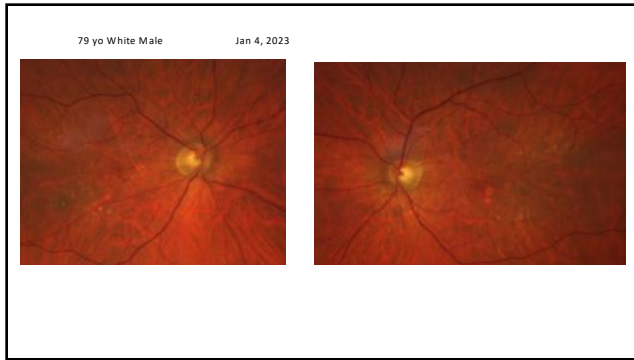82

1 year Later: 1/4/23

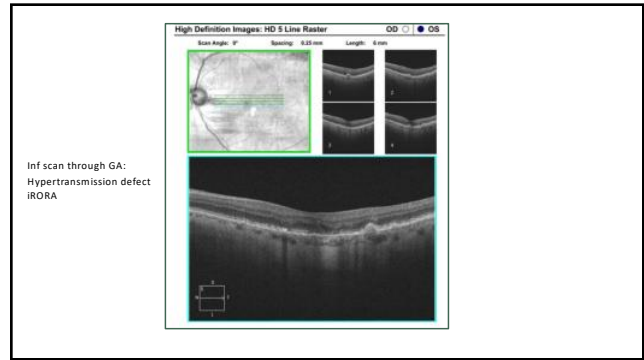
83

1/10/22 1/4/23

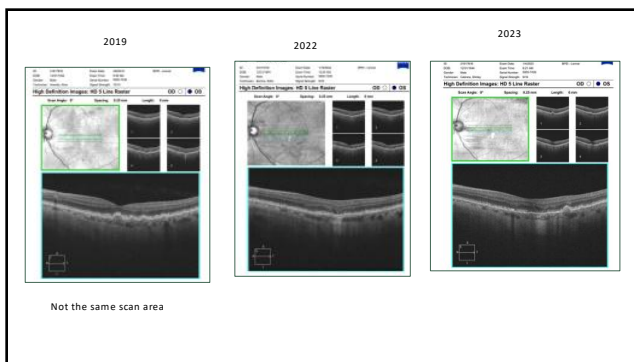
84



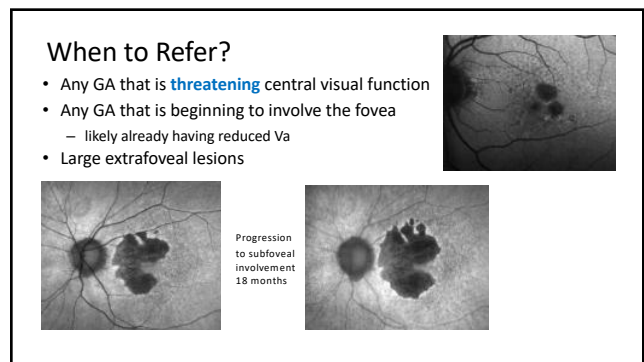
85



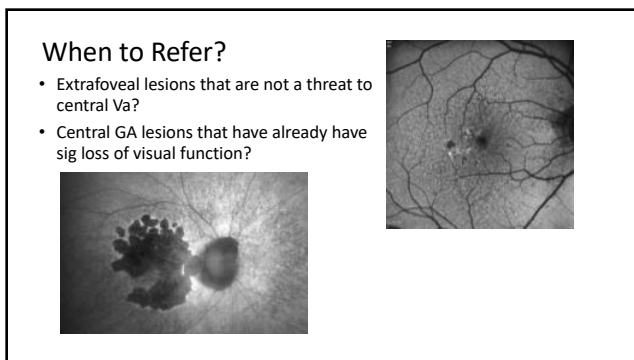
86



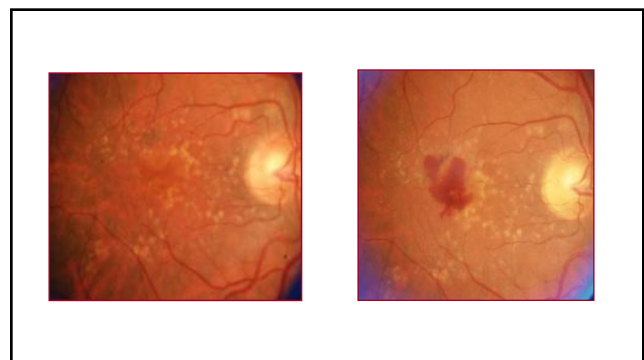
87



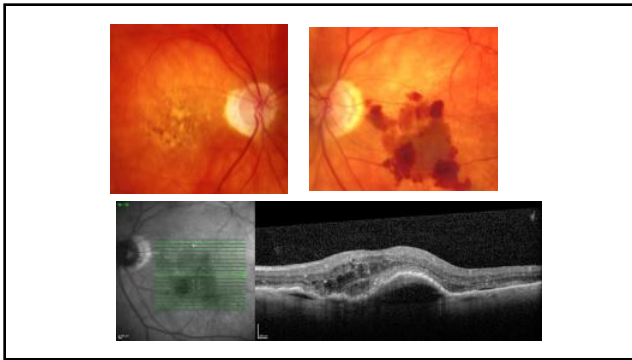
88



89



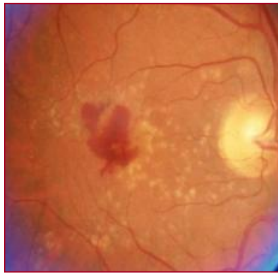
90



91

Wet AMD

- Subretinal hemorrhage
- Drusen changes



The fundus photograph shows a retina with a large, dark, subretinal hemorrhage and several yellowish drusen deposits, characteristic of wet age-related macular degeneration.

92

Consults in Retina: AMD

Absolute Referrals

- ANY suspicion of conversion from dry to wet
- ANY visual threatening geographic atrophy (GA)
 - What is visual threatening?

93

Consults in Retina: AMD

Maybe/Consider Referrals

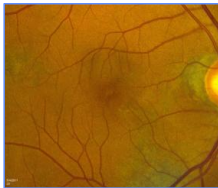
- Not comfortable ...or the patient isn't comfortable
- Insurance coverage
- Don't have technology

94

Occult Macular Disease

- What is occult macular disease?
 - Anything that is not "typical"
 - Unexplained reduced VA
- Examples of occult macular disease
 - Old/chronic CSR
 - Old trauma
 - VMT
 - Hereditary retinal disease
 - Pattern dystrophies

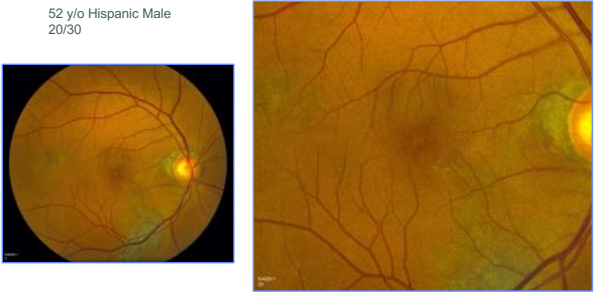
52 yo Male; 20/30



The fundus photograph shows a retina with a subtle, well-circumscribed lesion in the macula, characteristic of occult macular disease.

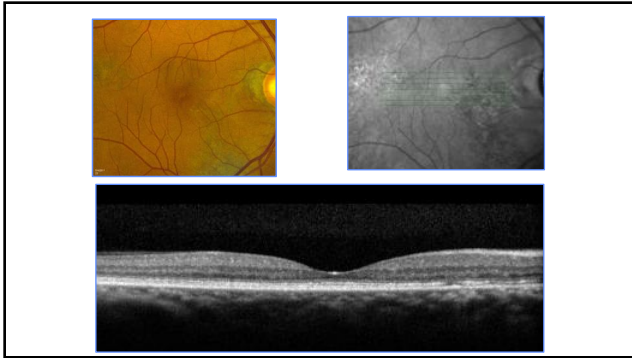
95

52 yo Hispanic Male
20/30

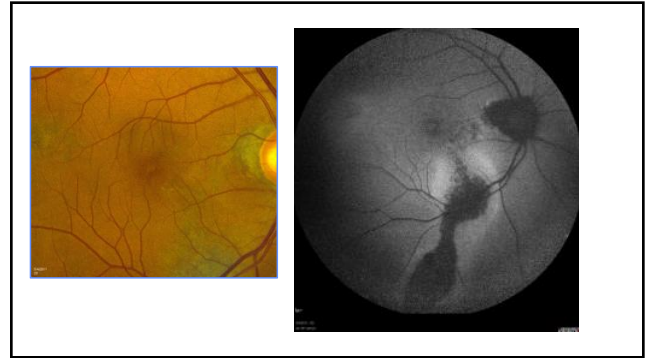


The two fundus photographs show a retina with a subtle, well-circumscribed lesion in the macula, characteristic of occult macular disease.

96



97



98

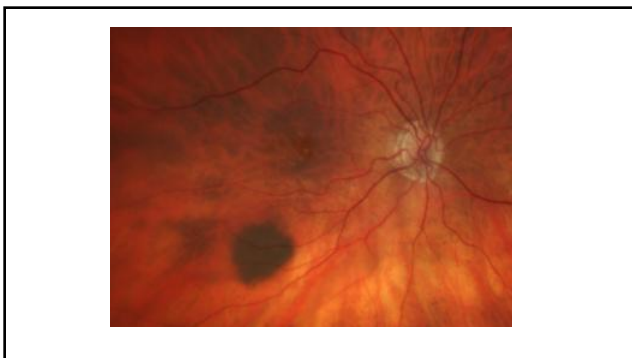89 yo White Male

- Presents 4/2/25 for annual follow up with complaint of watery eyes
- He was seen exactly 1 year earlier (4/3/24) and before that 2021
 - Had cataract surgery 2022 by outside provider (Baptist)
- VA: 20/20 each eye
- Anterior segment unremarkable -> MGD, gutta, PCIOL's

99

My Extern tells me:
 “the patient has a choroidal nevus, is this significant...?”

100



101


89 yo Pseudophakic with Watery Eyes

- He has a blatantly obvious pigmented choroidal lesion
- Has been seen twice before at our institution by 2 different providers
- Has been seen by an outside provider for cataract surgery (probably more than once)
- He has never been told (nor has it been recorded) that he has a pigmented lesion in his retina

102

Consults in Retina: Evaluating a Pigment Lesion in the Retina

Never-before-seen pigmented choroidal lesion in an 89 yo patient



Has it always been there...but just missed


Or

Is this new – and potentially a choroidal melanoma?

103

Choroidal Nevi

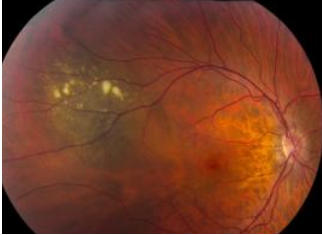
- < 3 mm elevation
- < 3 DD in size
 - 95% are less than 2 DD
- Slate gray
- Drusen
- SRF associated with drusen
- CNVM



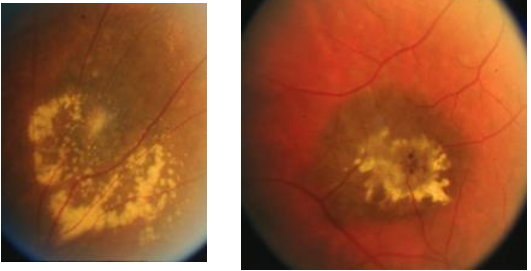
104

Features Suggesting Nevi

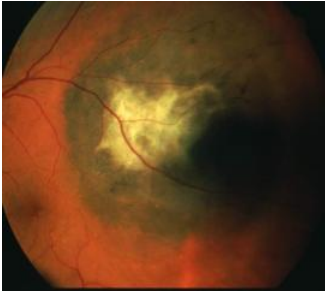
- Drusen
- Overlying neurosensory detachment
- Choroidal neovascular membrane
- Circinate exudate
- Bony pigment spicules
- Zones of RPE atrophy



105



106



107

Assessment and Plan

Dry eye syndrome of both eyes 2/2 MGD and blepharitis

- Use preservative-free artificial tears (recommend Refresh Mega-3, Systane, Thera Tears) 4-6x daily in both eyes.
- Apply a warm compress to the eyelids for 10 to 20 minutes at least twice a day. (Recommend Bruder's mask, Basch & Lomb Therapear, Rimex Ice & Fire mask, may also use warm washcloth).
- Eyelid cleansing 1-2x daily (recommend Thera Tears Sterlid Foaming Cleanser, Citradex light foam, OcuSoft HypoChlor, may also use diluted baby shampoo)

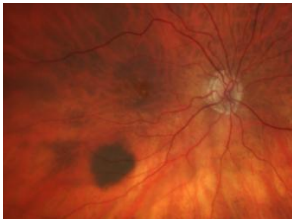
Dry AMD OU

Pseudophakia OU (Bill Tratter) with excellent visual results

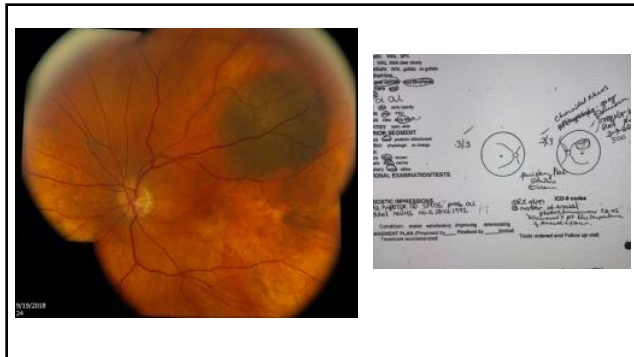
Choroidal nevus OD, smaller Ch nevus LE

- Never noticed before
- Flat, no HRC

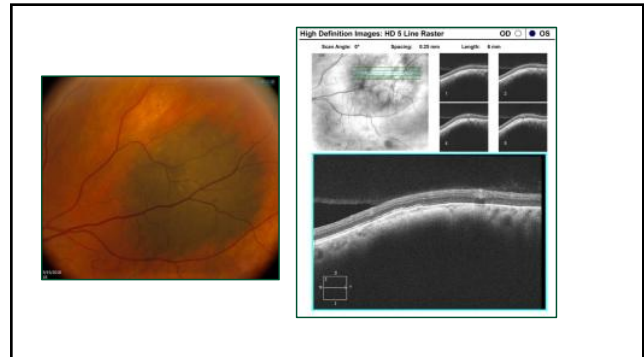
RTC 3 mo



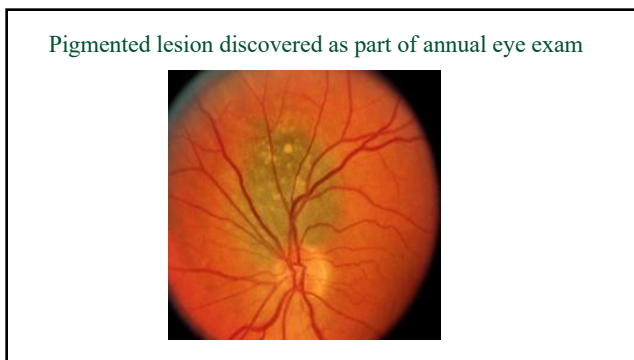108



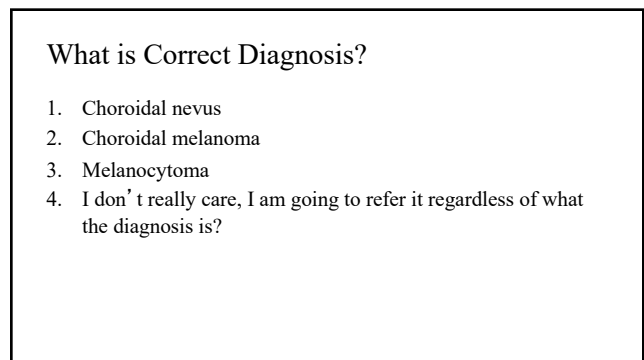
109



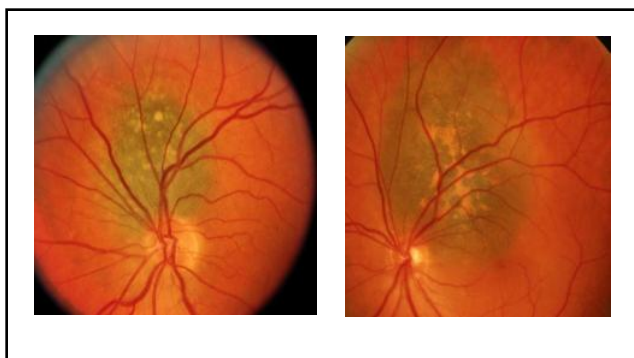
110



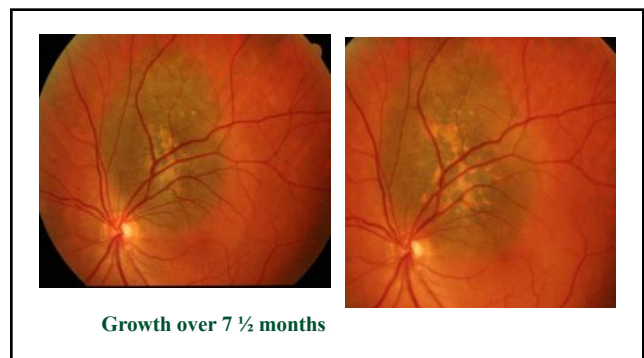111



112



113

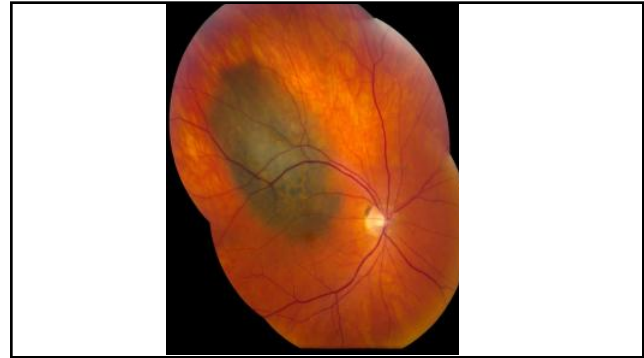

114

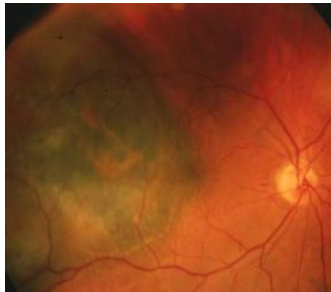
Choroidal Melanoma

- >3 mm elevation
- Variable pigment
- Multiple areas of orange pigment (lipofuscin)
- Serous fluid (detachment) in absence of drusen
- **Unequivocal evidence of growth**

115

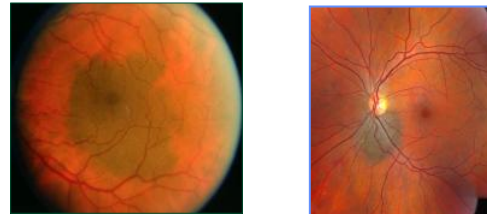


116



117

Do Choroidal Melanoma's Develop from Pre-Existing Choroidal Nevus



118

Long term ultrasonic follow up of choroidal nevi and their transformation to melanomas

Br J Ophthalmol 2006;90:8 994-998 Published Online

- 659 consecutive eyes with choroidal nevi examined between 1984 and 2004
 - **165 clinically suspicious nevi** were followed clinically w ultrasound
- 17 choroidal nevi (2.6% of all nevi, **10.3% of suspicious nevi**) converted to small choroidal melanoma
- 1.5 years of follow up were necessary to statistically distinguish between premalignant and benign nevi
- **No nevus smaller than 1 mm thickness converted to melanoma**
- A thickness of ≥ 2 mm and a LBD ≥ 7 mm were most predictive of conversion to melanoma

119

Consults in Retina: "Suspicious" Choroidal Nevus When to Refer?


- Anything that is NOT flat
 - Any time there is thickness or elevation of a pigment lesion
- The presence of orange -> lipofuscin
- Subretinal fluid
- Change over time

120

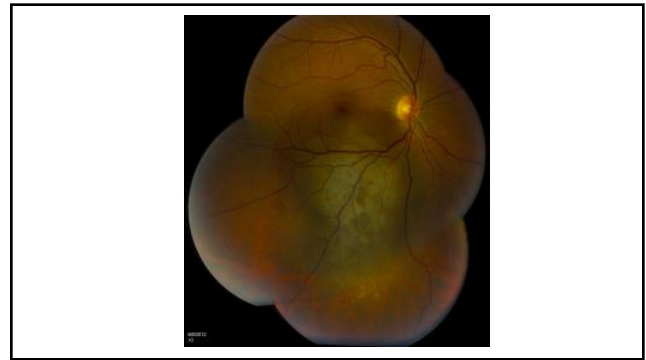
37 y/o Middle Eastern American Radiologist

Presented on Monday for a refraction

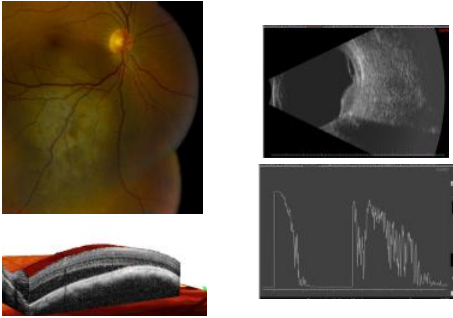
Blurry vision OU



121



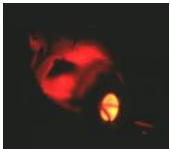

122



123

Plaque Radiation (Ionizing Radiation)

- Iodine-125
- Seeds of radioactive material implanted into a plaque
- Sewn onto the globe and left on for 3 d
- Dosage: 8-10 rads reach apex, 40-50,000 reach the base

124

COMS Results: Medium Tumors

- Unadjusted 5 yr survival: 81% vs 82%
- 5 year **adjusted rate of death** from metastatic melanoma:
 - 11% Enucleation
 - 9% Plaque
- Conclusion: Mortality rates do not statistically differ b/w the 2 treatments for up to 12 years

Arch of Ophthalmol July 2001 119(7):969-982

125

COMS Results: Medium Tumors

- Baseline Visual Acuity:
 - Median VA: 20/32
 - 70% with $\geq 20/40$, 10% $\leq 20/200$
- 3 yrs **Post I₁₂₅ plaque**
 - Median VA: 20/125
 - 34% $\geq 20/40$; 45% $\leq 20/200$
 - 43-49% impairment in VA (> 6 lines of acuity loss from pretreatment)

Ophthalmology Feb 2001 108(2):348-366

126

Large Choroidal Melanomas COMS Report # 10

Pre-enucleation Radiation vs Enucleation

- Total 435 deaths classified by Mortality Coding Committee
 - 269 had histologically confirmed melanoma metastases (166 died from other causes)
- 5 yr survival = 72% Enuc vs 74% PERT
 - No statistical survival difference b/w 2 groups

Initial Mortality, COMS Report # 10 AJO June 1998

127

Molecular Genetics of Ocular Melanomas

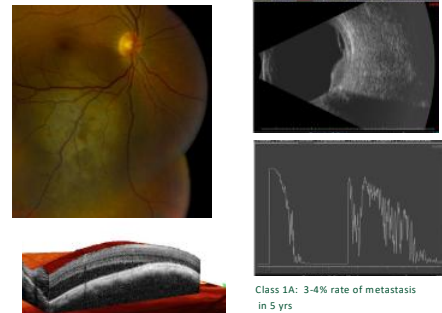- Discoveries in molecular genetics have established that there are 2 classes of tumors with distinct molecular signatures
- Class 1 -> carries a low risk of metastasis - less than 10%.
- Class 2 -> greater than 90% chance of spreading to the liver.

128

Molecular Genetics of Ocular Melanomas

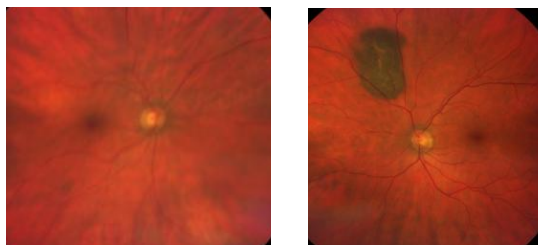
- Via fine needle biopsy transcriptomic profiling can be done which can accurately predict which tumors will likely go on to develop metastatic disease and which won't...
- This risk may be independent of what type of treatment that patient may have had

129

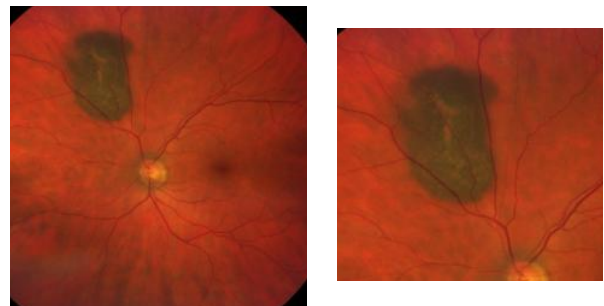


130

68 yo White Male: Works at UM: December 4, 2024
In for comprehensive exam: Hx of corneal trauma RE and never good vision



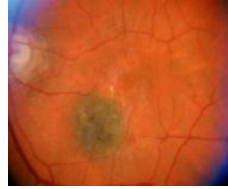131



132

Management

- Flat choroidal nevi: follow yearly
- Suspicious nevi:
 - photo
 - follow in 6 wks, 3 mo, then 6 mo
 - evidence of growth -> early melanoma
- Lesions > 3 mm thickness: probably early melanoma



133

Consults in Retina: The Patient with Diabetes

- 52 yo BM: Annual Diabetes Eye Exam
 - Has had T2D for ~ 7 years; on an oral medication
 - Was last seen 1 yr ago without any DR
- Doesn't have any visual complaints: 20/20 each eye
 - Today: A1C 6.9
- 20/20 each eye

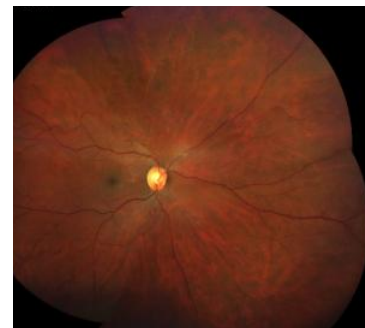134

His Exam 1 year ago (March 2024)

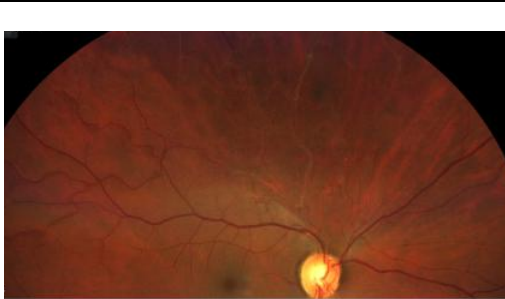
Slit Lamp and Fundus Exam			
External Exam:			
Visuals	Right	Left	
	Normal	Normal	
Slit Lamp Exam:			
Slit Lashes	Right	Left	
Conjunctiva/Sclera	No injected sclera	No injected sclera	
Cornea	Trace keratic	Trace keratic	
Anterior Chamber	Deep and quiet	Deep and quiet	
Iris	Flat and well formed () () ()	Flat and well formed () () ()	
Lens	Trace NS	Trace NS	
Fundus Exam:			
Disc	pink disc with good rim, slightly oval () hemorrhages, NVD	pink disc with good rim, slightly oval () hemorrhages, NVD	
Optic Nerve	OK	OK	
Macula	Normal	Normal	
Vessels	Normal	Normal	
Periphery	Normal, no DR	Normal, no DR	

Assessment:
Type 2 DM without Retinopathy
 - No retinopathy noted today
 - slightly large discs ()
Myopia of Both Eyes with Astigmatism and Presbyopia
 - Updated specs rx
 - Patient prefers PALS
Dry Eye - MGD
 - Trace PEE OU
 - Educated on importance of discontinuing Vasine and using Artificial tears as needed
Plan
 ED and measure
 OD control
 Annual Exam
 AT as needed for dryness
 Rx for specs - ok to wear OTC readers

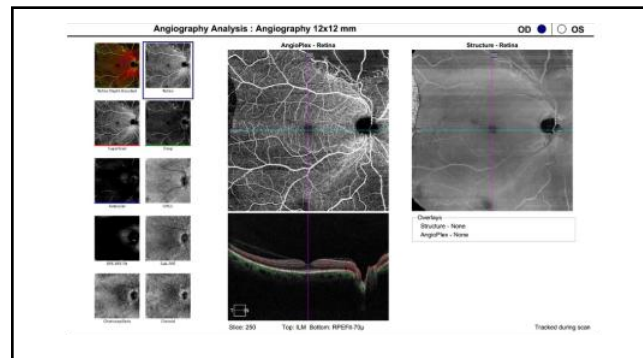
135



136



137



138

52 yo BM 1 yr follow up for DR Evaluation

Assessment

- Resolving BRVO RE
 - Likely ischemic
 - Suspicious area of NVE without fibrovascular proliferation
- T2D without retinopathy

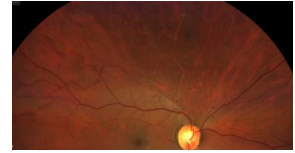
Plan

139

52 yo BM 1 yr follow up for DR Evaluation

Assessment

- Resolving BRVO RE
 - **Likely ischemic**
 - Suspicious area of NVE without fibrovascular proliferation
- T2D without retinopathy



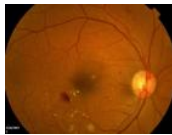
Plan

- Should be seen within 3 months (could be sooner)
 - Would benefit from wide-field FA
 - Most retina specialist wouldn't treat now

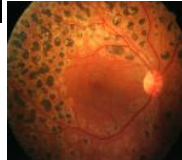
140

Consult of the Patient with Diabetes

- CI-DME
 - Non CI – DME?
- PDR
- ? More than Moderate



- Stable PDR following laser?



141