


# Brachycephalic Syndrome: Innovative Surgical Techniques



**Laurent Findji, DMV, MS, MRCVS, DECVS**  
*VRCC Veterinary Referrals*  
*Essex, United Kingdom*

**Gilles Dupré, DMV, DECVS**  
*University of Veterinary Medicine, Vienna*  
*Vienna, Austria*

**C**anine brachycephalic syndrome (BS) consists of anatomic abnormalities (eg, stenotic nares, tortuous nasal cavities, aberrant conchae, elongated soft palate [ESP], everted laryngeal sacculae, laryngeal collapse, tracheal hypoplasia) of brachycephalic dogs, which can lead to obstructive dyspnea and digestive disorders. In one study, 97% of brachycephalic dogs presented for BS had concurrent GI diseases.<sup>1</sup> Upper obstructions (eg, nares, conchae, soft palate) may aggravate and sometimes cause deeper obstructions (eg, laryngeal, tracheal, bronchial collapses) and digestive disorders.

Early surgical correction of these abnormalities is often recommended and commonly includes treatment for stenotic nares and ESP. Other abnormalities (eg, laryngeal collapse<sup>2</sup>) occasionally require surgical attention but rarely in first intention. ESP, the most consistent anatomic abnormality encountered in dogs with BS, has been reported in up to 100% of cases.<sup>3,4</sup> Initially, ESP was primarily described as excessive soft palate length, which can cause obstruction of the rima glottidis on inspiration (laryngeal obstruction). However, in many brachycephalic dogs, it has long been observed<sup>5-11</sup> and recently demonstrated<sup>12,13</sup> that the soft palate is also excessively thick, adding nasopharyngeal and oropharyngeal components to airway obstruction.

Folded flap palatoplasty (FFP) was developed to address the three components of obstruction caused by the soft palate by making it both thinner and shorter.<sup>8,9-11</sup> Stenotic nares, when present,

should be corrected following FFP. Various techniques have been described, but the authors prefer vertical wedge alarplasty, which consists of excising a vertical wedge from the ala nasi.

## Comparing Traditional & Innovative

Conventional surgical techniques for ESP correction often consist of a simple resection of the redundant portion of the soft palate using different devices and various resection landmarks; although these techniques address the laryngeal component of obstruction, they may fail to fully address nasopharyngeal and oropharyngeal obstructions.<sup>14-26</sup> FFP can address all components of the obstruction by reducing the soft palate's length and thickness. The use of bipolar cautery in FFP increases intraoperative comfort. Compared with conventional staphylectomies, the suture material is more rostral and therefore farther from the pharynx, which should result in less postoperative pharyngeal inflammation and edema. Also, the rostroventral traction exerted on the remainder of the soft palate tends to further widen the nasopharyngeal opening. FFP tends to be longer and more technically demanding than conventional staphylectomy.

MORE ►

Before surgery, the patient should be premedicated (see **Premedications to Consider**) and stress avoided. Before anesthesia induction, oxygen can be supplied by mask or flow-by. Induction must be swift to allow prompt control of the airway via tracheal intubation. The pharynx should be examined and the larynx assessed for signs of laryngeal collapse.

### Premedications to Consider

- Acepromazine (0.01–0.05 mg/kg IM, SC)
- Dexamethasone (0.1–0.2 mg/kg IM, SC)
- Opioid analgesic (eg, morphine or methadone, 0.2–0.5 mg/kg IM)
- Glycopyrrolate (2–10 µg/kg IM)
- Antiemetics & antacids (SC or IM, depending on drugs)

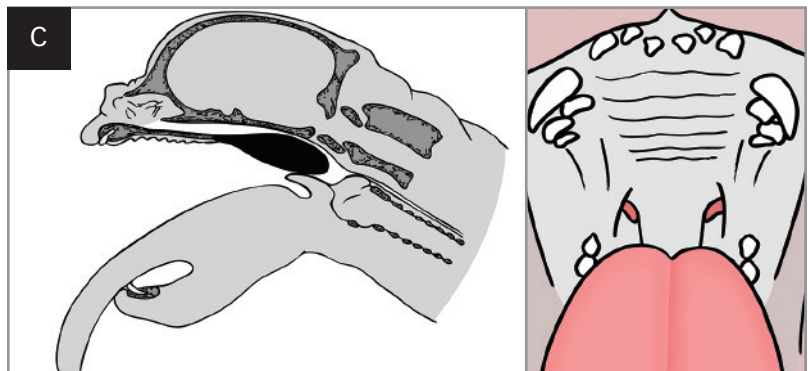
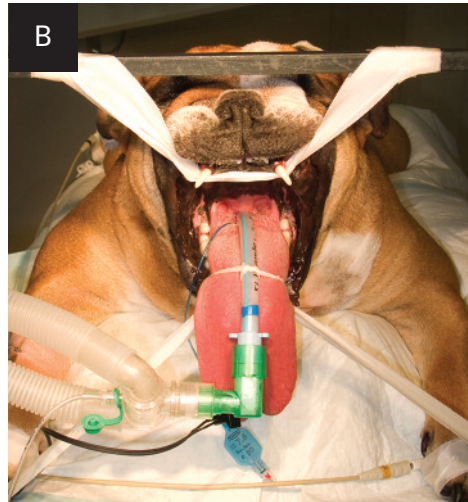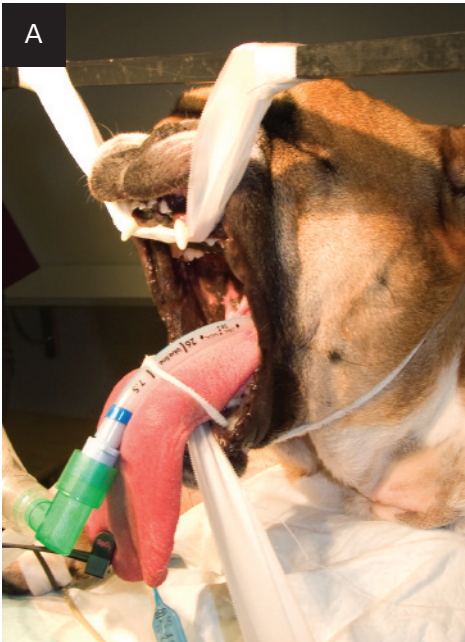### What You Will Need:

- Basic surgical kit
  - Long instruments to facilitate the procedure in small dogs with narrow pharynges (eg, pugs)
- Electrocautery
  - Precise monopolar cautery used in cutting mode for the initial palatoplasty incision
  - Bipolar electrocautery to facilitate hemostasis during the dissection of the soft palate
- Absorbable monofilament sutures on swaged round or tapercut needles, size 3-0–5-0

## Step-by-Step ■ Folded Flap Palatoplasty

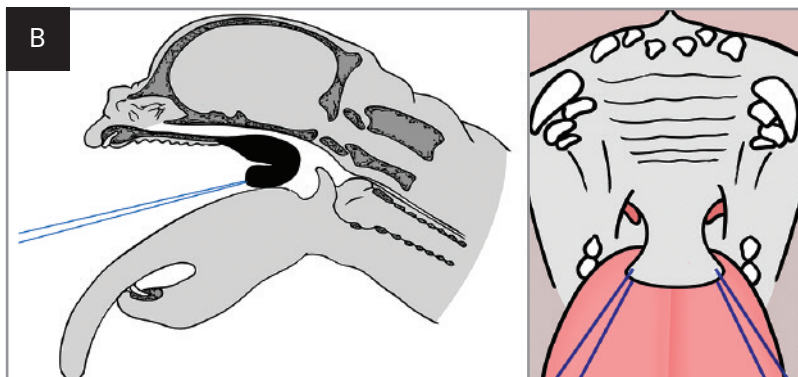
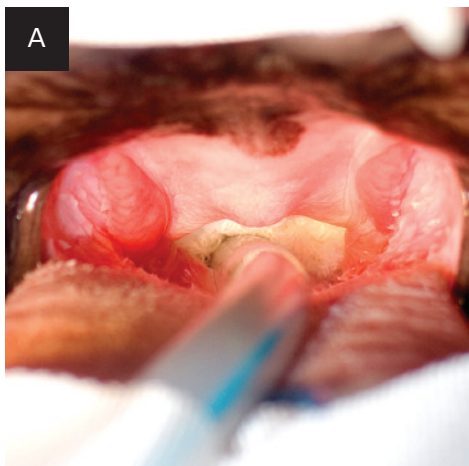
### Step 1

Place the dog in sternal recumbency. Restrain the head with the mouth open and the tongue gently pulled and fixed rostrally (A, B, C).



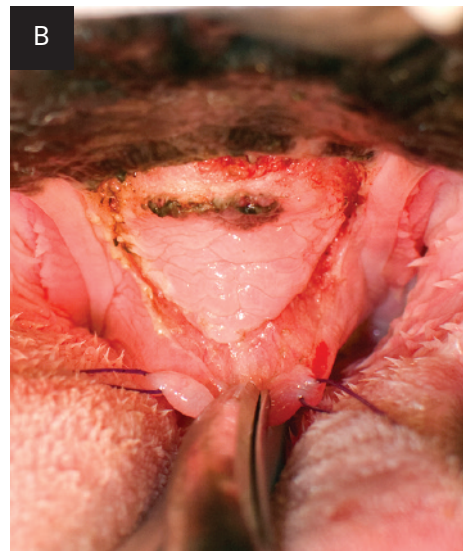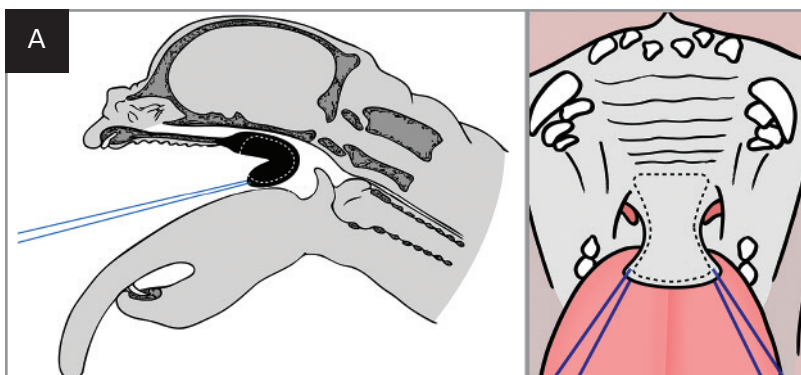
### Step 2

To prepare the oral cavity for surgery, pack the deep portion of the pharynx with swabs to prevent blood from reaching the glottis (A), and place stay sutures on each side of the caudalmost part of the soft palate (B).



### Step 3

Rotate the caudal border of the soft palate rostrally until the caudal opening of the nasopharynx is directly visible (A). Apply the retracted caudal edge on the ventral mucosa of the soft palate and mark the point to which the free border of the palate can be brought rostrally with a point of electrocautery. Incise the ventral mucosa of the soft palate in a trapezoidal shape from this mark rostrally to the free edge of the soft palate caudally (B).

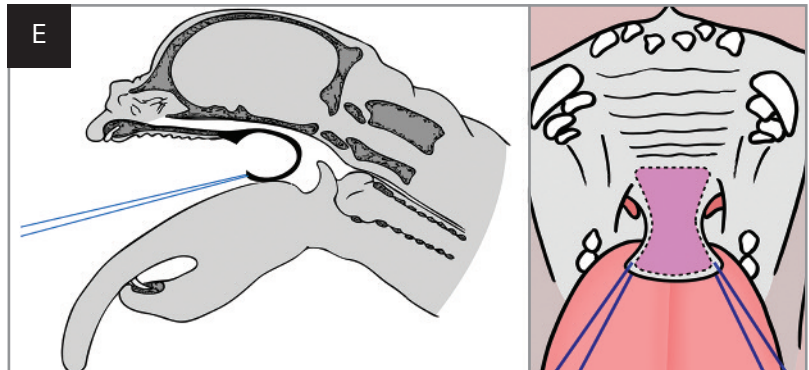
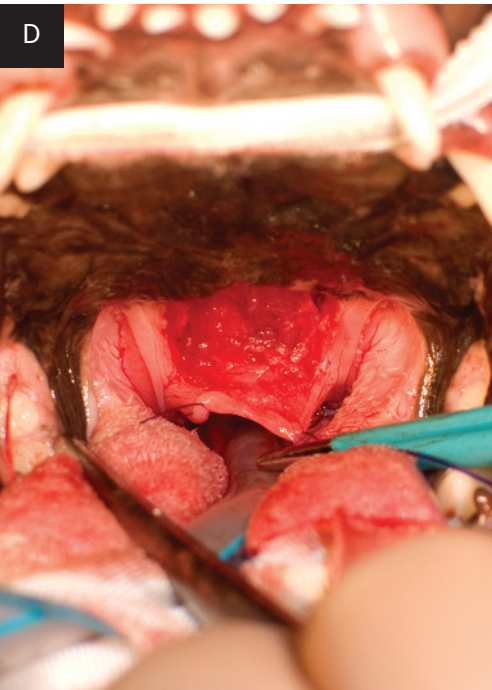
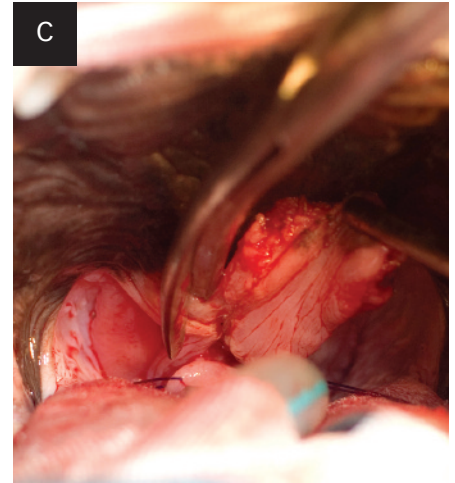
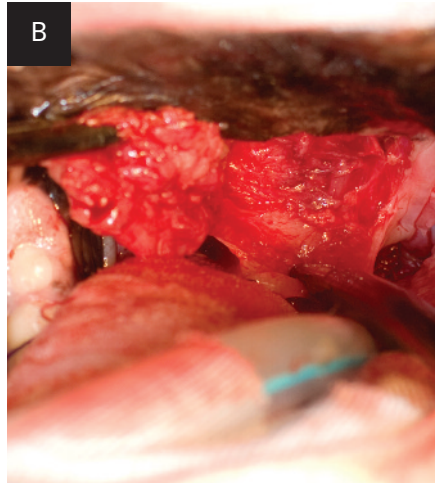
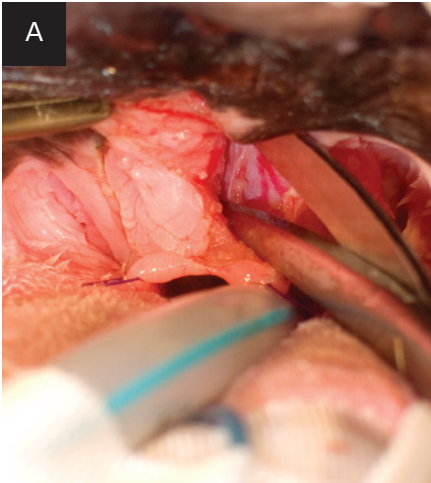


**Author Insight** Laterally, the sides of the trapezoid pass just medially to the tonsils.

MORE ►



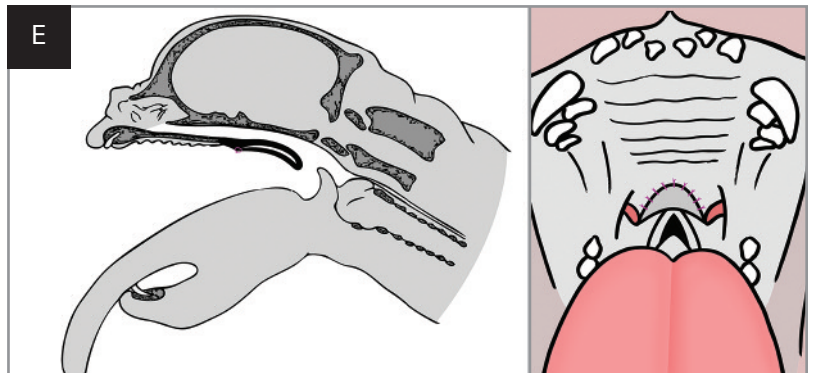
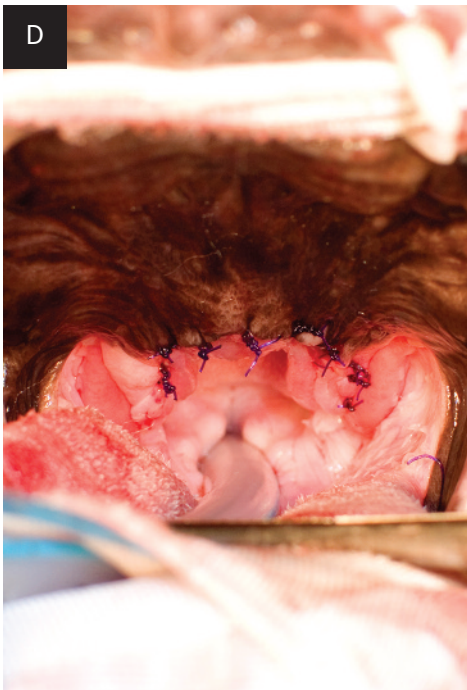
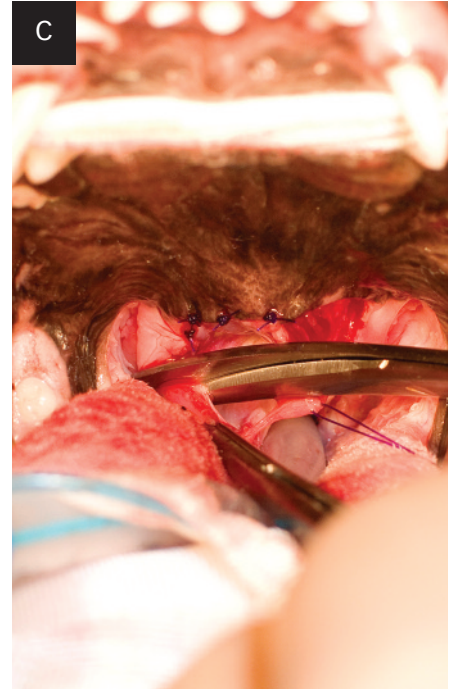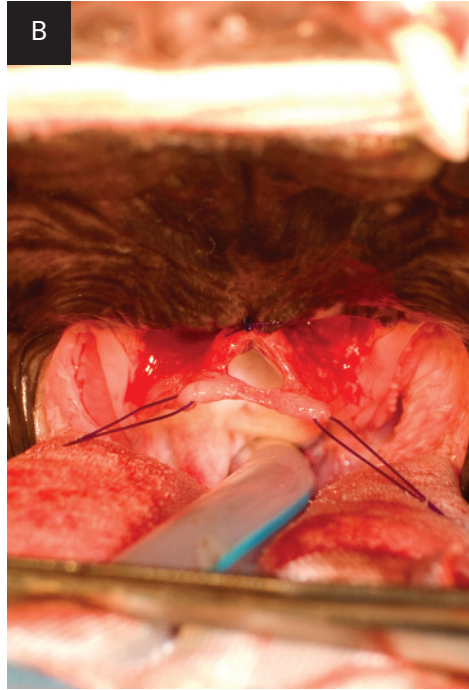
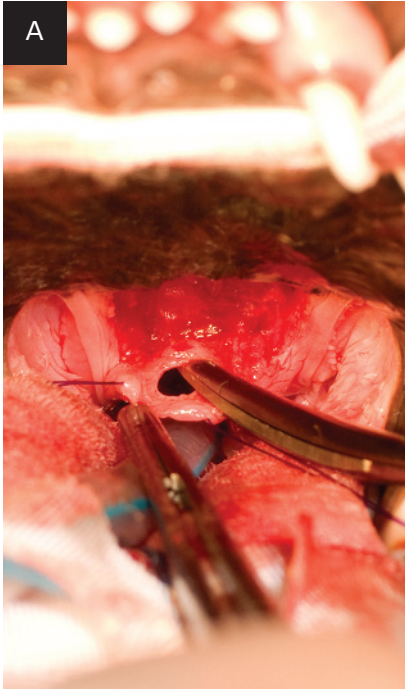
**Step 4** Using fine scissors for blunt dissection, resect most of the soft tissues between the nasopharyngeal and oropharyngeal mucosae of the soft palate: ventral mucosa, connective tissue, part of the palatinus, and levator veli palatini muscles (A, B, C, D, E).



**Author Insight** Bleeding of the palatine vessels can be anticipated on the rostralateral corners of the resection area. Hemostasis can be achieved with electrocautery, preferably using bipolar forceps. With experience, these vessels can be identified and cauterized before being sectioned, thereby avoiding any substantial bleeding.

**Step 5**

Trim the border of the palate's free end, consisting of the mucosa reflection. To keep the holding effect of the stay sutures, trim progressively in sequences alternating cutting and suturing (A, B, C). Fold the soft palate on itself and suture with monofilament absorbable sutures in an interrupted pattern (D, E).



MORE ►

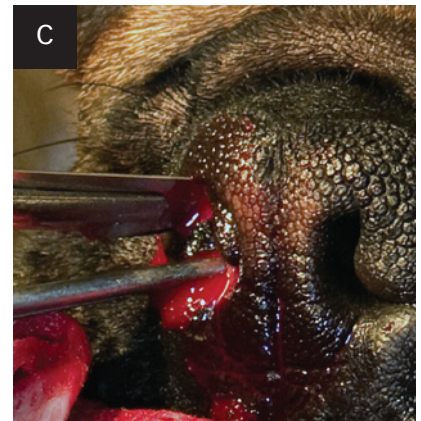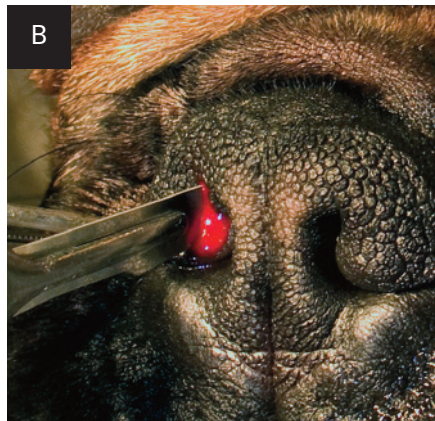

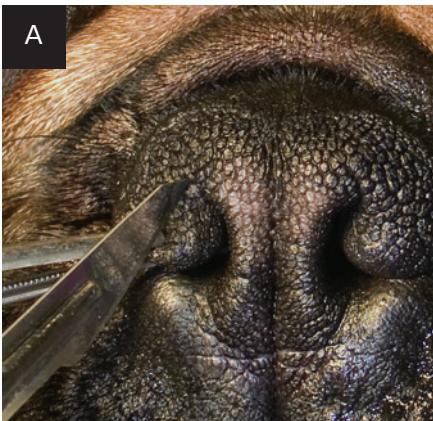
## Step-by-Step ■ Vertical Wedge Alaplasty

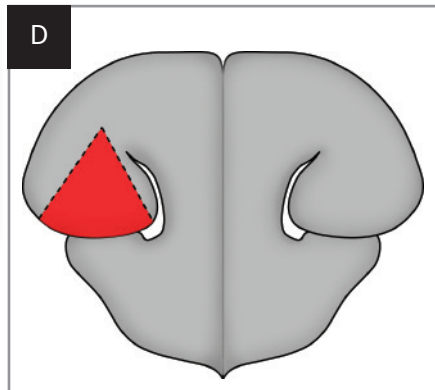
### Step 1

Start incising with a #11 scalpel blade at the apex of the wedge, which is positioned slightly dorsolaterally to the dorsal limit of the slit-like opening of the stenotic naris (A). Make incisions deep to include a portion of the alar fold to fully relieve the obstruction without limiting the opening to the rostral part of the nostril (B). The medial border of the wedge is parallel to the medial wall of the ala nasi. Make the lateral border of the wedge at a 40°–70° angle from its medial border (C, D).

**Author Insight** The degree of postoperative opening of the naris will be grossly proportional to the angle chosen.

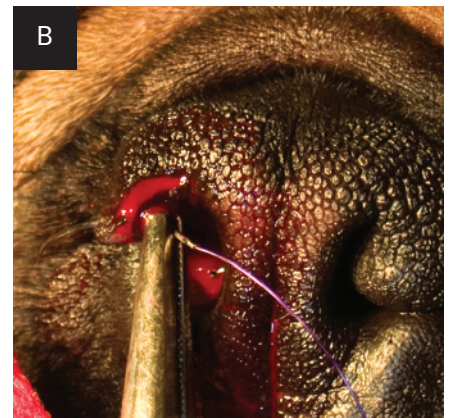
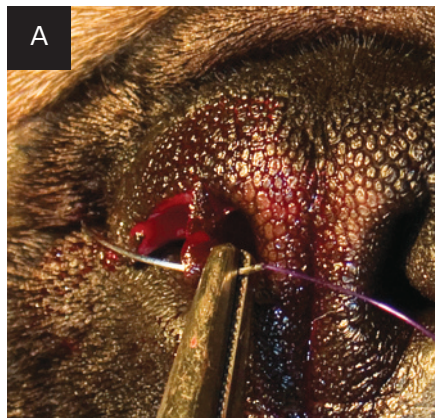

**Author Insight** Hemorrhage is usually brisk on incision and may somewhat impair visibility, but it resolves quickly when the wound is sutured.



### Step 2

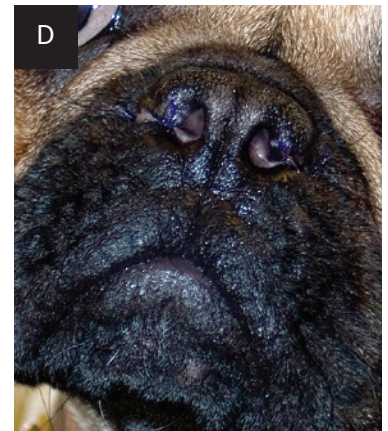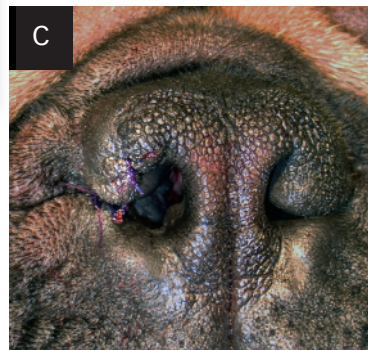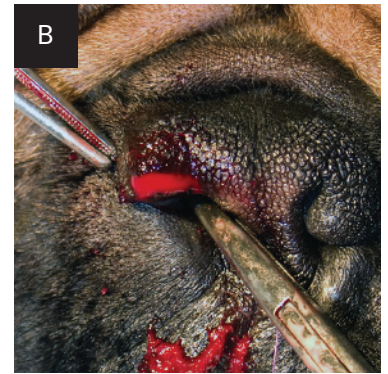
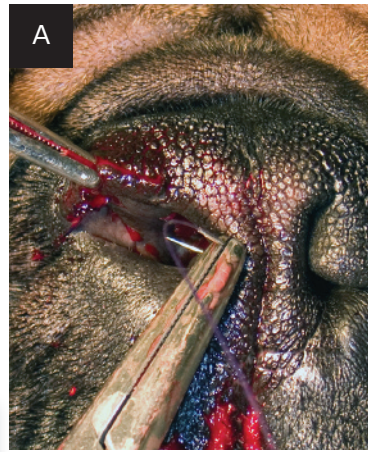Place 3 or 4 absorbable monofilament sutures in a simple interrupted pattern. Place the first suture at the ventrolateral corner of the naris (A, B) to obtain good alignment of the ventral border of the wound edges and a satisfactory cosmetic result.





### Step 3

Place another in-depth suture from medial to lateral, exiting through the skin just laterally to the caudal end of the alar notch (A, B). When gently tied, this suture should keep the deep portion of the naris wide during healing (C). Change scalpel blades and repeat the procedure on the other side. Take care to obtain symmetry on both sides (D); starting at the side of the surgeon's dominant hand (eg, right nostril for a right-handed surgeon) may help control symmetry. ■ **cb**



**Author Insight** When necessary, a nasotracheal tube for postoperative oxygen supplementation can be placed before the patient is allowed to recover from anesthesia.

See Aids & Resources, back page, for references & suggested reading.



- Seals the gingival sulcus against the formation of plaque
- Designed to allow water and oxygen to pass through
- One easy professional application every six months
- Extends the benefits of a professional dental cleaning
- Apply at spay or neuter to help the client get started on the path to wellness



Email: [info@allaccem.com](mailto:info@allaccem.com)



- The most convenient way to help manage otitis externa
- Applied as a preventive before/during allergy season and immediately after completion of treatment
- One easy professional application every three months
- Frees your clients from the burden of daily ear cleaning
- Steroid-free

Distributed by:  
Butler Schein Animal Health,  
MWI Veterinary Supply and  
Patterson Veterinary



Phone: 650-593-8700



- Forms a long-lasting protective layer over lick granulomas, lesions, sores, and hot spots
- Keeps the affected area clean and free of contamination during the healing process
- A single professional application, frees your clients from daily home care
- Easy to apply liquid formulation, dries clear and rapidly
- Durable and flexible for patient comfort



Web: [www.allaccem.com](http://www.allaccem.com)