



News

NAVC Brands

Search ...



One in-clinic dose of Zorbium™ provides 4 days of continuous post-op pain control—*for at-home comfort.*

The only FDA-approved long-acting transdermal buprenorphine for cats

**Zorbium™**  
(buprenorphine transdermal solution)




**Important Safety Information: Before using ZORBIUM (buprenorphine)**

**TVP**

TODAY'S VETERINARY PRACTICE

Articles ▾ CE Library Resources ▾ About ▾ Publication ▾



Subscribe



**RELIABLE, AFFORDABLE, CHEWABLE**

Enroflox<sup>®</sup> Chewable Tablets (enrofloxacin)

AVAILABLE TO ORDER

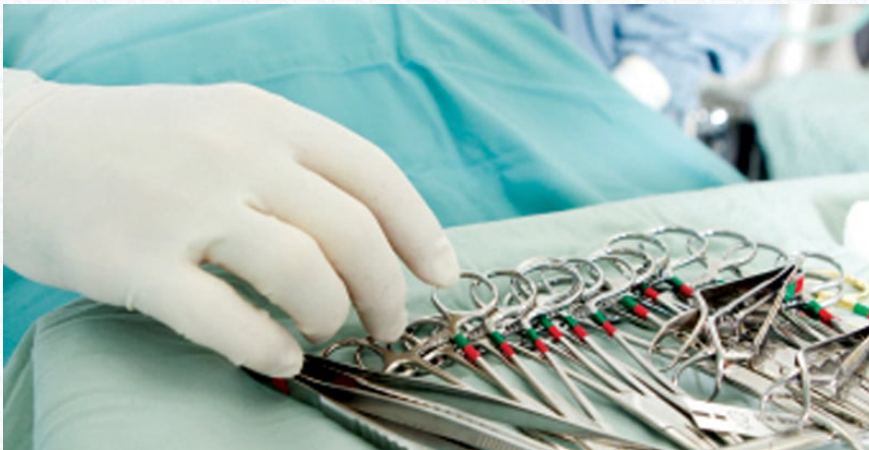PEER REVIEWED

SOFT TISSUE SURGERY

# Corrective Surgery: Dogs with Brachycephalic Airway Syndrome

Issue: January/February 2014



**Free eBook:**

**A Modern Guide to Managing Stress in the Veterinary Practice**

Get the eBook

Brought to you by 




Editor's Picks



**B**rachycephalic airway syndrome (BAS) refers to a group of primary and secondary abnormalities (**Table 1**) that result in upper airway obstruction. Primary abnormalities cause an increase in negative pressure within the upper airways that can eventually lead to secondary abnormalities.


Any tissue that obstructs the airway lumen is a source of resistance. According to the laws of physics, resistance in a single tube is inversely related to the radius raised to the fourth power. For example, if an airway is 50% obstructed, it is 16× harder to breathe, and if the diameter of any component of the upper respiratory tract is increased by 50%, resistance encountered on inspiration is decreased 16×.



## WHEN TO REFER

Typical clinical signs of BAS are listed in **Table 2**; dogs with these signs benefit from early surgical correction of existing primary abnormalities before secondary changes occur. For example, in puppies with stenotic nares it is recommended to perform rhinoplasty at 3 to 4 months of age, and at the same time perform a preliminary evaluation of the soft palate. Addressing these primary abnormalities at an early age may help avoid progression to secondary changes such as everted laryngeal saccules or laryngeal collapse.<sup>1-3</sup>

Screen Shot 2015-06-18 at 3.43.43 PM



When advanced secondary abnormalities have developed, such as laryngeal collapse, correction of these conditions requires additional training.



Sponsored  
**Ready to Satisfy Your Curiosity?**



Personal/Professional Development

**NAVC Certifications: Advancing Personally, Leading Professionally**



Practice Management

**Recognizing Futile Care in Veterinary Medicine**

Therefore, we recommend referring the patient to a board-certified veterinary surgeon.

This article describes practical approaches that will help the general practitioner efficaciously perform corrective surgery for:

- Stenotic nares
- Elongated soft palate
- Everted laryngeal sacculs
- Enlarged palatine tonsils.

## DIAGNOSTIC PROCESS

### Physical Examination

**Stenotic nares** are identified by physical examination (**Figure 1**).

Screen Shot 2015-06-18 at 3.43.49 PM



### Oral Cavity Examination

Elongated soft palate, everted laryngeal sacculs, and everted tonsils are identified by oral cavity examination, with the patient under heavy sedation or general anesthesia.

**The soft palate** is considered **elongated** when it extends 3 mm or further past the tip of the epiglottis. When evaluating the soft palate, correct positioning is crucial:

- Keep the mouth of the patient open by suspending the maxilla and

using a mouth gag (**Figure 2**), which allows the oral tissues to lie in their natural position.

- Exercise caution when evaluating the soft palate: traction on the tongue and oral tissues or presence of an endotracheal tube affect the soft palate's natural position, leading to altered landmarks.

Screen Shot 2015-06-18 at 3.43.55 PM



**Laryngeal saccules** are found just rostral to the vocal cords and, when **everted**, are white and glistening compared with surrounding tissues.

**The palatine tonsils** are located within the tonsillar crypts, just caudal to the palatoglossal arch, and protrude into the oral cavity when **enlarged** (**Figure 3**).<sup>4</sup>

Screen Shot 2015-06-18 at 3.44.03 PM

**Laryngeal function** is also evaluated during oral cavity examination. Laryngeal collapse is classified into 3 stages; in advanced stages of BAS (Stages II and III), laryngeal cartilage loses its integrity and collapses inward as a result of the excessive negative pressure created when affected dogs inspire:<sup>2,5</sup>

- **Stage I** refers to eversion of the laryngeal saccules.
- **Stage II** indicates that the cuneiform processes have come into apposition.
- **Stage III** designation means the corniculate processes are apposed and changes associated with Stages I and II are present.

**Table 3** describes the differences between abnormal laryngeal function and laryngeal collapse; **Figure 4** depicts the anatomic structure of the larynx.

Screen Shot 2015-06-18 at 3.44.09 PM

ss Fig 4

## Order of Corrective Surgical Techniques

Abnormalities should be corrected in the following order:

1. Stenotic nares
2. Elongated soft palate
3. Everted laryngeal saccules
4. Everted palatine tonsils.

# CORRECTIVE SURGICAL TECHNIQUES

## Stenotic Nares

Stenotic nares are easily corrected using a wedge resection technique or laser ablation.

In **commonly affected brachycephalic breeds** where the wedge resection technique is feasible, it is preferred over laser ablation because a laser:

- Tends to char the edges of the incision, causing the superficial layer of the nose to slough and leaving a noticeable depigmented area.
- Makes it hard to create a straight line while maintaining tension on the tissue being removed, leaving scarred, depigmented, and/or uneven tissue behind.

In **Persian cats and certain small brachycephalic breeds**, wedge resection is not feasible due to the nares' small size. In these cases, we find that the best results are achieved by performing a rhinoplasty via laser ablation (**Table 4**).


Screen Shot 2015-06-18 at 3.49.20 PM



## Wedge Resection

- 1. Approach:** In typical brachycephalic dog breeds, we prefer to *remove a wedge from the lateral aspect of the alar fold* with a #11 surgical blade (**Figure 5**). This approach differs from described techniques, which remove a *wedge of rostral alar cartilage*, leaving only a small amount of tissue rostrally on the nares. By performing the lateral wedge, more of the rostral alar fold is spared, allowing a larger, deeper incision and easier suturing.

Screen Shot 2015-06-18 at 3.44.32 PM



- 2. Closure:** When apposing the 2 cut edges, suture the most ventral aspect of the incision first, which aids in hemostasis, leading to better visualization of the surgical field. A cotton-tipped applicator soaked in epinephrine and placed in the nostril also helps control hemorrhage. Use absorbable, monofilament suture material, such as 4-0 PDS (ethicon.com), in a simple interrupted pattern, to effectively widen the nares (**Figure 6**). It is unnecessary to suture the incision edge inside the nostril. Leave ligatures in place for 10 to 14 days.



**3. Additional Notes:** During the procedure, inflate the endotracheal cuff and place gauze sponges in the back of the oropharynx to prevent blood from draining through the nasopharynx into the larynx. To ensure that all sponges are removed postoperatively, it is imperative to (1) either count the number of gauze sponges used or (2) clamp them with a hemostat before placing them in the caudal oral cavity.

## **Laser Ablation**

- 1. Approach:** When performing laser ablation, the medioventral aspect of the dorsolateral nasal cartilage is removed (**Figure 7**). Set the laser at 4 to 5 watts (W) on the continuous cutting setting for best results. Angle the laser in a medial to lateral direction, which keeps the laser



from affecting tissue outside the nostril, preventing visible depigmentation.

Screen Shot 2015-06-18 at 3.44.47 PM



- 2. Additional Notes:** Place a cotton-tipped applicator soaked in saline or epinephrine inside the nare to prevent the laser from penetrating the underlying or adjacent tissues inside the nostril.

## **Elongated Soft Palate**

- 1. Landmarks:** When measuring the amount of redundant soft palate tissue to remove, the published landmarks are the tip of the epiglottis and the middle to caudal aspect of the tonsillar crypt.<sup>2,3,6-8</sup> We prefer the junction where the soft palate and epiglottis touch as the landmark to determine the excision point of tissue (**Figure 8**). When evaluating this junction, it is extremely important that the animal be extubated, with no traction placed on the tongue.

When this junction has been identified, a skin marker, electrocautery unit (low setting), or a CO<sub>2</sub> laser (0.4 mm tip, 6–10 W, continuous cutting) can be used to create a mark that outlines and follows where the epiglottis touches the soft palate.

2. **Preparation:** Once the surgical landmarks have been identified and marked, reintubate the patient and pack gauze sponges in the back of the oral cavity to prevent blood from draining caudally through the nasopharynx into the trachea.
3. **Approach:** Soft palate resection, or staphylectomy, can be performed using the traditional sharp resection method, bipolar sealing device (BSD), fine-tip electrocautery unit, or CO<sub>2</sub> laser. Retract the tongue rostrally and ventrally to allow visualization of the soft palate and laryngeal tissues. Use Babcock or Allis tissue forceps to grasp the caudal margin of the soft palate and retract it rostrally. If electing to suture the mucosa, 2 stay sutures can be placed at the soft palate edges and used for manipulation during the transection process. Then resect the soft palate 2 mm caudal to the mark that was made. If using the sharp resection method, the soft palate is incised using Metzenbaum scissors.
4. **Closure:** For the sharp resection method, suture the soft palate incrementally in a simple continuous pattern to appose the nasal and oral mucosal edges. However, if a CO<sub>2</sub> laser, electrocautery unit, or BSD are used, suturing is not always necessary (see **No Scissors Needed**).

## No Scissors Needed

Advantages of using a CO<sub>2</sub> laser or electrocautery include:

- Minimal hemorrhage
- Decreased swelling and postoperative pain
- Potential bactericidal properties
- Reduction of surgery time by half.

These instruments act by coagulating small vessels while sealing lymphatic vessels and nerve endings. As a direct result of reduced hemorrhage, visualization of the surgical field is improved over sharp resection.

Postoperative swelling may be reduced if tissue handling is minimized, and because the nerve endings are sealed, signs of pain are decreased.

When using a CO<sub>2</sub> laser:

- Protect the endotracheal tube by covering it with moistened gauze sponges. The moistened sponges prevent accidental laser penetration of the endotracheal tube and ignition of oxygen.
- Vessels may be encountered that cannot be sealed with this instrument alone. In this situation, the electrocautery unit is used or, as an alternative, the BSD provides tissue compression, while cauterizing and permanently sealing collagen and elastin in vessel walls up to 7 mm in diameter.<sup>7</sup>

## Everted Laryngeal Saccules

1. **Approach:** Everted saccules can be removed by incising them with Metzenbaum scissors, a #15 blade or, in larger dogs, a CO<sub>2</sub> laser. Regardless of the method chosen, extubate the dog and grasp the saccules with forceps. Gently retract the saccules to further evert the tissue, then transect them (**Figure 9**).

If a CO<sub>2</sub> laser is used, position a cotton-tipped applicator soaked in epinephrine or saline behind the saccules and ablate the tissue over the applicator, which prevents the laser from penetrating any of the tissues behind the saccules. Use a 0.8- or 1.4-mm tip set at 6 to 10 W on a continuous cutting setting. We feel that the continuous cutting setting has better coagulating ability in contrast to the super pulse setting. If used properly, we feel that the CO<sub>2</sub> laser does not overheat adjacent tissue. However, if it is used improperly or a diode laser with a contact probe or electrocautery is employed for saccule excision, there is risk of overheating the adjacent tissues.

- 2. Closure:** Hemorrhage is usually minimal, and sutures are not usually indicated. If bleeding does occur, suction should be readily available to avoid drainage into the trachea. If hemorrhage cannot be controlled with the laser or electrocautery, reposition the endotracheal tube, with the cuff at the level of the transected saccules. Inflate the cuff, directly applying pressure to the bleeding tissue and leave in place for 5 minutes. Then deflate the cuff and reevaluate the area; if hemorrhage continues, repeat this process.
- 3. Additional Notes:** When performing this procedure, there is the potential for ventral laryngeal webbing. Avoid this complication by not excising the ventral midline mucosa adjacent to the saccules.

## Everted Palatine Tonsils

- 1. Indications:** Everted palatine tonsils can be treated via a

tonsillectomy; however, if the primary factors of BAS can be addressed and corrected, a tonsillectomy may not be indicated, especially if the tonsils return to their normal position. Removal is suggested when the tonsils:

- 2 Protrude into the oropharynx
- 3 Are a chronic problem or infected.

4. **Medical Therapy:** If the tonsils are infected, administer antibiotics for 5 to 7 days prior to surgery. The antibiotic should be effective against common oral bacteria as well as anaerobes. Frequently used antibiotics include clindamycin or amoxicillin/clavulanic acid (Clavamox, zoetis.com).
5. **Approach:** A tonsillectomy can be performed with a CO<sub>2</sub> laser, electrocautery, or sharp resection. The patient should be intubated with the tube cuff inflated; note that when extubating, the cuff should not be entirely deflated, which allows any fluid that has traveled down the trachea to be removed with the cuff. As with previous procedures, place gauze sponges in the back of the oropharynx. Regardless of the technique chosen, grasp the tonsil with an Allis tissue forceps or Babcock forceps. When using a CO<sub>2</sub> laser, retract the tissue and transect it at the base. An electrocautery unit should be available since, due to its size, the major palatine artery in larger dogs will not be sealed with the laser alone.<sup>1</sup> If using electrocautery or sharp resection, retract the tonsil from the crypt and place a curved hemostat (appropriately sized for the patient) along the base, ensuring that only the tonsil is inside the hemostat when it is closed. Remove the tonsil by transecting it along the distal aspect of the hemostat with either electrocautery or a scalpel blade. Leave the hemostat in place for 5 minutes; then remove it and examine the tissue for hemorrhage. If hemorrhage is present, electrocautery can be used to cauterize the offending vessel.
6. **Closure:** Because the major palatine artery is present inside the caudal aspect of the tonsillar crypt, 1 ligature of either 4-0 Monocryl or Vicryl (ethicon.com) can be placed at the caudal edge of the crypt. The decision to suture the crypt is left to the discretion of the clinician; we do not routinely suture the crypts closed. However, if excessive tissue is resected and there is extensive exposure of the underlying tissues, suture the defect closed with an absorbable suture (as above). If the tonsil is infected, it is beneficial to leave the crypt open for drainage.

## PERIOPERATIVE MEDICAL THERAPY

**Antibiotics** are usually not warranted unless the tonsils are infected; however, it is recommended to administer one dose of cefazolin perioperatively.

**Dexamethasone SP** (0.22 mg/kg IV) is also given perioperatively to decrease inflammation, and can be repeated in 12 hours if the clinician feels it is warranted. We do not recommend use of dexamethasone as a substitute for dexamethasone SP.

## RECOVERY & PAIN MANAGEMENT

### Postsurgical Recovery

- Delay extubation until the patient is conscious and has regained the ability to swallow, which ensures that the animal is able to adequately breathe. This may take longer than typically seen with routine postoperative recoveries.
- Provide supplemental oxygen as needed.
- Monitor the patient's respiratory rate and effort for a minimum of 12 to 24 hours postoperatively. If respiratory distress is encountered, address it immediately by administering supplemental oxygen and sedation. If the patient fails to respond, a temporary tracheostomy may need to be performed.
- Withhold water for 12 hours; then offer it in small amounts. If the patient tolerates water, offer food and monitor the animal closely for signs of impaired swallowing. Coughing and gagging may occur but generally resolve over several weeks.
- An E-collar may be beneficial to prevent self trauma to the nares.

### Pain Management

- **Butorphanol** (0.22–0.33 mg/kg IV) provides adequate analgesia for these procedures and is also beneficial for its antitussive properties and mild sedative effects. In addition, it does not create the panting, nausea, or vomiting seen with use of some opioids, which eliminates the risk for potential aspiration of vomitus. Its analgesic effects are short lived, so frequent dosing (Q 4 H) may be necessary.
- **Acepromazine** (0.005–0.02 mg/kg IV as needed) is beneficial for animals that are anxious or excited postoperatively.
- **Maropitant** (Cerenia, zoetis.com) is also recommended because, in general, nausea and regurgitation are common in brachycephalic breeds postoperatively.

## COMPLICATIONS

The most commonly encountered complications are:

- Inflammation that can obstruct the larynx and trachea, leading to respiratory distress



- Hemorrhage from the lateral aspect of the soft palate or caudal aspect of the tonsillar crypt
- Coughing and/or gagging
- Nasal discharge
- Voice change
- Regurgitation and/or vomiting
- Noncardiogenic pulmonary edema
- Aspiration pneumonia
- Infection
- Dehiscence
- Sloughing of the pigmented layer of the skin after laser rhinoplasty

A documented but rarely encountered complication is ventral laryngeal webbing, which develops during the healing process because, when removing the saccules, the ventral aspect of the larynx is incised. Avoid this complication by removing the everted tissue at the 4 and 8 o'clock positions only and not the tissue along the ventral midline of the larynx.

## IN SUMMARY

These corrective procedures should be performed early, to prevent progression to the secondary changes associated with BAS, thereby resulting in a better quality of life for animals with BAS. These techniques are recommended because they can be performed in general practice and create desirable results.

BAS = brachycephalic airway syndrome; BSD = bipolar sealing device; W = watt

## References



## Subscribe for More

Stay current with the latest techniques and information – sign up below to start your FREE Today's Veterinary Practice subscription today.

[Start My Subscription](#)





[Advertising Opportunities](#)