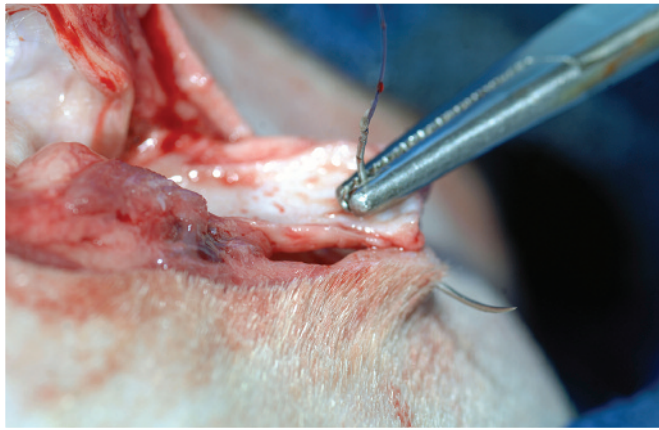


Lateral Ear Canal Resection in Dogs



Mona Qahwash, DVM
Georgia Veterinary Specialists

Karen M. Tobias, DVM, MS, DACVS
Gregory Hirshoren
University of Tennessee

Lateral ear canal resection, previously known as the *Zepp procedure*, can provide several benefits in dogs and cats with nonhyperplastic ear disease. It improves ventilation to the ear canal, thereby decreasing humidity, moisture, and temperature to foster an environment less conducive to bacterial and fungal growth.¹⁻³ It can also reduce secretion accumulation and subsequent otitis externa and/or otitis media in animals with congenital or traumatic stenosis of the vertical canal. In addition, lateral ear canal resection can improve intraoperative visualization and allow resection of small masses of the lateral wall of the vertical canal.¹

Patient selection for lateral ear canal resection is critical for a successful outcome.³ The horizontal canal must be patent on otoscopic examination, and no proliferation or calcification of the external canal should remain after surgery.² Concurrent dermatopathies should be under control at the time of surgery, and owners must agree to continue treating underlying causes of otitis.⁴ Success rates are below 15% in cocker spaniels because of their underlying skin and ear conditions.⁴ At the authors' practices, lateral ear resection is used only for mass removal or to correct congenital or traumatic canal stenosis. The procedure has a high failure rate for other conditions, and owners should be informed that future surgery (eg, total ear canal ablation, lateral tympanic bulla osteotomy) may be needed.

If possible, preexisting septic otitis externa should be treated with appropriate antimicrobials based on canal culture and sensitivity testing before surgery is undertaken. Unless caused by congenital stenosis, otitis media is best addressed before surgery. Alternatively, myringotomy and bulla cleansing can be performed during the procedure if the veterinarian is experienced with these treatments.

Preoperative Preparation

Many veterinarians clip and prepare the entire pinna to facilitate tissue manipulation and maintain anatomic orientation during intraoperative dissection. Skin and pinnae should be cleansed with antiseptic scrub solution; cotton can be temporarily placed in the canal to prevent detergent from reaching the tympanic membrane.

Patient selection for lateral ear canal resection is critical for a successful outcome.³

MORE ►

Lateral ear canal resection can be done to treat shar-peis with canal stenosis, the primary cause of otitis in this breed.

Because of concerns regarding ototoxicity, many veterinarians use sterile saline instead of 0.05% chlorhexidine or 1% povidone–iodine to flush the canal. Ototoxicity appears to be related to anti-septic concentration and its contact time within the round window.⁵ In several studies of dogs treated with topical otic chlorhexidine preparations, no vestibular effects were noted and brain-stem auditory evoked response (BAER) hearing tests remained unchanged, regardless of whether the tympanic membrane was intact.^{6,7}

Because completely removing microorganisms from the canal can be difficult, ear canal resection is usually considered a clean–contaminated or contaminated surgery. However, blood supply to the region is excellent, and infections are uncommon; therefore, prophylactic antibiotics may be unnecessary.

Suture Selection

Suture selection is based on clinician preference. Some veterinarians use 3-0 nonabsorbable monofilament suture in an interrupted pattern to prevent failure of the entire suture line if tension, necrosis, or trauma causes suture failure. Others prefer a continuous pattern of 3-0 or 4-0 absorbable or nonabsorbable monofilament along the pinna margins to reduce surgery time and postoperative accumulation of debris around knots. Incisions apposed with monofilament absorbable suture should be rechecked 10 to 14 days after placement to determine whether suture removal is necessary. Underlying skin and ear issues also can be checked at this time and owner compliance with postoperative treatment verified.

Postoperative Considerations

Postoperative analgesics usually include injectable opioids for the first 16 to 24 hours and, if desired, local anesthetic blocks. An NSAID can also be administered if the patient has not received glucocorticoids. Other options for oral pain relief in dogs include tramadol hydrochloride, gabapentin, or acetaminophen combined with codeine. The animal should wear an Elizabethan collar to prevent self-trauma, and treatment of the primary causes of otitis should continue.

Complications

Complications are usually related to poor patient selection; failure to treat the underlying cause of otitis externa; or poor surgical technique resulting in tension, inadequate horizontal canal drainage, suture failure, or stricture formation.² If dehiscence occurs, the site can be managed as an open wound until inflammation or infection resolves. Failure rates range from 34.9% to 55%.^{4,8,9} In one study, success rates increased from 45% to 63% when cocker spaniels were excluded, and 80% of shar-peis had good or excellent outcomes.⁴ Shar-peis were thought to have congenitally smaller canal diameters; lateral ear canal resection would, therefore, be performed to treat the primary cause of otitis (ie, canal stenosis).⁴

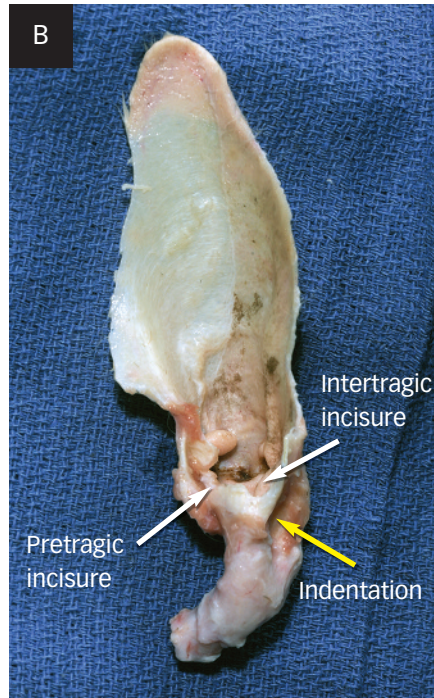
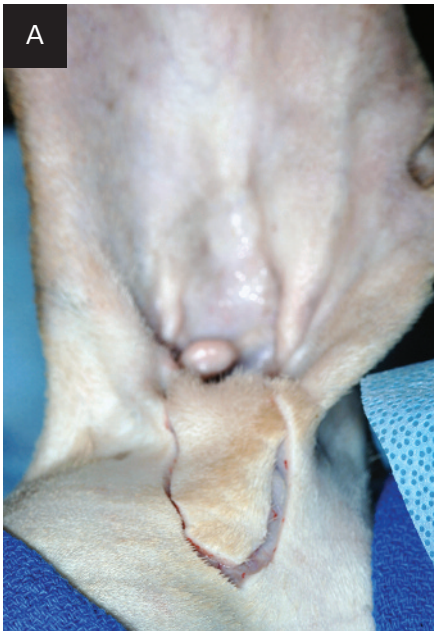What You Will Need

- #10 or #15 scalpel blade and handle
- DeBakey or Adson–Brown thumb forceps
- Needle drivers
- Mayo scissors
- Metzenbaum scissors (optional)
- Hemostats or electrocautery (optional)
- 3-0 or 4-0 monofilament suture

Step-by-Step ■ Lateral Ear Canal Resection

Step 1

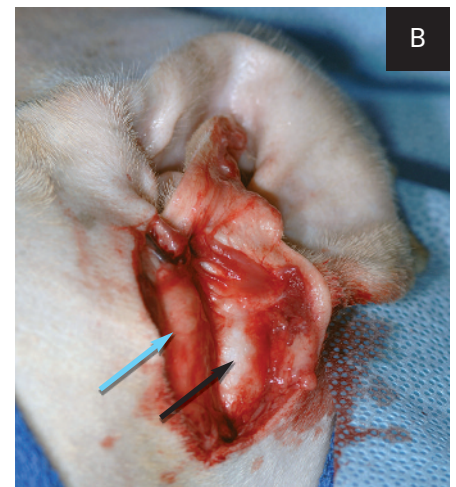
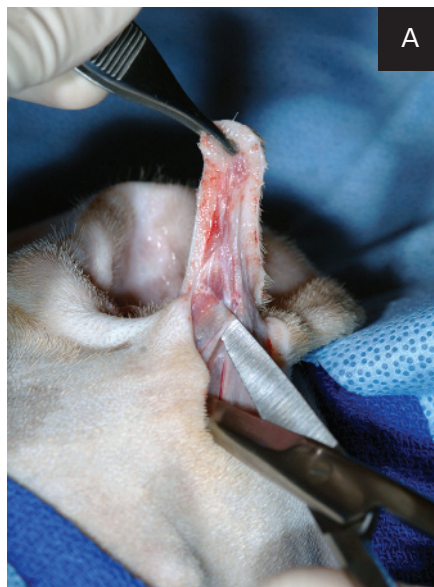
Make a U-shaped skin incision (A), starting and ending at the pretragic and intertragic incisures (B), which are adjacent to the tragus, and extending ventrally to the level of the horizontal ear canal.



Author Insight The ear's vertical canal spirals inward as it progresses proximally toward the horizontal canal. The distal portion of the vertical canal may contain an indentation (yellow arrow) that distorts the anatomy. The incisures, which define the distal borders of cartilage flap development, are noted.

Step 2

Dissect along the lateral surface of the vertical ear canal (A), keeping the scissors parallel to the canal, until the canal is exposed (B). In some dogs, the parotid salivary gland (blue arrow) covers a portion of the vertical canal (black arrow); transection of these tissues does not cause complications.

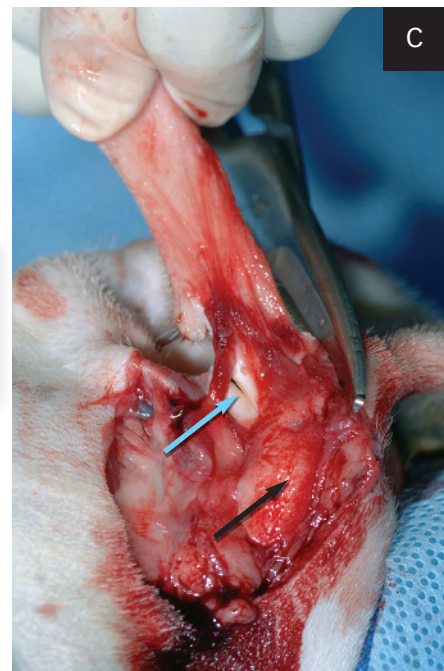
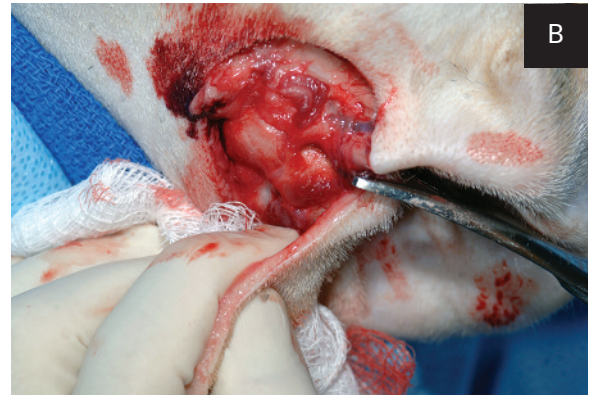
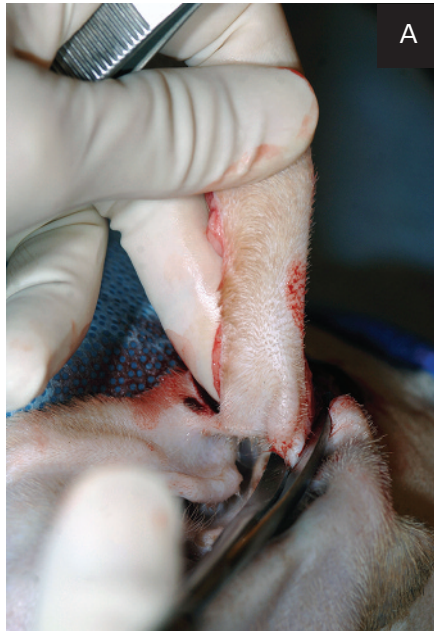
The parotid gland has been dissected away from the cartilage in the exposed lateral canal.

MORE ►

Step 3

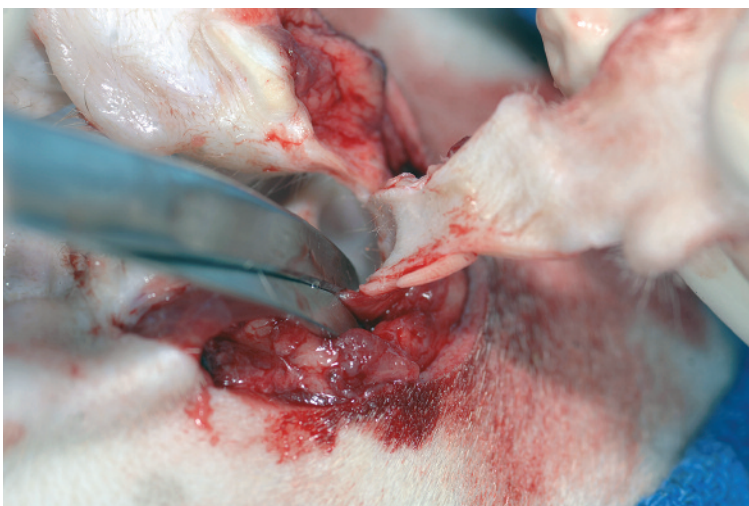
Begin formation of a drainboard by making 1- to 1.5-cm cuts down the lateral wall of the vertical canal, starting at each of the incisures (A, B); transection begins dorsally at the pretragic and intertragic incisures. Alternate cartilage cuts along each side of the flap (C, blue arrow) while observing the interior of the vertical canal (black arrow) to maintain even drainboard width.



Author Insight Attention to detail may prevent inadvertent narrowing of the flap or accidental transection of the medial wall of the vertical canal.

Step 4

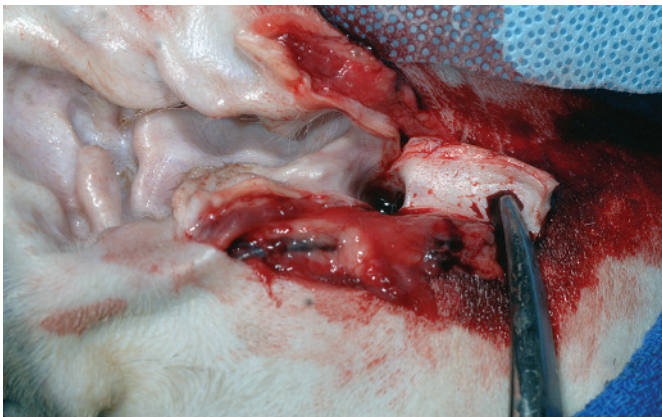
As the cuts approach the horizontal canal, evaluate the opening by pulling the flap ventrally. If the opening is oval, redirect the scissors to cut the cartilage at the rostral and caudal midpoints of the canal. This produces a round opening that is more likely to remain open.



Author Insight Additional cuts at the hinges of the flap may prevent narrowing of the new canal.

Step 5

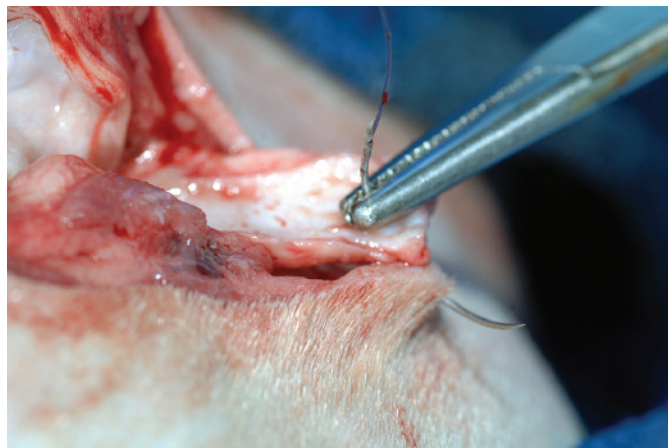
Transect the skin and ventral portion of the cartilage flap to make a drainboard of the desired length.



The excess skin and cartilage have been removed. Note how the canal opening remains circular as the flap is pulled ventrally.

Step 6

Place sutures between the corners of the drainboard and the skin. If the drainboard epithelium is thick, exclude cartilage from the suture bite so the skin edges are apposed. If the new opening is blocked because the flap is not pulled ventrally, remove extra facial skin before placing the corner sutures.

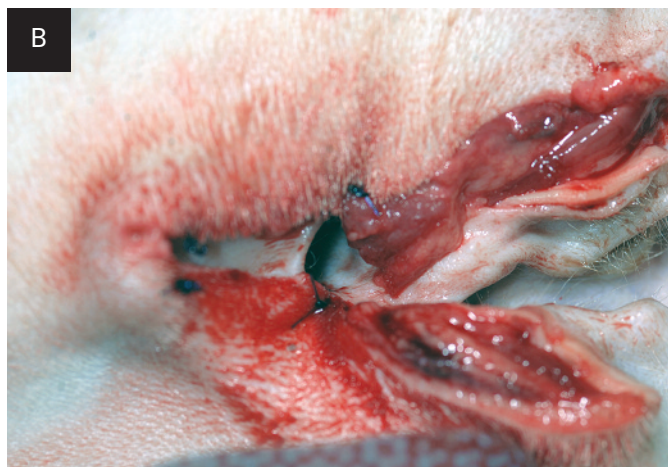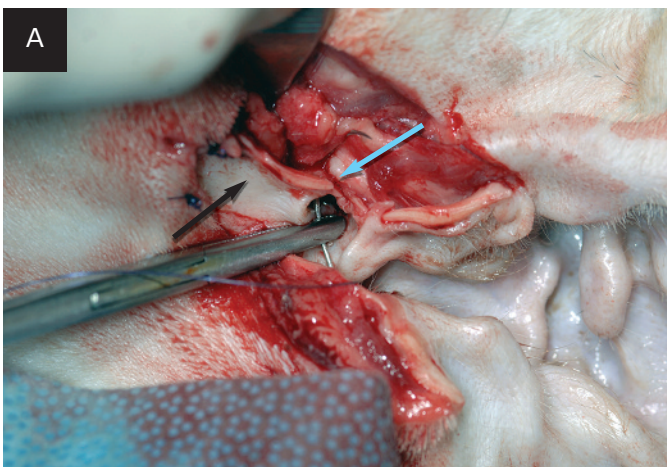


Author Insight Sutures are placed between the corners of the drainboard and the lateral facial skin first.

Step 7

Place sutures between the hinged (*crotch*) areas of the flap (**blue arrow**) and adjacent skin; note the relation to the ventral drainboard of the canal (**black arrow**). Because of the depth of the ear canal, these sutures will include cartilage (A). Make sure the

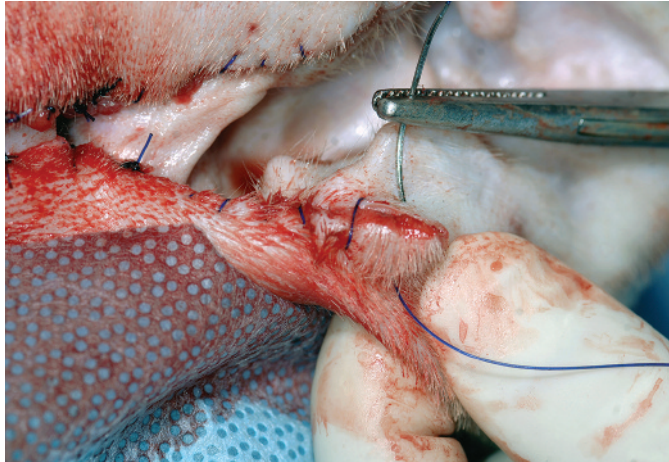
skin is not under tension at these sites; if tension is present, remove the hinge sutures and replace them using facial skin farther proximal along the incision margin (B).



MORE ►

Step 8

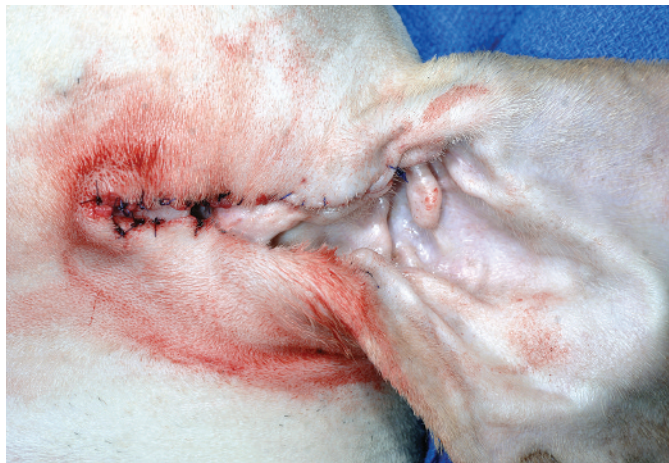Fill in remaining areas with sutures of interrupted or continuous pattern. Place sutures so the epithelium covers exposed cartilage edges.



Apposition of the vertical canal margins and skin using a continuous pattern of rapidly absorbable monofilament suture

Step 9

Trim suture ends short, particularly those pointing inward into the canal epithelium. ■ **cb**



See **Aids & Resources**, back page, for references & suggested reading.



Oral Suspension for Cats

**Veraflox (pradofloxacin) Oral Suspension for Cats
25 mg/mL**

For the treatment of skin infections (wounds and abscesses) in cats.
Do not use in dogs.

BRIEF SUMMARY:

Before using Veraflox Oral Suspension for Cats, please consult the product insert, a summary of which follows:

CAUTION:

Federal law restricts this drug to use by or on the order of a licensed veterinarian. Federal law prohibits the extra-label use of this drug in food-producing animals.

PRODUCT DESCRIPTION:

Pradofloxacin is a fluoroquinolone antibiotic and belongs to the class of quinolone carboxylic acid derivatives. Each mL of Veraflox Oral Suspension provides 25 mg of pradofloxacin.

INDICATIONS:

Veraflox is indicated for the treatment of skin infections (wound and abscesses) in cats caused by susceptible strains of *Pasteurella multocida*, *Streptococcus canis*, *Staphylococcus aureus*, *Staphylococcus felis*, and *Staphylococcus pseudintermedius*.

CONTRAINDICATIONS:

DO NOT USE IN DOGS. Pradofloxacin has been shown to cause bone marrow suppression in dogs. Dogs may be particularly sensitive to this effect, potentially resulting in severe thrombocytopenia and neutropenia. Quinolone-class drugs have been shown to cause arthropathy in immature animals of most species tested, the dog being particularly sensitive to this side effect. Pradofloxacin is contraindicated in cats with a known hypersensitivity to quinolones.

HUMAN WARNINGS:

Not for human use. Keep out of reach of children. Individuals with a history of quinolone hypersensitivity should avoid this product. Avoid contact with eyes and skin. In case of ocular contact, immediately flush eyes with copious amounts of water. In case of dermal contact, wash skin with soap and water for at least 20 seconds. Consult a physician if irritation persists following ocular or dermal exposure or in case of accidental ingestion. In humans, there is a risk of photosensitization within a few hours after exposure to quinolones. If excessive accidental exposure occurs, avoid direct sunlight. Do not eat, drink or smoke while handling this product. For customer service or to obtain product information, including a Material Safety Data Sheet, call 1-800-633-3796. For medical emergencies or to report adverse reactions, call 1-800-422-9874.

ANIMAL WARNINGS:

For use in cats only. The administration of pradofloxacin for longer than 7 days induced reversible leukocyte, neutrophil, and lymphocyte decreases in healthy, 12-week-old kittens.

PRECAUTIONS:

The use of fluoroquinolones in cats has been associated with the development of retinopathy and/or blindness. Such products should be used with caution in cats. Quinolones have been shown to produce erosions of cartilage of weight-bearing joints and other signs of arthropathy in immature animals of various species. The safety of pradofloxacin in cats younger than 12 weeks of age has not been evaluated. The safety of pradofloxacin in immunocompromised cats (i.e., cats infected with feline leukemia virus and/or feline immune-deficiency virus) has not been evaluated. Quinolones should be used with caution in animals with known or suspected central nervous system (CNS) disorders. In such animals, quinolones have, in rare instances, been associated with CNS stimulation that may lead to convulsive seizures. The safety of pradofloxacin in cats that are used for breeding or that are pregnant and/or lactating has not been evaluated.

ADVERSE REACTIONS:

In a multi-site field study, the most common adverse reactions seen in cats treated with Veraflox were diarrhea/loose stools, leukocytosis with neutrophilia, elevated CPK levels, and sneezing.

ANIMAL SAFETY:

In a target animal safety study in 32, 12-week-old kittens dosed at 0, 1, 3, and 5 times the recommended dose for 21 consecutive days. One 3X cat and three 5X cats had absolute neutrophil counts below the reference range. The most frequent abnormal clinical finding was soft feces. While this was seen in both treatment and control groups, it was observed more frequently in the 3X and 5X kittens.

U.S. Patent No. 6,323,213
May, 2012

84364593/84364607, R.0

NADA141-344, Approved by FDA

Made in Germany

Bayer, the Bayer Cross and Veraflox are registered trademarks of Bayer.

17928
GHG080213

Bayer

Bayer HealthCare LLC
Animal Health Division
Shawnee Mission, Kansas 66201, U.S.A.