

PRACTICAL TECHNIQUES FROM THE NAVC INSTITUTE

FELINE PERINEAL URETHROSTOMY

VENTRAL APPROACH



Clara S.S. Goh, BVSc, MS, Diplomate ACVS,
and Howard B. Seim III, DVM, Diplomate ACVS
Colorado State University

Welcome to the first article in our new *Practical Techniques from the NAVC Institute* column. Each year, the NAVC Institute takes place in Orlando, Florida, and specialists in select areas of veterinary medicine provide hands-on, one-on-one continuing education to the Institute attendees.

The *NAVC* and *Today's Veterinary Practice* have partnered together to present information from the NAVC Institute 2014 courses. For those unable to attend, this column provides the opportunity to experience the excellent education provided at the Institute. Visit navc.com/institute for further information.



Over the past decade, advances in the medical management of feline lower urinary tract disease (FLUTD) have decreased the requirement for surgical intervention of the blocked male cat.

Perineal urethrostomy (PU) is still the surgical treatment of choice for patients with:

- Repeated urethral obstruction despite medical management
- Obstruction that cannot be relieved by urethral catheterization
- Catheterization that has resulted in significant urethral trauma and/or stenosis.¹

INITIAL MEDICAL MANAGEMENT

Prior to anesthesia for an elective PU, manage the patient medically with IV fluid therapy and bladder decompression (via retropulsion of urethral crystal/mucus plugs or calculi, catheterization, repeat cystocentesis, or a temporary cystostomy tube) until all renal, metabolic, and electrolyte parameters are within normal limits.

FELINE PERINEAL URETHROSTOMY (DORSAL RECUMBENCY)

Our preferred technique is a slight variation on the traditional PU described by Wilson and Harrison in 1971.² In this variation, the cat is placed in dorsal recumbency instead of the standard perineal approach. This positioning is more ergonomic for the surgeon, and allows access to the ventral abdomen for concurrent cystostomy if indicated.

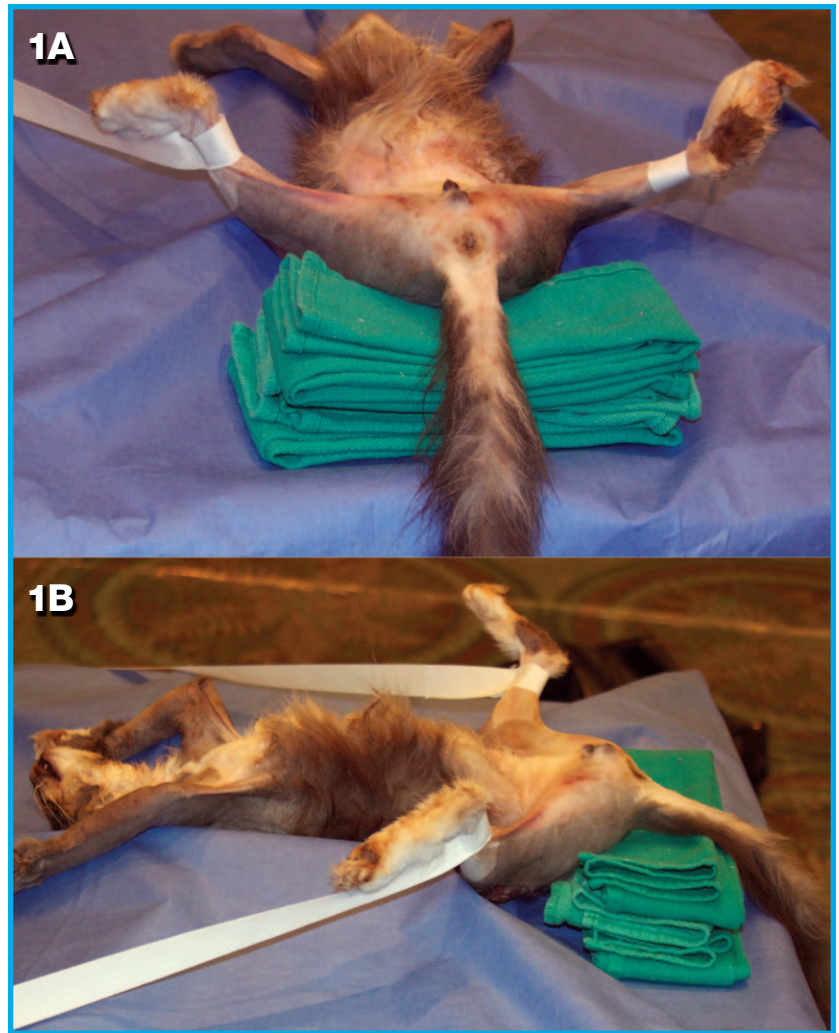
The Essentials for Perineal Urethrostomy

- Standard general surgery pack, including needle holders, thumb forceps (preferably Debaquey forceps), mosquito forceps, scalpel handle, Metzenbaum and Mayo scissors
- Stevens tenotomy scissors (4" straight)
- 2 Gelpi retractors (3.5" size)
- Suture (4-0 to 5-0 monofilament synthetic absorbable, on a taper or taper-cut needle)
- Suction device and small Frasier suction tip

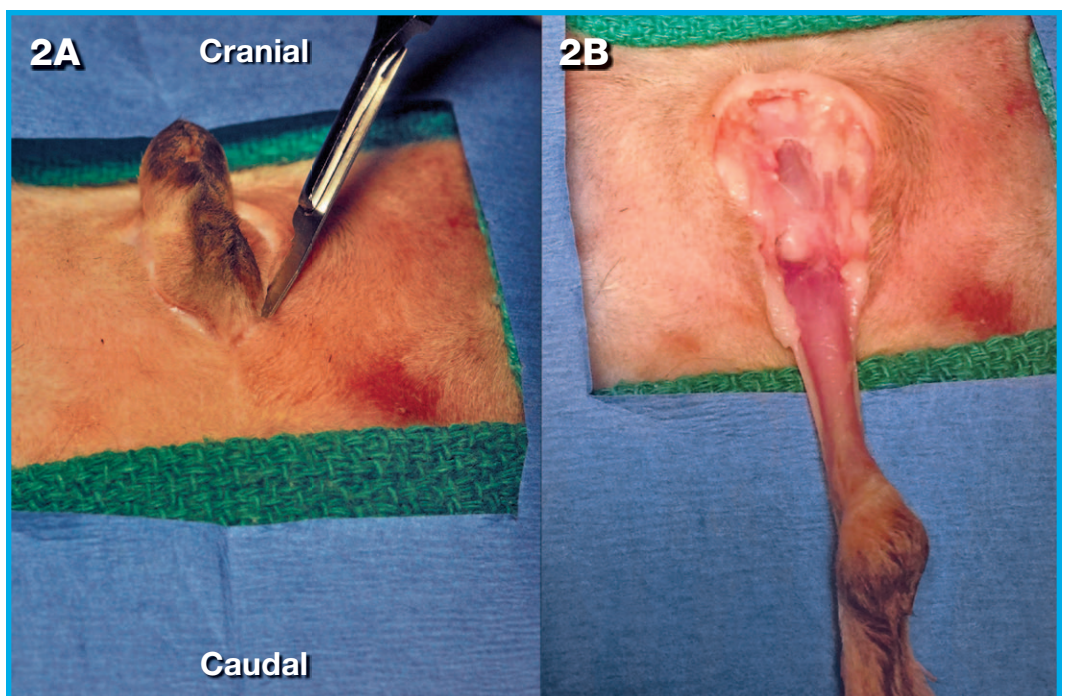
1 Position the cat in dorsal recumbency (see **Surgical Insight: Penile Orientation**) with the hindlimbs tied cranially until the pelvis is slightly elevated off the surgery table. Place a folded towel under the pelvis to support the patient (**A** and **B**) and place a purse string suture in the anus. Clip and aseptically prepare the perineal region ± ventral abdomen (if a cystotomy is indicated).

**SURGICAL INSIGHT:
PENILE ORIENTATION**

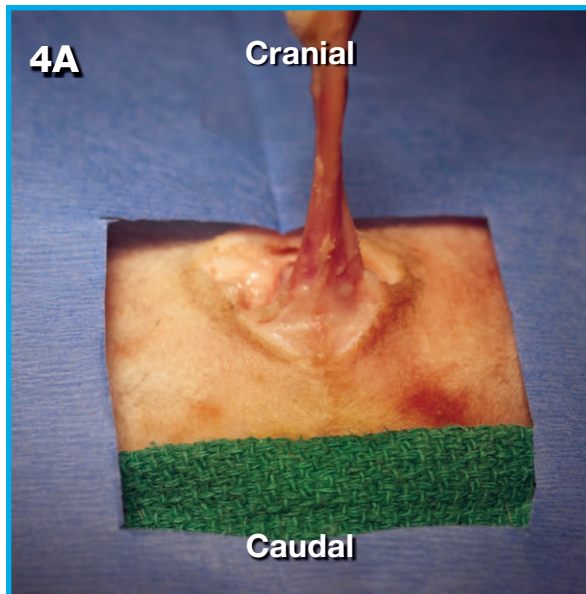
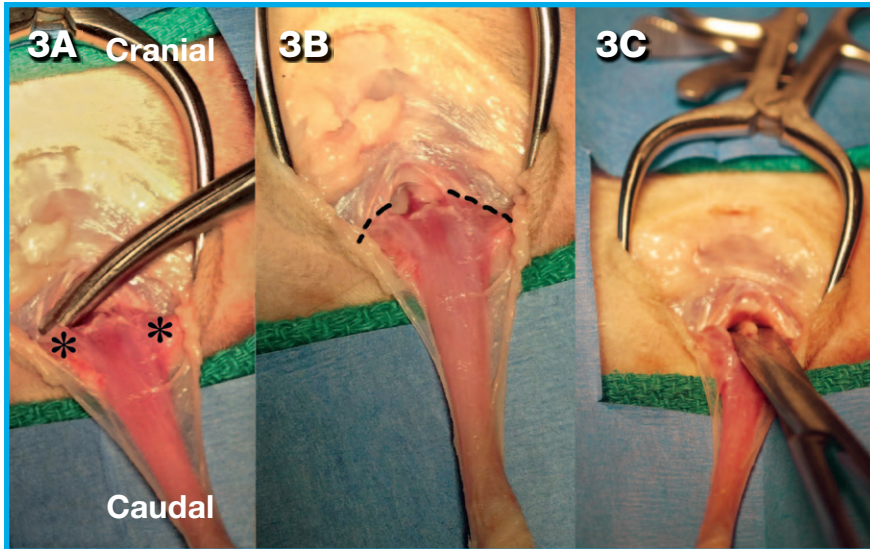
- » Pay close attention to penile orientation in this technique (ie, dorsal versus ventral side).
- » When the penis is pulled **caudally**, toward the tail, the surgeon is working on its **ventral aspect**.
- » When the penis is reflected **cranially**, toward the cat's head, the surgeon is working on the **dorsal aspect**.
- » Minimal delicate peripenile dissection is carried out on the **dorsal aspect** of the penis, as this is where the primary neurovascular supply is located.³
- » When dissecting the **dorsal aspect** of the penis, the surgeon is also in close proximity to the rectum, which is undesirable because it increases the risk of rectal perforation



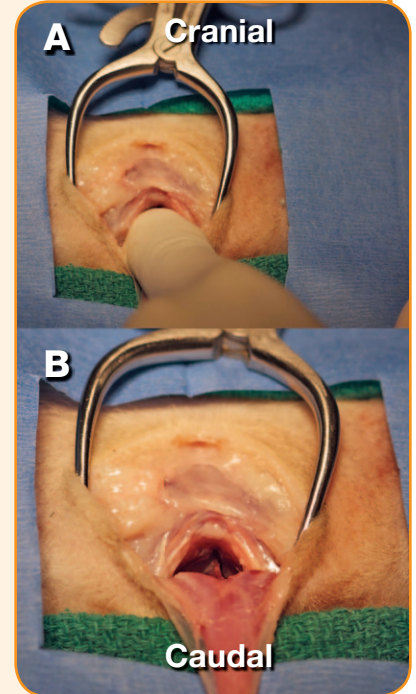
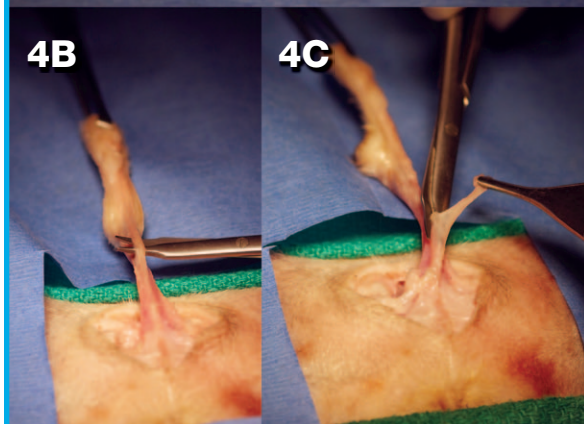
2 If the cat is intact, perform a routine castration. The urethra can be catheterized with a Tomcat catheter to aid identification and manipulation. Make a symmetric, elliptical incision around the scrotum and penis (**A**) at the junction of the perineal and scrotal skin. Perform a circumferential dissection of the subcutaneous connective tissues to isolate the penis (**B**).



3 With the penis pulled caudally, dissect the ventral connective tissue to isolate the paired ischiocavernosus muscles (A, asterisks), which attach the penis to the pelvis (see **Surgical Insight: Ischiocavernosus Muscles**). Transect these muscles at their attachment to the ischium (B, dotted line); then sharply and bluntly dissect the ventral penile ligament until the penis can be freely retracted caudally from any ventrolateral pelvic attachments (C).



4 The penis is now reflected cranially, allowing the surgeon to work on its dorsal aspect (A). Identify the thin retractor penis muscle on the dorsal midline directly overlying the urethra (B). Carefully isolate it, and use a combination of blunt and sharp dissection with Metzenbaum or Stevens tenotomy scissors to free and transect its attachment to the penis (C).

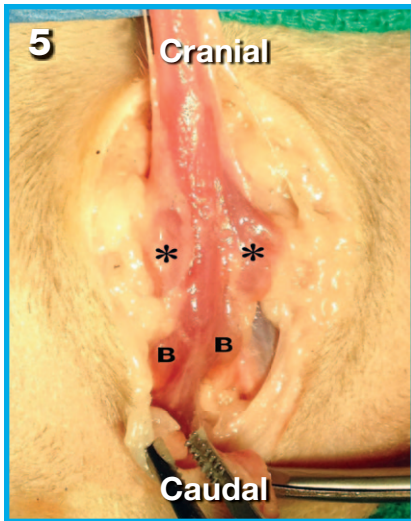


SURGICAL INSIGHT: ISCHIOCAVERNOSUS MUSCLES

- » Sharp transection of the ischiocavernosus muscles close to their ischial attachment limits hemorrhage from the body of the muscle.
- » Ventral dissection is considered sufficient when the surgeon can place a finger between the penis and ischium within the pelvic canal. Palpate the space between the penis and ischium to confirm sufficient ventral dissection (A and B).

Collaboration on Continuing Education

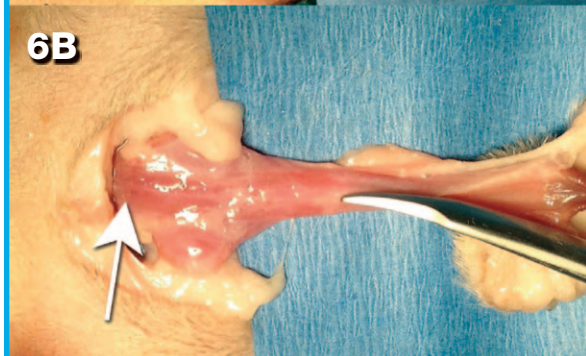
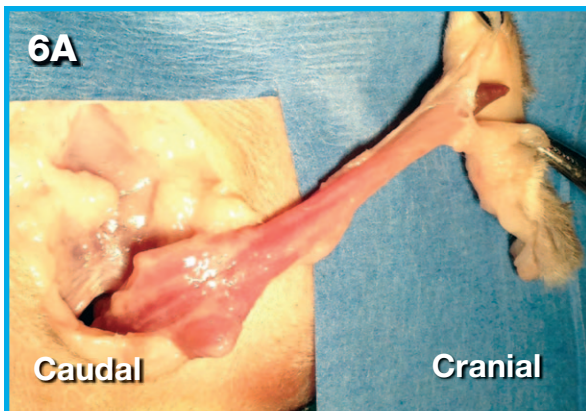
Turn to page 6 to read this issue's **Editor's Note** in which Editor in Chief, Dr. Lesley King, and NAVC Conference Coordinator, Dr. David Senior, provide more details about this collaborative column and how it meets the goals of both *Today's Veterinary Practice* and the **North American Veterinary Community** with regard to providing the highest quality continuing education for veterinary professionals.



5 Use the transected and isolated retractor penis muscle as a guide for continued careful dorsal dissection in the same tissue plane, which exposes the urethra to the level of the paired bulbourethral glands. Dorsal dissection is

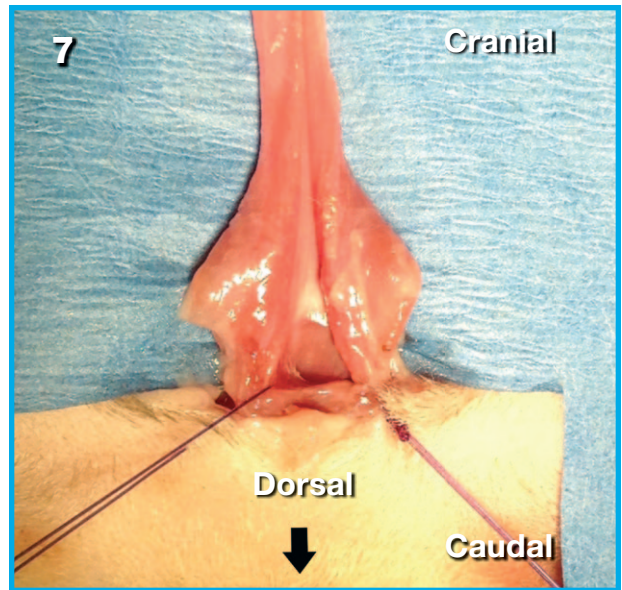
complete once the paired bulbourethral glands (**B**) are identified dorsolateral to the transected ischiocavernosus muscles (**asterisks**). Do *not* carry out any further dorsal peri-penile dissection once these glands are visualized.

6 Transect the scrotal and preputial skin to expose the tip of the penis (**A**), and remove the urethral catheter. Use Stevens tenotomy scissors to make a longitudinal incision into the urethral lumen, starting distally and continuing on the dorsal midline to the level of the bulbourethral glands (**B**, white arrow). See **Surgical Insights: Bulbourethral Glands and Urethrotomy Incision**.



SURGICAL INSIGHT: BULBOURETHRAL GLANDS

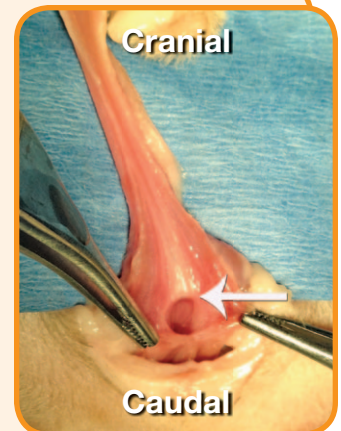
- » The transected paired ischiocavernosus muscles are sometimes misidentified as the bulbourethral glands.
- » These paired glands typically lie adjacent and just proximal to the transected muscles, lending a “butterfly” appearance to the penis and surrounding structures.
- » Identify these glands because they serve as key landmarks for the junction of the more narrow penile urethra and wider membranous pelvic urethra.

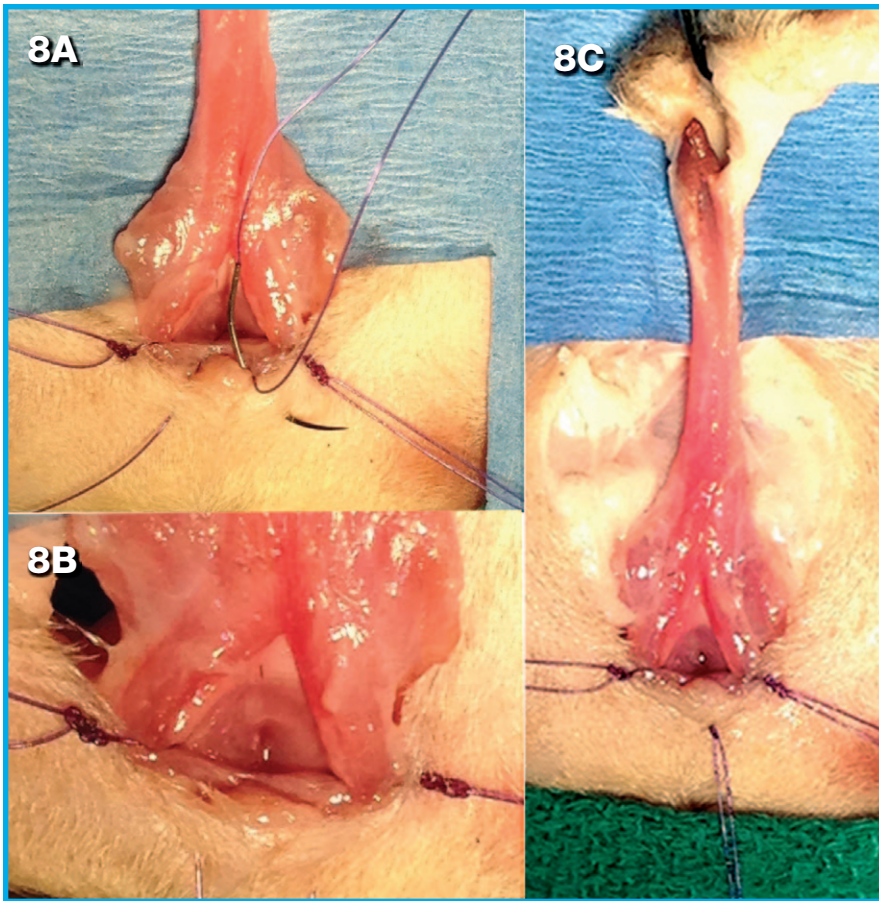


7 If the urethrostomy opening is thought of as a clock face (with the dorsal aspect pointing toward the anus at 6 o'clock), the most critical sutures are at the 6, 4, and 8 o'clock positions. The 4 o'clock and 8 o'clock interrupted sutures are placed first, leaving the suture ends long as stay sutures to aid in retraction of the tissues.

SURGICAL INSIGHT: URETHROTOMY INCISION

- » Make sure the urethrotomy incision is on the dorsal midline and is carried out to the level of the bulbourethral glands (ie, the widest point of the penile urethra).
- » Identify this junction by a visible pale line in the urethral mucosa at the level of the bulbourethral glands (**white arrow**).
- » If the urethrotomy is *not carried far enough*, the urethrostomy lumen will be too narrow.
- » If the urethrotomy is *carried too far*, there will be excessive tension on the PU site.
- » The ideal urethrostomy site lies 2 to 3 mm proximal to the penile urethra within the wider membranous urethra.

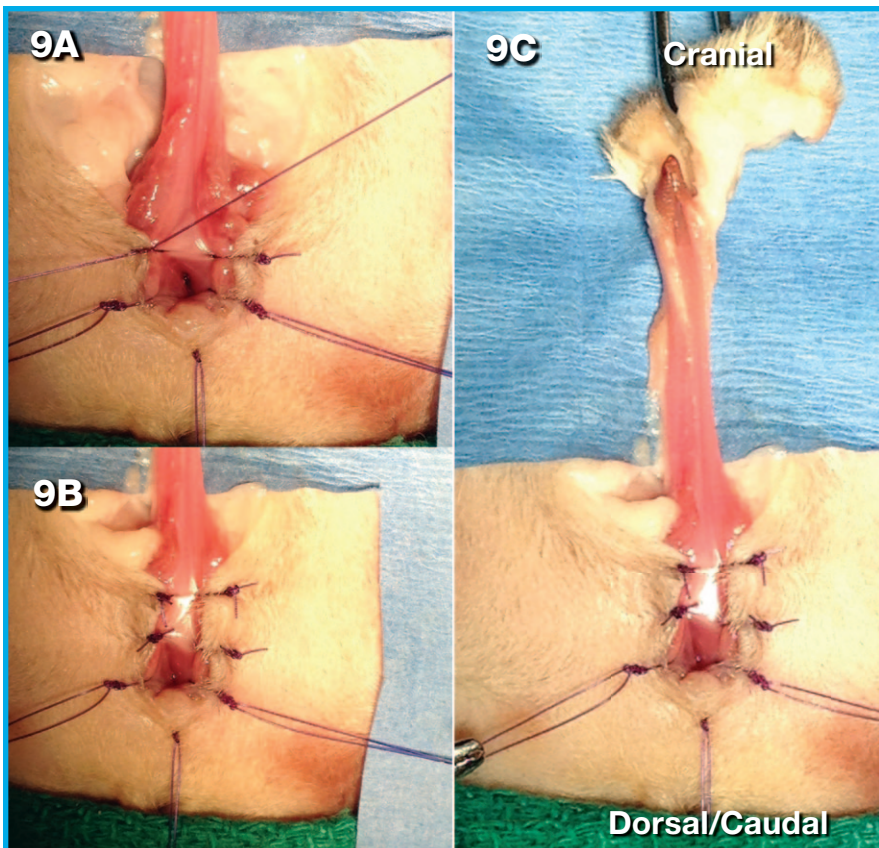




- 8** A mattress suture can be placed in the 6 o'clock position (see **Surgical Insights: Sutures and Tissue Handling**). This tissue bite sequence has 4 steps. The needle:
1. Engages split thickness skin (A)
 2. Penetrates the urethral mucosa (into urethral lumen) (B)
 3. Passes back through the urethral mucosa (from lumen out) (C)
 4. Passes split thickness skin.

SURGICAL INSIGHT: SUTURES

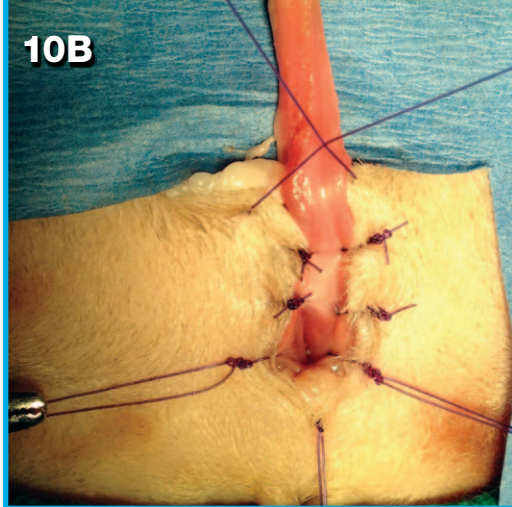
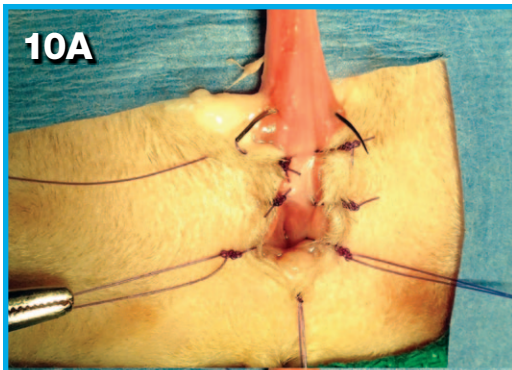
- » It is critical to identify the cut edge of the urethral mucosa (glistening pale tissue plane medial to the adjacent red cavernous tissue) and achieve perfect apposition of mucosa to skin.
- » A 5-0 synthetic absorbable monofilament suture on a taper-cut needle is ideal.
- » Encompass 2 to 3 individual tissue bites during each suture pass:
 1. Urethral mucosa
 2. Fibrous tunica albuginea (this bite may be included with the first)
 3. Split thickness skin.
- » Absorbable suture material does not require removal, which makes its use advantageous.



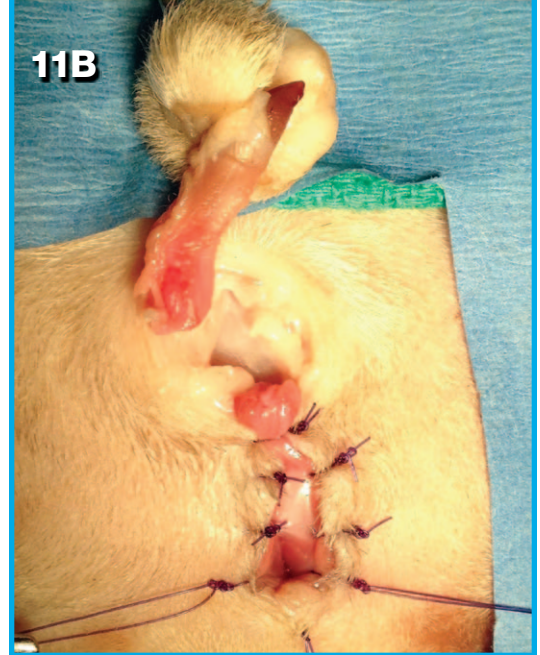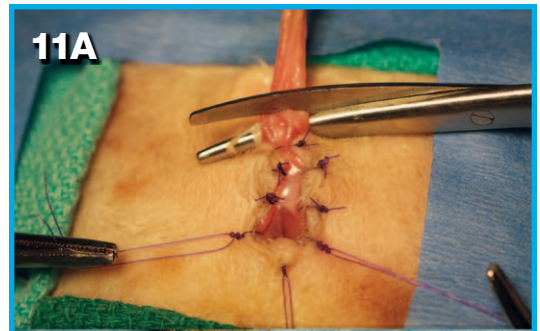
- 9** The remaining interrupted sutures of the PU site are placed in a dorsal to ventral sequence (A through C).

SURGICAL INSIGHT: TISSUE HANDLING

- » Do not grasp the fragile urethral mucosa or skin with forceps.
- » Instead, grasp only the adjacent fibrous tunica albuginea and hypodermal layer of the skin.
- » Dissipating mild hemorrhage with saline lavage and suction will facilitate visualization of tissue planes.

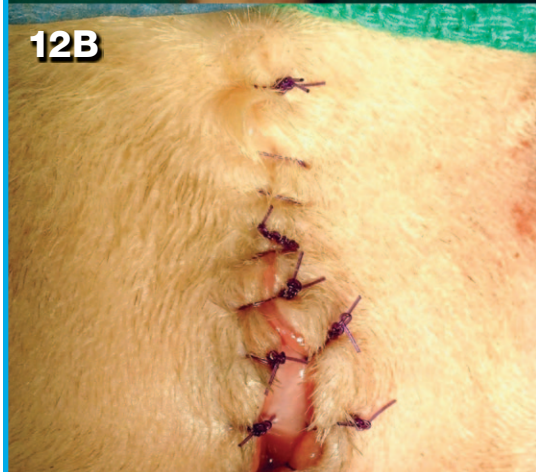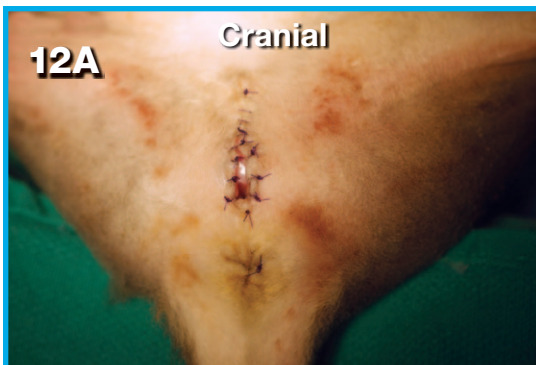


10 Following transection of the penis, the most ventral suture (A) should act as an encircling suture to ligate the penile stump (B); thus, controlling penile hemorrhage. Alternatively, a separate encircling suture can be placed around the penile stump.



11 The penis is amputated (A and B).

12 Complete the PU by closing the remaining skin incision using a simple continuous or interrupted pattern (A and B).



POSTOPERATIVE MANAGEMENT

Postoperative management includes:

- Appropriate pain management
- Monitoring urine output
- Continuation of IV fluid diuresis (at least 24 H post-surgery)
- Ensuring the patient cannot damage the repair (eg, E-collar, litter that will not adhere to the surgery site).

A postoperative indwelling urethral catheter is not indicated in a routine PU.

COMPLICATIONS

Educate owners about potential acute complications, such as hemorrhage, re-obstruction, urine dissection into the subcutaneous tissues, incisional dehiscence, urinary tract infection, urine scald, incontinence, and stricture.^{1,4,5}

Although the management of such complications is beyond the scope of this article, adhering to the basic surgical principles of delicate tissue handling, careful dissection, tension-free closure, and perfect mucosa-to-skin apposition should minimize occurrence of such complications.

Recurrent bacterial cystitis is the most common late complication, and appropriate ongoing medical management of the underlying FLUTD helps prevent it.^{4,5}

PROGNOSIS

The overall prognosis following PU is good, with around 90% of clients reporting a satisfactory long-term quality of life.^{4,5}

FLUTD = feline lower urinary tract disease; PU = perineal urethrostomy

SAVE THE DATE

The **NAVC Institute 2015** takes place July 26 through 31 in Orlando, Florida.

References

1. Williams J. Surgical management of blocked cats. Which approach and when? *J Feline Med Surg* 2009; 11:14-22.
2. Wilson GP, Harrison JW. Perineal urethrostomy in cats. *JAVMA* 1971; 159:1789-1793.
3. Sackman JE, Sims MH, Krahwinkel DJ. Urodynamic evaluation of lower urinary tract function in cats after perineal urethrostomy with minimal and extensive dissection. *Vet Surg* 1991; 20:55-60.
4. Ruda L, Heiene R. Short- and long-term outcome after perineal urethrostomy in 86 cats with feline lower urinary tract disease. *J Small Anim Pract* 2012; 53:693-698.
5. Bass M, Howard J, Gerber B, Messmer M. Retrospective study of indications for and outcome of perineal urethrostomy in cats. *J Small Anim Pract* 2005; 46:227-231.



Clara S.S. Goh, BVSc, MS, Diplomate ACVS, Founding Fellow Surgical Oncology, is a faculty surgeon at Colorado State University College of Veterinary Medicine and Biomedical Sciences. She graduated from Sydney University (Australia), and completed her internship, surgery residency, and surgical oncology training at CSU.



Howard B. Seim III, DVM, Diplomate ACVS, is on the surgical team at Colorado State University College of Veterinary Medicine and Biomedical Sciences. He was chief of CSU Small Animal Surgery and founder of VideoVet, a veterinary

surgery continuing education video series (videovet.org). He was selected as the NAVC 2009 Small Animal Speaker of the Year. He received his DVM from Washington State University, and completed a 2-year surgical residency at The Animal Medical Center in New York City.