



News

NAVC Brands

Search ...



IVERHART MAX
Chew
(ivermectin/pyrantel pamoate/praziquantel)



The protection dogs need.
Nothing they don't.

Learn More

©2022 Virbac Corporation. All rights reserved. IVERHART MAX is a registered trademark of the Virbac Group of Companies. 7/22 15228

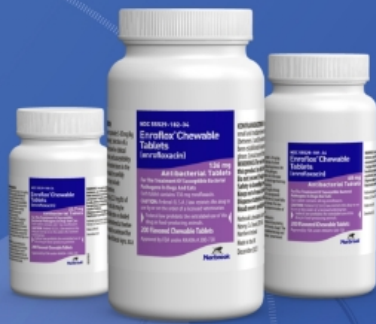

TVP

TODAY'S VETERINARY PRACTICE

Articles ▾ CE Library Resources ▾ About ▾ Publication ▾

Subscribe



RELIABLE, AFFORDABLE,
CHEWABLE

Introducing Enroflox[®] Chewable Tablets (enrofloxacin)

LEARN MORE



Enroflox Chewable Tablets
(enrofloxacin)

PEER REVIEWED

RADIOLOGY/IMAGING

Small Animal Pelvic Radiography

Issue: **January/February 2012**

Small Animal Pelvic Radiography - Featured Image

This is the third article in our Imaging Essentials series—a series focused on providing critical information on radiography of the dog and cat. Read the first two articles, [Small Animal Thoracic Radiography](#) (September/October 2011) and [Small Animal](#)

[Abdominal Radiography](#) (November/December 2011), at todaysveterinarypractice.com.

TICKS CAN SPREAD OVER 15 TYPES OF DISEASES...INCLUDING LYME DISEASE¹



HEARTWORM DISEASE

TICKS² & FLEAS

ROUNDWORMS & HOOKWORMS³

Simparica TRIO

(sarolaner, moxidectin, and pyrantel chewable tablets)

TRY SIMPARICA TRIO >

black-legged tick, and brown dog tick. ¹*Toxocara canis*, *Toxascaris leonina*, *Ancylostoma caninum*, and *Uncinaria stenocephala*.

SEE FULL PRESCRIBING INFORMATION >

Editor's Picks


The purpose of this article is to review the three basic components of creating high-quality pelvic radiographs of the dog and cat, including

positioning, technique, and quality control of the final images.

Pelvic radiographs are used in:

SPONSORED **Stretch Their Protection**

Get 2 months of flea, tick, and heartworm protection.



LEARN MORE

- Cases of trauma
- Evaluation of lameness
- Evaluation of congenital disorders (eg, hip dysplasia).

PELVIC RADIOGRAPHIC EXPOSURE

For any dog measuring 15 cm or greater (measured at the iliac crest), a grid (8:1, 110 lines per inch) should be used. Grids are available from most radiology manufacturers and a grid tray comes with all radiology units. The techniques for the ventrodorsal and lateral radiographic projections of the pelvis are the same. For dogs measuring less than 15 cm or cats, a tabletop technique is preferred (no grid).

If using direct or indirect digital radiography, then the imaging receptor remains fixed in the grid cabinet or within the table. If using a computed radiography system, the cassette and imaging plate can be used in a tabletop fashion, similar to film screen combinations.

ROUTINE RADIOGRAPHIC VIEWS

A routine radiographic examination of the pelvis consists of two orthogonal radiographs, including a lateral image and an extended leg ventrodorsal image. The stifle joints (through the level of the proximal crus) are included in both images.

Lateral Images

Positioning

For a lateral image of the pelvis, the patient is positioned on the table with the right side down for a right lateral image and left side down for a left lateral image. For cases, such as pelvic fractures or lameness, the side of concern should be the dependent side, which is placed closest to the table.



Personal/Professional Development

Veterinary Innovation Summit 2022



Personal/Professional Development

The Evolution of Mentorship for Veterinary Professionals

A right lateral image of the pelvis is standard.



The pelvic limbs should be taped separately with a sponge placed between them to ensure that the right and left hemipelves are aligned and directly superimposed.

The pelvic limb that is closest to the x-ray table is taped in a cranial position, whereas the limb away from the table is placed in a caudal position so the pelvic limbs are in a scissor position, with the stifle joints separate and not overlapping (**Figure 1**).

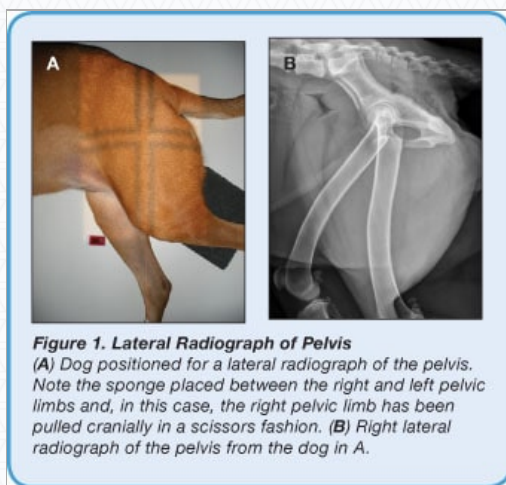


Figure 1. Lateral Radiograph of Pelvis
(A) Dog positioned for a lateral radiograph of the pelvis. Note the sponge placed between the right and left pelvic limbs and, in this case, the right pelvic limb has been pulled cranially in a scissors fashion. (B) Right lateral radiograph of the pelvis from the dog in A.

Collimation

Start by setting the collimator light (field of view or FOV) to the same size of the cassette or detector by using the corresponding numbers next to the collimator knobs (see [Small Animal Abdominal Radiography](#), November/December 2011). Then adjust the collimation to the actual size of the patient's pelvis and pelvic limbs (typically smaller than the original collimator light setting).

- **Cranial Border:** Place the vertical center of the FOV along the axis of the greater trochanter (upper leg). The greater trochanter should be midway between the iliac crest and ischiatic tuberosity. The cranial border of the collimator light (FOV) should be placed cranial to the iliac crest.

- **Caudal Border:** The caudal border of the collimator light should be placed at the level of the ischiatic tuberosity or caudal skin margin in the perineal region.
- **Dorsal Border:** The vertical portion of the FOV should extend dorsal to iliac crest and greater trochanter (skin margin of dorsal pelvis).
- **Distal Border:** Adjust the horizontal center of the collimator light so that it is midway between the dorsal skin surface and distally includes the stifle joints and proximal crura.

Ventrodorsal Images

Positioning

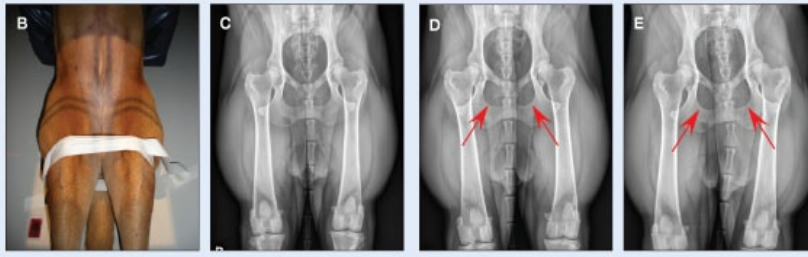
The patient should be placed in dorsal recumbency in a positioning V-trough (**Figure 2**). Using a V-trough helps keep the patient's vertebral column and sternum aligned and the pelvis in a straight position. To avoid superimposed artifacts from the V-trough, the entire pelvis should be positioned past the edge of the trough and placed on the x-ray table. This positioning also helps decrease geometric magnification of the image.

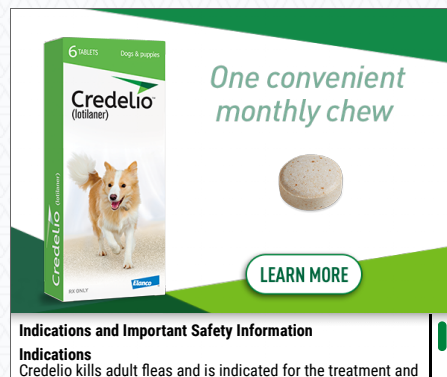
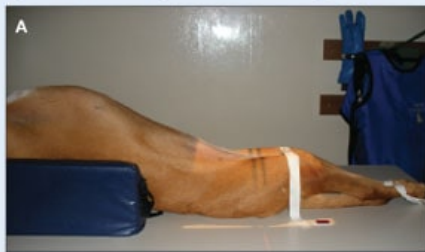
Figure 2. Extended-Leg Ventrodorsal Radiographs of Pelvis



(A) Lateral view of a dog that has been placed in dorsal recumbency in a V-trough (positioning trough) with the pelvis being pulled caudal to the V-trough. The pelvic limbs have been extended and are taped at the level of the stifle joints for appropriate positioning of the pelvic limbs relative to the pelvis, table, and each other.



(B) Another view of dog positioned for an extended-leg ventrodorsal radiograph. (C) Routine radiograph of the pelvis from the dog in A and B. Note the symmetry of the size and shape of the obturator foramina. (D and E) Oblique or rotated radiographs where the pelvis was positioned incorrectly; note the asymmetry of the obturator foramina (arrows). For D, the right side of the dog's pelvis should be pulled up (away from the table slightly) to correct this positioning abnormality. For E, the left side of the dog's pelvis should be pulled up (away from the table slightly) to correct this positioning abnormality.

- Tape the thoracic limbs together and pull them cranially to help align the vertebral column. This, in turn, will aid in keeping the pelvis straight. Each pelvic limb should be taped separately and extended evenly.
- Once the pelvic limbs have been extended, which typically requires the patient be adequately sedated, internally rotate the femurs so that they are parallel to one another and the x-ray table.
- When properly aligned, the patella for each pelvic limb will be centered within the trochlear groove over the distal femur. Secure the dog's pelvic limbs in this position using tape around the femurs at the level of the stifle joint (**Figures 2A and 2B**).

Collimation

Use the same procedures for setting the collimator light as described earlier for lateral images.

- **Cranial Border:** The cranial border of the collimator light (FOV) should be placed cranial to the iliac crest. Palpate the iliac crests and place the cranial edge of the collimator light just cranial to this level.
- **Caudal/Distal Border:** The caudal/distal border of the collimator light should be placed just distal to the stifle joints to allow the proximal crura to be included in the image.
- **Lateral Borders:** Close the collimator light laterally so the light is next to the skin on both the right and left sides. Add a film marker (R/L) for identifying the right or left side prior to exposure.

ADDITIONAL RADIOGRAPHIC VIEWS

Frog-Leg Ventrodorsal Images

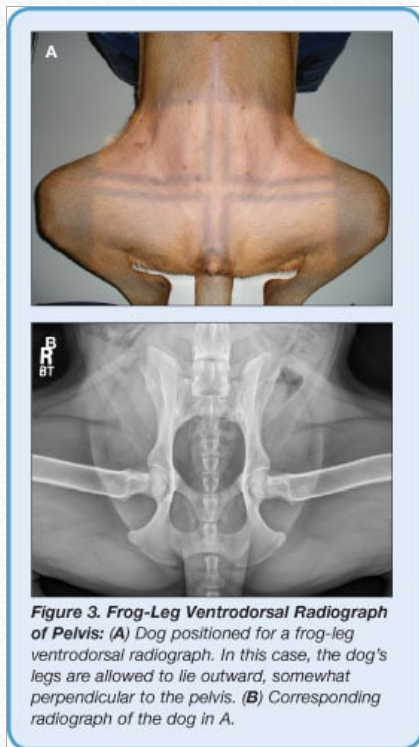
Dogs and cats with severe coxofemoral degenerative joint disease or fractures of the pelvis, femoral head/neck, or femur are not physically able to extend their femurs in the standard extended-leg ventrodorsal position.

In this case, a frog-leg ventrodorsal image can be used for initial assessment. In addition, in dogs or cats with capital physal fractures of the femoral head, extending the limbs into the routine position can actually reduce the fracture and render the fracture indistinguishable from the normal limb. In this case, the frog-leg ventrodorsal image should be used to confirm the fracture.



Positioning

Use a V-trough to help keep the patient's vertebral column and sternum aligned (**Figure 3**). As with standard ventrodorsal images, avoid superimposed artifacts caused by the V-trough by placing the entire pelvis past the edge of the trough onto the x-ray table, which also decreases geometric magnification.



- Tape the thoracic limbs together and pull cranially to help align the vertebral column that will, in turn, aid in keeping the pelvis straight.

- Place the pelvic limbs in a natural flexed position so that the femurs are at approximately ninety degrees to the spine and pelvis.

Collimation

- **Cranial Border:** The cranial border of the collimator light (FOV) should be placed cranial to the iliac crest based on palpation.
- **Caudal Border:** The caudal border of the collimator light should be placed just caudal to the ischiatic tuberosity.
- **Lateral Borders:** Close the collimator light laterally so the collimation includes at least the mid to distal femoral level. The stifle joints will need to be radiographed separately as necessary. Add a film marker (R/L) for identification of the right or left side prior to the exposure.

Orthopedic Foundation for Animals

Established in 1966, the Orthopedic Foundation for Animals' (OFA) mission has been to:

- Distribute information concerning orthopedic and genetic diseases
- Educate and establish control programs to lower the incidence of these diseases in animals.
- For hip dysplasia certification, OFA requires a straight, extended-leg ventrodorsal view of the pelvis.
- The femurs need to be extended and parallel to each other; the stifle joints need to be rotated internally so the pelvis is straight and symmetric (**Figure 2**).
- Chemical restraint is recommended to ensure a high-quality radiograph the first time and avoid repeats at the owner's expense.

For more detailed information regarding OFA certification, registry, details on radiographic requirements, and forms, veterinarians and/or technicians can visit offa.org.

Pennsylvania Hip Improvement Program


In 1993, Dr. Gail Smith from the University of Pennsylvania School of Veterinary Medicine established the Pennsylvania Hip Improvement Program (PennHIP) distraction technique as a method for assessing coxofemoral joint laxity.

The technique provides a quantitative measure of canine coxofemoral joint laxity using a standardized distraction technique:

- The routine views for submission include:
 - An extended-leg ventrodorsal view (standard OFA projection)

- A flexed pelvic limb ventrodorsal compression view
- A distraction flexed pelvic limb ventrodorsal view (**Figure 4**).
- This last projection requires use of a specialized distraction frame apparatus that is made available to trained and certified PennHip members. Specific details regarding PennHIP evaluation can be found at pennhip.org.

c03_fig4



QUALITY CONTROL

For quality control of any diagnostic image, keep a simple 3-step approach in mind:

1. Determine if the technique is appropriate.
2. Ascertain if the appropriate anatomy is present within the image.
3. Check the correct anatomic positioning for laterality and straightness.

Technique & Anatomy

Given that the desired technique has been attained, make sure that the appropriate anatomy is included: the lateral and ventrodorsal projections should include the cranial aspect of the iliac crest, pelvis, coxofemoral joints, and the proximal tibia, including the stifle joints.

Patient Positioning

Lateral Projection

- The transverse processes of the caudal lumbar vertebrae should be superimposed to determine if a patient is in a true lateral position. The right and left sides should form a single “Nike” swoosh (**Figure 5**).

c03_fig5

- Remember that in the larger dog, due to magnification, the iliac crest and femur furthest away from the cassette or detector will appear larger than the recumbent side.
- The ischia should be superimposed on the lateral projections; the dorsal acetabular rims should be superimposed.

Ventrodorsal Projection

- Each caudal lumbar spinous process is viewed end-on and has a distinct diamond or tear-drop shape.
- The obturator foramina should be symmetrical in shape and equal in size.
- The femurs should be parallel to each other.
- The patellas should be superimposed over the distal femoral trochlear groove in a normal dog. If the dog or cat has luxation of the patella, the patella may be laterally or medially displaced relative to the distal femur.
- The lateral aspects of the ischiatic tuberosities will overlap evenly along the medial aspect of the proximal femurs (Figures 2C, page 49, and 4A, page 51).

Pelvic Radiography Summary

Pelvic radiographs are used in:

- Cases of trauma
- Evaluation of lameness
- Evaluation of congenital disorders (eg, canine or feline hip dysplasia).

High-quality, correctly positioned radiographs are required in order to provide an accurate assessment, especially for surgical implant planning. A routine radiographic series of the pelvis should include a lateral and ventrodorsal view. Choosing the lateral projection used depends on the side of lameness and whether pelvic or femoral fractures are present. If the pelvic examination is routine, a right lateral of the pelvis is standard.

Following a consistent, repeatable pattern for obtaining pelvic radiographs ensures the quality of the images will be diagnostic.

FOV = field of view; OFA = Orthopedic Foundation for Animals; PennHIP = Pennsylvania Hip Improvement Program

References



Subscribe for More

Stay current with the latest techniques and information – sign up below to start your FREE Today's Veterinary Practice subscription today.

[Start My Subscription](#)



[Advertising Opportunities](#)