



# Lateral Approach to Subtotal Bulla Osteotomy in Dogs: Pertinent Anatomy and Procedural Details\*

Daniel D. Smeak, DVM, DACVS

Nongnuch Inpanbutr, DVM, PhD

The Ohio State University

## ABSTRACT:

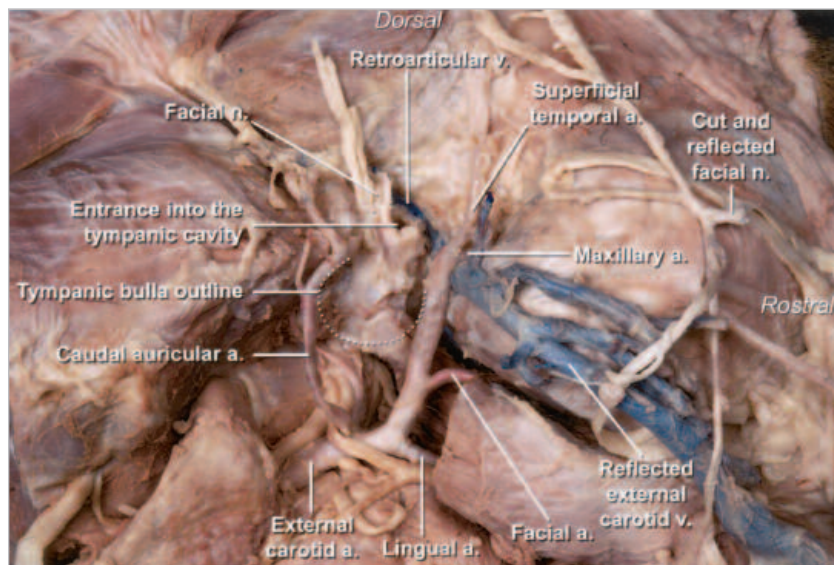
Lateral bulla osteotomy (LBO) is routinely performed with total ear canal ablation (TECA) to expose and debride tissue and exudate deep within the tympanic cavity. Because TECA permanently eliminates drainage from the middle ear through the external meatus, there is risk of intractable deep wound infection and sinus formation resulting from poor tympanic cavity debridement. Furthermore, the regional anatomy is complex and poorly exposed, and neurovascular damage during LBO can lead to acute life-threatening and/or long-standing complications. Most current surgery textbooks just briefly describe the LBO technique, and only limited access to the tympanic cavity can be achieved as it is described. This article presents detailed anatomic and procedural descriptions to provide maximal tympanic cavity exposure while avoiding complications during and after LBO in dogs.

Otitis media is often associated with long-standing otitis externa in dogs.<sup>1</sup> Accumulated bacteria and debris in the horizontal ear canal can eventually access the tympanic cavity, causing middle ear infection.<sup>2</sup> As the infection becomes established, the tympanic membrane and ear canal epithelium become thickened and hyperplastic, and dystrophic calcification often occurs in the cartilage. In end-stage middle ear infection, the epithelium undergoes metaplasia with new bone proliferation of the tympanic bulla (referred to as *bulla osteitis*), which serves as a resistant nidus of infection. Cholesteatomas, an unusual and aggressive sequelae to chronic inflammatory middle ear dis-

ease, is thought to form from a pocket of the tympanic membrane that becomes displaced and adheres to the inflamed mucosa in the tympanic cavity.<sup>3</sup> As cells shed from the keratinized membrane, an enlarging cystic structure develops within the bulla, resulting in extensive bone resorption and remodeling of the bulla. Surgery to completely remove this debris and adherent epithelium within the tympanic cavity is indicated when medical therapy is either no longer effective or not likely to be successful, particularly when signs of chronicity (i.e., end-stage changes) or cholesteatoma exist on radiographic imaging of the bullae. Because chronic otitis externa is the most common cause of middle ear disease, total ear canal ablation (TECA) combined with lateral bulla osteotomy (LBO) of the tympanic bulla is the most common procedure for accessing the tympanic cavity. This com-

Full-text articles and CE testing at [CompendiumVet.com](http://CompendiumVet.com). Send comments/questions via email [compendium@medimedia.com](mailto:compendium@medimedia.com), fax 800-556-3288, or web [CompendiumVet.com](http://CompendiumVet.com).

\*Funded by The Ohio State University Veterinary Alumni Association.



**Figure 1.** Lateral view of a dissected head showing entrance into the tympanic cavity after the annular cartilage and entire cartilaginous external ear canal have been excised from the rim of the osseous EAM. Note the close approximation of the facial nerve and maxillary artery and vein to the rim of the EAM. (a = artery; n = nerve; v = vein)

bined approach allows complete removal of chronically diseased ear canal tissue and permits exposure of the tympanic cavity through the same incision.<sup>4</sup>

Incomplete removal of epithelium from the tympanic cavity and unsuccessful treatment of the secondary infection have been implicated as the major causes of severe deep-seated infection of the middle ear after TECA and LBO for chronic end-stage otitis. Furthermore, when deep infection occurs following TECA and LBO, the patient's pain and suffering may be worse than the original smoldering ear condition and reexploration of the bulla is difficult and expensive, so it is of utmost importance to avoid this complication.<sup>5,6</sup> Deep dissection after removing the ear canal may be the most difficult and dangerous portion of TECA and LBO. Therefore, some surgeons try to avoid aggressive LBO in fear that additional deep dissection poses an increased risk of facial nerve or inner ear damage or profuse hemorrhage. However, if epithelium and debris extend into the tympanic cavity, the surgeon cannot feel confident that remote recesses of the cavity have been adequately debrided without aggressive LBO.

General small animal surgical textbooks would be incomplete without a thorough discussion of TECA and LBO because it is a common procedure performed by experienced soft tissue surgeons. Despite the impor-

tance of achieving complete tympanic bulla debridement for successful TECA and LBO, we have found only one informative description of tympanic LBO (performed on experimental dogs) in the literature.<sup>6</sup> Furthermore, we could find no article that thoroughly describes and illustrates important procedural and anatomic details in dogs with end-stage ear disease. Surprisingly, most recent surgical texts and symposia only briefly mention regional anatomy and have little more than a few sentences about removing as much of the lateral bulla as necessary with rongeurs or air-driven burrs to adequately expose the tympanic cavity.<sup>4,5,7-9</sup> Although we acknowledge there are many different successful methods of performing LBO, in our experience, the method described in this article offers excellent exposure of the tympanic cavity while avoiding undue risk of iatrogenic neurovascular trauma. This article pro-

vides a detailed anatomic description of structures pertinent to LBO, an illustrated step-by-step surgical procedure to safely and extensively expose the tympanic cavity, and guidelines for safe debridement and curettage within the tympanic cavity.

## INSTRUMENTATION AND SUPPLIES

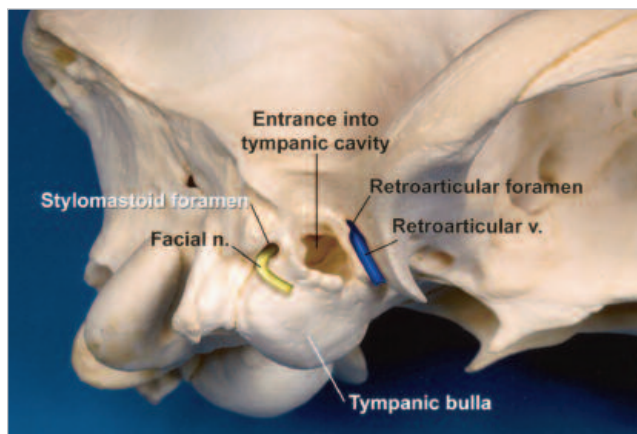
In addition to instruments included in a standard general surgery pack, several types of bone rongeurs and retractors are required for TECA and LBO. We prefer Cleveland or Zaufal rongeurs to remove the thicker bone of the lateral tympanic bulla and osseous external auditory meatus (EAM). In large- or giant-breed dogs with thick bones, double-action Ruskin rongeurs should be considered. A Kerrison down-bite laminectomy punch can be useful for safe bone removal from the caudal aspect of the EAM. Delicate Lempert or Beyer rongeurs can help clean up rough edges of the osteotomy site. In lieu of rongeurs, some surgeons equipped with air-driven instruments prefer burrs to remove bone. Freer periosteal elevators are used to reflect soft tissue attached around the ventral-lateral bulla face. For retraction, delicate Senn and the larger Army-Navy retractors suffice. We try to avoid using Gelpi retractors during deep dissection because they may increase the risk of iatrogenic trauma to the facial

nerve or regional vascular structures. If the surgeon must perform this surgery alone, carefully placed Weitlaner retractors can be useful. Angled 00 or 0 Daubenspeck bone curettes and malleable Halle bone curettes are useful for reaching deep recesses in the tympanic cavity.

Culture vials should be available to obtain bacterial isolation from debris or tissue removed from the tympanic cavity. Containers should be on hand for biopsy samples of tissue obtained during surgery.

## REGIONAL ANATOMY

During resection of the cartilaginous external ear canal (i.e., EAM) from the skull, the location of structures surrounding the lateral aspect of the osseous ear canal should be appreciated. The facial nerve exits the stylomastoid foramen ventral to the mastoid process at the 11 o'clock position in relation to the osseous ear canal. In chronic end-stage ear conditions, the nerve is often intimately adhered to the deep ear canal as it courses rostrally, just lateral to the bulla. The external carotid artery and maxillary vein lie immediately ventral to the tympanic cavity and must be safely retracted away from the tips of the rongeurs while the ventral aspect of the bulla is being removed (Figure 1). Sharp dissection and curettage of the rostral aspect of the osseous ear canal should be avoided to reduce the risk of retroarticular vein damage (Figure 2). During debris and epithelial evacuation of the tympanic cavity, curettage should be avoided in the rostral aspect to preserve the ossicles and sensitive inner ear



**Figure 2.** Close-up, oblique ventrolateral view of important deep structures surrounding the tympanic bulla of the skull. The retroarticular vein is located just rostral to the entrance to the osseous ear canal and tympanic bulla. A distinct bony rim separates the osseous EAM from the stylomastoid foramen (i.e., exit site for the facial nerve). (n = nerve; v = vein)

the EAM, and expose the entire circumference of the proximal horizontal ear canal with blunt and sharp dissection. The stylomastoid foramen is separated from the EAM by a distinct, readily palpable, sharp bone ridge along the caudal aspect of the EAM. Sever the attachment of the horizontal canal from the EAM with a #15 Bard Parker blade, and remember to direct the sharp blade edge away from the course of the facial nerve. Do not be concerned if a small fringe of cartilage remains

***The regional anatomy of the tympanic bulla is complex and poorly exposed during surgery, and neurovascular damage during LBO can lead to acute life-threatening and/or serious long-standing complications.***

structures. The internal carotid artery can be damaged if the thin bone wall between the carotid canal and tympanic cavity is disrupted by excessive medial pressure during curettage of the medial bulla wall (Figure 3).

## SURGICAL PROCEDURE

### Removing the Ear Canal

Excise the cartilaginous ear canal as described for TECA.<sup>4</sup> Identify and protect the facial nerve trunk as it courses from the stylomastoid foramen just caudal to

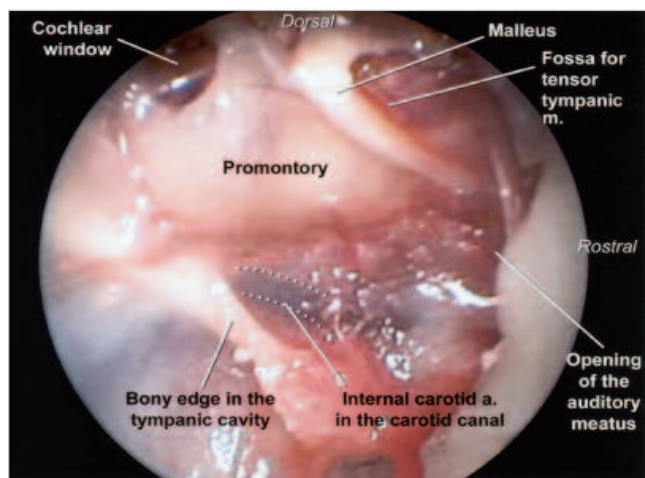
attached to the EAM (Figure 4). If the canal attachment is ossified, disconnect the ear canal from the EAM using bone rongeurs.

### Preparing the Bulla for Osteotomy

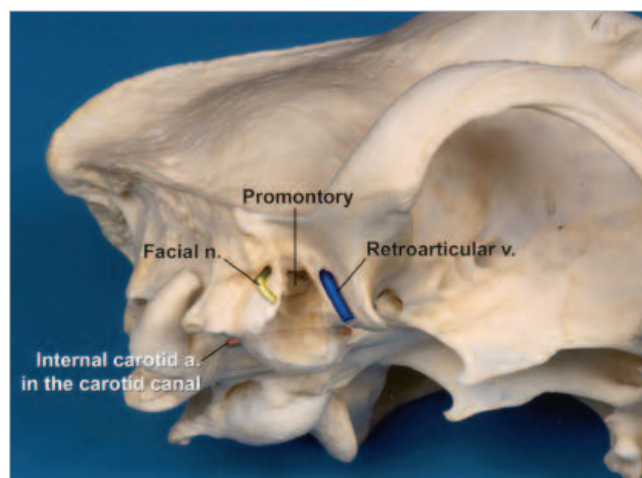
As the tympanic bulla is approached, take into account that the bulla may be extensively remodeled (expanded) from a mounting cholesteatoma or chronic bulla osteitis. Important neurovascular structures are more tightly draped around an expanded bulla (than what is shown in



**Figure 3. Oblique ventrolateral views of the tympanic cavity and skull.** (*a* = artery; *m* = membrane; *n* = nerve; *v* = vein)



Oblique ventrolateral view of important structures within the rostrrodorsal compartment of the tympanic cavity. The arch-shaped malleus is located in the rostrrodorsal aspect of the cavity referred to as the *epitympanic recess*. In the most rostral aspect of the cavity is the opening of the auditory tube, an area often lined with ingrown secretory epithelium from the external ear canal. This epithelium must be completely excised during LBO. Note the promontory and cochlear windows, which house the inner ear structures. A portion of the large fundic compartment of the tympanic cavity is well exposed caudally.

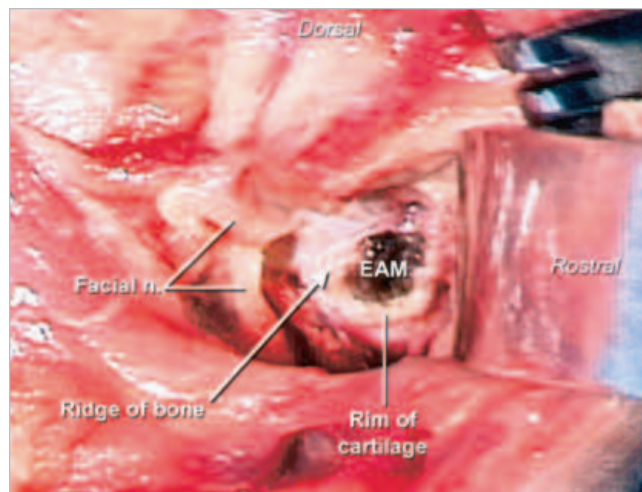


Oblique ventrolateral view of the skull after the lateral wall of the tympanic bulla has been removed. The internal carotid artery, a major blood supply to the brain, is illustrated. The internal carotid artery enters the caudal carotid foramen in the petrooccipital fissure and traverses in the carotid canal. The medial wall of the tympanic bulla forms the lateral wall of the carotid canal.

the cadaver images). This close anatomic relationship greatly increases the risk of iatrogenic damage if the following steps are not carefully completed. Always keep in mind the location of the facial nerve and attempt to place retractors lateral (or more superficial) to the nerve. We believe overzealous retraction during attempts at exposing deep structures during LBO is a major cause of temporary postoperative facial nerve dysfunction. Bluntly dissect soft tissue directly from the lateral and ventral aspects of the tympanic bulla with Freer elevators. Avoid stray dissection along the bulla, particularly rostral to the EAM (to spare the retroarticular vein) and ventral to the bulla (to avoid the carotid artery, maxillary vein, and their branches).

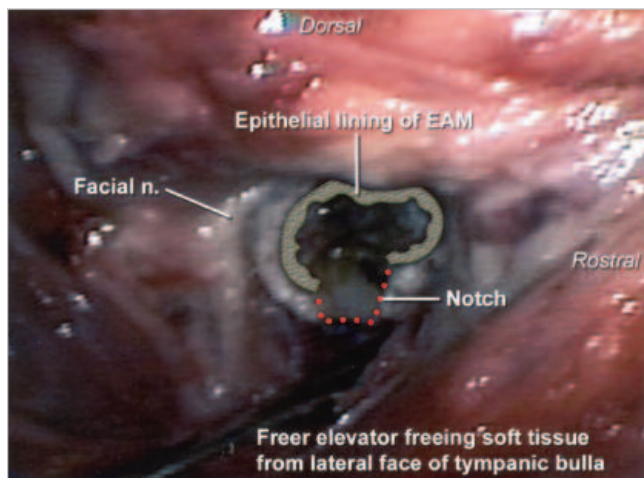
### Tympanic Bulla Excision

Using Freer elevators, pry and retract the soft tissue from the ventral aspect of the bulla (Figure 5). During the entire LBO procedure, make sure you visualize what is caught in the jaws of the rongeurs to help avoid inadvertent damage to important surrounding soft tissue. Begin bone removal with Cleveland or Lempert rongeurs (this choice depends on the thickness of bone and size of the patient), and take controlled bites from the floor of



**Figure 4. Surgeon's lateral view of EAM after the cartilaginous ear canal has been excised.** A thin rim of cartilage remains attached at the EAM. Note the location of the facial nerve and stylomastoid foramen. A prominent ridge (*arrow*; a consistent landmark) divides the EAM and foramen. (*n* = nerve)

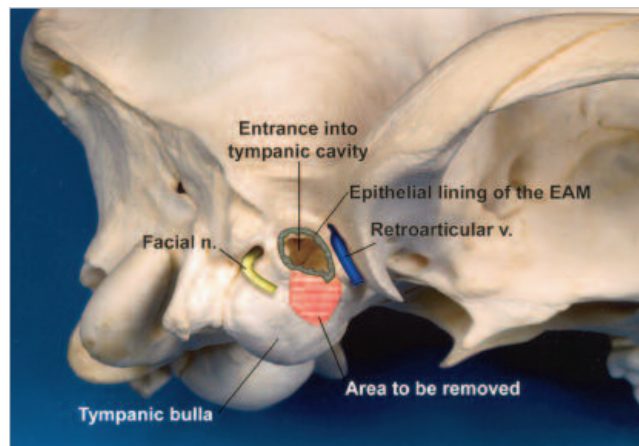
the EAM. This will create a notch in the soft tissue lining and ventral bony floor of the EAM (Figures 5 and 6). Using Freer elevators, attempt to peel the remaining soft tissue from the osseous ear canal by starting blunt dissection at the cut edge of epithelium just adjacent to the



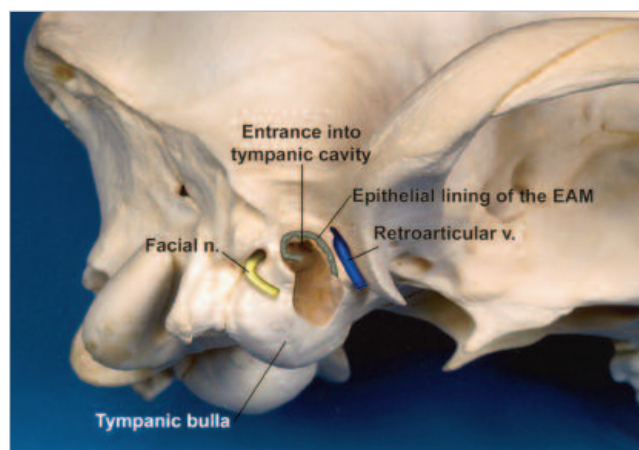
**Figure 5.** Soft tissue has been reflected and pried away from the lateral face of the tympanic bulla with a Freer elevator. A rongeur is used to create a notch in the ventrolateral floor of the osseous EAM. This maneuver helps free edges of epithelium lining the osseous EAM so the lining can be removed completely in one piece. (n = nerve)

notch. Once this dissection is complete, the EAM will appear as a shiny white surface throughout its circumference. The osseous ear canal is usually the thickest part of the tympanic bulla to remove during LBO. Continue bone removal from the ventral osseous ear canal and into the ventral tympanic cavity with bone rongeurs. If the bulla is sclerotic and proliferative, removing the ventral aspect of the osseous ear canal may be very difficult. Using an air-driven burr or Ruskin and Kerrison rongeurs may help remove this bone. Collect samples of tissue and debris, and submit them for biopsy and culture or susceptibility testing. Gently elevate the facial nerve trunk from the caudal (vertically oriented) shelf of bone between the stylomastoid foramen and the EAM. Next, carefully remove this vertical sharp bony ridge with Lempert rongeurs (Figure 7). This allows gentle elevation of the facial nerve from the lateral face of the caudolateral tympanic bulla. Keeping the nerve retracted with the Freer elevator, try to angle Cleveland or Lempert rongeurs into the EAM and remove the bone on the lateral aspect of the caudal tympanic bulla. If this is not possible, we prefer Kerrison rongeurs to begin bone removal ventral to the stylomastoid foramen just caudal to the EAM (Figure 8). Bone is very brittle and hard in this area, but once the shelf and bone just caudal to the EAM have been removed, the remaining caudal bulla bone is usually thinner and easier to excise (Lempert rongeurs will suffice here). Do not attempt to rongeur bone rostrally because

**Figure 6.** Lateral aspect of the skull showing the epithelial lining of the EAM. (n = nerve; v = vein)



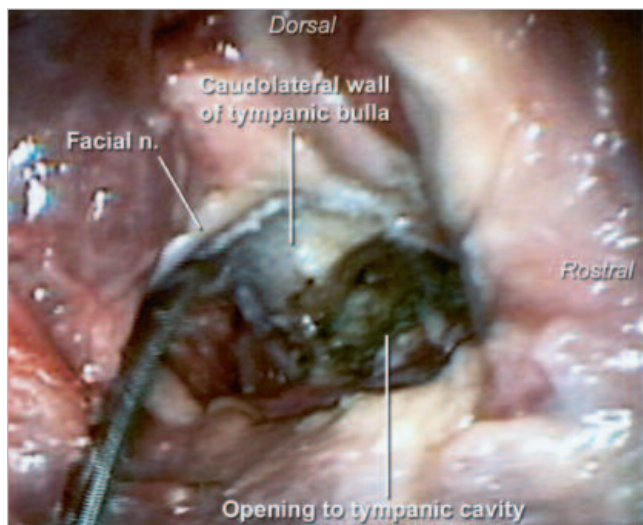
The notch to be created in the ventral floor of the osseous ear canal is indicated as described in Figure 5. The epithelial tissue lining the ear canal is also indicated.



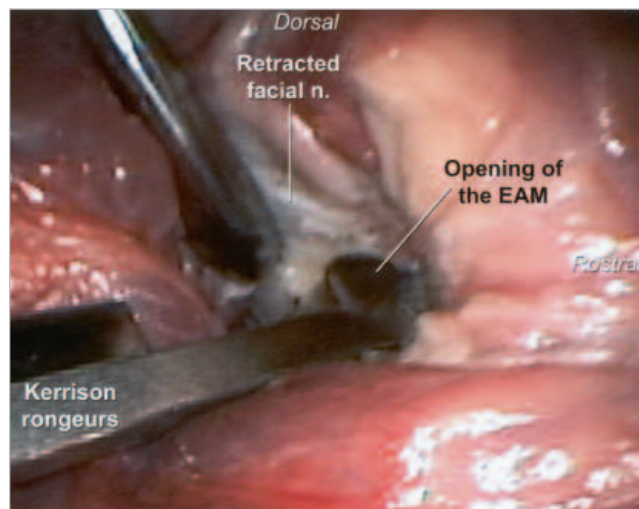
While the freed edge is grasped, the epithelial “cuff” is elevated both rostrally and caudally (the epithelium is shown elevated partially on the caudal aspect) from the osseous ear canal beginning at the notched area. The ridge of bone separating the EAM from the stylomastoid foramen is now well exposed.

structures of the epitympanic recess could be damaged and the retroarticular vein may be torn. The retroarticular vein cannot be exposed readily and is usually not evident to the surgeon unless it is damaged. If brisk hemorrhage is encountered in the rostral aspect of the EAM, use a cotton-tipped swab and apply pressure to the origin of the bleeding area. Remember that the retroarticular foramen opens ventrally, not laterally, just rostral to the EAM, so bone wax must be pushed in a dorsomedial direction to fill the foramen and maintain hemostasis. The LBO is complete once most of the lateral and ventral aspect of the





**Figure 7.** While the facial nerve is protected with a Freer elevator, the ridge of bone between the EAM and foramen is removed with a Lempert rongeur and the facial nerve is isolated and retracted caudally. ( $n$  = nerve)



**Figure 8.** A Kerrison rongeur is used to begin removing the caudolateral aspect of the tympanic bulla while the facial nerve is protected with the elevator. ( $n$  = nerve)

tympanic bulla has been removed. This creates a large window to adequately view the tympanic cavity interior.

### Tympanic Cavity Evacuation

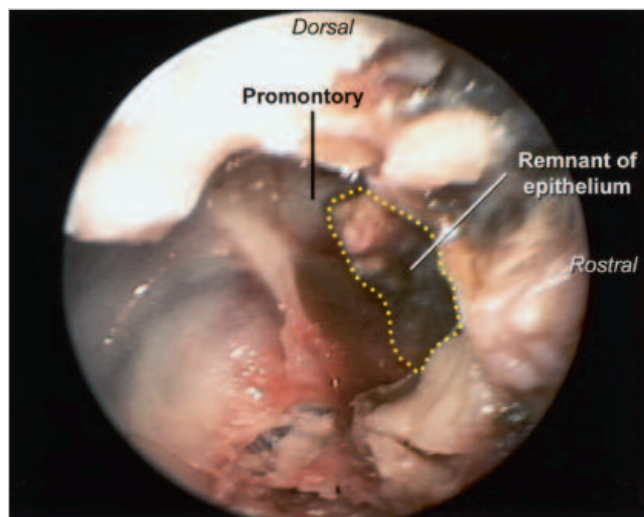
Carefully inspect the interior aspect of the tympanic cavity after irrigating the area with tepid sterile saline solution. When normal, the bulla is lined with a thin transparent epithelium, which does not need to be disturbed. If the external ear disease is chronic and there

9). The sock of epithelium is generally easy to remove. Grasp the edge of the epithelium with hemostats, and while placing traction on the tissue, use Freer elevators or a Daubenspeck curette to separate the attachments and remove the entire undisturbed epithelial cuff. If discolored or abnormal soft tissue clings from the dorsal compartment, carefully tease off the tissue with fine-tipped, curved hemostats. The ossicles are usually found tucked in the dorsal epitympanic recess just

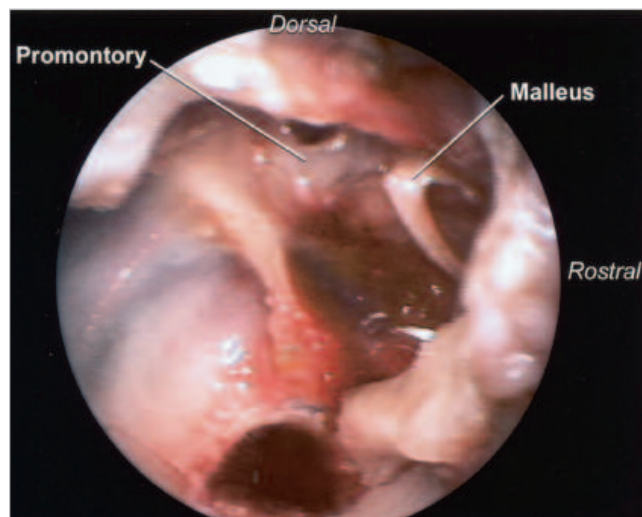
## ***Incomplete evacuation of epithelium from the tympanic cavity has been implicated as the major cause of intractable deep-seated infection of the middle ear after TECA and LBO have been performed for chronic end-stage otitis.***

are signs of bulla osteitis, the tympanic cavity is usually (either partially or completely) lined with greenish-brown to dark brown hyperplastic epithelial tissue. In most cases, a small cavity is found just within the rostral tympanic cavity (adjacent to the opening of the auditory tube), in which a “sock” of epithelium (sometimes called *false middle ear* or *acquired cholesteatoma*) is found.<sup>10,11</sup> In either case, all abnormal epithelium inside the tympanic cavity should be removed (Figure

medial to the bony dorsal rim of the EAM. There is no need to remove the ossicles unless abnormal soft tissue or the tympanum is adhered to them. Avoid curettage of the thin promontory area housing sensitive inner ear structures (Figure 9). Excessive downward (medial) force with the curette on the medial surface of the tympanic cavity should be avoided because bone covering the carotid canal (housing the internal carotid artery) can be penetrated, causing pro-

**Figure 9.** Lateral views of tympanic bulla after removing the caudal and lateral aspects of the bulla.

A greenish epithelial remnant in the rostral compartment of the cavity must be removed entirely without damaging the malleus and promontory.



Excellent exposure of the completely evacuated tympanic cavity is achieved with the described subtotal bulla osteotomy technique.

fuse hemorrhage. If this occurs, tightly pack the cavity with gauze stripping, wait 5 minutes (until hemostasis is established), and then slowly and gently remove the packing to continue the inspection. Daubenspeck or malleable curettes should be used to scrape the rostral, ventral, and caudal tympanic cavity. Tissue should be submitted for histopathologic evaluation. Carefully inspect the epitympanic recess and the EAM for remnants of abnormal epithelium or retained tympanum. Irrigate and then inspect the entire tympanic cavity again, and remove any remaining suspicious tissue and bony fragments. Figure 10 compares the tympanic cavity exposure achieved after the described subtotal LBO with that of previously described LBO techniques.

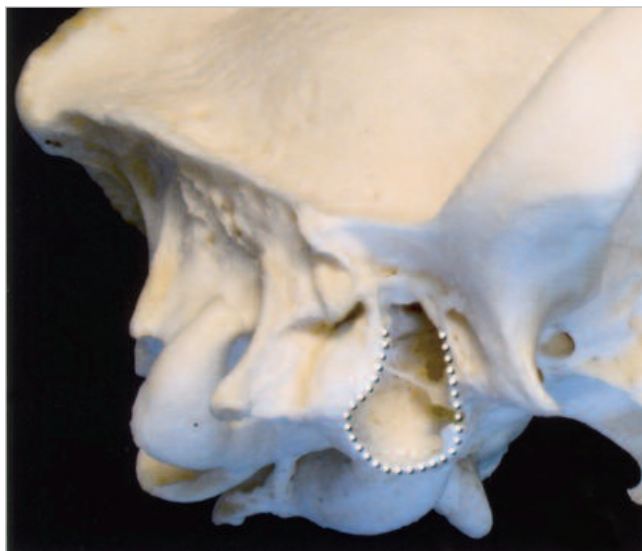Ideally, an active suction drain system (Jackson-Pratt) is recommended in patients with heavy intraoperative contamination, uncontrolled bleeding, concurrent paraaural abscessation, or a bulla that is difficult to clean out properly. Before wound closure, the fenestrated tubing should be placed within the wound dead space and tympanic cavity and exited through the skin caudomedial to the ear pinna (and fixed with a purse string and finger-trap suture). Alternately, if an active drainage system is unavailable and drainage is necessary, a passive surgical drain (i.e., Penrose drain) may be used. Using blunt dissection with Rochester Pean or Carmalt forceps, the drain should be tunneled from the bulla ventrally and exited through a separate

stab incision under the original TECA incision. Follow tissue planes during blunt tunneling, and never force the forceps through the tissue because severe hemorrhaging may occur. If the tissue surrounding the wound is minimally contaminated, inflamed, or hemorrhaging and the tympanic cavity has been thoroughly evacuated, there is usually no need for wound drainage.<sup>12</sup> Dead space is reduced during subcutaneous closure, and the skin should be closed routinely to complete the TECA.

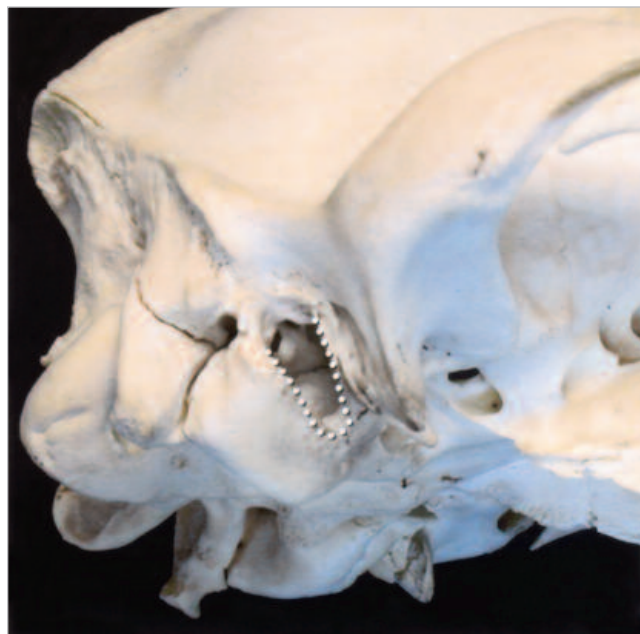Patients undergoing TECA and LBO often show evidence of extreme postoperative pain due to inflammation and nerve stimulation from deep wound dissection and bone removal. The surgeon must be prepared to aggressively manage this pain both preemptively and postoperatively. General postoperative guidelines for managing small animals after TECA and LBO are beyond the scope of this paper but are discussed elsewhere.<sup>8,9,12-15</sup>

## CONCLUSION

The main goal of LBO is to adequately expose the tympanic cavity. Poor evacuation of the bulla during TECA and LBO may ultimately result in intractable deep infection—a problem that is often clinically worse for the patient than the original external and middle ear disease. Therefore, we and others<sup>6</sup> recommend aggressive LBO when debris or abnormal tissue

**Figure 10. Skulls comparing tympanic exposure via different LBO techniques.**

Lateral view of the skull showing aggressive (preferred) excision of the lateral bulla through exposure of the tympanic cavity. The dotted line indicates the excision margin of the tympanic bulla.



Lateral view of the skull with limited excision of the tympanic bulla. The dotted line shows the extent of bone removed in "traditional" descriptions of the procedure in the veterinary literature. This limited approach provides poor exposure, particularly in the caudal aspect of the tympanic cavity.

is seen extending into the tympanic cavity during TECA. Although TECA is straightforward and well described in the veterinary literature, LBO has not been explained thoroughly. This article clarifies the anatomy of the regional, bulla, and tympanic cavity and describes technical details to improve exposure while minimizing the risk of complication during and following LBO.

Additional images and video of lateral bulla osteotomy will be available online in July 2005 at [vet.osu.edu/SurgeryAnatomyTechniques](http://vet.osu.edu/SurgeryAnatomyTechniques).

## ACKNOWLEDGMENT

The authors thank Ms. Elizabeth Mahle (The Ohio State University) for her assistance with dissecting the specimen and Mr. Tim Vojt (The Ohio State University) for his assistance with the illustrations.

## REFERENCES

1. Cole LK, Kwochka KW, Kowalski JJ, Hillier A: Microbial flora and antimicrobial susceptibility patterns of isolated pathogens from the horizontal ear canal and middle ear in dogs with otitis media. *JAVMA* 212:534–538, 1998.
2. Little CJ, Lane JG, Pearson GR: Inflammatory middle ear disease in the dog: The pathophysiology of otitis media. *Vet Rec* 128:293, 1991.
3. Little CJ, Lane JG, Gibbs C, Pearson GR: Inflammatory middle ear disease of the dog: The clinical and pathological features of cholesteatoma, a complication of otitis media. *Vet Rec* 128:319–322, 1991.
4. Smeak DD: Total ear canal ablation and lateral bulla osteotomy, in Bojrab MJ (ed): *Current Techniques in Small Animal Surgery*. Baltimore, Williams & Wilkins, 1998, pp 102–109.
5. Smeak DD, Crocker CB, Birchard SJ: Treatment of recurrent otitis media after total ear canal ablation and lateral bulla osteotomy in dogs: Nine cases (1986–1994). *JAVMA* 209:937–942, 1996.
6. McNulty JF, Hattel A, Harvey CE: Wound healing and brain stem auditory evoked potentials after experimental total ear canal ablation with lateral tympanic bulla osteotomy in dogs. *Vet Surg* 24:1–8, 1995.
7. Krahwinkel DJ: External ear canal, in Slatter D (ed): *Textbook of Small Animal Surgery*. Philadelphia, WB Saunders, 2003, pp 1746–1756.
8. Smeak DD, Kerpsack S: Total ear canal ablation and lateral bulla osteotomy for management of end-stage otitis externa. *Sem Vet Med* 8:30–41, 1993.
9. Fossum TW: Surgery of the ear, in Fossum TW (ed): *Small Animal Surgery*, ed 2. St. Louis, Mosby, 2002, pp 229–239.
10. Lesinskas E, Kasinskas R, Vainutiene V: Middle ear cholesteatoma: Present-day concepts of etiology and pathogenesis. *Medicina (Kaunas)* 38(11):1066–1071, 2002.
11. Davidson EB, Brodie HA, Breznock EM: Removal of a cholesteatoma in a dog, using a caudal auricular approach. *JAVMA* 211(12):1549–1553, 1997.
12. Devitt CM, Seim HB, Willer R, et al: Passive drainage versus primary closure after total ear canal ablation–lateral bulla osteotomy in dogs: 59 dogs (1985–1995). *Vet Surg* 26:210–216, 1997.
13. Buback JL, Boothe HW, Carroll GL, et al: Comparison of three methods of pain relief after ear canal ablation in dogs. *Vet Surg* 25:380–385, 1996.
14. Mathews KA: Management of pain. *Vet Clin North Am Small Anim Pract* 30(4), 2000.
15. Muir WW: Pain and stress, in Gaynor JS, Muir WW (eds): *Handbook of Veterinary Pain Management*. St. Louis, Mosby, 2002, pp 46–59.



**ARTICLE #4 CE TEST**

*This article qualifies for 2 contact hours of continuing education credit from the Auburn University College of Veterinary Medicine. Subscribers may purchase individual CE tests or sign up for our annual CE program. Those who wish to apply this credit to fulfill state relicensure requirements should consult their respective state authorities regarding the applicability of this program. To participate, fill out the test form inserted at the end of this issue or take CE tests online and get real-time scores at [CompendiumVet.com](http://CompendiumVet.com).*

- 1. The main goal of LBO is to**
  - a. expose the tympanic cavity for thorough evacuation of the bulla.
  - b. remove as much of the chronically infected tympanic bulla as possible.
  - c. drain the tympanic cavity.
  - d. completely remove soft tissue from the osseous ear canal.
  
- 2. The main reason some surgeons tend to be less aggressive with LBO includes risk of**
  - a. hemorrhage, particularly ventral to the bulla.
  - b. facial nerve damage.
  - c. inner ear damage.
  - d. all the above
  
- 3. \_\_\_\_\_ should be avoided or used with extreme care when performing LBO.**
  - a. Freer elevators
  - b. Kerrison rongeurs
  - c. Army-Navy retractors
  - d. Gelpi retractors
  
- 4. The first aspect of LBO following removal of the entire external ear canal is**
  - a. completely stripping the epithelium from the osseous ear canal.
  - b. elevating the facial nerve from the lateral face of the tympanic bulla.
  - c. using a rongeur to remove the ventral aspect of the osseous ear canal.
  - d. bluntly dissecting soft tissue ventral to the bulla.
  
- 5. Cutting tissue with a rongeur and elevating it just rostral to the opening of the osseous ear canal increases the risk of injuring the**
  - a. facial nerve.
  - b. trigeminal nerve.
  - c. maxillary artery.
  - d. retroarticular vein.
  
- 6. Epithelial remnants are most often found in the \_\_\_\_\_ aspect of the tympanic cavity.**

a. ventral	c. dorsomedial
b. caudal	d. rostradorsal
  
- 7. The most common result of incomplete evacuation of the tympanic cavity is**
  - a. chronic, intractable middle ear infection.
  - b. partial facial nerve deficits.
  - c. acute wound infection that is responsive to antibiotics.
  - d. inner ear infection and chronic neurologic signs.
  
- 8. Injury to the internal carotid artery can result from**
  - a. levering soft tissue from the ventral aspect of the bulla.
  - b. soft tissue dissection from the rostral aspect of the horizontal ear canal.
  - c. curettage of the medial aspect of the tympanic bulla.
  - d. curettage of the rostral aspect of the tympanic bulla.
  
- 9. Which statement regarding the technical aspects of evacuating the tympanic cavity is false?**
  - a. All abnormal epithelium and debris should be excised.
  - b. The ossicles should be removed because they can form a nidus of infection.
  - c. Curettage of the dorsal aspect should be avoided because the promontory could be damaged.
  - d. Aggressive removal of the ventrolateral aspect dramatically helps expose the tympanic cavity for evacuation of debris.
  
- 10. Which statement regarding the need for passive drainage after TECA and subtotal LBO is false?**
  - a. A drain should be placed if there is heavy contamination, hemostasis is poorly controlled, or the tympanic cavity is difficult to clean out properly.
  - b. A Penrose drain should be placed with blunt dissection using forceps and tunneled ventrolateral to the bulla.
  - c. When a tunnel is being created for a drain, forceps should never be forced through the soft tissue.
  - d. The drain usually exits at the ventral aspect of the vertical T incision created for TECA.