Oral Tumors

Associated Terms:
Tumors of the Mouth , Maxillectomy, Mandibulecomy, Melanoma, Ossifying Epulis, Fibrous Epulis, Epulis, Mouth or Jaw Cancer, Acanthomatous Ameloblastoma

Overview:

Is that lump you're seeing in your dog's mouth normal? Or is it something to be concerned about? The easiest way to know for sure is to have it evaluated by a veterinarian.

A tumor is an abnormal growth or enlargement. There are many kinds of tumors that can occur in a dog's mouth. Sometimes inflammation & infection will cause swelling & redness of the oral tissues that could mimic a tumor. Periodontal disease can also be a cause of gingival overgrowth called gingival hyperplasia, which may look like excessive gum tissue growing up around one or many teeth. This is benign process & it is NOT cancerous.

This dog has an example of a non-cancerous growth- **Gingival Enlargement** (or gingival hyperplasia). This is the result of periodontal disease, and can be treated by local removal and proper preventative dental care.

There are also many other types of growths that occur in the mouths of dogs that can be benign (non- cancerous) or malignant (cancerous). These are often difficult to tell apart without diagnostic tests to tell us what the growth looks like microscopically & on x-rays. When a mass shows rapid growth, we become more concerned that the growth may be malignant.

Many of the tumors we see in dogs tend to be benign- these include odontogenic tumors that arise from tooth-associated tissues, such as odontomas & fibromas, as well as other types of tumors such as granulomas, osteomas & others. Some of the tumors we see are malignant, the most common of which are Melanoma, SCC, Fibrosarcoma & Acanthomatous Ameloblastoma.

These tumors tend to invade the underlying jawbone, can grow rapidly, & sometimes can spread to other body organs such as the LNs or lungs. Unfortunately for us, many of these tumors, benign & malignant, look the same on the outside, & we can only diagnose those by getting a biopsy.

This dog has a growth at the lower incisors – It was diagnosed as a **benign** tumor called a Peripheral Odontogenic Fibroma.

This dog has a growth around his mandibular 1st molar tooth- This was diagnosed as a **malignant** squamous cell carcinoma- Very difficult to tell apart based on appearances alone!

FOAMS (Malignant Oral Cancer Acronym)

1. Fibrosarcoma
2. Osteosarcoma
3. Acanthomatous Ameloblastoma
4. Melanoma
5. Squamous Cell Carcinoma

Tumors of the oral cavity can arise from the bone, teeth or soft tissue structures of the lower (mandible) or upper (maxilla) jaw, or the tongue or pharynx. Most tumors of the oral cavity are malignant: malignant melanoma & Squamous Cell Carcinoma (SCC) are the most common oral tumors in dogs & cats.

Benign oral tumors are also common & include acanthomatous ameloblastoma & peripheral odontogenic fibroma. Surgery is usually recommended for the treatment of most malignant & benign oral tumors, but other options may be available depending on the tumor type.

Other treatment options, such as radiation therapy, chemotherapy &/or immunotherapy, may also be indicated for certain oral tumors instead of or in addition to surgery.

Oral tumors are relatively common in cats & dogs. Benign & malignant tumors of the oral cavity account for 3-12% of all tumors in cats & 6% of all tumors in dogs. Malignant melanoma & SCC are the most common oral tumors in dogs & SCC is the most common oral tumor in cats.

Oral Malignant Melanoma (OMM)

OMM arises from the pigmented cells located in the soft tissues that line the tongue, cheeks & jaws in the oral cavity of dogs & is one of the most common types of oral tumors. Certain breeds are predisposed to this type of cancer, including Golden retrievers, Dachshunds, Scottish terriers & poodles, though any breed can get this type of cancer. Most of the time, they are pigmented (& look black or dark brown like the one in this picture), though a small percentage may be non-pigmented (& look white or pink). Unfortunately, this type of cancer has a high rate of metastasis (spread to other areas of the body) to the lymph nodes (LNs) & lungs. If your dog is diagnosed with this type of cancer, we recommend having chest x-rays & LN biopsy performed prior to surgery to make sure that it has NOT spread. Surgery to remove the primary tumor & an appropriately wide margin of normal tissue can result in a good long-term outcome for of this type of cancer. Alternative therapy can include radiation therapy & chemotherapy. How well your dog will do after being diagnosed with OMM depends greatly on how big the tumor is when it is diagnosed, as well as whether it has already spread.

Squamous Cell Carcinoma (SCC)

This is one of the most common types of oral cancer in both dogs & cats, which arises from the tissues that line the surface of the mouth & throat. Often times these tumors are red (inflamed) & ulcerated & can cause significant oral pain. They also readily invade the underlying soft tissue & jaw bone. The prognosis is typically good to excellent when this disease is limited to the oral cavity (around the teeth, the cheeks or the tongue). However, if it is arising from the tonsils, the cancer tends to behave much more aggressively with a high rate of distant spread. Treatment for this type of cancer is surgical removal of the main tumor, which often involves removing a portion of the underlying bone as well. If we can achieve complete removal of the local tumor, then we can cure this type of cancer. However, if it has spread elsewhere, or is too large, we may need to include other therapies, including radiation therapy or chemotherapy, to treat your pet.

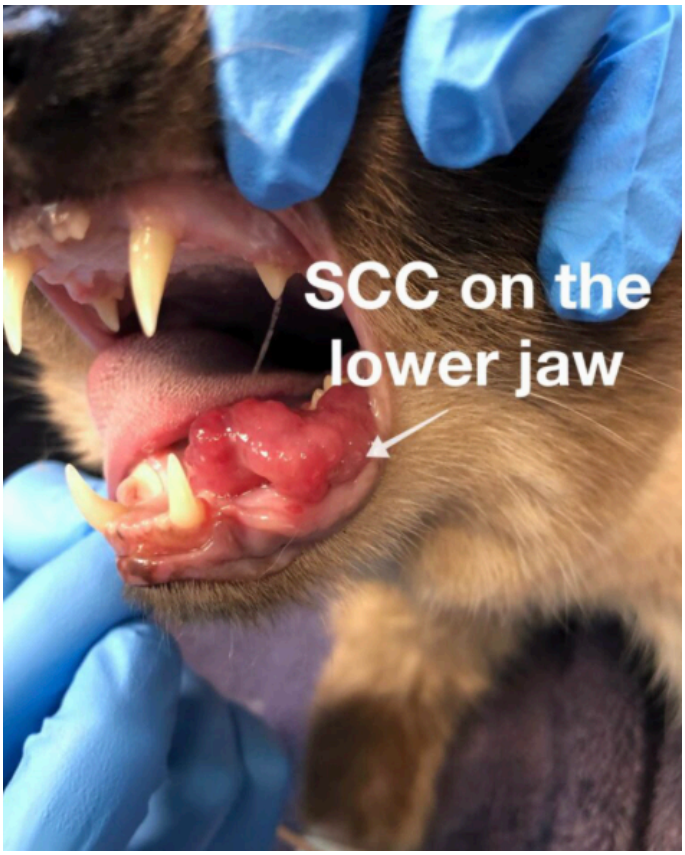

FibroSArcoma (FSA)

FSA are a type of cancer that arises from the connective tissue cells that lie underneath the soft tissues lining the mouth. These tumors tend to grow by sending out tendrils of cancer cells into the surrounding tissue. This means that in order to stop this cancer from growing, aggressive surgery through taking a wide margin of normal-looking tissue is necessary. These tumors fortunately rarely metastasize (spread) & often look smooth & firm. Since the tumors are slow to spread, a good prognosis can be achieved if we can remove the entire tumor, including all the tendrils of growth.

Histologically low-grade, biologically high-grade FSA is an important variant of the typical fibrosarcoma. This tumor is an extremely aggressive form of FSA that may look benign on biopsy, as did the tumor in this picture. Clinically, we see these tumors growing so rapidly that sometimes they have invaded so much of the normal tissue as to make surgery impossible. Luckily for this dog pictured, we were still able to perform surgery despite the tumor's rapid growth. If we catch a "Low-High FSA" early on, we can have a good prognosis if surgery is possible. Unfortunately, radiation therapy & chemotherapy tend to be unrewarding in treating this form of cancer.

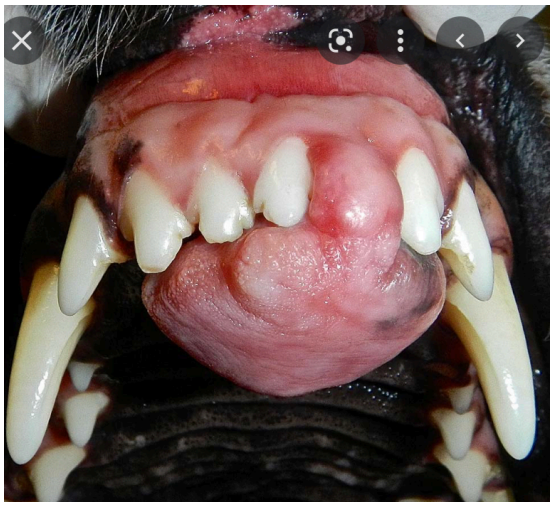

OsteoSArcoma (OSA)
OSA is a type of cancer that arises from bone. This can be from any bone in the body, including the skull, the legs, or the spine. OSAs that start in the oral cavity tend to have a better prognosis than those that arise in the legs of dogs. However, these can still be very aggressive cancers & spread to the lungs & other bones in the body. Having chest x-rays & LN biopsy performed prior to treatment for this disease is very important due to its higher rate of spread. The mainstay of treatment for OSA is to perform surgery to remove the tumor – which necessarily involves removing the underlying bone as well. In cases of maxillary osteosarcoma in both dogs & cats, recurrence is common after surgery. Chemotherapy & radiation in the treatment of oral osteosarcoma have NOT been associated with an increase in survival. Although malignant, oral osteosarcoma, which usually occurs in the mandible of dogs, may NOT be as aggressive as osteosarcoma of the appendicular skeleton in the dog. Osteosarcoma is rare in cats.

Canine Acanthomatous Ameloblastoma (CAA)
CAA is an odontogenic tumor. That means that it arises from the structures that support the teeth. This particular type of odontogenic tumor comes from epithelial cells (cells that line the surface of a structure. These used to be known as an “acanthomatous epulis”. This type of tumor is locally aggressive, & invades the underlying bone supporting the teeth. Luckily however, these tumors do NOT tend to spread. With surgery to completely remove the tumor (including the underlying bone that is involved) this type of cancer can be cured.

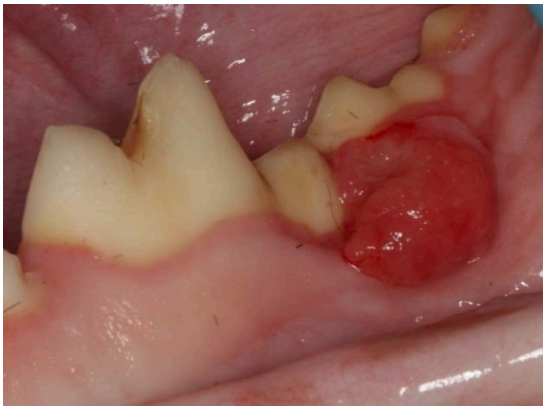

Peripheral Odontogenic Fibroma (POF)
Formerly known as ossifying fibromatous epulis or fibromatous epulis
POFs are benign odontogenic tumors- this means they arise from the structures that support the teeth. These tend to be slow-growing masses that do NOT largely invade the underlying bone, which means that local removal is typically curative. Occasionally these tumors do require more aggressive surgery if they come back or grow rapidly.

Odontoma
An odontoma is a benign, odontogenic (tooth-derived) tumor that can be classified as "compound" or "complex" depending on the appearance of the tumor. These are typically found in young dogs (<2years old) & can appear as a slow-growing swelling on the upper or lower jaw, in association with the teeth. Treatment by complete surgical removal is typically effective in curing this disease.

Papillomas
Papillomas are wart-like growths that typically affect young dogs, & are caused by a virus that most dogs become immune to by the time they become adults. Many times, these go away on their own & do NOT need treatment. Occasionally these lesions can spread through the mouth, interfering with normal chewing & swallowing, & do require some treatment either through surgical or laser removal of these lesions.

Signs and Symptoms:

-Presence of a mass in the oral cavity
-Increased salivation, blood in the saliva, odorous breath
-Ulceration
-Swelling of the face or bulging of an eye
-Bloody nasal discharge
-Difficulty eating or pain on opening the mouth, weight loss & enlarged LNs in the neck region
-Loose teeth, especially in an animal with generally good dentition, may be indicative of cancer-
-Induced bone loss, especially in cats
-Cause teeth to move out of their normal location

Signs of pain may include pawing at the face, chewing on the opposite side of the mouth the mass, rubbing the face excessively, drooling & jaw chattering.

Diagnostics:

Physical Examination (PE), blood tests (complete blood count & serum biochemistry), radiographs or computed tomography (CT) scan of the skull, chest radiographs or CT scans, & aspiration of the regional LNs are recommended for cats & dogs with suspected oral tumors.

In general, the following tests are recommended to diagnose the tumor, provide a clear clinical picture of overall health & evaluate for metastasis:

-PE: assess general health status, identify any other concomitant problems, examine & measure the oral tumor & assess the size of the regional LNs.
-Blood Tests: assess general health status as many cats & dogs with primary bone tumors are older & may have other problems which need to be considered when developing a treatment plan.
-Aspiration: a small needle is inserted into the tumor & the LN to obtain a few cells that can differentiate cancer from infection or inflammation. Alternatively, a biopsy of the oral mass may be recommended to maximize the chance of obtaining a conclusive diagnosis before surgery.
-Imaging of the Skull: depending on the location & size of the mass x-rays, CT scan or MRI may be used to better see the extent of the cancer & plan for treatment. It is important to determine the degree of bone invasion & assist in surgical planning.
-Chest x-rays or CT scan: look for signs the cancer has spread to the lungs

Biopsy allows us to identify the cause of the growth & how far it extends into the underlying tissues. In some cases we can take the whole tumor when we take our biopsy. This is called an excisional biopsy. However, most of the time it is advisable to take an incisional biopsy, where we take a small piece of the tumor, to be able to plan exactly what type of treatment will be best for your pet. Biopsy samples are submitted to a pathologist who is an expert in diagnosing different types of tumors & usually report back to us their results within 1-2 weeks.

Treatment:

Further consultation with your primary care veterinarian may result in a referral to veterinary surgeon to fully explore options for your pet. Surgery is often recommended for the management of oral tumors. The treatment options depend on the location of the tumor & the type of tumor. In general, benign tumors are excised with >1cm margins & malignant tumors are excised with >2-3cm margins.
Mandibulectomy is removal of part of the lower jaw. Various mandibulectomy procedures have been described, depending on how much of the jaw needs to be removed.

The choice of mandibulectomy technique depends on the tumor type & location.
For benign & low-grade malignant tumors, less aggressive techniques are usually adequate (Figure 1). However, for malignant tumors or large tumors, more aggressive procedures such as subtotal or total hemimandibulectomy are recommended (Figure 2).

Maxillectomy is removal of part of the upper jaw. Similar to mandibulectomy, various maxillectomy procedures have been described. These procedures can be combined with removal of the nose, orbit, skull & mandible if necessary. Similar to mandibulectomy, the choice of maxillectomy technique depends on the tumor type & location. For benign & low-grade malignant tumors, less aggressive techniques are usually adequate (Figures 3, 4). However, for malignant tumors or large tumors, more aggressive procedures such as caudal maxillectomy or hemimaxillectomy are recommended (Figure 5).

Figure 1. The typical postoperative appearance of a dog following bilateral rostral mandibulectomy. Note the shortened mandible and the tongue hanging out.

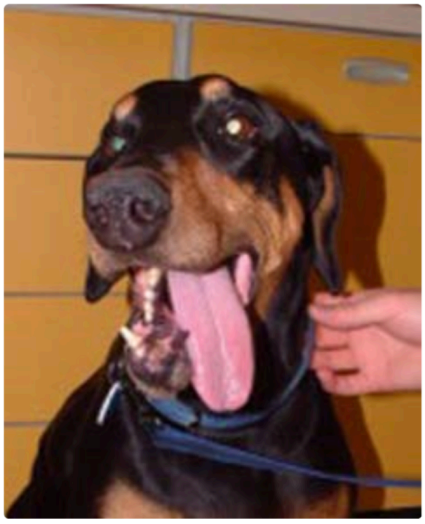

Figure 2. The typical postoperative appearance of a dog following subtotal (pictured) or total hemimandibulectomy. The lower jaw drifts towards the midline and the tongue hangs out on the surgery side.

Figure 3. Intraoperative image following hemimaxillectomy for excision of a fibrosarcoma. Hemimaxillectomy involves removal of the maxilla on one side of the upper jaw.

Figure 4. The typical appearance of a dog following bilateral rostral maxillectomy. Note the mild drooping of the nose.

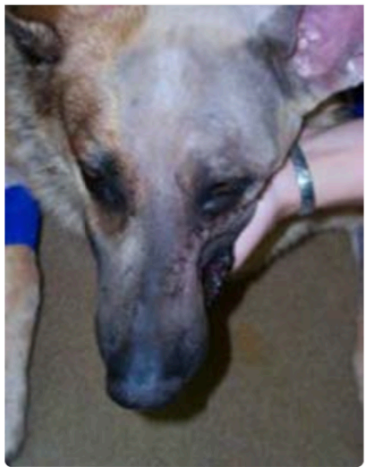

Figure 5. The typical appearance of a dog following caudal maxillectomy or hemimaxillectomy with scalloping of the maxilla on the affected side. Photo

Aftercare and Outcome:

Most animals are discharged 2-5 days after surgery, depending on their level of surgery, comfort & ability to eat soft food. They are usually returned for recheck & incision check 10-14 days after surgery. Pain can be well-controlled with owner-administered medications.

RESTRICTIONS FOLLOWING SURGERY usually are:
-use a restrictive collar for 10-14 days after surgery to prevent the natural tendency of dogs to lick & chew at a wound. This can cause breakdown of the wound & infection.
-Limited & restricted activity is indicated for about 2 weeks to allow recovery & incision healing
-Soft canned food, or water-soaked kibble for 2-3 weeks after surgery.
-A feeding tube may also be used depending on the extent of surgery in dogs or in cats (Figure 6)
-No chew toys, raw hide or ball playing for 2-4 weeks after surgery

POST-OPERATIVE COMPLICATIONS can include:
-Incision opening or breakdown is common & may require additional minor procedures or may be left to heal on its own depending on the size of the defect & location
-Bleeding from the nose for a few days is common after maxillectomy procedures
-Increased salivation may be temporary after surgery, but persists in some cases
-Swelling under the tongue (Figure 7)
-Mandibular drift, jaws NOT lining up well
-Difficulty eating, although this usually resolves within a couple weeks if NOT sooner. The vast majority of animals eat within 1-2 days of surgery
-Recurrence of the tumor

Figure 7. A ranula-like lesion (arrow) in a dog one day following subtotal hemimandibulectomy for an osteosarcoma. These may represent either a hematoma or accumulation of saliva. Treatment is rarely required because these lesions often resolve spontaneously.

The prognosis for cats & dogs with oral tumors is dependent on the type of tumor & sometimes the location of the tumor, size of the mass, success of surgery, & presence of metastatic disease. Tumors located in the front of the oral cavity are usually detected at an earlier stage & are more likely to be completely removed with surgery. Fibrosarcoma continues to have a high local recurrence rate & needs to be addressed with wider resections or other adjuvant therapies, such as postoperative radiation. On the other hand, surgery &/or radiation therapy is successful in controlling malignant melanoma locally in 75% of cases, but metastatic disease requires more effective adjuvant therapy, such as radiation therapy, chemotherapy, or immunotherapy.

Surgery plays a pivotal role in the management of most oral tumors & advice from an veterinary surgeon is recommended for all cats & dogs with an oral mass. While resection of various segments of bone from the skull can be a daunting prospect for owners, the vast majority of dogs have minimal cosmetic & functional consequences as a result of these surgeries.

If you have any questions, please feel free to ask your primary veterinarian &/or veterinary surgeon.

TREAT Veterinary Surgery Service
Dr. Le-Nguyen, DVM (Practice Limited to Surgery)
(916) 230-8103
treatveterinarysurgeryservice@gmail.com
https://treatveterinarysurgeryservice.com