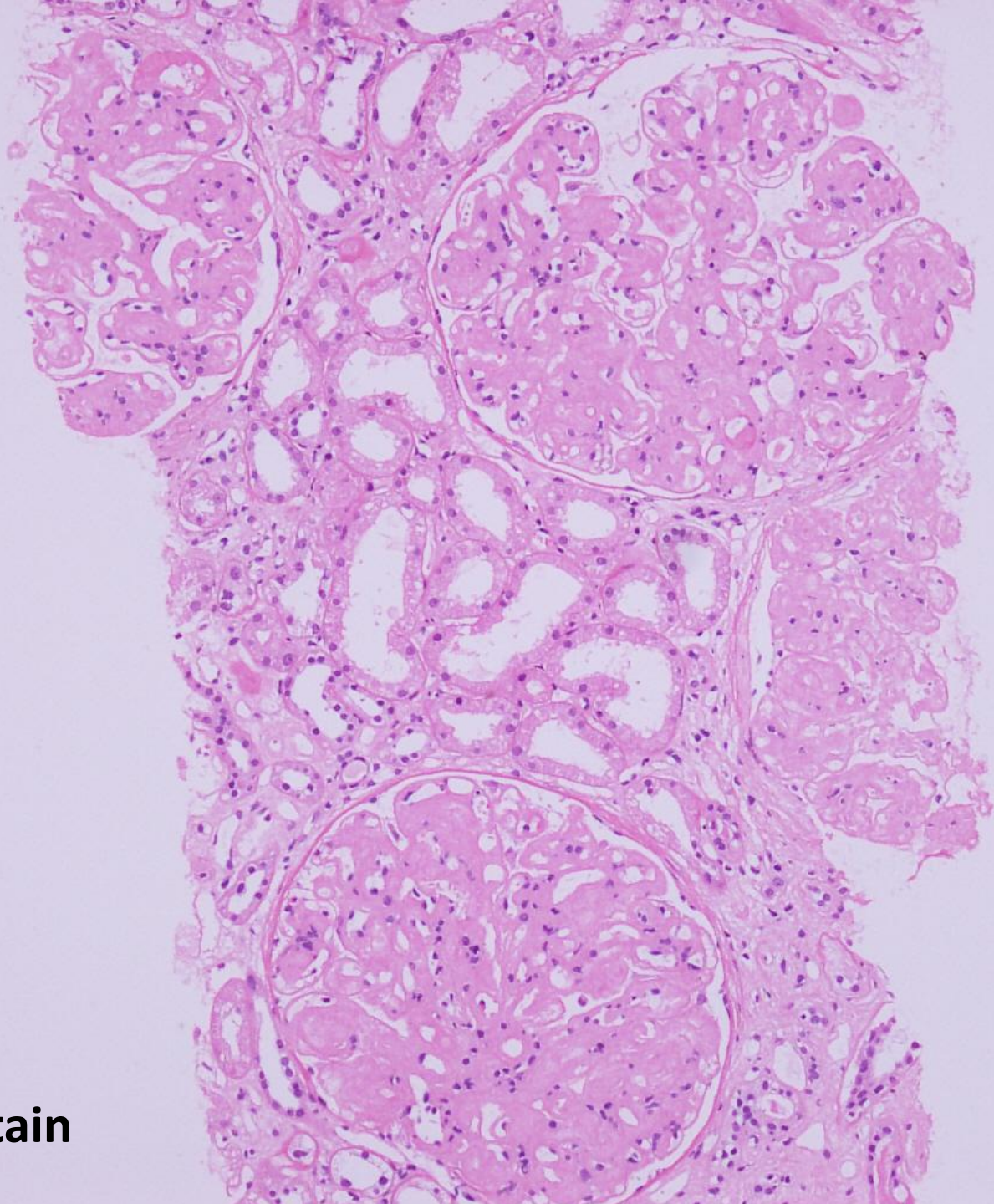


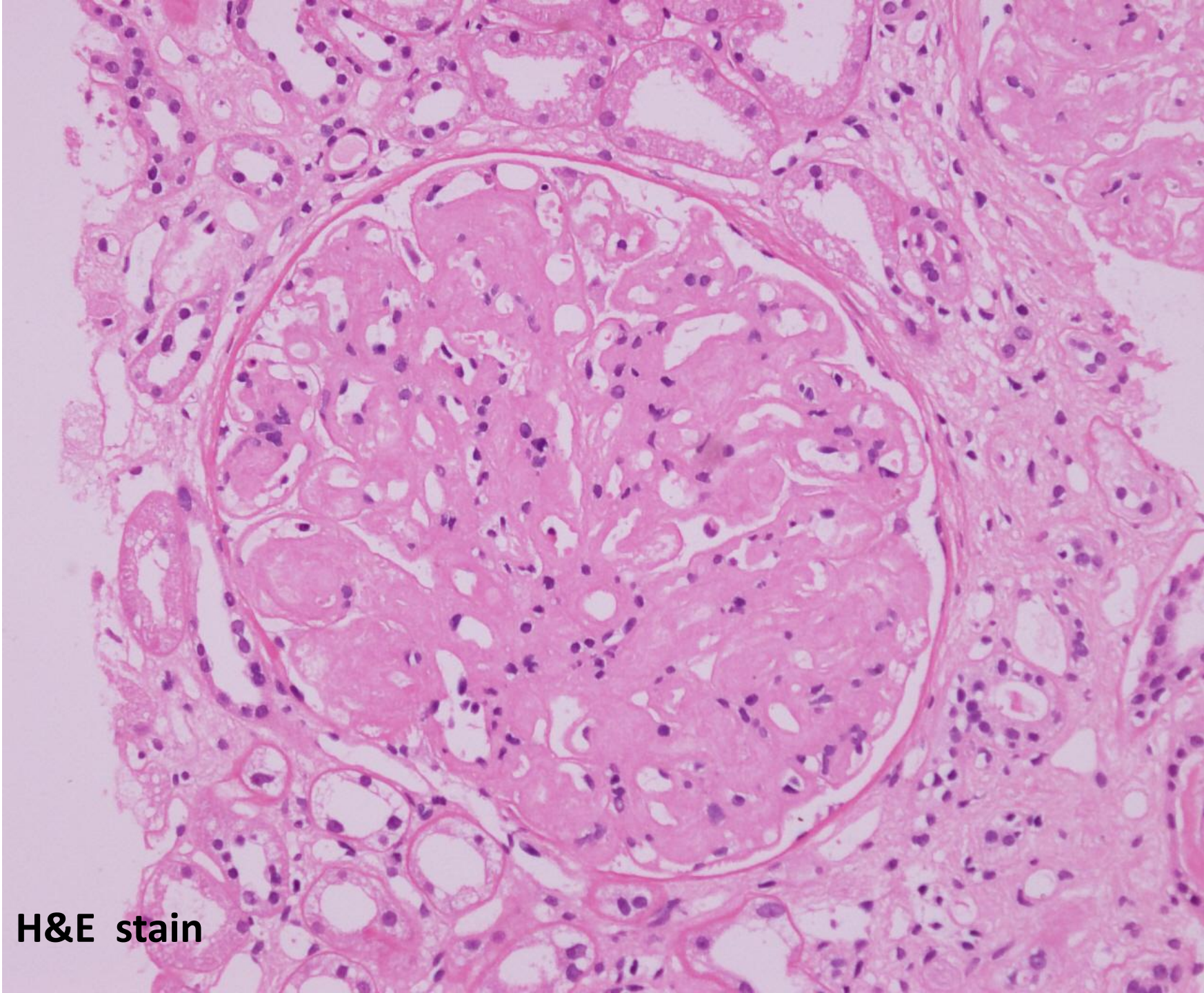
# Clinical History

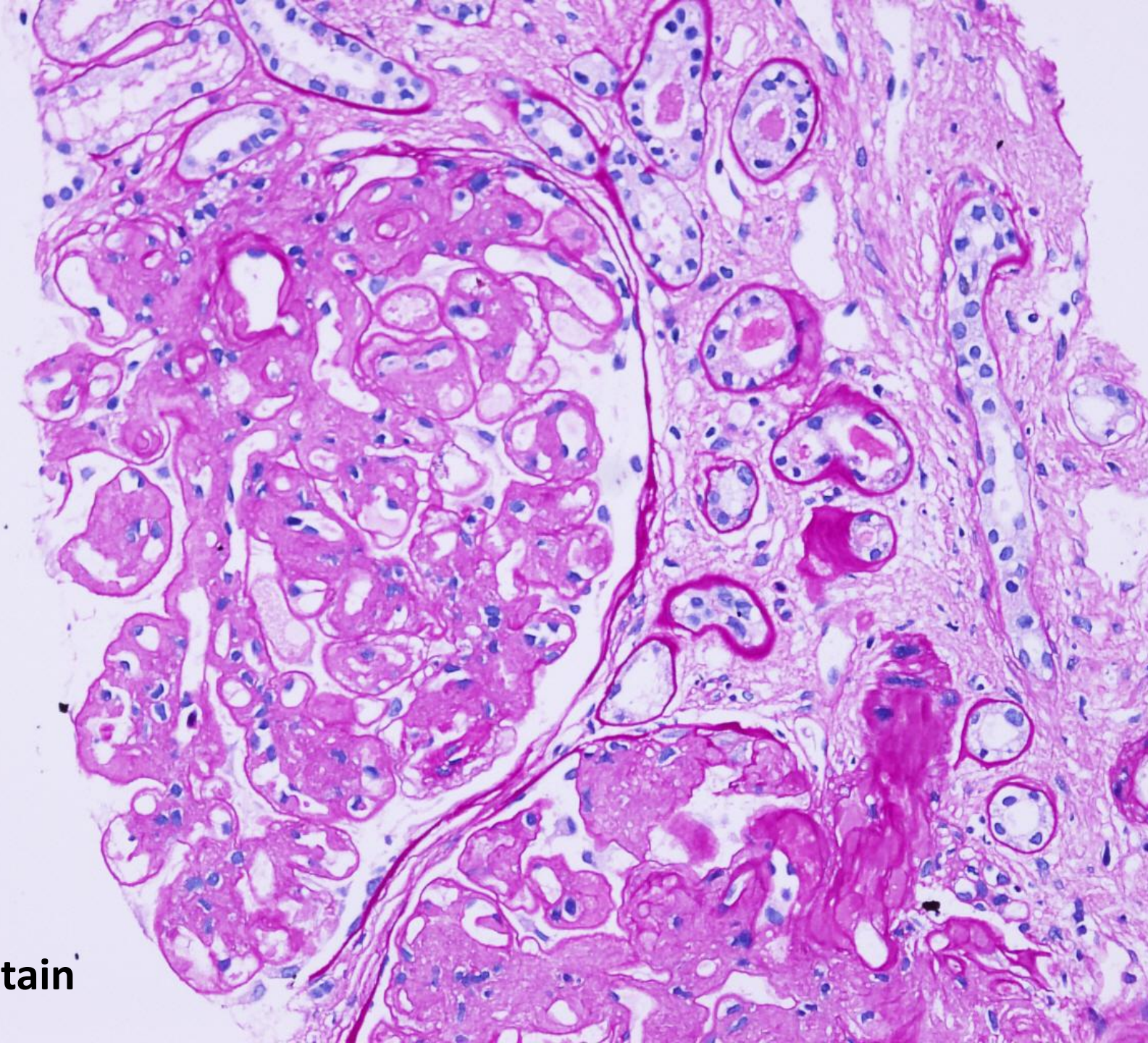
- 32-year-old female with nephrotic syndrome;
- Non- diabetic, non- hypertensive
- Serum creatinine 1.06
- Alb – 2.6;
- Urine R/E : 3+ protein; RBC -Nil



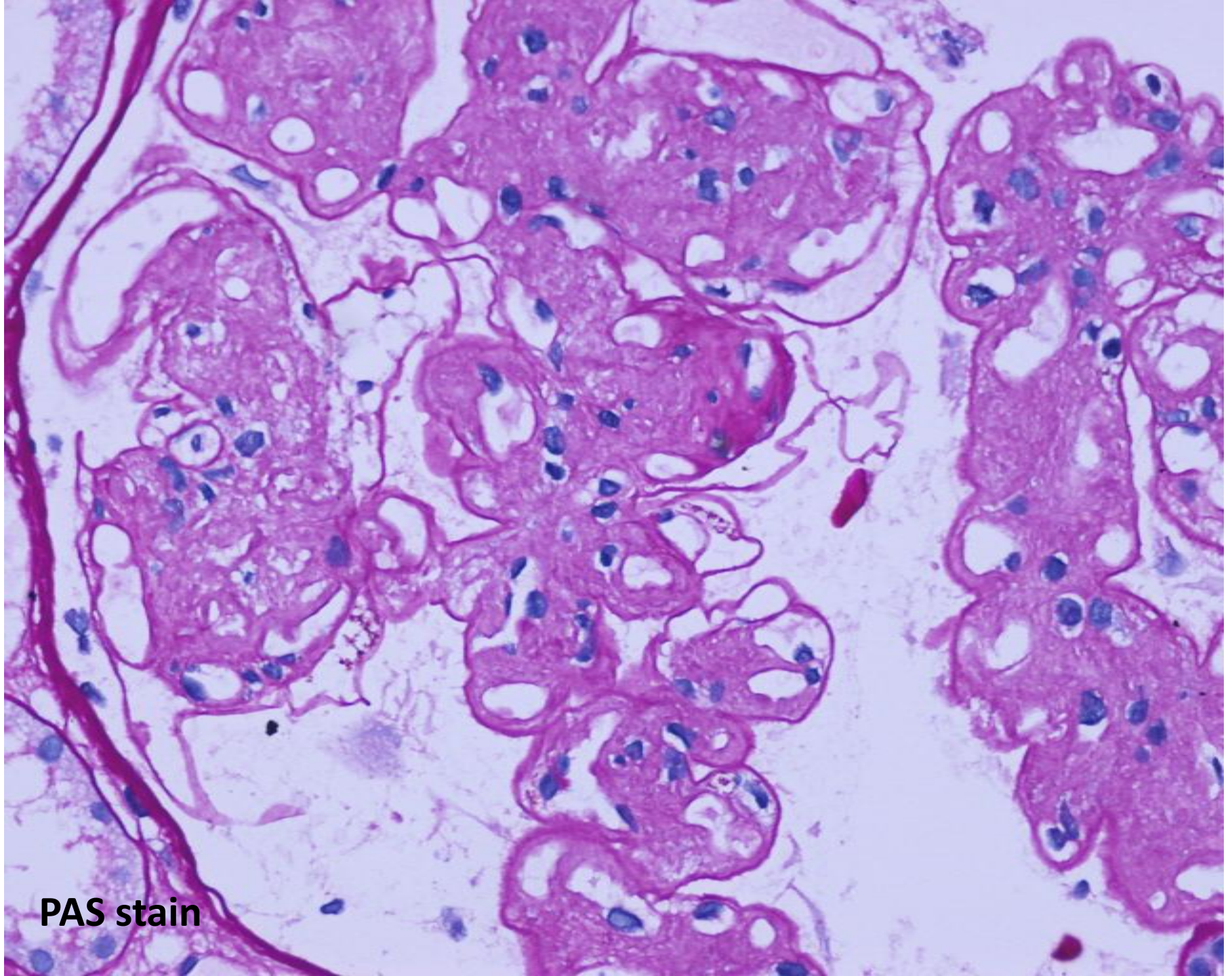
**H&E stain**

**H&E stain**

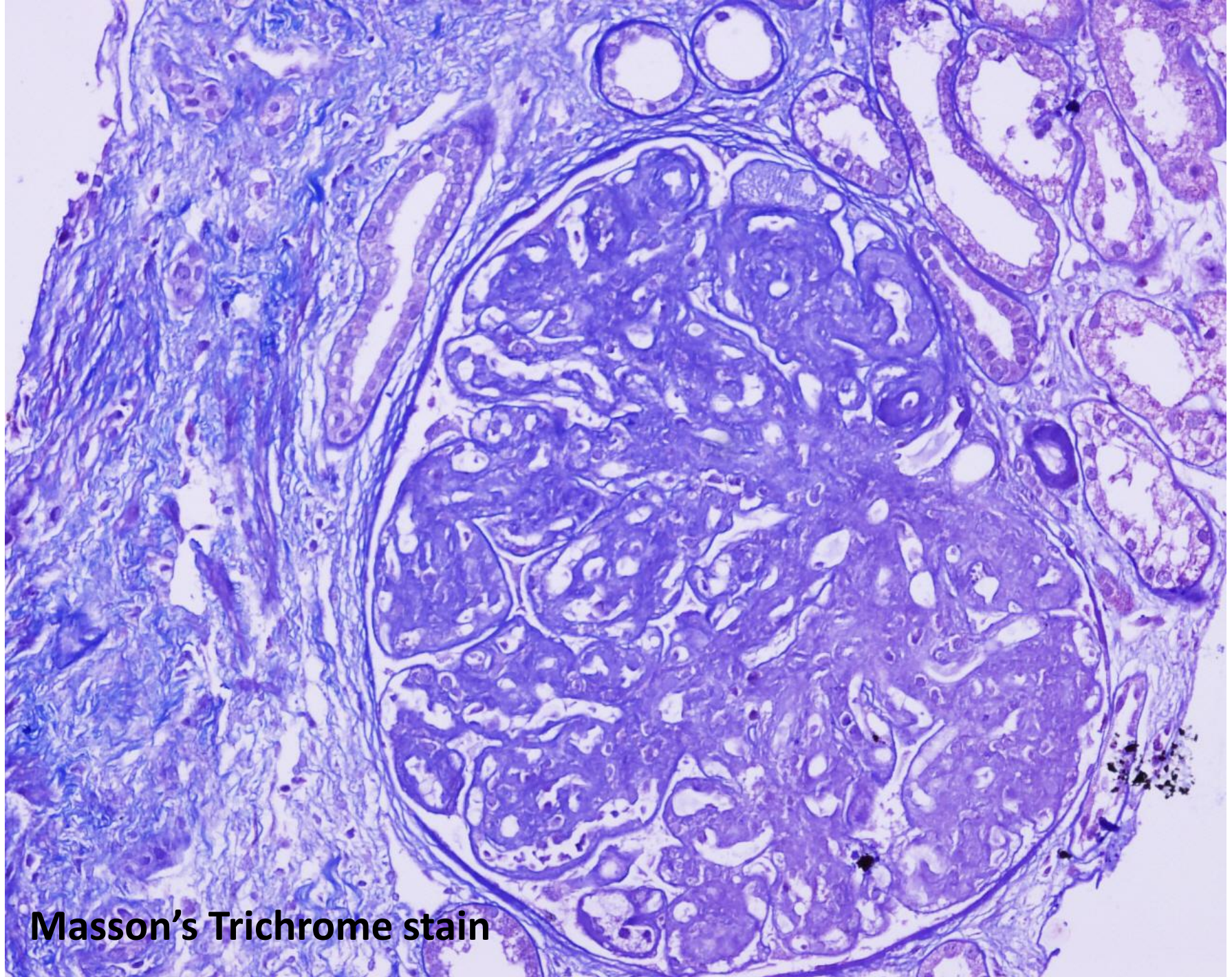




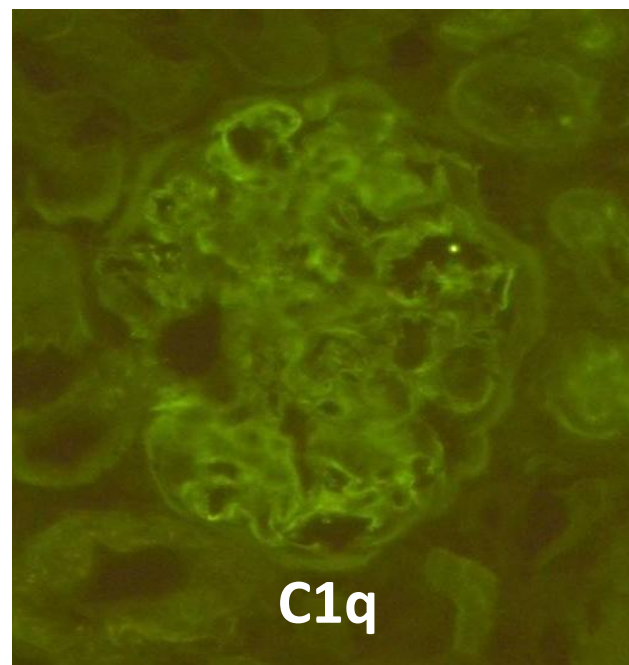
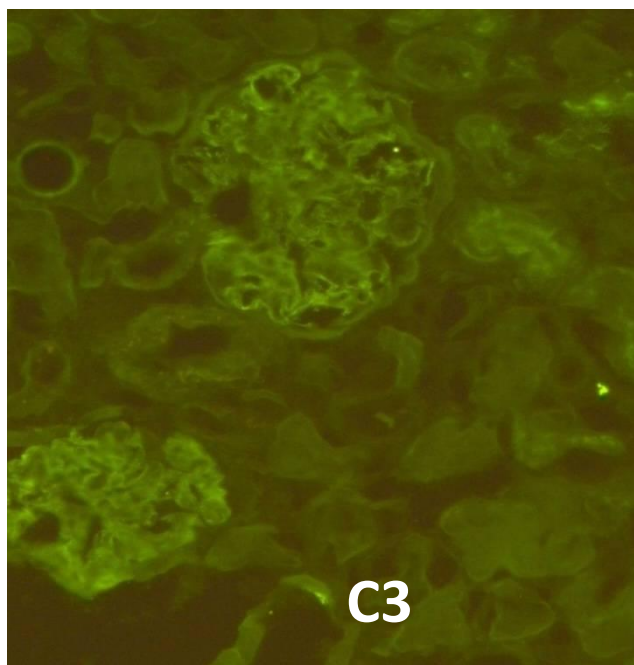
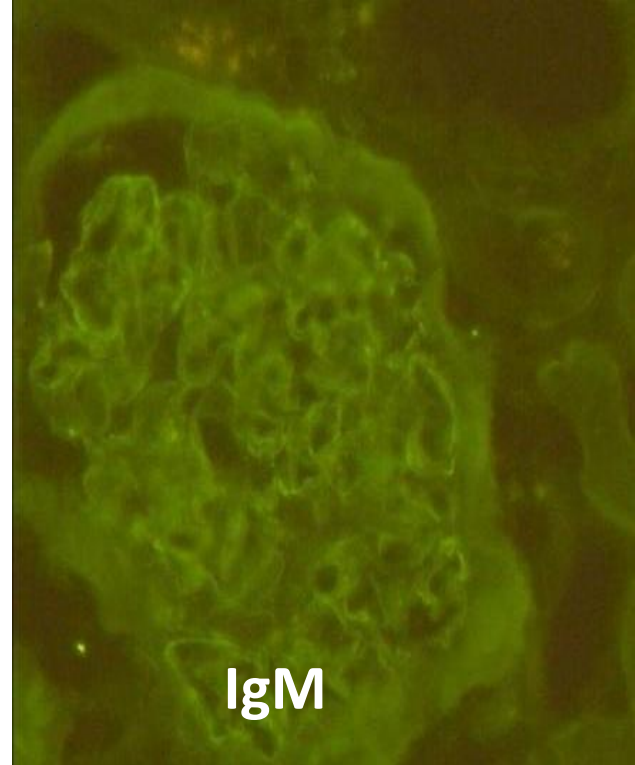
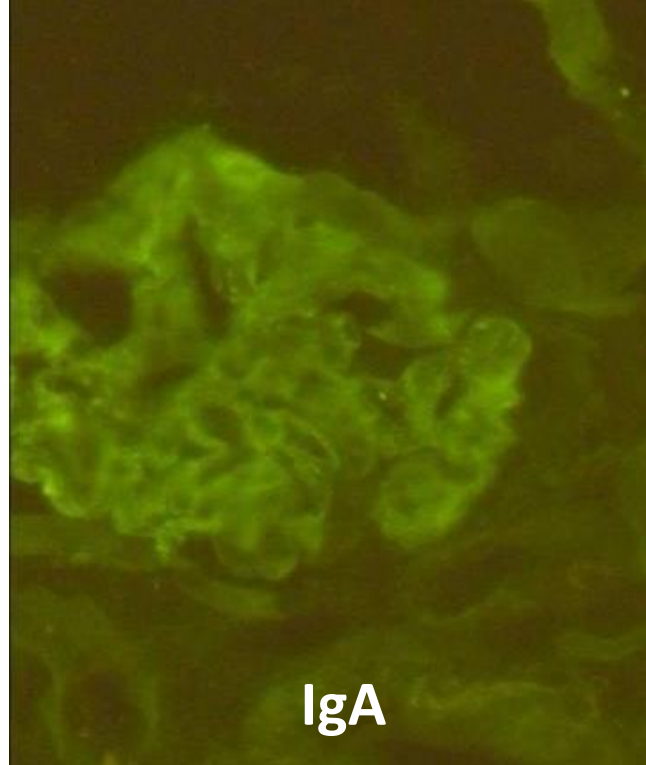
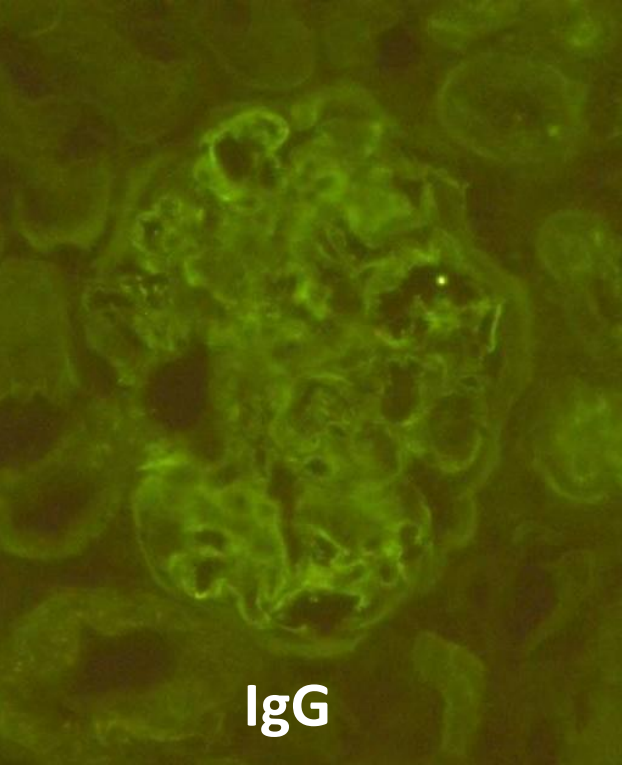
**PAS stain**

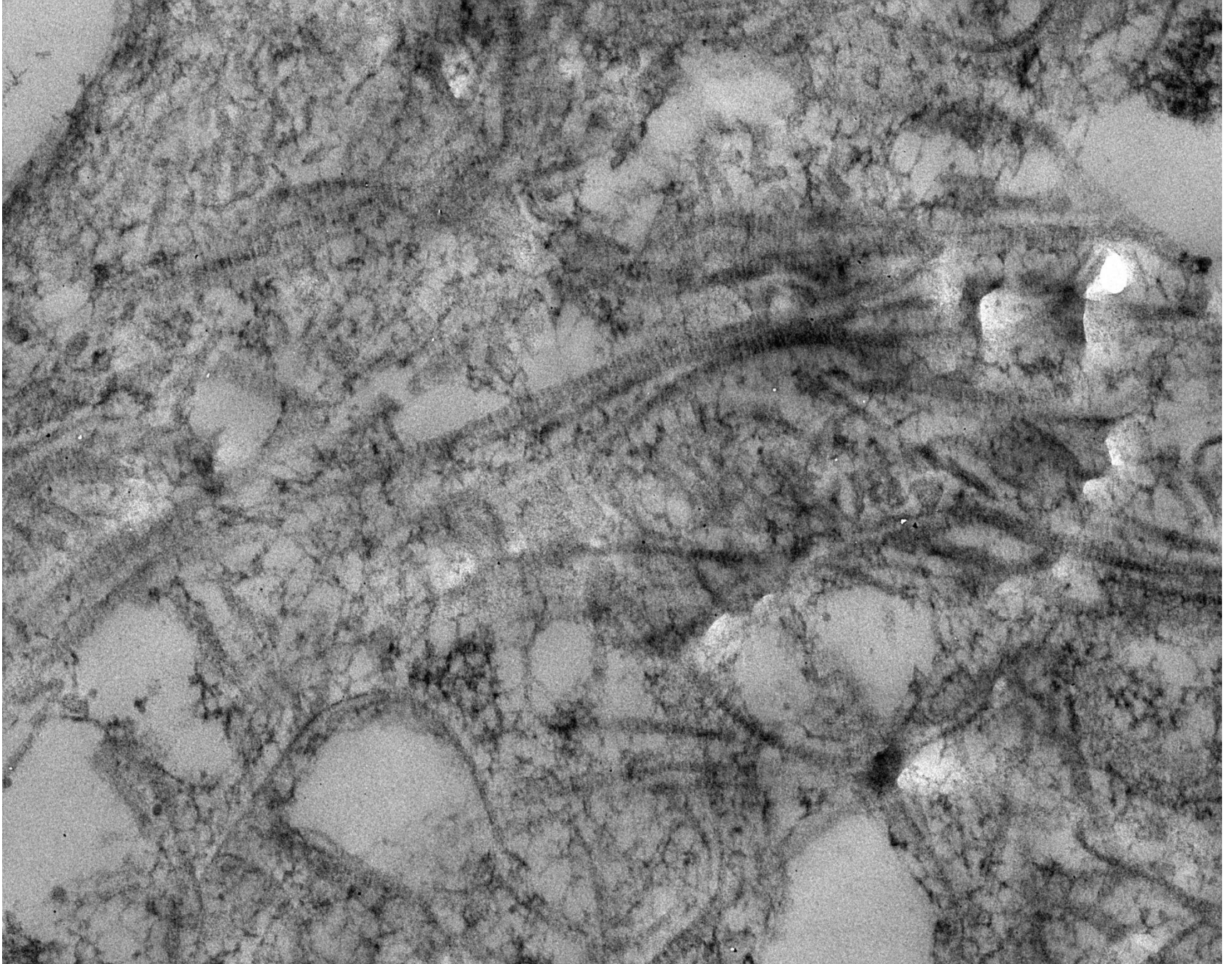


**PAS stain**



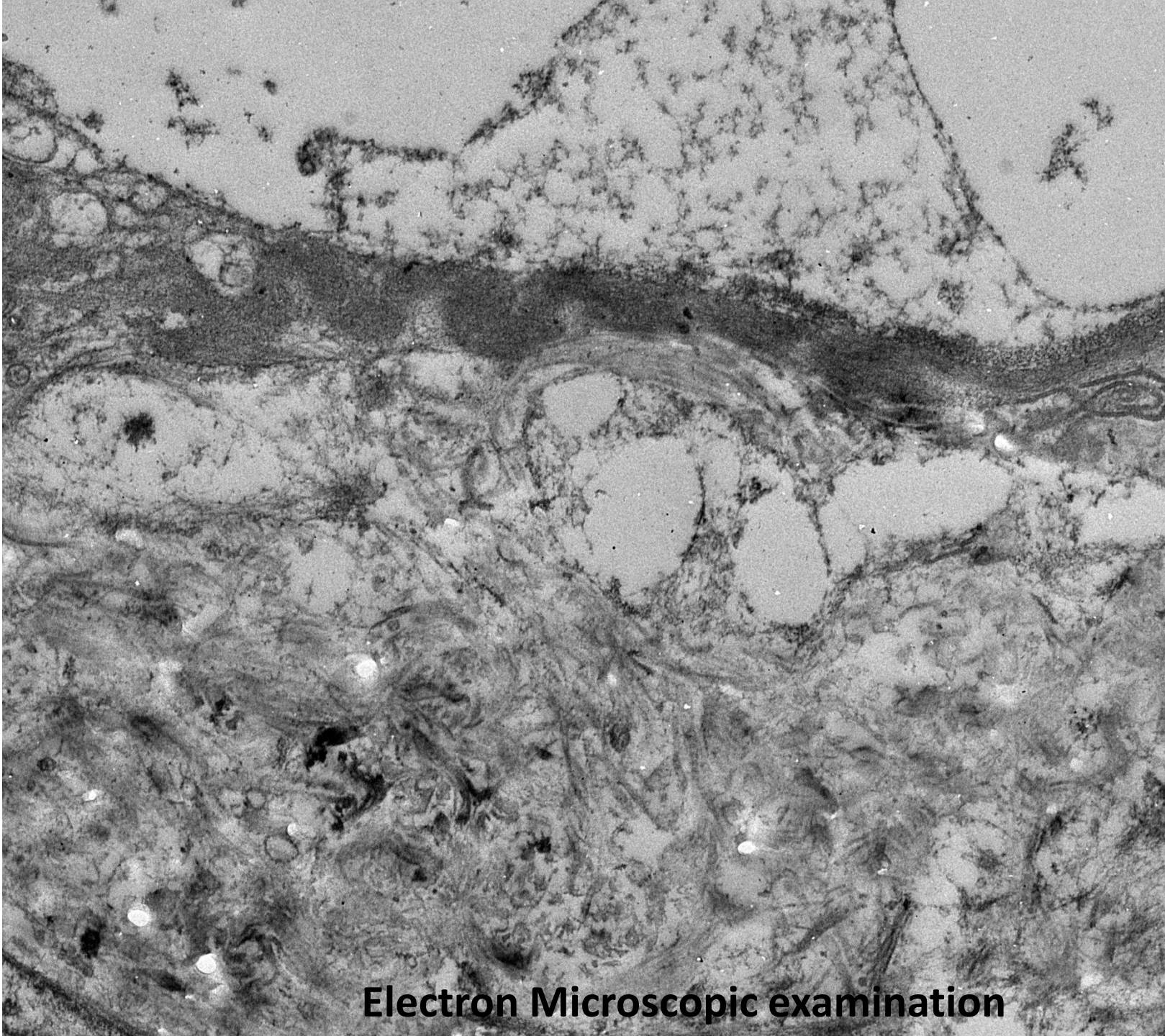
**Masson's Trichrome stain**





**Electron Microscopic examination**





**Electron Microscopic examination**

# MCQ

- Question 1. What is the pattern of glomerular injury ?
- Question 2. What is the name of this glomerular lesion ?
- Question 3. Which immunohistochemical stain is useful in confirming this glomerular pathology ?
- Question 4. Is this disease common in Asian countries ? (Yes/No)