

## Toward a more rationalized use of a special technique for repair of frontal air sinus after cerebral aneurysm surgery: The most effective technique



Ittichai Sakarunchai MD<sup>a,\*</sup>, Rokuya Tanikawa MD<sup>b</sup>, Nakao Ota MD<sup>b</sup>, Kosumo Noda MD<sup>b</sup>, Hidetoshi Matsukawa MD<sup>b</sup>, Hiroyasu Kamiyama MD<sup>b</sup>

<sup>a</sup> Division of Neurosurgery, Department of Surgery, Faculty of Medicine, Prince of Songkla University, Songkhla, Thailand

<sup>b</sup> Department of Neurosurgery, Teishinkai Hospital, Sapporo, Hokkaido, Japan

### ARTICLE INFO

#### Article history:

Received 16 December 2015

Accepted 17 January 2016

Available online xxxx

#### Keywords:

Bifrontal craniotomy

Frontal air sinus

Nasofrontal outflow tract

Infection

Mucocele formation

### ABSTRACT

A craniotomy that passes through the frontal air sinus (FAS) often results in postoperative complications such as infection, cerebrospinal fluid leakage or mucocele formation. A good understanding of FAS reconstruction can decrease the morbidity rate of complications. This study describes the outcomes of treatment and establishes the most effective technique for FAS reconstruction in our institution. We enrolled 107 patients who had a bifrontal craniotomy which exposed the FAS during the operation for an anterior communicating artery (ACoA) aneurysm. Demographic data including the follow-up information were collected and analyzed. The complications after surgery were observed and described in the treatment procedure. The patency of the nasofrontal outflow tract (NFOT) was proved by removal of blood clots and bone dust by irrigation and by direct inspection under a microscope before closure of the frontal sinus mucosa with a monofilament non-absorbable 7/0 material suture. The dura was closed in a watertight fashion and an abdominal fat graft was packed into the FAS cavity. There were 33 male and 74 female patients and the mean age (range) was 64 years (32–90 years). The mean follow-up time was 13 months (1–35 months) and complications were found in only 2 patients. One patient suffered from dislocation of the fat graft and the other patient developed a surgical wound infection. At post-operation the first patient sneezed several times and the second patient suffered from trauma in the nasal area after discharge to home. Both patients were surgically treated and cured. In conclusion, FAS reconstruction from our technique is very effective for the prevention of complications after bifrontal craniotomy. Direct suturing of the frontal sinus mucosa and proving the patency of the NFOT are keys to successful treatment.

© 2016 The Authors. Published by Elsevier B.V. This is an open access article under the CC BY-NC-ND license (<http://creativecommons.org/licenses/by-nc-nd/4.0/>).

### 1. Introduction

Nowadays, the surgical approach to pass through the frontal air sinus (FAS) is a serious procedure for neurosurgeons to perform as the surgery increases the possibility of complications related to the procedures such as infection, cerebrospinal fluid (CSF) leakage or mucocele formation. The clues for an effective procedure to decrease these problems are: 1) maintain the patency of the nasofrontal outflow tract (NFOT) and 2) disconnect the space between the intracranial and air sinus compartments. Obstruction of the NFOT can cause an infection and mucocele formation at post-operation due to insufficient drainage

of secretions via the primary ostium, hence the complication rates were reported as 0–10% [2,4,6,12]. The authors reported several effective methods for FAS reconstruction by using either artificial or autologous materials to obliterate the FAS or exenterate the frontal sinus mucosa and then use an autologous flap to close the space with fibrin glue. These procedures were reported to be safe and effective especially in FAS fracture from trauma [2,11,12]. However, only a few papers mentioned non-traumatic patients who had a craniotomy that involved the FAS such as anterior cerebral artery aneurysms or anterior skull base tumor surgeries [15,18]. Dealing with the complications requires aggressive treatment for repair or to rid the patient of an infection both of which require long hospitalization.

The technique of FAS reconstruction by closing the frontal mucosa after proving the patent status of the NFOT and then packing with abdominal fat has been established in a few reports [8,14]. Our series is the largest series that studied the results of FAS reconstruction in

\* Corresponding author at: Division of Neurosurgery, Department of Surgery, Faculty of Medicine, Prince of Songkla University, 15 Kanjanavanich Road, Ko-hong, Hat Yai, Songkhla, 90110, Thailand. Tel.: +66 74 45 1400; fax: +66 74 42 9384.

E-mail address: [it\\_svu039@hotmail.com](mailto:it_svu039@hotmail.com) (I. Sakarunchai).

non-traumatic patients after we performed the anterior interhemispheric approach for every anterior communicating artery (ACoA) aneurysm. Data of both ruptured and unruptured aneurysms of the patients were collected and the effective technique of frontal sinus reconstruction was described.

## 2. Methods

### 2.1. Study design

The retrospective cohort review was collected from April 2012 to April 2015 in Teishinkai Hospital, Sapporo, Japan. All of the patients signed a completed informed consent form before the operation. The inclusion criteria were the patients who underwent interhemispheric approach for ACoA aneurysm and had a bifrontal craniotomy performed that exposed the FAS. In patients who were diagnosed as ACoA aneurysm with a simultaneous aneurysm at another site, such as middle cerebral artery or posterior communicating artery aneurysm, we chose the fronto-temporal approach instead of the interhemispheric approach and these patients were excluded from the study. The patient demographic data, follow-up times, and complications from the treatment were collected and analyzed after a review of the ethical issues and approval by the institutional review board committee. All patients were post-operatively followed up.

### 2.2. Surgical techniques

After the informed consents were signed by the patients but before undergoing surgery, preoperative information was obtained in each patient from fusion images (MRA and CTA scans of the brain) for the characteristics of aneurysms, superficial veins related to the anterior segment of the superior sagittal sinus, and the morphology of the frontal sinus. A routine intravenous antibiotic of first generation cephalosporin was administered before the operation and until the third day post-operation for prophylaxis treatment. After the neutral position and head elevation above the heart to decrease intracranial pressure were arranged, the standard bicoronal skin incision was made. The bifrontal craniotomy was performed until the FAS was exposed (Fig. 1). The frontal mucosa was stripped from the table of sinus in all directions (Fig. 2A). Afterwards the mucosal edge was trimmed to the appropriate shape of the sac (Fig. 2B). A survey of the NFOT patency was proved by using the irrigation-suction device designed by Kamiyama et al. [7] to remove blood clots and small bone dust that can result in obstruction of the NFOT before closing the frontal mucosa. Patency was verified under microscope. This step is necessary to decrease the incidence of recurrent infection or mucocele formation in the long-term. Additional

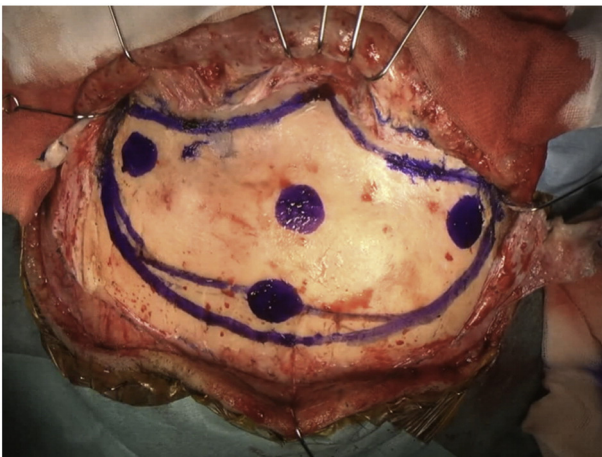

Fig. 1. The bone flap was done by the bifrontal craniotomy approach for an ACoA aneurysm.

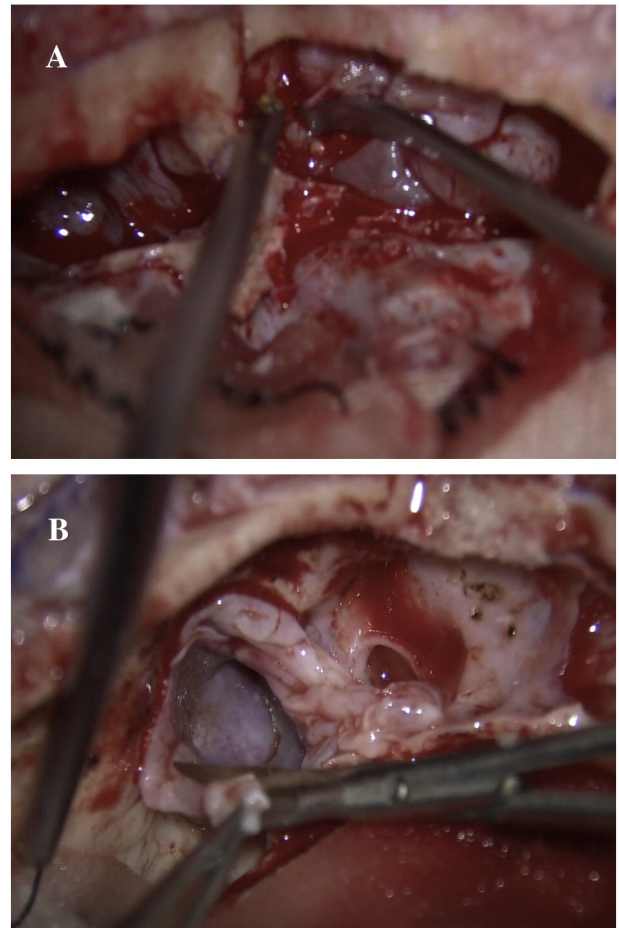
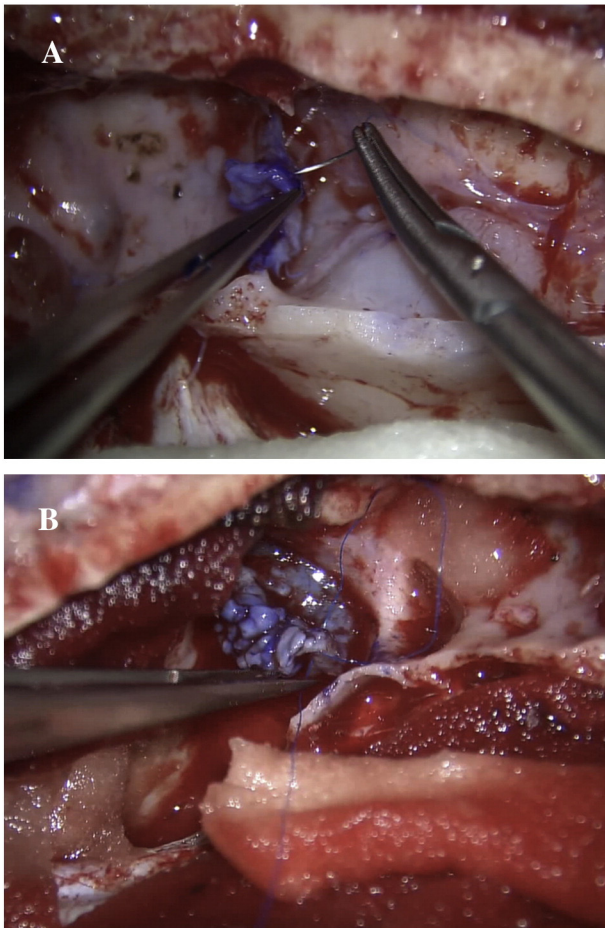


Fig. 2. A: The mucosa was stripped from the anterior and posterior wall of the frontal air sinus by small dissector. B: Frontal mucosa was exposed and the edge was trimmed to reshape the closure.

removal of the inner table of the FAS was performed to make a wider space for reconstruction of the FAS. Pyoktanin was used to mark the edge of the mucosa for easier closure with monofilament non-absorbable 7/0 suture material by continuous technique under microscope (Fig. 3A–B). After this process was finished, saline-soaked cottonoid was used to temporarily pack the mucosal space. Then the crista galli was removed. The dura was opened in the next step and the aneurysm was clipped. The dura was closed in a watertight fashion after clipping the aneurysm to prevent CSF leakage. Abdominal fat was harvested to pack the FAS space and then sealed with fibrin glue (Fig. 4A). Cranialization of the mucosa and removal of the posterior table of the frontal sinus from the bone flap was done before closure. After that the bone flap was closed for cosmetic reconstruction (Fig. 4B). The pericranial flap that included the skin was closed layer by layer. The patient needed to stay in the hospital for post-operative care for 2 weeks and was advised to avoid certain activities for at least 3 months that would cause the fat graft to be blown away such as sneezing or the Valsalva maneuver to allow complete epithelialization of the FAS [17]. An MRI scan of the brain was performed post-operatively before discharge and at follow-up times of 3 and 6 months and then once a year if the clinical condition was stable. Complications such as infection were determined by a clinical presentation according to the following criteria: nasal discharge related to the clinical symptoms of sinusitis, fever with nuchal rigidity or headache (meningitis), and headache and fever with deterioration of neurological signs (brain abscess). Imaging was also used to confirm this condition. CSF leakage was detected by clinical rhinorrhea and CSF rhinorrhea was proved by a fluid profile. Mucocele formation was confirmed by revealing the





**Fig. 3.** A: The mucosa was marked with Pyoktanin. B: Closing with monofilament non-absorbable (nylon) 7/0 running fashion.

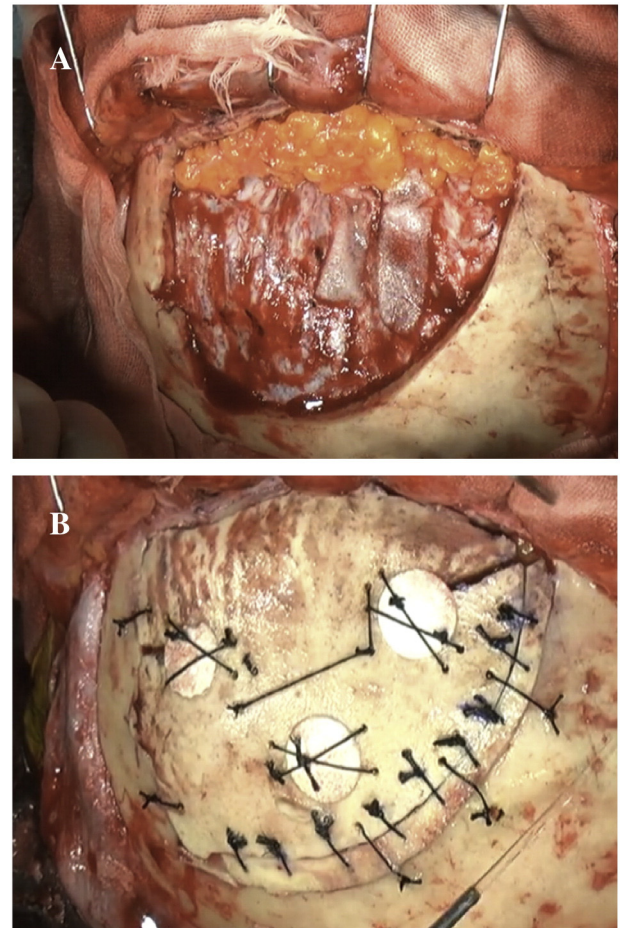
opacification of one or more sides of the frontal sinus on imaging and associated with a bony expansion of a cystic lesion that corresponded with the clinical symptoms. Skin flap inflammation or surgical site infection was proved by a specific physical examination of the infection.

### 2.3. Outcome of treatment

The data of the complications in the case series were collected and the details of treatment were described. The demographic data of the patients were used to analyze sex, age, and duration of follow-up.

### 3. Results

From the total of 107 patients, there were 33 male and 74 female cases. The mean follow-up time was 13 months (1–35 months) and the mean age was 64 years (32–90 years). The number of ruptured aneurysms was 17 and the number of unruptured aneurysms was 90. Only 2 cases (1.8%) had complications from sinus reconstruction. The first patient was a 73-year-old male who was diagnosed as having unruptured ACoA aneurysm and underwent elective aneurysm clipping. One month later, the patient came to the hospital before the appointed follow-up date due to swelling of his forehead around the surgical site. He had sneezed several times after discharge from the hospital even though he was advised to beware of sneezing and the Valsalva maneuver for the first 3 months after the operation. The MRI scan of the brain revealed that the fat had dislodged from the site of the FAS. However, no evidence of infection such as an abscess in the sinus space was detected by imaging. After the diagnosis of fat graft malposition was established, open surgery for revision of the fat graft and re-exploration of the FAS



**Fig. 4.** A: The abdominal fat graft was harvested and placed in the frontal sinus. B: The skull was placed for the cosmetic reconstruction technique.

was performed. The dura was still intact and there was no evidence of CSF leakage from the intraoperative view. The fat graft was removed and a new one was harvested and placed into the frontal sinus space. Sealing with fibrin glue was done before closing the bone flap. The patient returned to a good clinical outcome and was completely cured after the second operation. The second case was a 60-year-old male treated for an unruptured distal anterior artery aneurysm. Three weeks after discharge, he suffered a broken nose from a blunt object. Three weeks later he developed an inflammation at the surgical wound. The bone flap was removed and cranialization of the frontal mucosa was done. The patient returned home without further incident. Both patients did not have any underlying disease such as diabetic mellitus or hypertension and neither patient developed mucocele formation or CSF leakage.

### 4. Discussion

In our study of 107 patients, two had a complication from fat graft malposition and infection of the surgical wound. No patients were diagnosed with serious complications such as CSF leakage or mucocele formation. We performed the standard technique for watertight closing of the dura which is a necessary technique to prevent CSF leakage. We didn't perform the popular technique of cranialization to prevent mucocele formation by resection of the mucosa lining of the anterior and posterior walls and then plugging with autologous material such as pericranial flap, fat or bone in the frontal sinus space [6,10,11,18]. This technique prevents the inversion of the pericranial flap when sneezing, and in addition, it is an effective and inexpensive procedure [2,3,11,15,16,18]. However, the outcome of treatment from our study

**Table 1**  
List of previous frontal air sinus reconstructions from a literature review [1,2,3,5,6,11].

Author and year (months)	Description of technique	No. of patients	Follow-up time	Complication
1. Horowitz G. et al., 2000	Cranialization and obliteration	69	N/D	Infection 6 cases (9%)
2. Friedman DC. et al., 2000	Cranialization and pericranial flap closure	40	24	Infection 2 cases (5%)
3. Mori K. et al., 2002	Pack with small bone	11	N/D	No
4. Ito S et al., 2003	Autologous bone graft with fibrin glue	12	51	No
5. Donath A. et al., case 2006	Cranialization and pericranial flap closure	19	9–55	CSF leakage 1 (5%)
6. Chen KT. et al., 2006	Cranialization, partial and complete obliteration with bone and pericranium	78	3–94	CSF leakage 6 cases, wound infection 4 cases, infection 2 cases, pyomucocele 1 case (17%)

N/D: Not determined.

reported a low rate of morbidity which was similar to previous studies that reported post-operation morbidity ranges of 0–17% (Table 1). We performed a different surgical treatment technique; specifically, direct frontal mucosa suturing and an abdominal fat graft to obliterate the frontal sinus. Before closing the frontal mucosa, we used a special suction device system (Suction Plus®, Johnson & Johnson, Japan) developed by our institute with an irrigation function that was manipulated easily to check the patency of the NFOT by removing any bone dust or blood clots around this area. Afterward, closing the frontal mucosa has the benefit of completely separating the intracranial and nasofrontal compartments so that infection cannot spread anterogradely into the intracranial space. The abdominal fat graft also has the advantage of increasing the healing process. There is a paucity of information in the literature about autologous fat grafts; however, plastic surgeons studied the yield of autologous abdominal fat graft and found that it not only filled the dead space of the frontal sinus but it also increased the healing process from the adipose-derived stem cells contained in the grafts. The viable adipocytes provided the growth factors and imaging proved the incorporation of the fat with the surrounding soft tissue within 6 months after the inflammatory process had finished [19]. For this reason, we preferred to use this procedure to close the frontal sinus after repair of the dura. The outcome of healing was excellent from the follow-up MRI studies.

After the abdominal fat graft was packed into the frontal space, fibrin glue sealed the fat graft to the structure. All patients were advised to avoid an excessive Valsalva maneuver or sneezing after the operation. Unfortunately, in this study one patient had a history of sneezing that caused a complication. Treatment of FAS complications after surgery was described in several techniques such as endoscopic drainage and maintenance of a patent frontal recess [9] or the debridement and cranialization of the frontal mucosa including elimination of the frontal sinus outflow tract which is the cause of recurrent infection and then used the temporalis muscle or pericranial flap to make a new space between the intracranial and frontal sinuses [13,18]. In our study, we had no detected recurrence of infection after treatment. Removal of the mucosa by the open technique is very effective and the abdominal fat should be harvested to obliterate the FAS.

However, a satisfactory outcome of the treatment varies and depends on the individual technique. A long follow-up time is also important to evaluate the long term complications, especially mucocele formation. Some authors found complications 23 years after surgery [18].

## 5. Limitations

The follow-up time in our study was too short compared with previous studies that reported the incidence of infection could occur more than 20 years post-operatively. Therefore, we need to find other associated factors of infection such as diabetes mellitus in order to evaluate the possible complications.

## 6. Conclusions

The complications from frontal air sinus exposure during bifrontal craniotomy surgeries are infection, CSF leakage, and mucocele formation.

The most important factors that can decrease the incidence of infection are closure of the space between the intracranial component and the frontal sinus space, watertight fashion for dural closing, and maintaining patency of the NFOT. The use of the abdominal fat graft enhances the healing process of the frontal air sinus after surgery. Finally, patients need to avoid sneezing and an excessive Valsalva maneuver.

## Disclosure

The authors report no conflict of interest concerning the materials or methods used in this study or the findings specified in this paper.

## Acknowledgments

We thank the native English speaker, Mr. Glenn Shingledecker, for his assistance in editing the English language of this paper.

## References

- [1] K.T. Chen, C.T. Chen, S. Mardini, P.K. Tsay, Y.R. Chen, Frontal sinus fractures: a treatment algorithm and assessment of outcomes based on 78 clinical cases, *Plast. Reconstr. Surg.* 118 (2006) 457–468.
- [2] A. Donath, R. Sindwani, Frontal sinus cranialization using the pericranial flap: an add layer of protection, *Laryngoscope* 116 (2006) 1585–1588.
- [3] D.C. Friedman, D.P. Costantino, H.C. Snyderman, C.L. Chow, S. Takagi, Reconstruction of the frontal sinus and frontofacial skeleton with hydroxyapatite cement, *Arch. Facial Plast. Surg.* 2 (2000) 124–129.
- [4] M. Hasegawa, S. Torii, K. Fukuta, K. Saito, Reconstruction of the anterior cranial base with the galeal frontalis myofascial flap and the vascularized outer table calvarial bone graft, *Neurosurgery* 36 (1995) 725–731.
- [5] G. Horowitz, N. Margalit, M. Amit, Z. Gil, M.D. Fliss, Efficacy and safety of frontal sinus cranialization, *J. Neurol. Surg. B Skull Base* 73 (2012) 116.
- [6] S. Ito, K. Nagayama, N. Iino, I. Saito, Y. Takami, Frontal sinus repair with free autologous bone graft and fibrin glue, *Surg. Neurol.* 60 (2003) 155–158.
- [7] H. Kamiyama, H. Abe, M. Nomura, H. Saito, N. Yasui, Acute stage operations for cerebral aneurysm, intracerebral hematomas, arterio-venous malformation high pressure irrigation and suction system, *Surg. Cereb. Stroke* 16 (1988) 282–286.
- [8] J.D. Kantanen, J.J. Closmann, H.H. Rowshan, Abdominal fat harvest technique and its uses in maxillofacial surgery, *Oral Surg. Oral Med. Oral Pathol. Oral Radiol. Endod.* 109 (2010) 367–371.
- [9] F.A. Kuhn, A.R. Javer, Primary endoscopic management of frontal sinus, *Otolaryngol. Clin. N. Am.* 34 (2001) 59–75.
- [10] K. Meetze, J.N. Palmer, R.J. Schlosser, Frontal sinus complications after frontal craniotomy, *Laryngoscope* 114 (2004) 945–948.
- [11] K. Mori, M. Nakajima, M. Maeda, Simple reconstruction of frontal sinus opened during craniotomy using small autologous bone piece, *World Neurosurg.* 60 (2003) 326–328.
- [12] Y. Murai, T. Mizunari, S. Koyabashi, A. Teramoto, Surgical technique for the prevention of cerebrospinal fluid leakage after bifrontal craniotomy, *World Neurosurg.* 81 (2014) 344–347.
- [13] J.S. Rubin, V.J. Lund, B. Salmon, Frontoethmoidectomy in the treatment of mucoceles: a neglected operation, *Arch. Otolaryngol. Head Neck Surg.* 112 (1986) 434–436.
- [14] M.B. Soyka, A. Annen, D. Holzmann, Where endoscopy fails: indications and experience with the frontal sinus fat obliteration, *Rhinology* 47 (2009) 136–140.
- [15] S. Takeuchi, R. Tanikawa, M. Katsuno, T. Tsuboi, K. Noda, J. Oda, S. Miyata, N. Ota, H. Kamiyama, An effective method of frontal sinus reconstruction after bifrontal craniotomy: experience with 103 patients, *World Neurosurg.* 83 (2015) 907–9011.

- [16] C.S. Tan, V.K. Yong, L.W. Yip, S. Amrith, An unusual presentation of a giant frontal sinus mucocele manifesting with a subcutaneous forehead mass, *Ann. Acad. Med. Singap.* 34 (2005) 397–398.
- [17] G. Xu, H. Jiang, H. Li, J. Shi, H. Chen, Stage of nasal mucosal transitional course after functional endoscopic sinus surgery and their clinical indications, *ORL J. Otorhinolaryngol. Relat. Spec.* 70 (2008) 118–123.
- [18] N. Yoshioka, Modified cranialization and secondary cranioplasty for frontal sinus infection after craniotomy: technical note, *Neurol. Med. Chir. (Tokyo)* 54 (2014) 768–773.
- [19] M. Zhu, Z. Zhou, Y. Chen, R. Schreiber, J.T. Ransom, J.K. Fraser, M.H. Hedrick, K. Pinkernell, H. Kuno, Supplementation of fat grafts with adipose-derived regenerative cells improves long-term graft retention, *Ann. Plast. Surg.* 64 (2010) 222–228.