

A rare case of ochronosis presenting with cervical compressive myelopathy

Sir,

Cervical compressive myelopathy is a common problem for which the etiopathology is varied. However, ochronosis with disc prolapse causing cervical compressive myelopathy has not been reported. There are only two reported cases of ochronosis causing cervical compressive myelopathy due to nondisc pathologies. We report and discuss a case of cervical disc prolapse with compressive myelopathy due to ochronosis.

Alkaptonuria (AKU) is a rare hereditary autosomal recessive genetic disorder characterized by a defect in the gene that codes for the enzyme homogentisate-1,2 dioxygenase.^[1] The reported incidence of the disorder is one in one million population.^[2] It occurs especially in the cartilage of the joints causing arthropathy; and, in the intervertebral discs, which is named as ochronosis.^[3-5] Ochronosis can affect cardiovascular, genitourinary, and respiratory systems.

AQ1 A 38-year old female patient presented with complaints of stiffness and heaviness in the lower limbs and difficulty in walking for 3 months. Earlier, she had difficulty in holding objects with both hands and tingling and numbness sensations

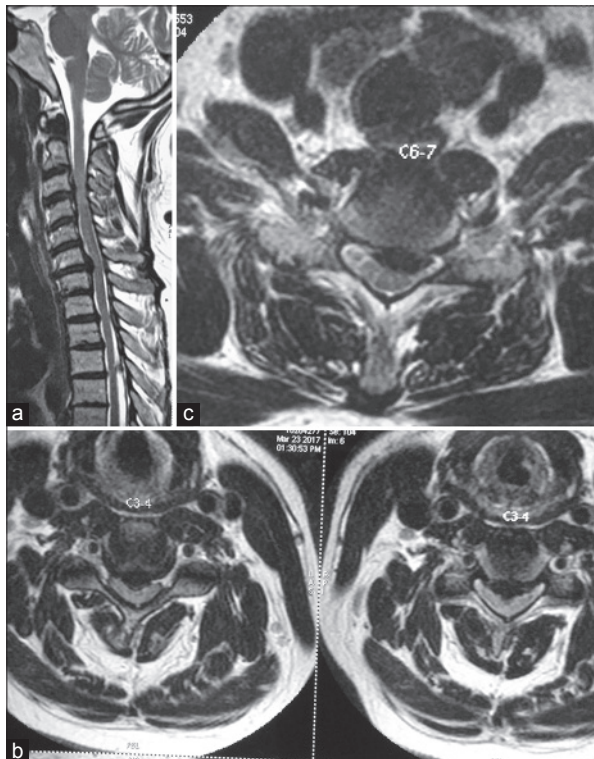


Figure 1: (a) MRI sagittal image of the cervical spine showing degenerated and prolapsed discs at the C3-4 and C6-7 levels. (b) MRI axial image at the C3-4 level showing disc prolapse with cord compression. (c) MRI axial image at the C6-7 vertebral level showing disc prolapse and cord compression

in both her upper limbs for an year's duration. On examination, there was hypertonia in all her limbs, decreased power in upper and lower limbs, and hyperreflexia. The magnetic resonance imaging (MRI) of the cervical spine showed degenerated C3-C4 and C6-C7 discs with prolapse, and significant cervical cord compression [Figure 1a-c].

By anterior cervical approach from the left side using a transverse incision, C3-C4 and C6-C7 discectomy were done and noninstrumented fusion was carried out with an iliac crest autologous bone graft. Intraoperatively, the discs and the posterior longitudinal ligament appeared black in color [Figure 2]. The disc material removed was sent for histopathological examination. The urine collected in the bag was brownish-black in color [Figure 3], and was sent for biochemical analysis. The pathological analysis of the disc material on haematoxylin and eosin (H and E) staining showed degenerating collagen, seen as loose thin fibers, containing deposits that showed grades of yellow discoloration [Figure 4a and b].^[6]

The urine analysis revealed the presence of benzoquinone acetic acid (BQA), which is a melanin-like pigment and is responsible for the brownish-black colour of urine. The patient had an uneventful postoperative course and was discharged on postoperative day 4.

Postoperatively, in 6 months, she had improved from Nurick grade 5 to grade 3. Spasticity in the limbs had decreased. She was counseled about the disease and its prognosis and the further chance of involvement of the skin, eyes and ears as well as the cardiovascular, and genitourinary systems.

Alkaptonuria is usually an autosomal recessive disorder; although in some cases, it is transmitted in an autosomal dominant manner. The aromatic amino acids, tyrosine and phenylalanine, are not metabolized beyond the stage of homogentisic acid (HGA). The absence of the enzyme leads to the accumulation of HGA in the body. Some of the excess HGA

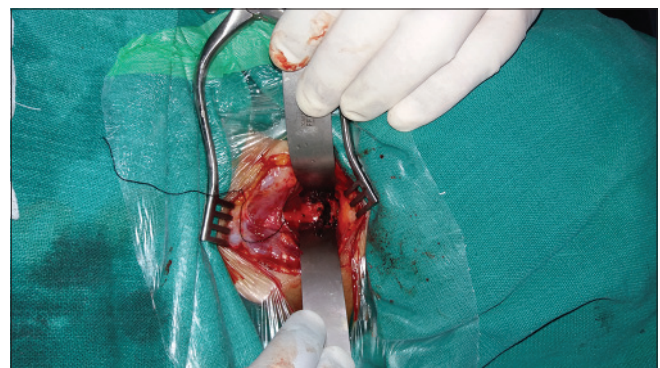

Figure 2: Intraoperative image showing the black coloured disc material



Figure 3: Urine collected in the urobag during the intraoperative period showing a brownish-black colouration

excretes through the urine, which turns dark on exposure to oxygen as alkalization occurs. Homogentisic acid is a strong reducing agent that on exposure to atmospheric oxygen gets converted to an oxidized polymer, BQA, which is black in colour. Urine containing homogentisic acid, therefore, turns black on standing. Rest of the accumulated HGA oxidizes initially, and subsequently, deposits within the connective tissue irreversibly turn into a melanin-like pigment. These are deposited in the collagen of tissues, such as cartilage and intervertebral discs, leading to spondyloarthropathies. This process is called ochronosis.

The three major features of AKU are the presence of HGA in the urine, ochronosis, and arthritis of the spine and larger joints.^[6] Rudolf Virchow in 1866 was the first to describe the condition “ochronosis,” indicating the yellow discoloration of the tissues under microscopic examination. However, the tissues on gross examination show grey-blue/black discoloration. Ochronotic tissues are stiffened and brittle. The deposits impair the normal functioning of tissues and causes damage. Other systems or tissues that may be affected are the kidneys with renal stones formation, prostatic tissue with deposits, and salivary glands as well as gallbladder with stones. Osteopenia may lead to fractures; weakening of collagen may lead to ruptures of muscular tendons and ligaments. Aortic valve disease has also been reported.^[6] Identification of these clinical conditions needs systemic investigations.

Histologically, the tissue containing deposits of HGA shows degenerating collagen, seen as loose thin fibres. On hematoxylin and eosin stain, the collagen containing the deposits shows grades of yellow discoloration.^[6] The deposits do not lose their pigmentation even after 3 days in 10% hydrogen peroxide. The ochronotic pigment shows a positive reaction with all routine stains for melanin.

Cervical myelopathy in ochronosis is usually due to degenerative changes in the spine, with osteophytes from the posterior part of the vertebral body and uncinat process encroaching upon the neural canal. The patient usually suffers from ochronotic spondylosis accompanied by peripheral joint arthropathy and the disease progresses to frank cervical spondylotic myelopathy. Complaints usually include neck pain with stiffness, low back pain and occasionally sciatica resulting from disc protrusion.^[6,7] A few cases of lumbar disc prolapse and thoracic compressive myelopathy with ochronosis have

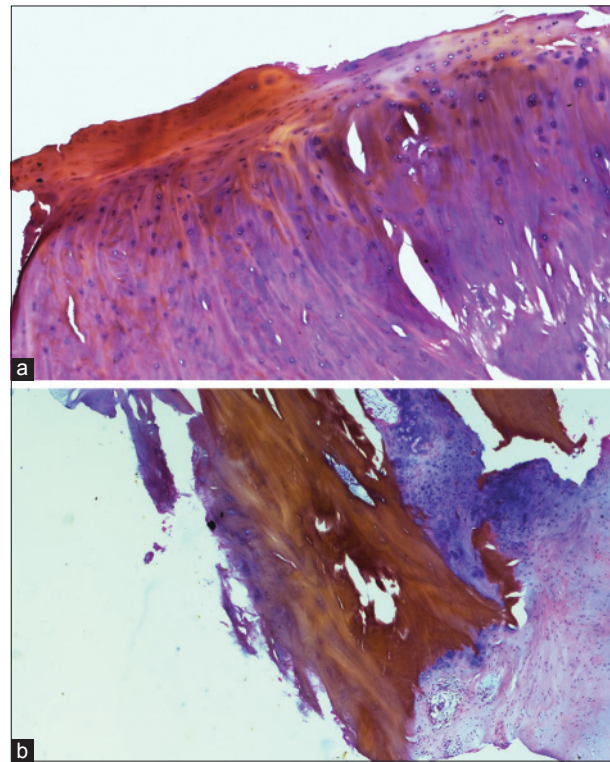


Figure 4: (a) Histopathology of the removed disc material showing degenerated collagen with yellowish deposits. (b) Histopathology of the involved disc showing the dark yellowish deposits

been described.^[6-10] A search for PubMed indexed articles on the association of ochronosis or alkaptonuria with cervical disc prolapse did not show any positive results. Neuropathy in ochronosis has been suggested by Mavra *et al.*^[11] They, however, did not find any clear association and so have opined that it may be an accidental finding as well.

Ochronosis should be considered as one of the pathologies responsible for disc prolapse in a patient where there is no other relevant history that may establish the aetiology of the disc prolapse. Enquiring about the color of urine may not help in the preoperative diagnosis, as urine, when passed, may still be straw colored. In some patients, alkaptonuria may be suspected if there is black pigmentation over the nose, ears, sclera, axilla, and groin. The clothes may be stained in region of the axilla, and the underclothes may also be stained.^[12] X-ray of the spine may show calcification of discs and MRI may show degenerated hypointense discs on T1 and T2 weighted imaging. The possibility of multilevel compression and also of postoperative recurrence due to the pathology being at another level should be kept in mind. Awareness of this condition will help the neurosurgeon explain the prognosis to the patient. Systemic examination should be done and the patient should be referred to the concerned specialists. In our patient, there were no clinical features like skin pigmentation, suggesting alkaptonuria to make a preoperative diagnosis. Ankylosing spondylitis, rheumatoid arthritis, and age-related degenerative spondylitis have been included in the differential diagnosis of ochronotic spine.^[6] Though there is no cure for this condition, dietary restriction of tyrosine and increased intake of vitamin C due to its antioxidant effect may be helpful.^[13] A close

follow-up of the patient is needed to help the patient lead a near normal life.

AKU is a rare metabolic as well as genetic disorder that can cause spinal compressive myelopathy and radiculopathy. It can involve the bones, cartilage, ligaments, and discs. Though the surgical management is not different from other causes of myelopathy or radiculopathy, awareness of this condition and its natural history and prognosis will help the surgeon in guiding the patient in the postoperative period.

Financial support and sponsorship

Nil.

Conflicts of interest

There are no conflicts of interest.

References

1. Fernández-Cañón JM, Granadino B, Beltrán-Valero de Bernabé D, Renedo M, Fernández-Ruiz E, Peñalva MA, *et al.* The molecular basis of alkaptonuria. *Nat Genet* 1996;14:19-24.
2. Li N, Tian W, Yuan Q, He D. Cervical spondylotic myelopathy due to the ochronotic arthropathy of the cervical spine. *J Korean Neurosurg Soc* 2016;59:65-8.
3. Van Offel JF, De Clerck LS, Francx LM, De Jonge MJ, Stevens WJ. A patient with ochronotic arthropathy and spondylopathy: A difficult differential diagnosis with spondylitis ankylosans. *Clin Exp Rheumatol* 1995;13:259-61.
4. Zhao BH, Chen BC, Shao de C, Zhang Q. Osteoarthritis? Ochronotic arthritis! A case study and review of the literature. *Knee Surg Sports Traumatol Arthrosc* 2009;17:778-81.
5. Kusakabe N, Tsuzuki N, Sonada M. Compression of the cervical cord due to alcaptonuric arthropathy of the atlanto-axial joint: A case report. *J Bone Joint Surg Am* 1995;77:274-7.
6. Babu SS, Sudhakar G, Sonylal PE, Sridevi M. Prolapsed lumbar disc in alkaptonuria. *J NTR Univ Health Sci* 2016;5:55-8.
7. Gurkanlar D, Daneyemez M, Solmaz I, Temiz C. Ochronosis and lumbar disc herniation. *Acta Neurochir* 2006;148:891-4.
8. Emel E, Karagöz F, Aydın IH, Hacısalihoğlu S, Seyithanoğlu MH. Alkaptonuria with lumbar disc herniation: A report of two cases. *Spine* 2000;25:2141-4.
9. Akeda K, Kasai Y, Kawakita E. Thoracic myelopathy with

alkaptonuria. *Spine* 2008;33:62-5.

10. Bozkurt S, Aktekin L, Uğurlu FG, Balci S, Sezer N, Akkus S. An unusual cause of myelopathy: Ochronotic spondyloarthropathy with positive HLA B27. *Am J Phys Med Rehabil* 2017;96:e206-9.
11. Mavraa M, Chadhaa G, Henein MM, Bhargava S. Alcaptonuria with myelopathy and neuropathy. *Med Principles Pract* 1999;8:73-6.
12. Findlay GH. Ochronosis. *Clin Dermatol* 1989;7:28-35.
13. Wolff JA, Barshop B, Nyhan WL, Leslie J, Seegmiller JE, Gruber H, *et al.* Effects of ascorbic acid in alkaptonuria: Alterations in benzoquinone acetic acid and an ontogenic effect in infancy. *Pediatr Res* 1989;26:140-4.


Mohan Nelanuthala, Sridhar Kotta¹, Sandeep Talari, Vijay K Terapalli

Department of Neurosurgery, Care Hospitals, ¹Department of Neurosurgery, Apex Hospital, Visakhapatnam, Andhra Pradesh, India

Address for correspondence:

Dr. Sandeep Talari,
Department of Neurosurgery, Care Hospitals,
Visakhapatnam, Andhra Pradesh, India.
E-mail: sandeep0214@gmail.com

This is an open access journal, and articles are distributed under the terms of the Creative Commons Attribution-NonCommercial-ShareAlike 4.0 License, which allows others to remix, tweak, and build upon the work non-commercially, as long as appropriate credit is given and the new creations are licensed under the identical terms.

Access this article online	
Website: www.neurologyindia.com	Quick Response Code 
DOI: xxxx	
PMID: xxxx	

How to cite this article: Nelanuthala M, Kotta S, Talari S, Terapalli VK. A rare case of ochronosis presenting with cervical compressive myelopathy. *Neurol India* 2018;66:XX-XX.
© 2018 Neurology India, Neurological Society of India | Published by Wolters Kluwer - Medknow

Author Query???

AQ1: Please ensure that the patient consent form has been obtained.