

signal previously present in the left cochlea, left vestibule, and right cochlea; a small amount of abnormal T1 hyperintensity was present in the right vestibule and superior semicircular canal (figure, C and D).

Discussion. In normal cochleae and vestibules, the endolymphatic fluid and perilymphatic fluid generate the same MR signals as CSF.¹ High signal seen on the precontrast T1-weighted images in our case helps to exclude an inflammatory process as the sole cause. The strategy of obtaining only enhanced images in the evaluation of sudden hearing loss may be misleading because without precontrast imaging, contrast enhancement related to inflammatory cochleitis and high T1 signal related to intracochlear hemorrhage cannot be easily distinguished.² Hyperintense T1 signal on precontrast scans can be caused by methemoglobin due to hemorrhage or elevated protein levels or both.³ Hyperintense T1 signal has been shown to persist for up to 6 months after the onset of symptoms, due to the extended lifespan of erythrocytes in perilymphatic fluid.¹ In the acute phase, T2-weighted images demonstrate hypointense signal due to the accumulation of deoxyhemoglobin and methemoglobin within intact erythrocytes, although this was not seen in our case.

Bilateral hearing loss, an uncommon manifestation of leukemia, has been reported in patients with acute and, rarely, chronic myeloid forms.⁴ Proposed etiologies include hyperleukocytosis, causing leukostasis and abnormal microvascular perfusion, leukemic infiltration, and infection.⁵ Autopsy cases from patients with acute myelogenous leukemia, chronic myelogenous leukemia, acute lymphocytic leukemia, and chronic lymphocytic leukemia demonstrated hemorrhage, leukemic infiltration, infection,⁶ and reduced hair cells. The inner ear is supplied by the labyrinthine artery (a branch of the anterior inferior cerebellar artery), whose small caliber and tortuosity predispose it to effects of hyperviscosity.⁴ Most reports are of acute hearing loss,^{4,5,7} which is more suggestive of infarction or hemorrhage rather than leukemic infiltration.^{4,5} In our patient, the improvement on MRI is likely due to resolution of blood products. Whether the initial hemorrhage was

due to leukemic infiltration or infarct is not clear, but the persistence of hearing loss suggests the latter.

From the Section of Neuroradiology (E.H., N.N., E.R.), Department of Radiology, Department of Medicine (O.F.), Robert H. Lurie Comprehensive Cancer Center, and Davee Department of Neurology and Neurological Sciences (M.C., J.R.), Feinberg School of Medicine, Northwestern University, Chicago, IL.

Disclosure: The authors report no conflicts of interest.

Received December 20, 2005. Accepted in final form March 17, 2006.

Address correspondence and reprint requests to Dr. M. Cherchi, Davee Department of Neurology and Neurological Sciences, Feinberg School of Medicine, Northwestern University, 710 North Lake Shore Dr., Abbott Hall, 11th fl., Chicago, IL 60611-3078; e-mail: m-cherchi2@md.northwestern.edu

Copyright © 2006 by AAN Enterprises, Inc.

References

1. Shinohara S, Yamamoto E, Saiwai S, et al. Clinical features of sudden hearing loss associated with a high signal in the labyrinth on unenhanced T1-weighted magnetic resonance imaging. *Eur Arch Otorhinolaryngol* 2000;257:480–484.
2. Papadopoulos A, Vlahos L, Xenelis J, Papafragou C, Adamopoulos G. Value of Gd-DTPA-enhanced MR imaging of the labyrinth in patients with sudden hearing loss. *Magn Res Imag* 1995;13:387–391.
3. Choi JH, Nath J, Chang A. MRI findings of vestibulocochlear hemorrhage in a leukemic patient with sensorineural hearing loss. *J Comput Assist Tomogr* 2002;26:699–700.
4. Chae SW, Cho JH, Lee JH, Kang HJ, Hwang SJ. Sudden hearing loss in chronic myelogenous leukaemia implicating the hyperviscosity syndrome. *J Laryngol Otol* 2002;116:291–293.
5. Naithani R, Chandra J, Mathur NN, Narayan S, Singh V. Brief report: hearing loss in chronic myeloid leukemia. *Pediatr Blood Cancer* 2005;45: 54–56.
6. Paparella MM, Berlinger NT, Oda M, el-Fiky F. Otological manifestations of leukemia. *Laryngoscope* 1973;83:1510–1526.
7. Genden EM, Bahadori RS. Bilateral sensorineural hearing loss as a first symptom of chronic myelogenous leukemia. *Otolaryngol Head Neck Surg* 1995;113:499–501.

Hemangioblastoma of the obex mimicking anorexia nervosa

G. Pavesi, MD; S. Berlucchi, MD; A. Feletti, MD; G. Opocher, MD; and R. Scienza, MD

Hemangioblastomas are benign vascular tumors that may affect CNS sporadically or as part of von Hippel–Lindau syndrome. The natural history of hemangioblastomas, which are characterized by a progressive and unpredictable rate of growth, has been well studied for the patients with VHL because they commonly need a long follow-up.^{1,2}

Posterior fossa and spine are the most frequent localizations. The dorsal pontomedullary junction, at the obex, is a common site for posterior fossa hemangioblastomas, producing mainly symptoms related to impairment of lower cranial nerves. Obstructive hydrocephalus may also occur when the lesion blocks CSF circulation. In the current study on two VHL patients with such lesions but no hydrocephalus, aversion to food, which especially in young females may frequently have a psychological origin, was the common presenting clinical feature.

Case reports. **Case 1.** An 18-year-old woman presented to our hospital with a 4-year history of eating disorders, initially

suggesting anorexia nervosa, with a recent worsening of her condition leading to a 37% weight loss in a few months. She had hypoesthesia and hyposthenia in the upper limbs, nausea, dizziness, and cervical pain and presented with a progressive dysphagia, which caused an aspiration pneumonia accompanied by deterioration of consciousness. No other symptoms of brainstem damage were detected. CT showed a large solid hemangioblastoma displacing the IV ventricle and involving the obex area (figure, A). These radiologic findings and family history suggested a diagnosis of VHL, which was confirmed by a VHL gene mutation analysis. Following surgical removal of the tumor and rehabilitation, the patient underwent a very good recovery, including a full normalization of her feeding habits.

Case 2. A 27-year-old woman affected by VHL disease was periodically monitored with MRI for multiple CNS localizations, including a small solid nodule at the caudal end of the fourth ventricle floor associated with a syrinx of the medulla oblongata. Aversion to food intake had started 4 years before admission, resulting in a progressive weight loss from 55 to 37 kg (32%), for which she was undergoing psychotherapy. During the last months, she had mild ataxia, fatigue, palpitations, headache, vomiting, and sporadic opisthotonic fits. No other signs of brainstem dysfunction were observed. MRI showed a mild increase in size of the lesion in the fourth ventricle (figure, B). A surgical removal of the obex lesion and three small satellite nodules at the cervicobulbar junction resulted in an immediate relief of her eating disorder and a rapid return of her body weight to normal.

Discussion. The results reinforce the notion that clinical conditions initially interpretable as psychiatric eating disorders can be caused by focal brain lesions. Whereas there is considerable evidence that eating disorders can occur following hypothalamic or right frontal and temporal lobe damage,^{3,4} cases of anorexia possibly resulting from brainstem lesions have seldom been reported.^{5,6} The two cases described here are interesting because their eating disorders were undoubtedly caused by treatable brainstem tumors, as shown by the complete recovery of normal eating habits following the surgical removal of such tumors. Both patients had a VHL disease initially presenting with persistent food refusal, followed by the appearance of clear-cut neurologic

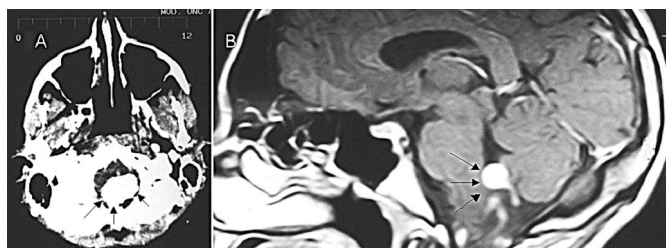


Figure. Contrast CT of Case 1 (A) and MRI of Case 2 (B), showing both the hemangioblastomas (arrows) growing in the obex area of the medulla oblongata.

symptoms in about 4 years. An organic basis for an apparently functional anorexic condition should be suspected when chronic food aversion is associated with symptoms such as occasional fainting, palpitations, dyspepsia, and vomiting, all of which are often neglected in a typical focal sign-seeking neurologic exam. With regard to pathophysiology, the most likely cause of the current eating disorders and associated symptoms was an encroachment of the lesions on the region of the nuclei of the lower cranial nerves, especially the vagus nerve and the nucleus of the solitary tract. The vagus nerve plays a major role in the regulation of alimentary canal functions from pharynx to colon, and the nucleus of the solitary tract has recently been shown to be a key relay of satiety signals conveyed by afferent vagal fibers,⁷ so that disturbances in appetite regulation can be expected to occur after lesions of these structures. On the other hand, observations of eating disorders in cases with lesions involving the brainstem at the medulla oblongata are rare.³

From the Department of Neurosurgery (G.P., S.B., A.F., R.S.), Padua City Hospital, and Department of Endocrinology (G.O.), Padua University, Italy.

Disclosure: The authors report no conflicts of interest.

Received September 7, 2005. Accepted in final form March 21, 2006.

Passive smoking and Parkinson disease

George D. Mellick, PhD; Coral E. Gartner, BSc (Hons); Peter A. Silburn, FRACP, PhD; and Diana Battistutta, PhD

Cigarette smoking is consistently associated with a reduced risk of Parkinson disease (PD), having been reported in prospective studies,¹ retrospective case-control studies,² twin studies,³ and studies of case-sibling pairs.⁴ Conjecture remains as to whether this association reflects a true biologic neuroprotection from tobacco smoking or whether shared genetic and behavioral factors influence both smoking propensity and PD risk.

Although genetic and behavioral factors may have less influence on an individual's exposure to passive tobacco smoke, there are no previous reports on the effects of passive smoking on the risk for PD. Here we provide evidence that passive exposure to cigarette smoke might also be less common in PD.

We recruited 163 patients with PD. Inclusion criteria were community-dwelling patients who had consulted the clinic of one of the authors between October 2003 and October 2004 and received a diagnosis of definite idiopathic PD⁵; assessed at >27 on the Mini-Mental State Examination (MMSE); capable of completing the risk factor questionnaire; and currently listed in the Australian Commonwealth Electoral Roll (voting is compulsory in Australia). Exclusion criteria were a diagnosis of dementia or symptoms suggestive of an alternative form of parkinsonism. Each of 151 patients was individually matched to a control (free of parkinsonism and screening >27 MMSE) selected by random sampling from all enrolled voters of the same sex, age (± 2 years), and residential suburb.

Questions were asked regarding history of tobacco smoking. Information about initiation, cessation, frequency, and quantities smoked was collected. Regular smoking was defined as having smoked "as often as once/week regularly for 6 months or more." In addition, several questions assessed exposure to passive smoke. These assessed whether and for how long: 1) participants had lived with a smoker (and how often the smoker smoked in the participant's vicinity) and 2) participants had worked in workplaces with substantial tobacco smoke. The relevant section of our structured questionnaire is presented in table E-1 on the *Neurology* Web site (go to www.neurology.org). The development and establishment of test-retest repeatability of the study instrument is described elsewhere.⁶

Relative odds of passive smoking exposure (PD cases to con-

Address correspondence and reprint requests to Dr. G. Pavesi, Neurosurgery, Padua City Hospital, Via Giustiniani 2, 35100, Padua, Italy; e-mail: giacomo.pavesi@sanita.padova.it

Copyright © 2006 by AAN Enterprises, Inc.

References

1. Niemelä M, Lemeta S, Summanen P, et al. Long-term prognosis of haemangioblastoma of the CNS: impact of von Hippel-Lindau disease. *Acta Neurochir* 1999;141:1147-1156.
2. Wanebo JE, Lonser RR, Glenn GM, Oldfield EH. The natural history of hemangioblastomas of the central nervous system in patients with von Hippel-Lindau disease. *J Neurosurg* 2003;98:82-94.
3. Chipkevitch E. Brain tumors and anorexia nervosa syndrome. *Brain Dev* 1994;16:175-179.
4. Uher R, Treasure J. Brain lesions and eating disorders. *J Neurol Neurosurg Psychiatry* 2005;76:852-857.
5. Grossmann D, Burtzlaff B, Griefahn B, et al. Cavernoma of the medulla oblongata mimicking "anorexia nervosa"—a case report. *Klin Padiatr* 2002;214:41-44.
6. Maroon JC, Albright L. "Failure to thrive" due to pontine glioma. *Arch Neurol* 1977;34:295-297.
7. Schwartz MW, Woods SC, Porte D Jr, et al. Central nervous system control of food intake. *Nature* 2000;404:661-671.

trols) and 95% CIs were estimated using conditional logistic regression for matched sets in SAS version 9.1. The multivariable model included consumptions of coffee (average cups per day), alcohol (average drinks per day), and tea (regular), family history of PD (first- or second-degree relative), hobby gardening, and tobacco smoking (pack-years) as potential confounding variables. Exposures for active smoking, coffee, tea, and alcohol were considered up to age at diagnosis in cases; for control subjects, truncation occurred at age at diagnosis of their matched case. No truncation was applied to the passive smoking data.

Eighty-six percent of eligible patients and 69% of invited control subjects participated. Sixty-three percent of participants were men; mean age was 67 years (SD 9 years). Median years since diagnosis of PD for cases was 6 years (range 0 to 33 years).

Smoking prevalence in PD cases and effect size for ever smoking (odds ratio [OR] = 0.66) are consistent with Australian data⁷; a significant dose-response relationship was observed (pack-years OR = 0.98, 95% CI = 0.97 to 0.99). Interestingly, we observed that all variables assessing passive smoking exposure were also consistently less common in the PD vs control group (table). Whereas the 95% CIs for most of these observations span unity, these data provide preliminary evidence that passive smoking is, independently of active smoking, associated with a reduced risk for PD. Moreover, the passive smoking effect was statistically dose dependent, with increased exposure associated with reduced risk. Further evidence in support of this observation comes from our analysis of the sample stratified for regular/never active smoking status. This revealed similar trends in the passive smoking variables for both groups; the effect of exposure of passive tobacco smoke is independent of active smoking.

It has been argued that the association between smoking and PD is related to common genetic variables predisposing to both PD and an aversion to cigarette smoking. Whereas aversion to cigarette smoking may also influence an individual's preference for "smoke-free" environments, one might speculate that, compared with active smoking, passive smoking is less dependent upon genetic predilection. Alternatively, the association could result from the presence of neuroprotective constituents of cigarette smoke (e.g., nicotine or monoamine oxidase inhibitors). In this exploratory study, we did not examine more quantitative measures of passive smoking exposure; repeatability of these estimates was poor. Nor did we examine the specific sources and chronology of the exposures. Our data are also limited by power constraints and other potential biases inherent in case-control study design. Nonetheless, our results implicate passive smoking as another factor influencing PD risk.

From the Institute of Cell and Molecular Therapies (G.D.M.), Griffith University, School of Public Health and Institute of Health and Biomedical Innovation (C.E.G., D.B.), Queensland University of Technology, and De-

Additional material related to this article can be found on the *Neurology* Web site. Go to www.neurology.org and scroll down the Table of Contents for the July 11 issue to find the title link for this article.