

Amaurosis in infancy due to craniopharyngioma: a not-exceptional but often misdiagnosed symptom

ALBERTO FELETTI, M.D.,¹ ELISABETTA MARTON, M.D.,¹ GRAZIA MARINA MAZZUCCO, M.D.,¹ SHANNA FANG, B.S.,² AND PIERLUIGI LONGATTI, M.D.¹

¹Department of Neurosurgery, Treviso Regional Hospital–University of Padova, Treviso, Italy; and ²Department of Neurological Surgery, University of California, San Francisco, California

Since children may not be able to complain of progressive reduction in optic acuity, visual assessment in infancy may present practical difficulties. The authors report a case of craniopharyngioma, which led a young child to early blindness before the correct diagnosis could be made. Similar to other reported cases, the authors found that surgery did not substantially modify the preoperative visual deficit. They conclude that minimal improvement in visual acuity can be expected despite successful microsurgical removal of the tumor. (DOI: 10.3171/2010.1.FOCUS09262)

KEY WORDS • craniopharyngioma • amaurosis • childhood • misdiagnosis • visual outcome

CRANIOPHARYNGIOMAS are rare brain tumors that cause visual impairments and symptoms in almost all cases. Visual disturbances are notoriously misleading in infancy since ophthalmological symptoms are difficult to detect, and they commonly result in incorrect differential diagnoses. Furthermore, it is not easy to determine the indication for neuroradiological assessment in children whose visual symptoms are unclear.

Although rarely, pediatric patients may undergo neurosurgical evaluation when amaurosis is already present. The reported case illustrates how the rare but insidious craniopharyngioma can cause amaurosis to be misdiagnosed as more benign visual impairments.

Case Report

This 2-year-old girl presented with a 9-month history of progressive divergent strabismus, which began initially in the left eye, and then progressed to bilateral strabismus. The pediatric ophthalmologist, diagnosing the patient with congenital strabismus, prescribed the usual occlusion therapy to avoid amblyopia and continued with patient follow-up. After some months, however, the child's relatives noted some gait uncertainty, with disequilibrium, frequent falls, and difficulty in evaluating the distances of objects. The little girl walked up the stairs, touching the steps one by one; when the floor changed color, she stopped walking, squatted down, and felt her way along the floor to determine if there was a step in front of her. This behavior frightened her parents who brought their

daughter to our hospital for an urgent evaluation. At admission, the child's hypothalamus-pituitary axis function was unimpaired, but fundus oculi examination revealed an atrophic papilla (Fig. 1). Magnetic resonance imaging showed the presence of an expansive sellar lesion of 3.8-cm maximum diameter, with severe compression of the optic chiasm, suggesting a diagnosis of craniopharyngioma (Fig. 2). Visual evoked potentials demonstrated a complete absence of cortical signal (Fig. 3).

The tumor, found to be adherent to the optic nerves, was radically removed through a frontobasal interhemispheric approach with preservation of the pituitary stalk. Pathological examination confirmed the diagnosis of adamantinomatous craniopharyngioma (WHO Grade I). Aside from transient polydipsia, the patient's postoperative recovery was uneventful, although she continues to experience subtotal visual deficit and unstable gait. An MR imaging examination 1 year after surgery confirmed complete removal of the tumor (Fig. 2).

Discussion

The child whose case is reported above developed visual disturbances without anyone noticing it until an almost complete amaurosis: the ophthalmologist focused on the strabismus, disregarding the progressive loss of visual acuity. It is surprising that in this era a benign tumor like craniopharyngioma could be detected only after such serious damage to the optic nerves.

Despite the vast amount of literature on craniopharyngioma,

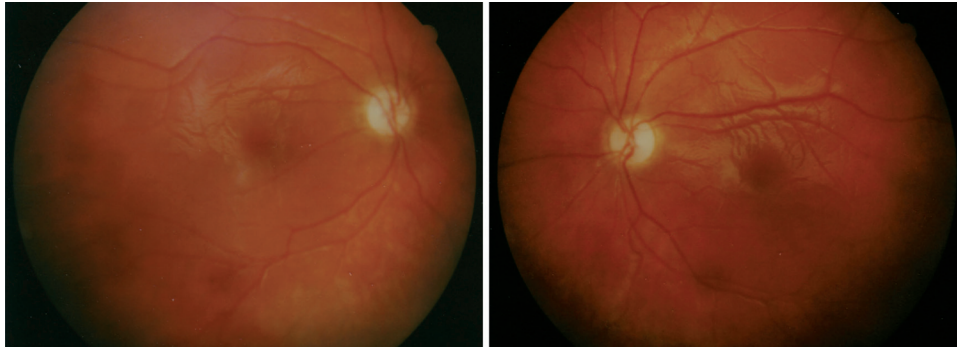


Fig. 1. Fundus oculi revealing an atrophic papilla.

ryngiomas, the incidence of amaurosis due to this benign tumor in the pediatric population has not yet been established. We reviewed the literature to identify all cases of craniopharyngiomas causing blindness in children and found an incidence of amaurosis ranging from 0 to 33% (Table 1). It is remarkable that the highest incidences often correspond to series of patients from developing countries,^{2,16} or from specific subpopulations such as giant craniopharyngiomas.³ It is likely that amaurosis is not that unusual a symptom in infants with craniopharyngio-

ma, but its prevalence is probably underestimated. The high variability in reported incidence rates may be due to difficulty in assessing visual acuity in very young children, who are usually unable to communicate these important visual changes. The reported frequency of visual disturbances due to craniopharyngioma is higher in the adult population than in children,²⁶ probably because of frequent misdiagnosis in pediatric patients. Furthermore, young age at diagnosis and the presence of visual symptoms are unfavorable predictors of visual outcome since

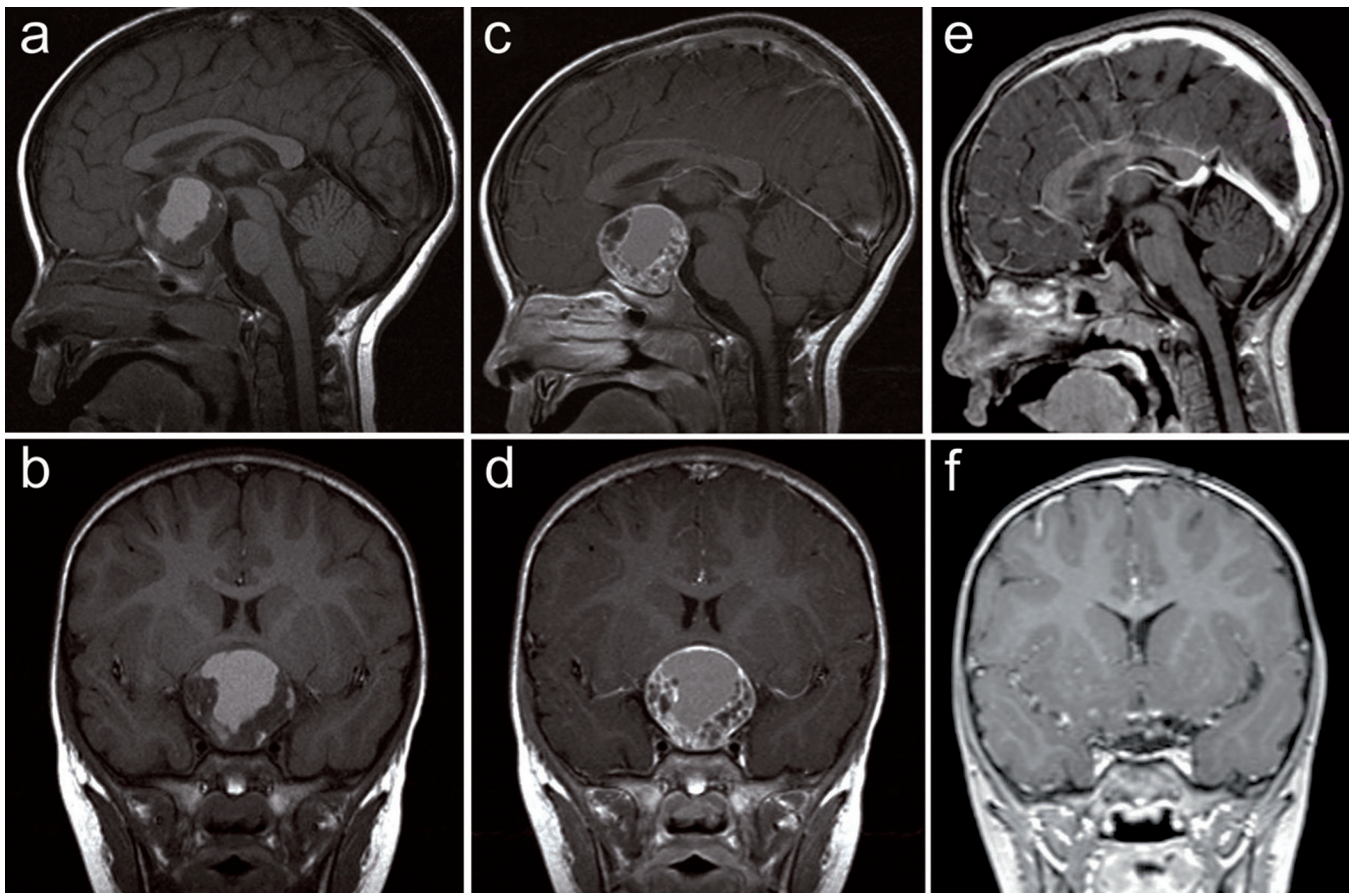


Fig. 2. **a-d**: Preoperative T1-weighted sagittal and coronal MR images, without (**a and b**) and with (**c and d**) gadolinium, demonstrating the presence of an expansive sellar lesion of 3.8-cm maximum diameter, with considerable compression of the optic chiasm. **e and f**: Postoperative Gd-enhanced T1-weighted sagittal and coronal MR images obtained 1 year after surgery confirming complete removal of the tumor and absence of any recurrence.

Amaurosis in infancy due to craniopharyngioma

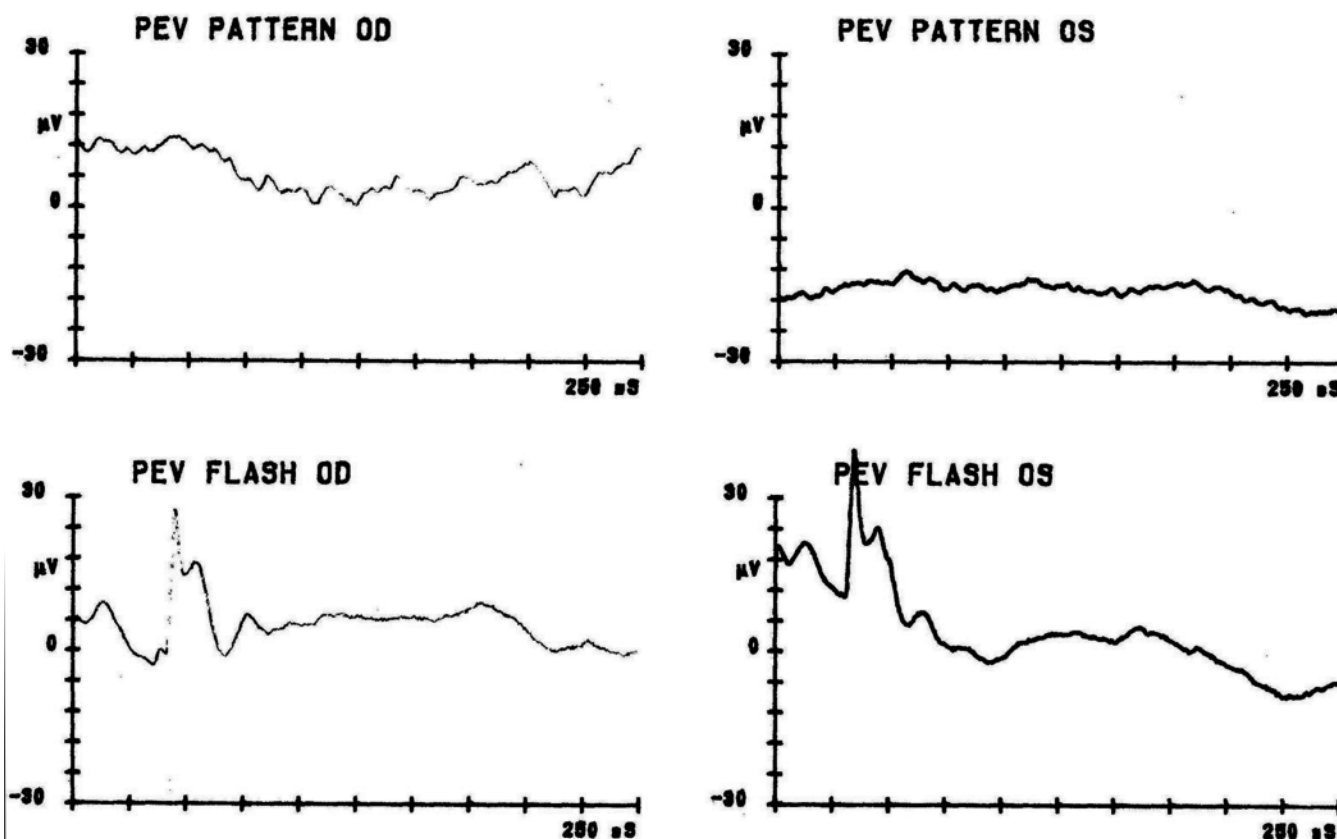


Fig. 3. Preoperative pattern and flash visual evoked potentials showing an almost complete absence of cortical signal. OS = left eye; OD = right eye; PEV = visual evoked potentials.

impairment of the optic pathways occurs more rapidly in children under 3 years of age.^{1,13} It has been demonstrated that visual acuity deficits seldom improve even after surgical decompression of optic nerves;¹³ in fact, the deficit often remains unchanged or continues to worsen.^{2,6,7,28} For patients suffering from amaurosis, it is suggested that preoperative visual loss is strongly predictive of persistent postoperative visual deficits.¹³

Pediatric patients presenting with amaurosis and showing improvement in visual function after surgical treatment of craniopharyngioma are extremely rare.^{4,18,25} The complete vision recovery in a 9-year-old girl reported by Stark et al.²⁸ should be considered exceptional. In fact, only a few cases of complete visual recovery after surgery have been reported in patients suffering from nontraumatic compression of the anterior visual pathway.^{14,28,29} All other pediatric patients for whom clinical evaluation at follow-up is available showed uniformly persistent visual acuity deficits. Although pediatric craniopharyngioma patients presenting with amaurosis are often included in larger series and specific visual follow-up is only occasionally available, the outcome for unilateral amaurosis does not seem to be different than that for bilateral amaurosis.^{3,5,10} No significant improvement should be expected when serious damage to one or both optic nerves is present.^{10,21}

For these reasons, a well-timed diagnosis of visual impairments is vital to avoid irreparable deficits in children. Special attention to any behavioral change, usually

reported by parents, is sometimes the most important way to reduce the diagnostic delay. Moreover, neuroradiological assessments like MR imaging should be taken into consideration in cases of long-lasting strabismus or papillary alterations on fundus oculi examination.

Although visual function only occasionally improves after surgery, especially in cases of amaurosis, every effort should be made to preserve the anatomical integrity of the optic nerve during the removal of the tumor. The surgical planning is important, as the pterional approach carries a not-negligible risk of postoperative visual worsening.²³ Instead, we chose the interhemispheric approach, which allows for minimal traction on the optic structures.

Due to the excellent survival rates of these patients in the modern era, long-term consequences of treatment and overall quality of life are of utmost importance, especially when deciding on a treatment strategy. In addition to the visual deficits, endocrine balance, neurological and hypothalamic function, school performance, and behavioral and emotional status are often impaired in patients with craniopharyngioma.²⁴ Therefore, these children may have a worse quality of life than patients who are blind for other causes. In the major pediatric series of surgically treated cases, the rates of diabetes insipidus and hypothalamic obesity vary between 33–100% and 15–94%, respectively, and the incidences of visual deficits and neurological morbidity vary between 0 and 41% and 0 and 29%,

TABLE 1: Review of amaurosis caused by craniopharyngioma in childhood*

Authors & Year	No. of Pts	No. of Pts w/ Amaurosis (%)		Outcome	FU
		Monolat	Bilat		
Kennedy & Smith, 1975	14	1 (7)			
Al-Mefty et al., 1985	20†	2 (10)	5 (25)	not impr	up to 3 yrs
Adeloye et al., 1988	20		4 (20)	not impr	
Ammirati et al., 1990		1		not impr	
al-Wahhabi et al., 1993	1		1	rt eye: impr; lt eye: not impr	2 wks
Abrams & Repka, 1997	20	2 (10)‡		8 pts‡	mean 6.5 yrs
Stark et al., 1999	1	1		impr	6 yrs
Duff et al., 2000		5		80% poor	
Van Effenterre & Boch, 2002	29		7 (24)		
Gonc et al., 2004	64	14 (22)	6 (9)		median 5.1 yrs
Erşahin et al., 2005	87	13 (15)			
Hukin et al., 2005	29	2 (7)	2 (7)	impr	median 84 mos
Lena et al., 2005	47	3 (6)	2 (4)	not impr	min 5 yrs
Mottolese et al., 2005	60		2 (3)		
Teo, 2005	36		5 (14)		
Sainte-Rose et al., 2005	66		7 (10)		mean 7 yrs
Zuccaro, 2005	153		13 (8.5)	not impr	
Hamid et al., 2007	12		4 (33)		
Puget et al., 2007	66 (retrosp) 22 (prosp)	10 (15) 4 (18)		not impr 3 impr	

* FU = follow-up; impr = improved; prosp = prospective; Pts = patients; retrosp = retrospective.

† Giant craniopharyngiomas.

‡ Visual acuity < 20/200.

respectively.^{11,24} Moreover, several authors reported worse outcome and a higher chance of recurrence in younger children.^{8,9,12,13} Age under 5 years has been reported to be a predictor of poor outcome at a long-term follow-up,⁹ higher risk of tumor progression following Gamma Knife surgery,²⁰ and decreased resistance of the hypothalamus to surgical trauma.¹⁷

The case presented in this paper and those reviewed in the literature caution against underestimation of visual impairments in children, and demonstrate the importance of careful ophthalmological evaluation in pediatric patients who are often unable to identify and reliably report visual deficits. In order to arrive at the correct diagnosis, the physician often needs to know details of the child's daily behavior and changes of habits, as provided by the parents of the child in our case.

Disclosure

The authors report no conflict of interest concerning the materials or methods used in this study or the findings specified in this paper. Author contributions to the study and manuscript preparation include the following. Conception and design: A Feletti. Acquisition of data: A Feletti. Analysis and interpretation of data: A Feletti. Drafting the article: A Feletti. Critically revising the article: E Marton, GM Mazzucco, S Fang, P Longatti. Reviewed final version of the manuscript and approved it for submission: A Feletti, E Marton, GM Mazzucco, S Fang, P Longatti. Study supervision: P Longatti.

References

1. Abrams LS, Repka MX: Visual outcome of craniopharyngioma in children. *J Pediatr Ophthalmol Strabismus* **34**:223–228, 1997
2. Adeloye A, Nottidge VA, Udi J: Craniopharyngioma in Nigerian children. *Childs Nerv Syst* **4**:128–134, 1988
3. Al-Mefty O, Hassounah M, Weaver P, Sakati N, Jinkins JR, Fox JL: Microsurgery for giant craniopharyngiomas in children. *Neurosurgery* **17**:585–595, 1985
4. al-Wahhabi B, Choudhury AR, al-Moutaery KR, Aabed M, Faqeeh A: Giant craniopharyngioma with blindness reversed by surgery. *Childs Nerv Syst* **9**:292–294, 1993
5. Ammirati M, Samii M, Sefhernia A: Surgery of large ret-rochiasmatic craniopharyngiomas in children. *Childs Nerv Syst* **6**:13–17, 1990
6. Caldarelli M, Massimi L, Tamburrini G, Cappa M, Di Rocco C: Long-term results of the surgical treatment of craniopharyngioma: the experience at the Policlinico Gemelli, Catholic University, Rome. *Childs Nerv Syst* **21**:747–757, 2005
7. Chen C, Okera S, Davies PE, Selva D, Crompton JL: Craniopharyngioma: a review of long-term visual outcome. *Clin Experiment Ophthalmol* **31**:220–228, 2003
8. Choux M, Lena G, Genitori L: Le craniopharyngiome de l'enfant. *Neurochirurgie* **37** (1 Suppl):1–174, 1991
9. De Vile CJ, Grant DB, Kendall BE, Neville BG, Stanhope R, Watkins KE, et al: Management of childhood craniopharyngioma: can the morbidity of radical surgery be predicted? *J Neurosurg* **85**:73–81, 1996
10. Duff JM, Meyer FB, Ilstrup DM, Laws ER, Schleck CD, Scheithauer BW: Long-term outcomes for surgically resected craniopharyngiomas. *Neurosurgery* **46**:291–305, 2000

Amaurosis in infancy due to craniopharyngioma

11. Elliott RE, Wisoff JH: Successful surgical treatment of craniopharyngioma in very young children. **J Neurosurg Pediatr** 3:397–406, 2009
12. Erşahin Y, Yurtseven T, Ozgiray E, Mutluer S: Craniopharyngiomas in children: Turkey experience. **Childs Nerv Syst** 21:766–772, 2005
13. Fisher PG, Jenab J, Gopldthwaite PT, Tihan T, Wharam MD, Foer DR, et al: Outcomes and failure patterns in childhood craniopharyngiomas. **Childs Nerv Syst** 14:558–563, 1988
14. Garrott HM, Wallace D, Wallace DJ: Ossifying fibroma of the jugum sphenoidale. **J Clin Neurosci** 11:544–546, 2004
15. Gonc EN, Yordam N, Ozon A, Alikasifoglu A, Kandemir N: Endocrinological outcome of different treatment options in children with craniopharyngioma: a retrospective analysis of 66 cases. **Pediatr Neurosurg** 40:112–119, 2004
16. Hamid R, Sarkar S, Hossain MA, Mazumder U, Akanda NI, Parvin R: Clinical picture of craniopharyngioma in childhood. **Mymensingh Med J** 16:123–126, 2007
17. Hayward R: The present and future management of childhood craniopharyngioma. **Childs Nerv Syst** 15:764–769, 1999
18. Hukin J, Visser J, Sargent M, Goddard K, Fryer C, Steinbok P: Childhood craniopharyngioma: Vancouver experience. **Childs Nerv Syst** 21:758–765, 2005
19. Kennedy HB, Smith RJ: Eye signs in craniopharyngioma. **Br J Ophthalmol** 59:689–695, 1975
20. Kobayashi T, Kida Y, Mori Y, Hasegawa T: Long-term results of gamma knife surgery for the treatment of craniopharyngioma in 98 consecutive cases. **J Neurosurg** 103 (6 Suppl):482–488, 2005
21. Lena G, Paz Paredes A, Scavarda D, Giusiano B: Craniopharyngioma in children: Marseille experience. **Childs Nerv Syst** 21:778–784, 2005
22. Mottolise C, Szathmari A, Berlier P, Hermier M: Craniopharyngiomas: our experience in Lyon. **Childs Nerv Syst** 21:790–798, 2005
23. Pierre-Kahn A, Sainte-Rose C, Renier D: Surgical approach to children with craniopharyngiomas and severely impaired vision: special considerations. **Pediatr Neurosurg** 21 (Suppl 1):50–56, 1994
24. Poretti A, Grotzer MA, Ribl K, Schönle E, Boltshauser E: Outcome of craniopharyngioma in children: long-term complications and quality of life. **Dev Med Child Neurol** 46:220–229, 2004
25. Puget S, Garnett M, Wray A, Grill J, Habrand JL, Bodaert N, et al: Pediatric craniopharyngiomas: classification and treatment according to the degree of hypothalamic involvement. **J Neurosurg** 106 (1 Suppl):3–12, 2007
26. Rushing EJ, Giangaspero F, Paulus W, Burger PC: Craniopharyngioma, in Louis DN, Ohgaki H, Wiestler OD, Cavenee WK (eds): **WHO Classification of Tumours of the Central Nervous System**. Lyon: IARC Press, 2007, pp 238–240
27. Sainte-Rose C, Puget S, Wray A, Zerah M, Grill J, Brauner R, et al: Craniopharyngioma: the pendulum of surgical management. **Childs Nerv Syst** 21:691–695, 2005
28. Stark KL, Kaufman B, Lee BC, Primack J, Tychsen L: Visual recovery after a year of craniopharyngioma-related amaurosis: report of a nine-year-old child and a review of pathophysiological mechanisms. **J AAPOS** 3:366–371, 1999
29. Taşdemiroğlu E, Zuccarello M, Tew JM Jr: Recovery of vision after transcranial decompression of pituitary apoplexy characterized by third ventricular hemorrhage. **Neurosurgery** 32:121–124, 1993
30. Teo C: Application of endoscopy to the surgical management of craniopharyngiomas. **Childs Nerv Syst** 21:696–700, 2005
31. Van Effenterre R, Boch AL: Craniopharyngioma in adults and children: a study of 122 surgical cases. **J Neurosurg** 97:3–11, 2002
32. Zuccaro G: Radical resection of craniopharyngioma. **Childs Nerv Syst** 21:679–690, 2005

Manuscript submitted November 10, 2009.

Accepted January 19, 2010.

Address correspondence to: Alberto Feletti, M.D., Department of Neurosurgery, Treviso Regional Hospital–University of Padova, 31100, Treviso, Italy. email: alberto.feletti@unipd.it.