

Cavum septi pellucidi and external ventricular drain failure

Case illustration

ALBERTO FELETTI, M.D., LUCA DENARO, M.D., ROBERTO FAGGIN, M.D., PIETRO CICCARINO, M.D., MARTA ROSSETTO, M.D., AND DOMENICO D'AVELLA, M.D.

Neuroscience Department, Academic Neurosurgery, University of Padova, Italy

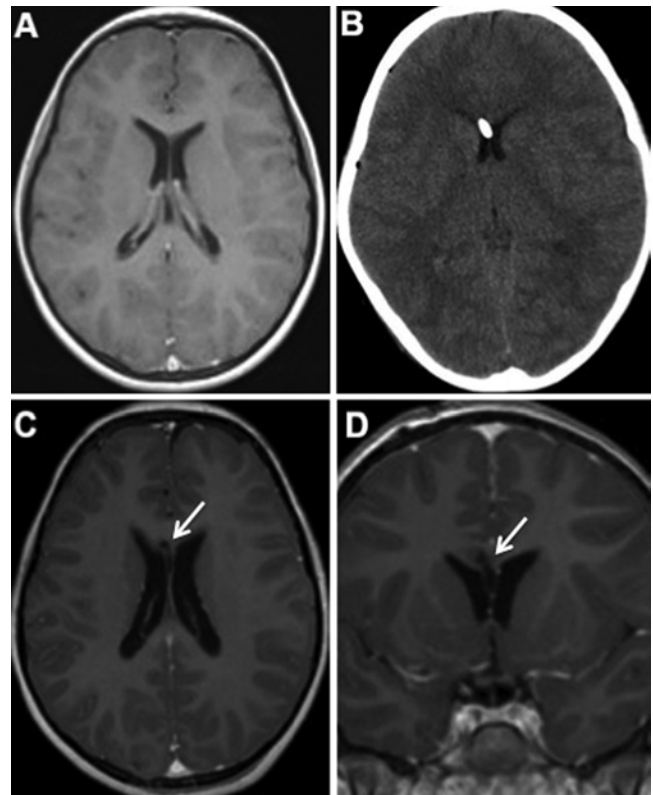
KEY WORDS • cavum septi pellucidi • external ventricular drain • failure

An external ventricular drain was placed in an 8-year-old patient after surgery for medulloblastoma resection. The following day, the shunt was no longer draining. A CT scan showed correct placement of the catheter; however, an MR image revealed the tip of the catheter resting within the two layers of the septum pellucidum, which had adhered to the shunt (Fig. 1). Cavum septi pellucidum is an uncommon anatomical condition. If a catheter is fortuitously inserted into a preexisting cavum, or the catheter splits the two leaves of the septum, the walls of the cavum can adhere to and consequently block the shunt.^{1,2} (DOI: 10.3171/2011.4.PEDS1114)

References

1. Mapstone TB, White RJ: Cavum septi pellucidi as a cause of shunt dysfunction. *Surg Neurol* 16:96–98, 1981
2. Shaw CM, Alvord EC Jr: Cava septi pellucidi et vergae: their normal and pathological states. *Brain* 92:213–223, 1969

FIG. 1. **A:** Preoperative MR image showing no evidence of cavum septi pellucidi. **B:** A CT scan showing the correctly placed catheter. **C and D:** Axial (**C**) and coronal (**D**) MR images showing the route of the catheter (arrows).



Manuscript submitted January 12, 2011; accepted April 19, 2011.

Disclosure: The authors report no conflict of interest concerning the materials or methods used in this study or the findings specified in this paper. Author contributions to the study and manuscript preparation include the following. Conception and design: Feletti, Denaro, Rossetto. Acquisition of data: Ciccarino, Rossetto. Drafting the article: Feletti, Faggin. Critically revising the article: Denaro, Faggin, Ciccarino, d'Avella. Study supervision: d'Avella.

Address correspondence to: Alberto Feletti, M.D., Neuroscience Department, Academic Neurosurgery, University of Padova, Via Giustiniani 5, 35128 Padova, Italy. email: alberto.feletti@unipd.it.