

Neuroendoscopic Aspiration of Blood Clots in the Cerebral Aqueduct and Third Ventricle During Posterior Fossa Surgery in the Prone Position

Alberto Feletti, MD, PhD*
Riccardo Stanzani, MD*
Matteo Alicandri-Ciuffelli, MD*
Giuliano Giliberto, MD*
Matteo Martinoni, MD*
Giacomo Pavesi, MD*

*Department of Neurosciences, Neurosurgery Unit, Azienda Ospedaliero-Universitaria di Modena, Modena, Italy;
 †IRCCS Institute of Neurological Sciences of Bologna, Division of Neurosurgery, Bellaria Hospital, Bologna, Italy

Correspondence:

Alberto Feletti, MD, PhD,
 Department of Neurosciences,
 Neurosurgery Unit,
 Azienda Ospedaliero-Universitaria di
 Modena,
 Via Giardini 1355,
 41126 Baggiovara (MO), Italy.
 E-mail: a.feletti@ausl.mo.it

Received, April 11, 2018.

Accepted, September 22, 2018.

Copyright © 2018 by the
 Congress of Neurological Surgeons

BACKGROUND: During surgery in the posterior fossa in the prone position, blood can sometimes fill the surgical field, due both to the less efficient venous drainage compared to the sitting position and the horizontally positioned surgical field itself. In some cases, blood clots can wedge into the cerebral aqueduct and the third ventricle, and potentially cause acute hydrocephalus during the postoperative course.

OBJECTIVE: To illustrate a technique that can be used in these cases: the use of a flexible scope introduced through the opened roof of the fourth ventricle with a freehand technique allows the navigation of the fourth ventricle, the cerebral aqueduct, and the third ventricle in order to explore the cerebrospinal fluid pathways and eventually aspirate blood clots and surgical debris.

METHODS: We report on one patient affected by an ependymoma of the fourth ventricle, for whom we used a flexible neuroendoscope to explore and clear blood clots from the cerebral aqueduct and the third ventricle after the resection of the tumor in the prone position. Blood is aspirated with a syringe using the working channel of the scope as a sucker.

RESULTS: A large blood clot that was lying on the roof of the third ventricle was aspirated, setting the ventricle completely free. Other clots were aspirated from the right foramen of Monro and from the optic recess.

CONCLUSION: We describe this novel technique, which represents a safe and efficient way to clear the surgical field at the end of posterior fossa surgery in the prone position. The unusual endoscopic visual perspective and instrument maneuvers are easily handled with proper neuroendoscopic training.

KEY WORDS: Aspiration, Blood clots, Neuroendoscopy, Posterior fossa, Prone position, Suboccipital

Operative Neurosurgery 0:1–6, 2018

DOI: 10.1093/ons/opy324

The advantages of the sitting position to approach the posterior fossa, the pineal region, and the superior cervical canal are well known. The optimal biomechanical condition of intracranial compartments allows a clean operative field, good anatomic orientation, and wider operative spaces obtained by gravitational downward displacement of the cerebellar

hemisphere. Nevertheless, many neurosurgeons are concerned about the increased risk of venous air embolism, especially in the presence of a patent foramen ovale (PFO). In these cases, some authors advocate PFO closure before surgery in the sitting position, while others prefer to perform surgery in the prone position. However, in the prone position the venous drainage from the vertebral venous plexus to vena cava is not as efficient as in the sitting position, due to the lack of the driving force exerted by gravity. This can produce an excessive venous intraoperative bleeding with decreased surgical visibility, and blood clots can wedge into the cerebral

ABBREVIATIONS: CSF, cerebrospinal fluid; ETV, endoscopic third ventriculostomy; IVH, intraventricular hemorrhage; MRI, magnetic resonance imaging; PFO, patent foramen ovale

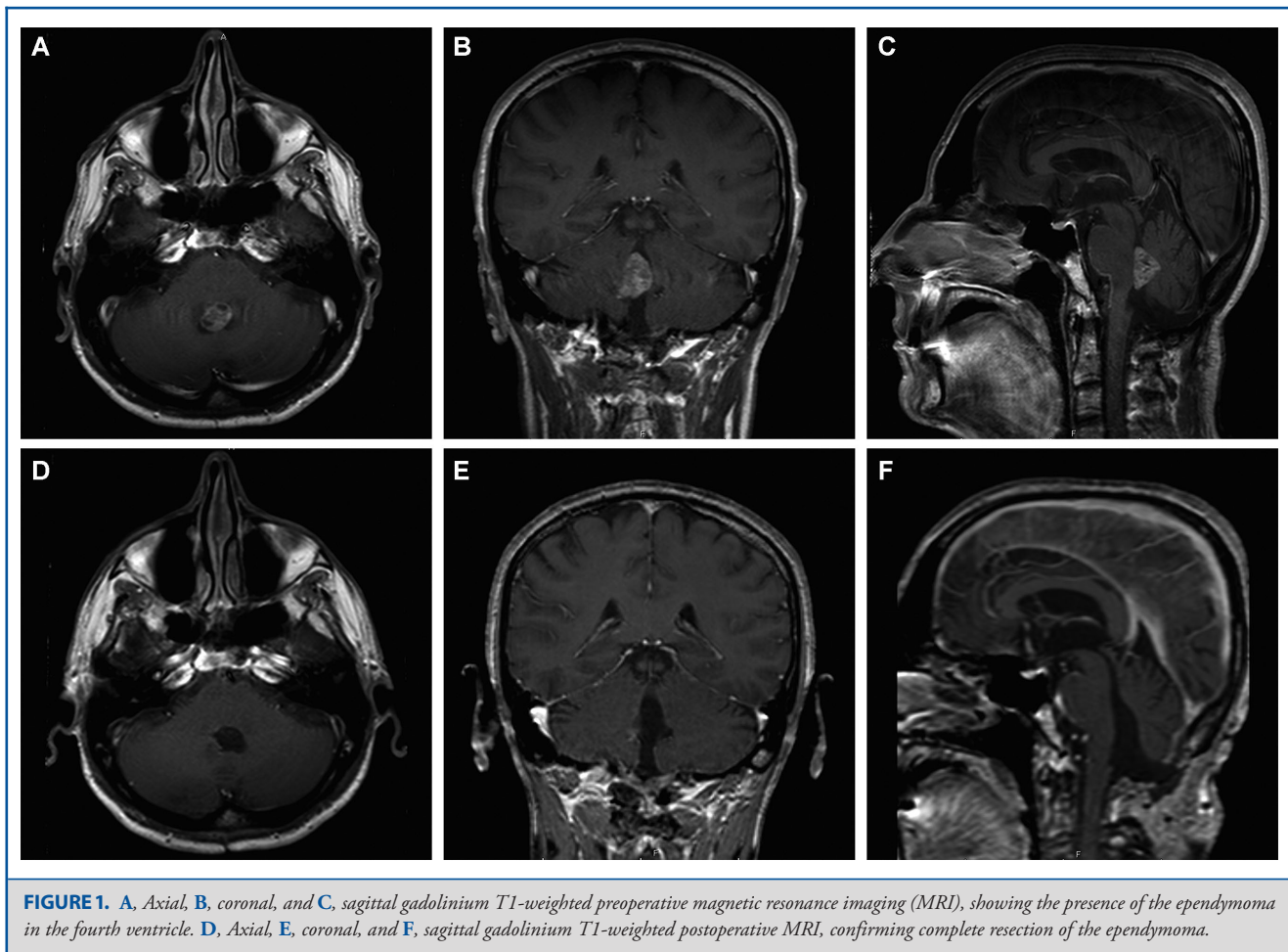


FIGURE 1. A, Axial, B, coronal, and C, sagittal gadolinium T1-weighted preoperative magnetic resonance imaging (MRI), showing the presence of the ependymoma in the fourth ventricle. D, Axial, E, coronal, and F, sagittal gadolinium T1-weighted postoperative MRI, confirming complete resection of the ependymoma.

aqueduct causing obstructive hydrocephalus during the postoperative course. We report on the use of the flexible neuroendoscope to explore and clear blood clots from the cerebral aqueduct and the third ventricle after the resection of an ependymoma of the fourth ventricle in the prone position.

METHODS

Case Report and Operative Technique

A 54-yr-old man presented to our clinic with a 4-mo history of loss of memory, headache, and diplopia particularly in the right gaze. Seven years earlier, he underwent surgery for the resection of an ependymoma (grade I, WHO) of the fourth ventricle. Since then, he had been complaining of mild dysphagia and dysphonia. A magnetic resonance imaging (MRI) showed the presence of a lesion in the fourth ventricle, possibly a recurrence of the ependymoma, with extension at the foramen of Magendie and partially at the right foramen of Luschka, with hyperintense fluid-attenuated inversion-recovery signals, inhomogeneous hyperintense T2 signals, and strong enhancement after gadolinium administration (Figure 1). Hydrocephalus was ruled out. The patient was therefore scheduled for surgery. As preoperative transcranial Doppler

echography detected right-to-left shunt due to PFO, surgery was planned in the prone position. A midline suboccipital craniectomy was performed, and the fourth ventricle was entered from the Magendie foramen with minimal vermis split. The tumor appeared to be crumbling and bleeding, and was completely resected. When hemostasis was completed, as the tumor was particularly bloody, we decided to introduce a flexible scope with a freehand technique into the fourth ventricle to explore the ventricular system and eventually clear it from blood clots. We used the 34-cm Neurofiberscope (Karl Storz GmbH & Co, Tuttlingen, Germany; external diameter 3.7 mm, operative channel diameter 1.5 mm), connected to an Image 1 H3-Z-FI Spies camera (Karl Storz GmbH & Co; model TH100). A Xenon 300 cold light fountain was used as light source. The images were projected on a Monitor HD 26" (Karl Storz GmbH & Co; Model 9826NB/9826NB-US). We inserted the scope through the opened roof of the fourth ventricle and navigated the scope from the inferior to the superior triangle. The surgeon's position is exactly behind the patient's head. Therefore, when inserting the scope through the roof of the fourth ventricle, the posterior structures (cerebellum, posterior commissure) will be at the bottom of the screen, and anterior structures (the floor of the fourth ventricle) will be at the top of the screen. The anatomic landmarks, including the median sulcus, the median eminence, the facial colliculi, the superior *velum medullare*, and the superior cerebellar peduncles, allowed us to

proceed to the caudal egress of the cerebral aqueduct. The scope was easily inserted through the aqueduct, where the second constriction, the ampulla, and the first constriction were clearly seen. Entering the third ventricle through the aditus ad aqueductum cerebri (or aditus aqueducti, or adytum of the aqueduct), we could appreciate its anatomy from a novel point of view, having a direct and complete vision of the anterior two-thirds of the ventricle. After passing the adytum of the cerebral aqueduct, the roof of the third ventricle appears in front of the tip of the endoscope. At this stage, it is necessary to slightly bend the tip of the scope upward in order to explore the anterior third of the third ventricle. In this way, the floor of the third ventricle will appear at the top of the screen. A large blood clot that was lying on the roof of the third ventricle was aspirated with a syringe using the working channel of the scope as a sucker, setting the ventricle completely free. Other clots were aspirated from the right foramen of Monro and from the optic recess. Finally, the normal anatomic structures were identifiable: the optic chiasm, the optic recess, the lamina terminalis, the whitish and bright anterior commissure, the foramina of Monro, the anterior part of the roof of the third ventricle with the choroid plexus (Figure 2). The scope was then carefully withdrawn without any ependymal damage. The main limitation during the procedure is of course the cerebral aqueduct. However, similarly to the explorations of the fourth ventricle through a frontal precoronal burr hole, the flexible scope slowly slides along the structures without exerting significant pressure against them, as it can assume an italic S shape. Nevertheless, it is very important for the surgeon to retrace exactly the same path used to enter the third ventricle when withdrawing the endoscope. The postoperative computed tomography scan showed the absence of blood in the third and fourth ventricles and in the cerebral aqueduct. The postoperative course was uneventful.

An MRI performed 1 mo after surgery confirmed the complete resection of the ependymoma and the normal ventricular system diameters (Figure 1). Consent was obtained from the patient for publication. Ethics committee approval was not required because there is no information in the manuscript that unveils the identity of the patient.

DISCUSSION

When performing surgery in the posterior fossa, many neurosurgeons favor the prone position instead of the sitting position, mainly because of the claimed increased risk of venous air embolism and severe hemodynamic adverse events in the sitting position. Although safer from the anesthesiological point of view, the prone position has some drawbacks compared to the sitting position. Ventilation is more difficult in the prone position, and there is a constant need for continuous aspiration of blood and other fluids, which tend to fill the surgical cavity because of gravity. This can prevent optimal vision of anatomic structures, especially of the brainstem and the floor of the fourth ventricle. Moreover, especially in those cases when the tumor is particularly vascularized, blood and surgical debris can flow through the fourth ventricle into the cerebral aqueduct and eventually into the third ventricle, dropping onto the roof of the third ventricle driven by gravity force. In the postoperative period, the presence of blood clots and debris in the ventricular system can be threatening. Actually, due to the movement of the patient to the supine or semisitting position, they can potentially move to the floor of

the third ventricle and wedge into the adytum of the cerebral aqueduct, obstructing the cerebrospinal fluid (CSF) flow and causing acute hydrocephalus. This event has also been proposed as one of the mechanisms that can reduce the long-term success rate of preoperative endoscopic third ventriculostomy (ETV) in patients who subsequently undergo posterior fossa surgery in the prone position.¹ Interestingly, there is an association between the prone position and a lower success rate of preoperative ETV.² Conversely, other studies showing higher success rate of ETV report on the use of the sitting position in their series.^{3,4}

In such cases, we think neuroendoscopy can be of great value to aspirate blood clots and surgical debris from the ventricular system, therefore reducing the risk of postoperative obstruction of the CSF pathways. Several authors proposed and performed the exploration of the fourth ventricle moving the scope from a suboccipital craniectomy and through the foramen of Magendie in order to achieve aqueductoplasty in patients with triventricular hydrocephalus due to aqueductal stenosis.⁵⁻¹⁰ All the published studies report on the use of rigid endoscope to this purpose, and claim the procedure to be safe.

Austerman et al¹¹ recently published an interesting technical note describing the use of a rigid endoscope with an adjustable angle to assist the resection of fourth ventricular tumor through a telovelar incision. In their experience, the endoscope provided visualization of the roof and rostral portion of the ventricle, otherwise difficult to visualize with the microscope alone. A suction device could be inserted to remove any residual tumor. In this way, the degree of telovelar dissection and vermis splitting was minimized. Moreover, it was possible to directly check the patency of the cerebral aqueduct.

However, although a rigid endoscope is effective to explore the caudal portion of the aqueduct from a fourth ventricular access, it is not suitable to actually navigate its narrow and slightly curved lumen to explore the third ventricle. The use of a flexible scope is the only way to safely navigate the cerebral aqueduct in order to obtain a complete exploration of both the fourth and the third ventricles, which is advisable to effectively clear the ventricular system from blood clots and debris. Several studies already proved the navigation of the cerebral aqueduct with a flexible scope to be safe, when performed by experienced neuroendoscopists.¹²⁻²² Of course, good expertise with handling a flexible scope is mandatory before navigating it through the cerebral aqueduct. After the appropriate learning curve performing other kind of endoscopic procedures, the passage of the scope through a nonstenotic aqueduct is harmless, as long as the movements are cautious and the bending of the instrument is respectful of the anatomic irregular shape of the ventricular system, both when inserting and withdrawing it. The aspiration of intraventricular hemorrhages (IVH) with a flexible scope through a frontal precoronal burr hole has been already published, and we also normally perform this kind of procedure in cases of hemocephalus totalis.^{18,23-26} However, to the best of our knowledge, no one has published the aspiration of blood clots during posterior fossa surgery entering the ventricular system from the fourth ventricle and advancing the

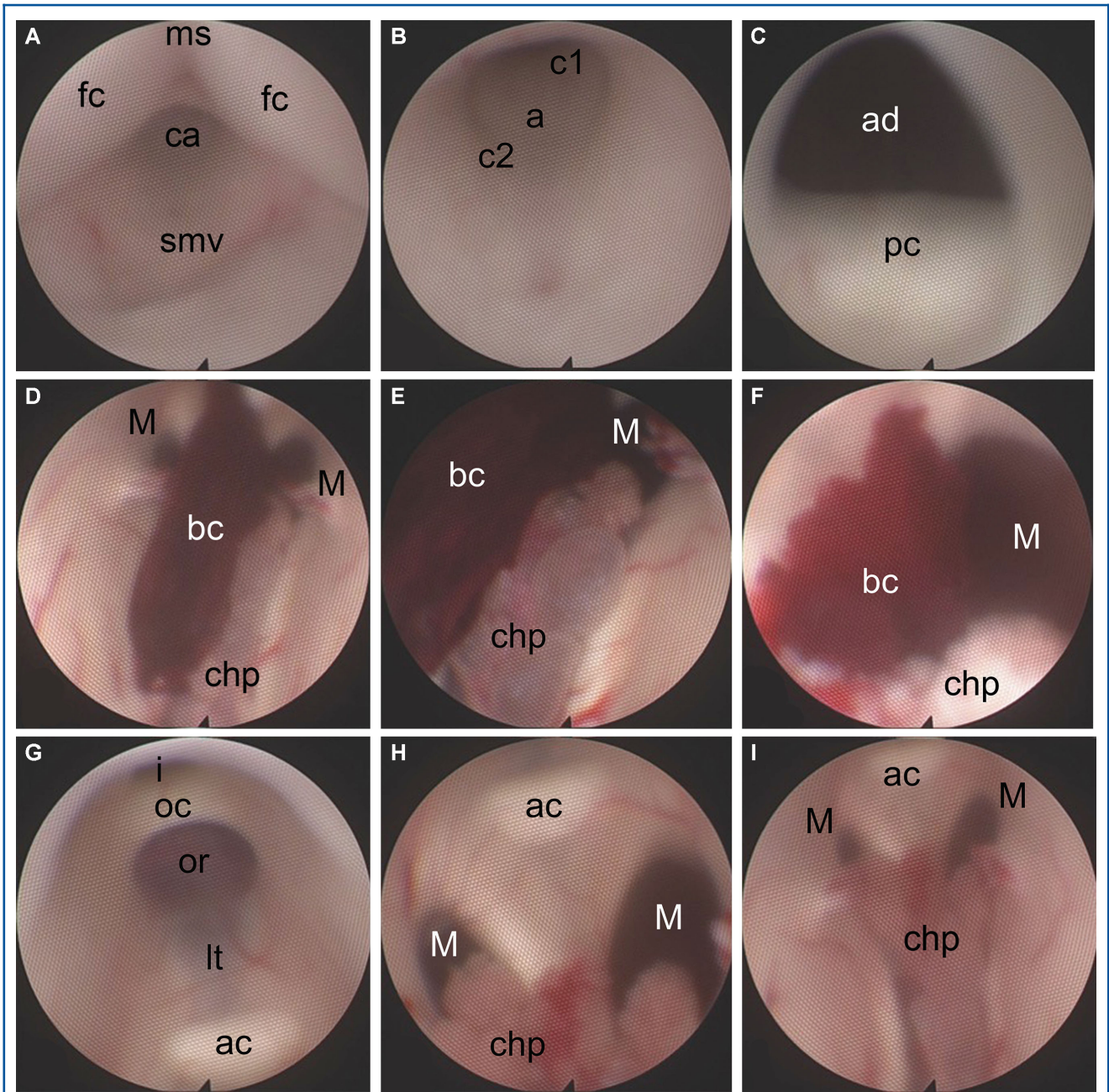


FIGURE 2. Endoscopic views at the end of ependymoma resection, using a flexible scope introduced through the surgical field. **A**, The endoscope is first directed toward the superior triangle of the fourth ventricle, and then advanced into the cerebral aqueduct. **B**, The second constriction, the ampulla, and the first constriction of the cerebral aqueduct are seen. **C**, The triangular shape of the adytum of the cerebral aqueduct indicates the access to the third ventricle. **D**, A large blood clot is noticed nestling on the roof of the third ventricle. **E**, A closer inspection allows understanding the relation of the blood clot with the underlying choroid plexus, before aspirating the clot. **F**, Another blood clot is found and aspirated at the right Monro foramen. **G-I**, The final inspection of the anterior and middle parts of the third ventricle confirms the absence of blood clots, and allows the identification of optic chiasm, optic recess, lamina terminalis, anterior commissure, Monro foramina, and choroid plexus. smv: superior medullary velum; ms: median sulcus; fc: facial colliculus; ca: cerebral aqueduct; c1: first constriction; a: ampulla; c2: second constriction; ad: aditus ad aqueductum cerebri; pc: posterior commissure; bc: blood clot; chp: choroid plexus; M: Monro foramen; ac: anterior commissure; lt: lamina terminalis; or: optic recess; oc: optic chiasm; i: infundibulum.

scope upward into the cerebral aqueduct and the third ventricle. We applied this “retrograde” technique inserting the scope from the fourth ventricle in 2 patients operated for the removal of posterior fossa tumors. Unfortunately, the video recordings of the second patient have been missed. Although we are more familiar with a craniocaudal trajectory, in both cases the navigation from the fourth to the third ventricle was not a challenging maneuver. We were able to explore the lumen of the cerebral aqueduct and the third ventricle, aspirating some blood clots that were floating in the CSF.

Other strategies may be used to prevent postoperative IVH and hydrocephalus. Surgical cottonoids can be placed at the proximal portion of the IV ventricle to block the egress of the cerebral aqueduct and avoid blood to flow into the third ventricle. We routinely use this method. However, in some cases when the fourth ventricle is completely occupied by the tumor it is not possible to reach and block the egress of the aqueduct at an early stage. Therefore, some blood might leak into the third ventricle during tumor removal before the surgeon can place a cottonoid at the superior triangle of the fourth ventricle. Microscopic inspection of the IV ventricle at the end of tumor removal is commonly performed to inspect the surgical field and rule out the presence of blood clots even in the cerebral aqueduct. However, a complete inspection of the third ventricle is not achievable, and the possibilities to eventually remove blood clots from the third ventricle are limited. Although preoperative external ventricular drainage can be placed when ventricles are dilated, it is a questionable procedure when hydrocephalus is not present, as in our patient, and in any case it does not prevent blood to flow from the fourth into the third ventricle.

It is worth giving a short description of the endoscopic anatomy of the superoanterior part of the third ventricle, which is not possible to appreciate with a transfrontal trans-Monro approach. After passing the adytum of the cerebral aqueduct and entering the third ventricle, it was possible to clearly see the roof of the third ventricle and its choroid plexus, partially covered by a blood clot that was aspirated. Following these structures from a posteroanterior direction, both the foramina of Monro were identified. Just anterior to the Monro foramina, the bright, whitish strip of the anterior commissure was very clear. To the best of our knowledge, this is the second in vivo endoscopic description of the anterior commissure with a complete view, after that provided by Nishiyama et al,²⁷ who visualized it during an endoscopic cystoventriculostomy of a parasellar arachnoid cyst into the third ventricle using a steerable scope. The lamina terminalis as well as the optic chiasm and the optic recess were also evident.

CONCLUSION

After completing tumor removal in the posterior fossa in the prone position, neurosurgeons should be aware of the possibility that blood clots and surgical debris could be forced by gravity into the cerebral aqueduct and the third ventricle. In the postoperative

period, the clots could potentially obstruct the CSF pathways causing acute hydrocephalus. The use of a flexible scope from a suboccipital approach is safe when performed by experienced neurosurgeons and allows direct and almost complete exploration of the aqueduct, the fourth and the third ventricles, with the possibility to aspirate debris and blood clots, therefore reducing the risk of postoperative complications.

Disclosure

The authors have no personal, financial, or institutional interest in any of the drugs, materials, or devices described in this article.

REFERENCES

1. Tamburrini G, Frassanito P, Bianchi F, Massimi L, Di Rocco C, Caldarelli M. Closure of endoscopic third ventriculostomy after surgery for posterior cranial fossa tumor: the “snow globe effect”. *Br J Neurosurg.* 2015;29(3):386-389.
2. Sainte-Rose C, Cinalli G, Roux FE, et al. Management of hydrocephalus in pediatric patients with posterior fossa tumors: the role of endoscopic third ventriculostomy. *J Neurosurg.* 2001;95 (5):791-797.
3. El Beltagy MA, Kamal HM, Taha H, Awad M, El Khateeb N. Endoscopic third ventriculostomy before tumor surgery in children with posterior fossa tumors, CCHE experience. *Childs Nerv Syst.* 2010;26 (12):1699-1704.
4. Ruggiero C, Cinalli G, Spennato P, et al. Endoscopic third ventriculostomy in the treatment of hydrocephalus in posterior fossa tumors in children. *Childs Nerv Syst.* 2004;20 (11-12):828-833.
5. Cinalli G, Spennato P, Savarese L, et al. Endoscopic aqueductoplasty and placement of a stent in the cerebral aqueduct in the management of isolated fourth ventricle in children. *J Neurosurg.* 2006;104(1 suppl):21-27.
6. da Silva LR, Cavalheiro S, Zymberg ST. Endoscopic aqueductoplasty in the treatment of aqueductal stenosis. *Childs Nerv Syst.* 2007;23(11):1263-1268.
7. Ferrer E, de Notaris M. Third ventriculostomy and fourth ventricle outlets obstruction. *World Neurosurg.* 2013;79(2 suppl):S20.e9-e13.
8. Raouf A, Zidan I. Suboccipital endoscopic management of the entrapped fourth ventricle: technical note. *Acta Neurochir.* 2013;155(10):1957-1963.
9. Sansone JM, Iskandar BJ. Endoscopic cerebral aqueductoplasty: a trans-fourth ventricle approach. *J Neurosurg.* 2005;103(5 suppl):388-392.
10. Toyota S, Taki T, Oshino S, et al. A neuroendoscopic approach to the aqueduct via the fourth ventricle combined with suboccipital craniectomy. *Minim Invasive Neurosurg.* 2004;47(5):312-315.
11. Austerman R, Lucas J, Kammen A, Zada G. Endoscopic-assisted median aperture approach for resection of fourth ventricular tumor and confirmation of patency of cerebral aqueduct using an adjustable-angle endoscope: technical case report. *Oper Neurosurg.* 2017;13(2):293-296.
12. Feletti A, Alicandri-Ciuffelli M, Pavesi G. Transaqueductal trans-Magendie fenestration of arachnoid cyst in the posterior fossa. *Acta Neurochir.* 2016;158(4):655-662.
13. Feletti A, Marton E, Fiorindi A, Longatti P. Neuroendoscopic aspiration of tumors in the posterior third ventricle and aqueduct lumen: a technical update. *Acta Neurochir.* 2013;155(8):1467-1473.
14. Hamada H, Hayashi N, Kurimoto M, et al. Neuroendoscopic removal of intraventricular hemorrhage combined with hydrocephalus. *Minim Invasive Neurosurg.* 2008;51(06):345-349.
15. Longatti P, Basaldella L, Feletti A, Fiorindi A, Billeci D. Endoscopic navigation of the fourth ventricle. *Neurosurg Focus.* 2005;19(6):1-4.
16. Longatti P, Fiorindi A, Feletti A, Baratto V. Endoscopic opening of the foramen of Magendie using transaqueductal navigation for membrane obstruction of the fourth ventricle outlets. *J Neurosurg.* 2006;105(6):924-927.
17. Longatti P, Fiorindi A, Feletti A, d’Avella D, Martinuzzi A. Endoscopic anatomy of the fourth ventricle. *J Neurosurg.* 2008;109 (3):530-535.
18. Longatti P, Fiorindi A, Martinuzzi A. Neuroendoscopic aspiration of hematocephalus totalis: technical note. *Neurosurgery.* 2005;57(4 Suppl):E409.
19. Longatti P, Fiorindi A, Martinuzzi A, Feletti A. Primary obstruction of the fourth ventricle outlets: neuroendoscopic approach and anatomic description. *Neurosurgery.* 2009;65 (6):1078-1086.

20. Longatti P, Fiorindi A, Perin A, Martinuzzi A. Endoscopic anatomy of the cerebral aqueduct. *Neurosurgery*. 2007;61(3 suppl):1-5.
21. Torres-Corzo JG, Rangel-Castilla L, Islas-Aguilar MA, Vecchia RR. A novel approach of navigation-assisted flexible neuroendoscopy. *Oper Neurosurg*. published online ahead of print: May 18, 2017 (doi: 10.1093/ons/oxx118)..
22. Torres-Corzo J, Sánchez-Rodríguez J, Cervantes D, et al. Endoscopic transventricular transaqueductal Magendie and Luschka foraminoplasty for hydrocephalus. *Neurosurgery*. 2014;74 (4):426-436.
23. Basaldella L, Marton E, Fiorindi A, Scarpa B, Badreddine H, Longatti P. External ventricular drainage alone versus endoscopic surgery for severe intraventricular hemorrhage: a comparative retrospective analysis on outcome and shunt dependency. *Neurosurg Focus*. 2012;32(4):E4.
24. Longatti P, Basaldella L. Endoscopic management of intracerebral hemorrhage. *World Neurosurg*. 2013;79(2 suppl):S17.e1-e7.
25. Nishikawa T, Takehira N, Matsumoto A, Kanemoto M, Kang Y, Waga S. Delayed endoscopic intraventricular hemorrhage (IVH) removal and endoscopic third ventriculostomy may not prevent consecutive communicating hydrocephalus if IVH removal was insufficient. *Minim Invasive Neurosurg*. 2007;50(4): 209-211.
26. Toyooka T, Kageyama H, Tsuzuki N, Ishihara S, Oka K. Flexible endoscopic aspiration for intraventricular casting hematoma. *Acta Neurochir Suppl*. 2016;123:17-23.
27. Nishiyama K, Mori H, Yoshimura J, Fujii Y. Endoscopic fenestration of the third ventricle in the reverse direction. *Childs Nerv Syst*. 2008;24(4):507-508.