

Endoscopic Approach to Putaminal Bleed

Abstract

Objective: To highlight the basic points of brain endoscopic procedure for Putaminal Bleed to achieve repeatability and reproducibility in the results among the new brain endoscopic surgeons.

Method: Sharing the experience of 10 years as an endoscopic surgeon to bring out the basic insight into the method, challenges, points which need special attention during the surgery and discussion of recent advancements in the endoscopic equipment for safe surgery. **Conclusion:** Procedure of endoscopic evacuation of brain hematoma is simple with learning curve. In the beginning new endoscopic surgeons should operate in the presence of experience surgeon. They should follow standard technique to achieve the good surgical outcome and uniformity in the result every time they perform the surgery.

Keywords: Cerebral hemorrhage, Neuroendoscope, Putamen

Basic points have been discussed in the article for the Endoscopic Evacuation of Putaminal Bleed.

Key points discussed:

- Three-dimensional visualization of procedure before the surgery
- Coagulation of even small vessels
- Waiting for the softening of hematoma for easy evacuation
- Decision regarding the position of the burr hole – Degree of entry to the hematoma is more important than the closeness to the surface.

Introduction

Endoscopic evacuation of hematoma was started appearing in the major journals around 2000, gradually widened. In 2014, doctors started operating under medical insurance in Japan. Procedure is simple, but there is a learning curve. Beginners learn from the seniors, and everyone has some own methods, so there is no repeatability and reproducibility. The aim of this article is to highlight the basic points of the endoscopic evacuation of the putaminal hemorrhage to achieve repeatability and reproducibility among the different new endoscopic surgeons.

Preprocedure Preparations

1. Instruments: Translucent sheath^[1] (5–10 mm), suction tube nontapered

This is an open access journal, and articles are distributed under the terms of the Creative Commons Attribution-NonCommercial-ShareAlike 4.0 License, which allows others to remix, tweak, and build upon the work non-commercially, as long as appropriate credit is given and the new creations are licensed under the identical terms.

For reprints contact: reprints@medknow.com

(2–4 mm), rigid endoscope (2.7 mm), and flexible endoscope [Figure 1]

2. Hematoma evacuation: After making the burr hole, durotomy is done. Translucent sheath is inserted. Endoscope and suction tube are inserted through the port. Evacuation of hematoma is started from the margin. Tip of suction tube should not be taken far from sheath
3. Hemostasis: Coagulation of the bleeding vessel can be done by monopolar through the suction tube. The author prefers artificial cerebrospinal fluid (CSF) (Artificial CSF)^R for the irrigation of the hematoma cavity, but Ringer lactate (RL) (warm) can also be used. Four packs (2000 ml) of ARTCERIB/RL should be kept reserved for the procedure.

Trephination and Puncture

There are different ways adopted by the different doctors for making flaps, burr hole, and puncture. Any of the methods is acceptable. Some prefers stereotactic drainage of the hematoma and some prefers evacuation by craniotomy. In many cases, microscopic arteriovenous malformations are associated with the putaminal hemorrhage, so there is a need to change from endoscopic to microscopic procedure. For an endoscopic surgeon, his endoscope, like microscope, uses sheath as brain spatula and keyhole as craniotomy. Burr hole needs to be close to the

Daisuke Suyama,
Brajesh Kumar¹,
Saiko Watanabe²,
Riki Tanaka²,
Yasuhiro Yamada²,
Tsukasa Kawase²,
Yoko Kato²

Department of Neurosurgery,
Fuchu Keijinkai Hospital,
Tokyo, ²Department of
Neurosurgery, Banbuntane
Hotokukai Hospital, Fujita
University, Nagoya, Japan,
¹Department of Neurosurgery,
Ruban Hospital Patliputra,
Patna, Bihar, India

Address for correspondence:

Dr. Brajesh Kumar,
House No-15, Gokul Marg,
North SK Puri, Boring Road,
Patna - 800 013, Bihar, India.
E-mail: drbrajesh78@gmail.com

Video Available on:
www.asianjns.org

Access this article online

Website: www.asianjns.org

DOI: 10.4103/ajns.AJNS_215_17

Quick Response Code:



How to cite this article: Suyama D, Kumar B, Watanabe S, Tanaka R, Yamada Y, Kawase T, et al. Endoscopic approach to putaminal bleed. Asian J Neurosurg 2019;14:63-6.

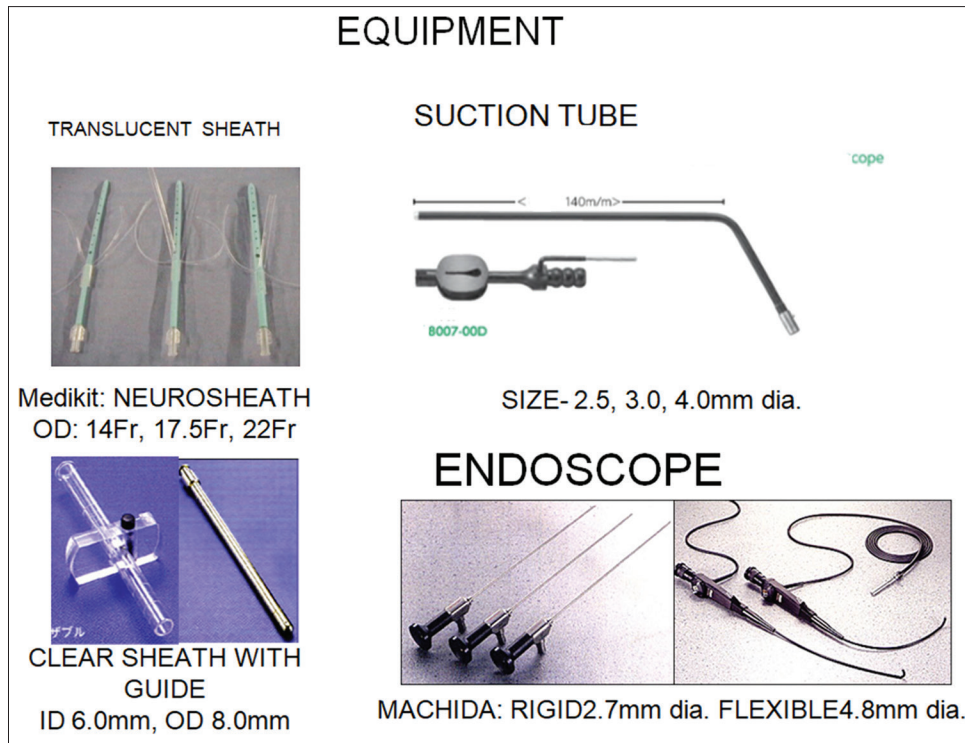


Figure 1: Instruments used

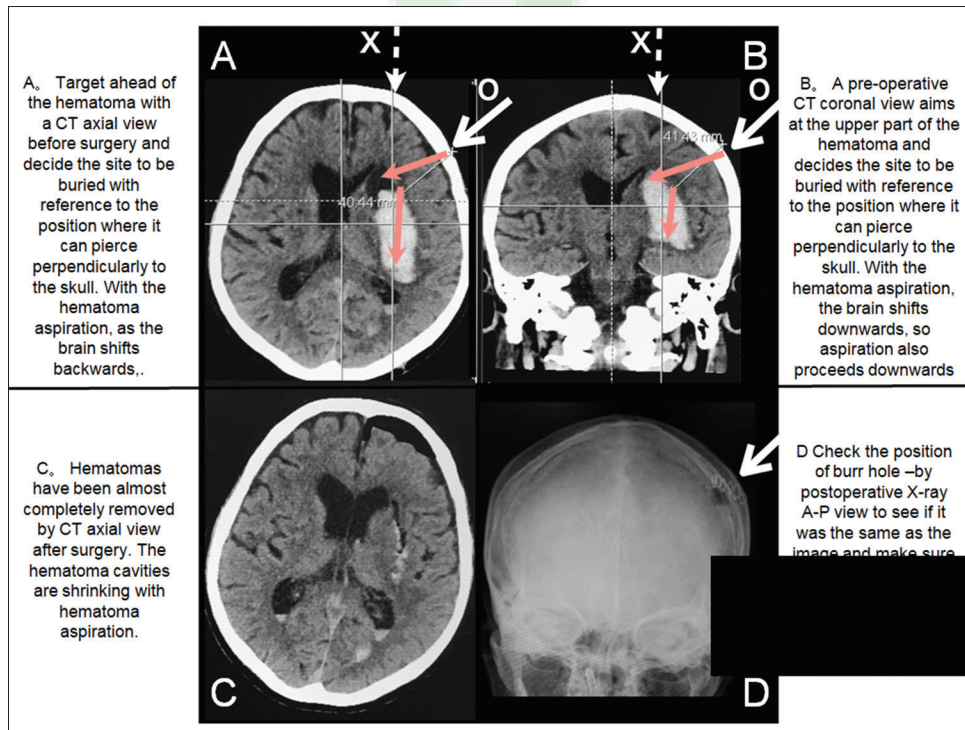


Figure 2: Computed tomography images - how to target

hematoma and direction of puncture should be vertical to the skull as it is easy to manipulate the sheath in this trajectory. Position of burr hole should be posterolateral to the burr hole for the frontal horn. We can mark the burr-hole point through the coronal image [Figure 2]. It is very important to always keep the image of brain shift after the decompression.

Evacuation of Hematoma

Today, we use translucent sheath, through which we can check margin and evacuate the hematoma, and instruments can be moved like brain spatula as in microscopic surgery. In putaminal hemorrhage, we remove hematoma from

closure part to deeper part. Once sheath is inserted in center of the hematoma, we move sheath toward the margin of hematoma at closure part and we make some working space after some evacuation, then marginal part is evacuated followed by deeper part behind the center and finally deeper margin [Figures 3-5]. After the decompression

After the Decompression of the Hematoma, working space and Hematoma cavity slowly disappears as brain occupies the space. If we lose orientation at this point, we should get back to the margin and check around the hematoma. Sometimes, we can also remove contused brain tissue to get working space. If we encounter red bleeding, it is either

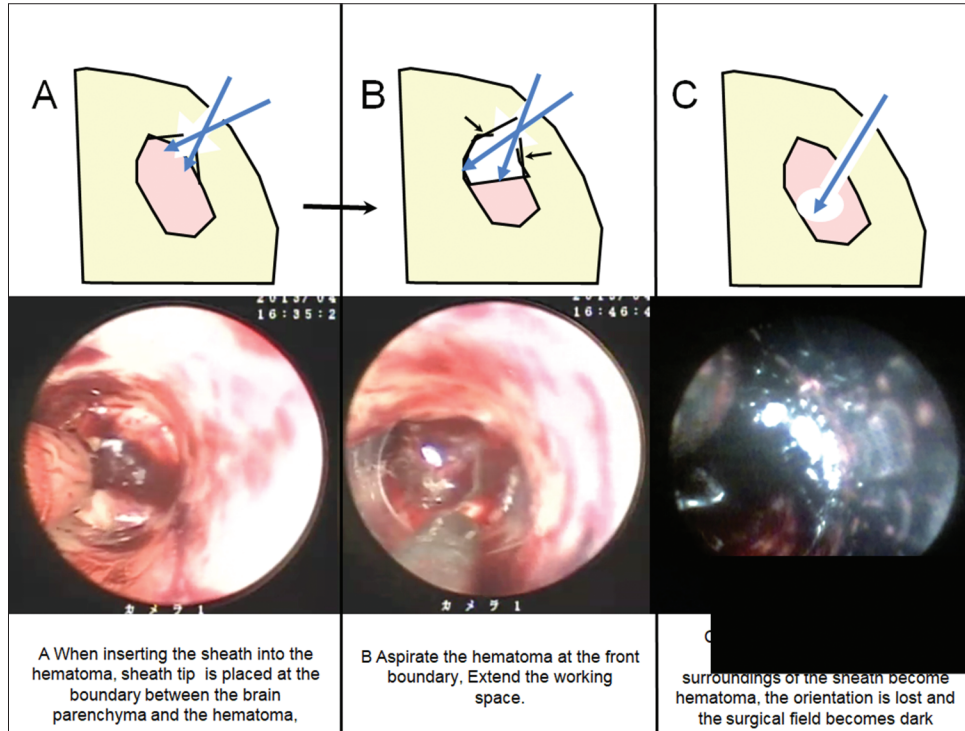


Figure 3: Procedure of hematoma evacuation

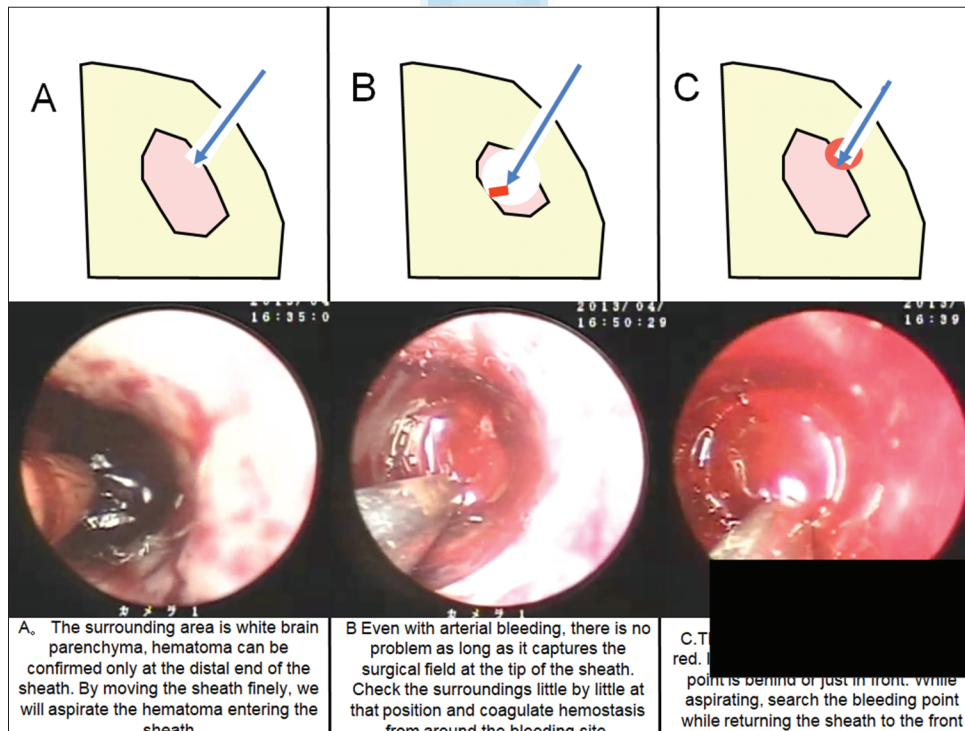


Figure 4: Procedure of hematoma evacuation

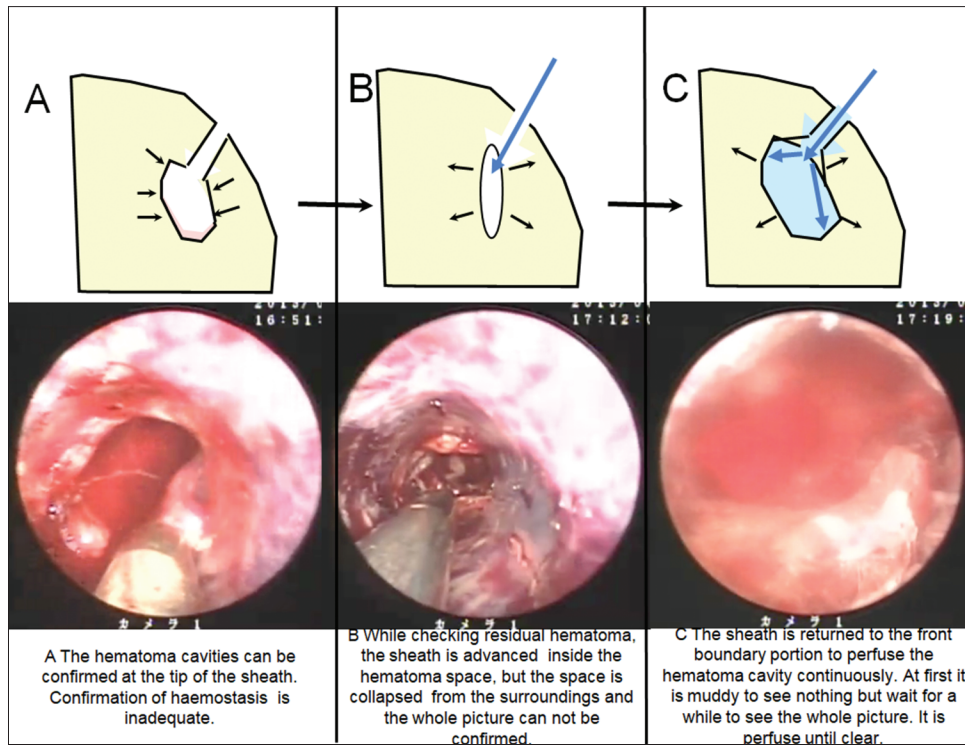


Figure 5: Procedure for hematoma evacuation

from the surface or tract and it needs to get coagulated [Video].

Hemostasis

We should do hemostasis all the time. Fresh bleeding is red in color and hematoma is dark red, so we can easily differentiate them during the surgery and should be coagulated as soon as we find them. If we find arterial bleeding but do not have the working space, we should first make working space using the large bore suction cannula and then should search for the bleeding. We can put suction tube over the bleeding point and do the electrocoagulation by monopolar placed over the suction cannula in wet condition over many times (4–5 times) with low voltage. We should be careful for the suction injury to the large vessels as it difficult to control bleeding. If there is minor oozing irrigation with artificial CSF/RL is sufficient. Even after this oozing continues, then we can do pressure control with cotton.

Irrigation of Hematoma Cavity

When there is no bleeding, we irrigate the hematoma cavity with the artificial CSF/RL. We can put 5F angiographic catheter or flexible endoscope for the irrigation of the hematoma cavity. Widening of hematoma cavity with irrigation is important as it stops oozing.

Conclusion

It is important with endoscopic approach to learn how to cope with hard hematoma. We should observe and wait for the softening of the hematoma. We should not chase too far for complete clearance of the hematoma. Getting disoriented is another problem in endoscopic surgery. In this situation, we should again go back to the margin or proximally come deeper again. Brain shift should always be kept in mind. If we feel bleeding is troublesome, it is not wise to lose valuable time to control bleeding, and there should be no hesitation in switching over to microscopic procedure. Before one gets enough experience, we should operate with the experienced surgeon. If it is not possible to have an expert, a beginner should start with small craniotomy rather than burr hole.

Financial support and sponsorship

Nil.

Conflicts of interest

There are no conflicts of interest.

Reference

1. Nishihara T, Teraoka A, Morita A, Ueki K, Takai K, Kirino T, *et al.* A transparent sheath for endoscopic surgery and its application in surgical evacuation of spontaneous intracerebral hematomas. Technical note. *J Neurosurg* 2000;92:1053-5.