

Redo Microvascular Decompression in a Patient of Resistant Cochleovestibular Nerve Compression Syndrome

Abstract

Cochlea-vestibular nerve compression syndrome (CVCS) may present as recurrent attacks of vertigo, dizziness, imbalance, etc. Those patients who do not respond to medical management, are usually managed by “microvascular decompression (MVD) of cochlea-vestibular nerve.” The success rate of MVD is not 100% and few patients present with the recurrence of symptoms. We are reporting management of one such resistant case of CVCS. A 40-year-old female patient who was a known case of CVCS, was managed by medical and surgical (MVD) management. She had no relief of symptoms. We did redo MVD of cochlea-vestibular nerve after full evaluation of symptomatology. Patient had complete relief in her symptoms. In failed MVD cases, redo MVD can be performed if patient is still having e/o nerve compression, adhesions on magnetic resonance imaging.

Keywords: Anterior inferior cerebellar artery, cochlea-vestibular nerve compression syndrome, microvascular decompression, Teflon, vertigo

Introduction

Cochlea-vestibular nerve compression syndrome (CNCS) may be caused by compression of cochleo-vestibular nerve from arterial loop, most commonly anterior inferior cerebellar artery (AICA) or mass lesion.^[1] It is characterized by variety of symptoms, for example, repeated attacks of vertigo, tinnitus, hearing loss, and balance difficulty.^[2,3] Medical treatment is used as first-line management, but few patients do not respond. Few studies have reported the use of microvascular decompression (MVD) of 8th nerve in treatment of these resistant cases with encouraging results.^[4-6] There may be some cases who fail with initial surgical treatment. It is unclear if there can be a role of redo MVD in such cases. We are reporting about a female patient who had recurrent CNCS after initial MVD of the 8th nerve and she responded after redo MVD.

Clinical Presentation

A 40-year-old female patient had history of attacks of vertigo on changing position of head for the past 12 years. The onset was insidious and sometimes it was associated with vomiting. There was no relief after vomiting or lying down. She first consulted

ENT specialist and was diagnosed as a case of “Meniere’s Disease.” She underwent two procedures, first was injection Gentamycin in the left ear, 3 years back and there was no relief. Later on, she underwent right endolymphatic sac fenestration, still there was no relief. She was referred to neurosurgeon who diagnosed her as a case of “CNCS.” She underwent MVD of the right 7th–8th nerve. Teflon patch graft was used to separate AICA and 7th–8th nerve complex. The records of the patient also revealed that she underwent vestibular neurectomy simultaneously. She developed right side hearing loss in the postoperative period. Initially, she improved for 9 months; however, symptoms recurred in the form of episodes of vertigo, refractory to medical management (tablet β -histine 64 mg and tablet cinnarizine 120 mg daily)

On examination, she had 30%–40% sensory loss in territory of the right V1, V2, and V3 nerve and complete sensorineural deafness on same side. There was no other neurological deficit.

Radiology

Constructive interference in steady-state of magnetic resonance imaging (MRI) brain showed loop of AICA compressing right 7th–8th nerve complex with a

**Ishu Bishnoi,
Tushit Mewada,
Daljit Singh,
Hukum Singh**

*Department of Neurosurgery,
G B Pant Institute of
Postgraduate Medical Education
and Research Institute,
New Delhi, India*

Address for correspondence:

*Dr. Ishu Bishnoi,
B-48, First Floor,
New Rajinder Nagar,
New Delhi - 110 060, India.
E-mail: ishubishnoi@gmail.com*

Access this article online

Website: www.asianjns.org

DOI: 10.4103/ajns.AJNS_48_15

Quick Response Code:



How to cite this article: Bishnoi I, Mewada T, Singh D, Singh H. Redo microvascular decompression in a patient of resistant cochleovestibular nerve compression syndrome. *Asian J Neurosurg* 2017;12:735-7.

This is an open access article distributed under the terms of the Creative Commons Attribution-NonCommercial-ShareAlike 3.0 License, which allows others to remix, tweak, and build upon the work non-commercially, as long as the author is credited and the new creations are licensed under the identical terms.

For reprints contact: reprints@medknow.com

lesion (?Teflon graft) in right cerebellopontine angle (CPA) cistern [Figure 1].

Operative technique

Patient underwent surgery, that is, redo MVD of 7th-8th nerve complex, after informed consent. Surgery was performed under general anesthesia using sitting position with due precautions. Previous operative site (retromastoid-retrosigmoid, suboccipital craniectomy) was re-explored. Cerebellum was adhered to Dura. 7th-8th nerve complex along with AICA loop was visualized. Teflon graft was densely adhered to nerve complex and was compressing it [Figure 2]. The Teflon graft was removed using meticulous sharp dissection.

We also observed that the continuity of 7th-8th nerve complex was maintained despite previous record of vestibular neurectomy. However the nerve complex was thinned out, which was cut [Figure 3]. The 7th nerve was seen preserved and carefully dissected out from the adhesions. A new Teflon ring graft (3.5 mm) was used to separate AICA from the 7th to 8th nerve complex [Figure 4]. The trigeminal and lower cranial nerves were identified and preserved.

Patient got relief from repeated attacks of vertigo in immediate postoperative period. She developed right side partial facial weakness (house - Brackmann Grade 2). There was no other focal deficit. Patient was discharged

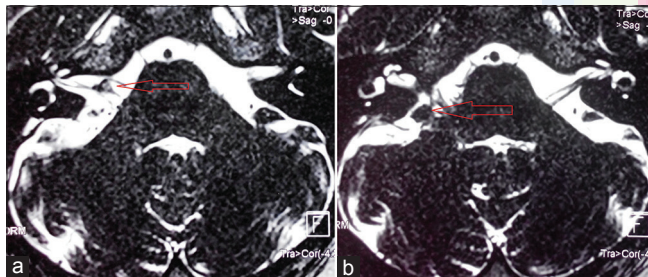


Figure 1: (a) Axial section of T2 constructive interference in steady-state - magnetic resonance imaging showing tri-radiate appearance (red arrow) of clumped anterior inferior cerebellar artery, 7th and 8th nerve in right cerebellopontine angle cistern. (b) Axial section of T2 constructive interference in steady-state - magnetic resonance imaging showing hypodense round lesion (?Teflon graft) (red arrow) adhered to 7th-8th nerve complex

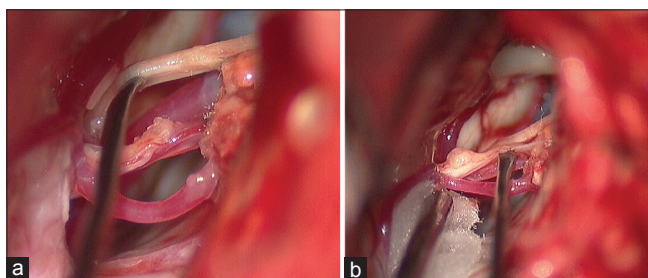


Figure 3: (a) Thinned out 8th nerve with neuroma dissected free from anterior inferior cerebellar artery and 7th nerve. (b) Eighth nerve stump after severance and 7th nerve pushed up. Anterior inferior cerebellar artery loop is free from 7th nerve

after 7 days. She was taught facial exercises. She was followed up after 14 days. Her facial weakness improved to some extent. Patient was relieved from vertigo completely. A follow up after 3 weeks showed complete recovery from vertigo and facial palsy.

Discussion

Patient of CNCS who are resistant to medical treatment, they are treated by MVD.^[4-6] The efficacy of MVD is around 65%-80% as reported by various studies.^[4-7] Few patients who do not respond to MVD, are managed by medical treatment. The results of medical treatment is however unsatisfactory. Such patients can be managed by redo MVD. PTFE or Teflon graft is usually the material of choice for MVD because it is inert, well-tolerated in the nervous system, resistant to resorption, and has a lower complication rate than other materials.^[8] In spite of this safety profile, inflammatory foreign-body reactions, granuloma formation, and fibrosis can occur at the site of implantation. There are very few studies that have reported about treatment of failed cases of MVD in trigeminal neuralgia due to inflammatory granuloma formation, but there is no published study of MVD in vertigo due to CNCS.^[9-13]

The MVD of 7th-8th nerve complex requires special attention when compared with MVD of 5th nerve. The cochlear nerve as a sensory cranial nerve, has longer root entry zone (REZ) when compared with the motor cranial nerves. REZ of the cochlear nerve runs through entire CPA

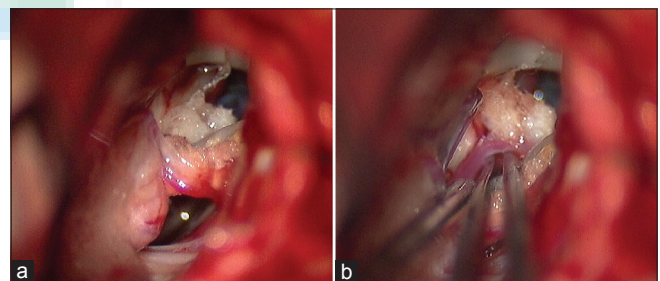


Figure 2: (a) Intra-operative photo depicting white-orange colored previous Teflon graft adhered to 7th-8th nerve complex and anterior inferior cerebellar artery. (b) Teflon graft partially dissected free from anterior inferior cerebellar artery

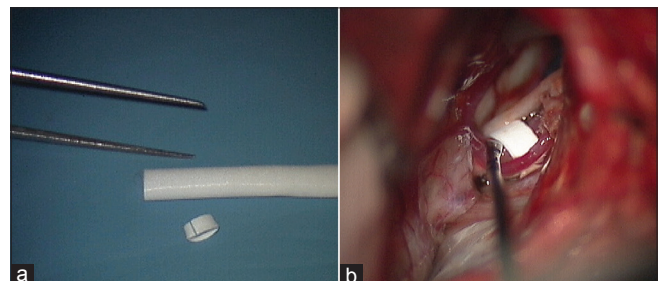


Figure 4: (a) Teflon ring graft 3.5 mm size. (b) Teflon ring graft placed between anterior inferior cerebellar artery and 7th-8th nerve complex to prevent vascular compression

cistern starting from the internal auditory foramina.^[7,14] Therefore, all surrounding blood vessels from the internal auditory foramina to REZ region, should be pushed aside and separated, and all the tissue adhesion should be sharply dissected to get complete relief and prevent recurrence.

Re-do surgery is difficult due to dense adhesions between neurovascular complex. The adhesions should be sharply dissected. Blunt dissection or traction can result into injury of neurovascular complex.

Our shortcoming was no use of electrophysiological monitoring of VII nerve. It could have helped us in preventing facial palsy.

Conclusion

MVD is the best choice for management of resistant CNCS cases. For failed MVD cases, redo MVD can be done if patient is still having e/o nerve compression, adhesions on MRI. However, redo surgery needs great preoperative planning, experience and surgical skills.

Financial support and sponsorship

Nil.

Conflicts of interest

There are no conflicts of interest.

References

1. Schwaber MK, Hall JW. Cochleovestibular nerve compression syndrome. I. Clinical features and audiovestibular findings. *Laryngoscope* 1992;102:1020-9.
2. Markowski J, Gierak T, Kluczevska E, Witkowska M. Assessment of vestibulocochlear organ function in patients meeting radiologic criteria of vascular compression syndrome of vestibulocochlear nerve – Diagnosis of disabling positional vertigo. *Med Sci Monit* 2011;17:CR169-73.
3. Noguchi Y, Ohgaki T, Tsunoda A, Komatsuzaki A, Muraoka H. Clinical study in vertiginous patients suspected of having neurovascular compression syndrome of the eighth cranial nerve. *Nihon Jibiinkoka Gakkai Kaiho* 1997;100:492-8.
4. Møller MB, Møller AR, Jannetta PJ, Jho HD, Sekhar LN. Microvascular decompression of the eighth nerve in patients with disabling positional vertigo: Selection criteria and operative results in 207 patients. *Acta Neurochir (Wien)* 1993;125:75-82.
5. Brackmann DE, Kesser BW, Day JD. Microvascular decompression of the vestibulocochlear nerve for disabling positional vertigo: The House ear clinic experience. *Otol Neurotol* 2001;22:882-7.
6. Okamura T, Kurokawa Y, Ikeda N, Abiko S, Ideguchi M, Watanabe K, *et al.* Microvascular decompression for cochlear symptoms. *J Neurosurg* 2000;93:421-6.
7. De Ridder D, Ryu H, Møller AR, Nowé V, Van de Heyning P, Verlooy J. Functional anatomy of the human cochlear nerve and its role in microvascular decompressions for tinnitus. *Neurosurgery* 2004;54:381-8.
8. Ammar A, Lagenaur C, Jannetta P. Neural tissue compatibility of teflon as an implant material for microvascular decompression. *Neurosurg Rev* 1990;13:299-303.
9. Cho DY, Chang CG, Wang YC, Wang FH, Shen CC, Yang DY. Repeat operations in failed microvascular decompression for trigeminal neuralgia. *Neurosurgery* 1994;35:665-9.
10. Bakker NA, Van Dijk JM, Immenga S, Wagemakers M, Metzemaekers JD. Repeat microvascular decompression for recurrent idiopathic trigeminal neuralgia. *J Neurosurg* 2014;121:936-9.
11. Chen J, Lee S, Lui T, Yeh Y, Chen T, Tzaan W. Teflon granuloma after microvascular decompression for trigeminal neuralgia. *Surg Neurol* 2000;53:281-7.
12. Megerian CA, Busaba NY, McKenna MJ, Ojemann RG. Teflon granuloma presenting as an enlarging, gadolinium enhancing, posterior fossa mass with progressive hearing loss following microvascular decompression. *Am J Otol* 1995;16:783-6.
13. Preamsagar IC, Moss T, Coakham HB. Teflon-induced granuloma following treatment of trigeminal neuralgia by microvascular decompression. Report of two cases. *J Neurosurg* 1997;87:454-7.
14. Zhang L, Yu Y, Yuan Y, Xu J, Xu X, Zhang J. Microvascular decompression of cochleovestibular nerve in patients with tinnitus and vertigo. *Neurol India* 2012;60:495-7.