

# Management of a rare case of intraventricular ruptured dermoid cyst and chemical meningitis

Ishu Bishnoi<sup>1\*</sup> Sheikhoo Bishnoi<sup>2</sup> Nisha Gahlawat<sup>1</sup> Lalit Bhardwaj<sup>1</sup> Geetika Duggal<sup>3</sup> Gopal Singal<sup>1</sup> Pardaman Singh<sup>4</sup>

<sup>1</sup>*Surgery department, Maharaja Agrasen Medical College, Agroha, India;*

<sup>2</sup>*Psychiatry, Maharaja Agrasen Medical College, Agroha, India;*

<sup>3</sup>*Anaesthesia department, Maharaja Agrasen Medical College, Agroha, India;*

<sup>4</sup>*Radiodiagnosis department, Maharaja Agrasen Medical College, Agroha, India*

\*CONTACT Ishu Bishnoi [ishubishnoi@gmail.com](mailto:ishubishnoi@gmail.com) Surgery department, Maharaja Agrasen Medical College, Room No 18, OPD block, Agroha, Haryana 125047 India

---

## ABSTRACT

**Introduction:** Intraventricular dermoid cyst are very rare benign tumour. Due to benign nature, it may go un-noticed for years and might present with sudden rupture. Ruptured cyst can cause chemical meningitis, hydrocephalus, seizures etc. Due to lack of data, there are no defined guidelines about its management. We are reporting an interesting case of ruptured intraventricular dermoid cyst and chemical meningitis, who was managed successfully and will review the literature.

**Case report:** A 48 years male patient was brought with complaint of sudden mental deterioration, irritability, headache, vomiting for 3 days. He had history of seizures for 1 year. On examination, his higher mental functions were deteriorated, had neck rigidity and left lower limb weakness. CT/MRI brain confirmed diagnosis of right frontal horn ruptured dermoid cyst with scattered fat droplets, hydrocephalus and ventriculitis. Excision of cyst was done via right trans-sulcal (superior frontal sulcus) approach. Patient recovered well.

**Discussion:** Intraventricular dermoid cyst are a rare benign lesion. Due to potential of rupture, it must be surgically treated. Steroids should be used to treat chemical meningitis. Various individual case reports have shown good outcome after surgical management.

**Conclusion:** We recommend early surgery, thorough ventricular wash with ringer lactate, post-operative extraventricular drain and steroid cover to manage ruptured cyst and chemical meningitis.

---

**KEYWORDS** Intraventricular; dermoid cyst; chemical meningitis; steroids

## Introduction

Dermoid cyst is a rare type of benign mass lesion, formed due to abnormal non-disjunction of all dermal layers (ecto-, meso- and endoderm). It is uncommon in brain, reported incidence is 0.04–0.7%.<sup>1</sup> The dermoid cyst rupture is quite rare, around 0.18%, reported by a single independent study.<sup>2</sup> The probable hypothesis behind rupture is spontaneous onset due to accumulation of glandular secretions, brain pulsations and head movement.<sup>3,4</sup> In cranial cavity, most common locations of dermoid cyst are cranial midline at skull base e.g. suprasellar, parasellar and fronto-nasal region.

Less than 15 cases of ruptured intraventricular dermoid cyst have been reported till now. Dr. Howard Brown and Dr. Douglas Miller first reported about ruptured intraventricular dermoid cyst in 1947 and 1950 respectively.<sup>5</sup> Dermoid cyst are otherwise benign, asymptomatic lesions. But various complications have been reported following rupture of dermoid cyst, like, seizures, hydrocephalus, meningitis, deranged mental functions, focal deficit, death.<sup>5–7</sup> Even after surgical excision, patient might deteriorate due to meningitis or hydrocephalus. There are no set guidelines to treat such kind of situation. We are reporting about management of a case of intraventricular ruptured dermoid cyst and review the literature.

## Case report

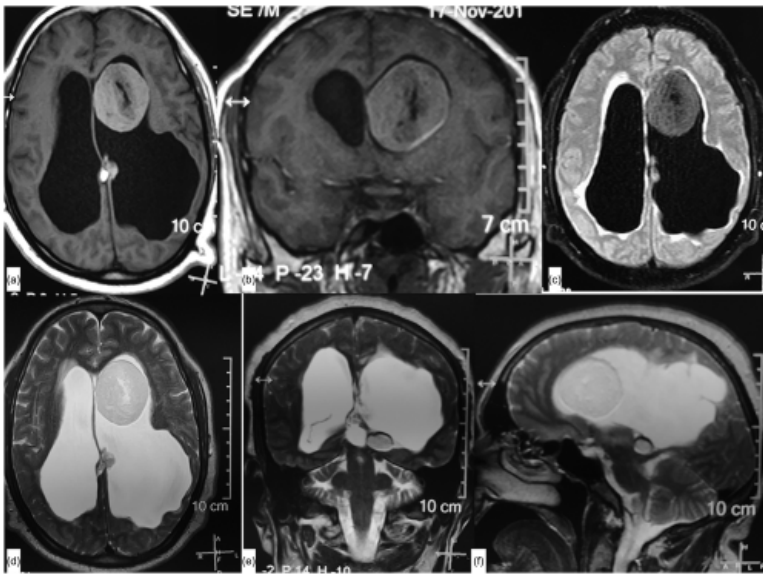
A, 48 years old, male patient was brought in emergency with complaints of headache, vomiting, mental function deterioration, seizures (three episodes), and irritability for last 3 days. Patient was progressively worsening. He had past history of seizures (generalized tonic-clonic) for last 1 year. He was a chronic alcoholic and smoker. There was no past history of any kind of radiological investigation. On examination, he was disoriented, not able to follow simple commands and had neck rigidity. There was weakness (power 4/5) of right lower limb. Fundus examination revealed bilateral papilledema.

CT head revealed dark colored, round hypo-density in left frontal horn with few hyper- and hypo-dense lesions scattered in left lateral ventricle, hydrocephalus and peri-ventricular ooze/ventriculitis (Figure 1). MRI brain confirmed the findings (Figure 2(a-f)). Patient was started on intravenous dexamethasone 18 mg/day, ceftriaxone 2 g/day, amikacin 1 g/day, levetiracetam 1 g/day and planned for surgery. Due to large size of lesion ( $5.6 \times 5.5 \times 4$  cm), we planned for trans-sulcal approach via superior frontal sulcus.

Figure 1. NCCT brain showing hypodense round lesion left frontal horn with scattered contents in ipsilateral ventricle's body.

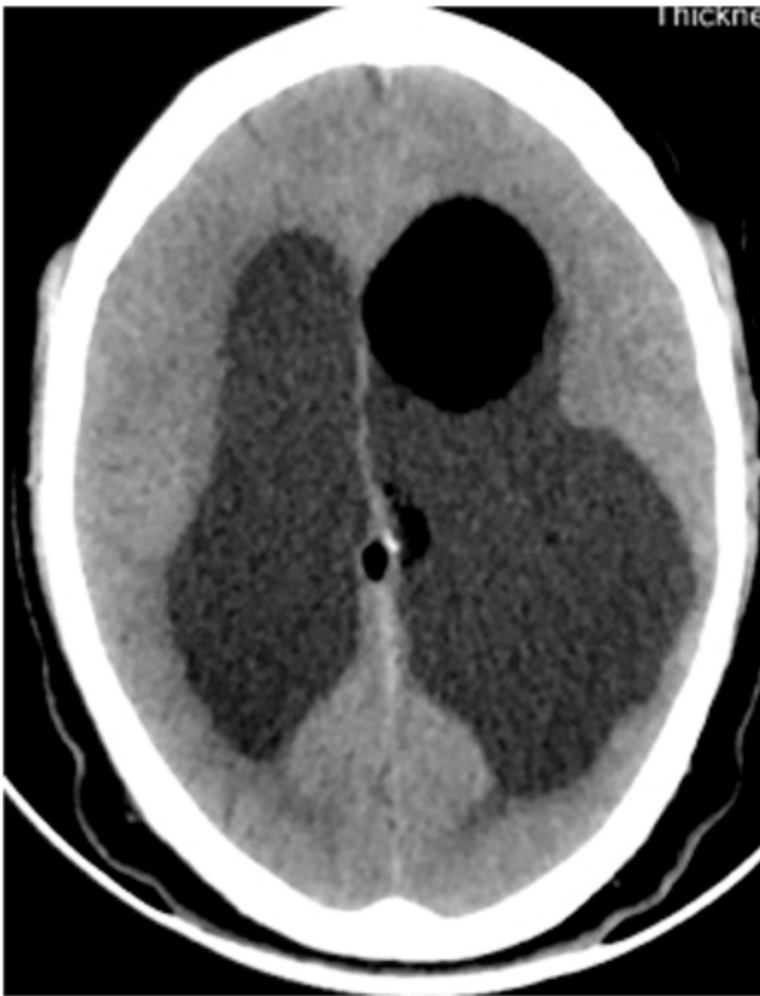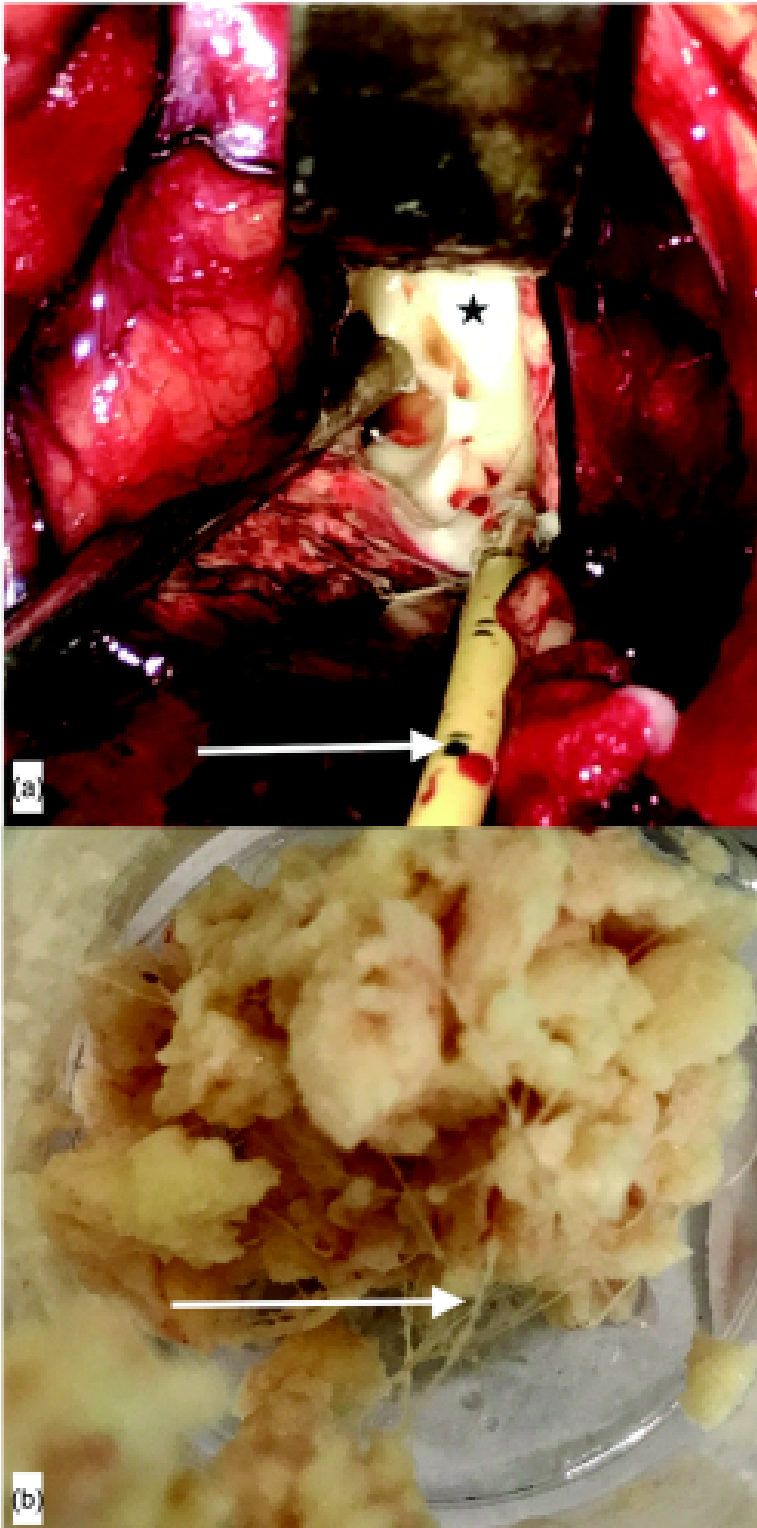


Figure 2. (a) T<sub>1</sub> MRI brain, axial cut, (b) coronal cut showing hyperintense round lesion with hypointense core in left frontal horn, hyperintense small lesions in left ventricle's body, dilated ventricles, (c) FLAIR showing hyperintense lesion with periventricular ooze, (d) T<sub>2</sub> axial, (e) coronal, (f) sagittal cuts showing hyperintense lesion almost similar to CSF, with scattered contents.



Procedure – Patient was kept in supine position with head in neutral state. Bicoronal skin incision was given and left paramedical frontal craniotomy (4 cm size) was made. Before opening superior frontal sulcus, we passed ventricular catheter through it to drain CSF (CSF was opaque) and followed its trajectory to open frontal horn (Figure 3(a)). The cyst was arising from medial wall of frontal horn. It was containing cheesy, fatty material with hairs (Figure 3(b)). Scattered contents were seen lying on the floor. Few of these were removed. After complete excision, the cavity was thoroughly irrigated with ringer lactate solution, till it became clean. The ventricular catheter was left *in situ* to drain CSF externally and prevent its collapse.

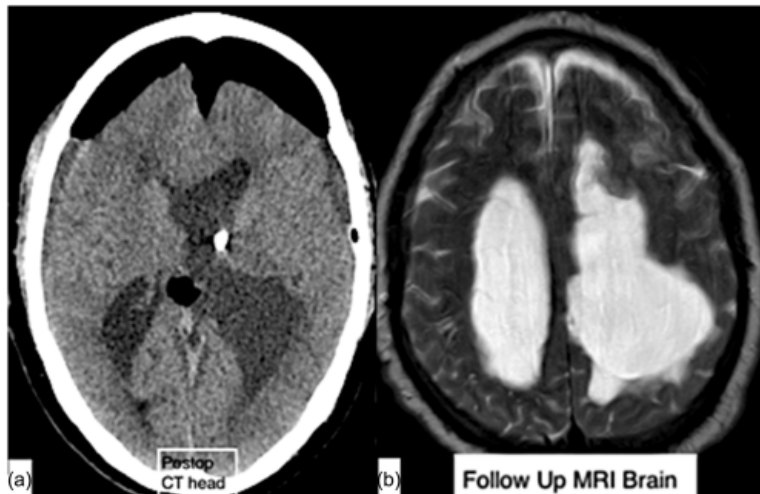
Figure 3. (a) Intraoperative image showing ruptured dermoid cyst (star) intraventricular location, seen through superior frontal sulcus with ventricular drain (arrow) *in situ*, (b) dermoid contents, cream coloured mainly fatty material, with hair strands (arrow).



Postoperative stay – Patient was kept in ICU for 1 day. He was given same medication as before. NCCT head ([Figure 4\(a\)](#)), after 24 h, revealed Pneumocephalus, ventricle catheter *in-situ* and complete excision of cyst. Patient mental function improved significantly. After 24 h, he became conscious, oriented and was following simple commands. His

lower limb weakness was still present. The ventricular catheter was removed on 5th day when CSF became clear and pressure was normal. He was kept under observation for next 7 days to detect any mental deterioration or signs of hydrocephalus. He performed well and was discharged on 15th day. After 1 month follow up, he was in satisfactory condition. His lower limb power is +4/5. Postop MRI, on 30th day (Figure 4(b)), revealed dilated ventricles, but no ooze, no dermoid cyst. Some scattered contents were still present.

Figure 4. (a) Postoperative NCCT head showing complete excision of dermoid cyst, pneumocephalus, EVD in situ and contents in left ventricle's body, (b), follow up MRI brain T<sub>2</sub> image showing same sized lateral ventricles as before, resolution of pneumocephalus and periventricular ooze.



## Discussion

Intracranial dermoid cyst is a benign mass lesion, develops as a result of ectodermal inclusions of primitive pleuripotent cells following defect of neural tube closure at 3–5 weeks gestational age.<sup>8,9</sup> It usually contains lipid cells, apocrine glands, hair follicles and sweat glands.

Due to benign and slow growing nature, dermoid cyst usually goes unnoticed for long duration. This leads to large size and pressure over adjacent neurovascular structures. In our case, prolonged history of seizures could be due to pressure effect of cyst and chronic hydrocephalus. Usual pressure symptoms are headache, seizures and focal deficit. However rupture can cause sudden release of chemicals, like fat globules, secretions of glands, into CSF. It can cause severe chemical meningitis, acute hydrocephalus, seizures, mental deterioration and focal deficit.<sup>5–7</sup> It can be asymptomatic also.<sup>10</sup>

There is no separate hypothesis behind intraventricular origin of dermoid cyst. Almost all reported intraventricular dermoid cyst case reports have one thing common i.e. rupture.<sup>5,7,11,12</sup> The probable reason could be non-significant pressure symptoms, which go un-noticed and pressure due to large CSF volume and pulsations. Rupture in ventricular cavity manifests more prominently than subarachnoid spaces. It is because of contamination of larger volume of CSF and thus severe chemical meningitis, ventriculitis and sudden hydrocephalus.<sup>5,7,11</sup> Thus ruptured intraventricular dermoid cyst is more dangerous and reported more.

The Dermoid cyst contents are unique and thus it has a characteristic CT and MRI appearances. The usual shape is round/globular or lobulated. Due to excessive fat content, the CT gives attenuation values from –150 to 0 HU and appears like air bubble.<sup>8,9</sup> Ruptured cyst can give impression of multiple air bubbles. The cyst can show foci of calcification without evidence of enhancement or surrounding edema after contrast. On MRI brain, there is high signal intensity on T<sub>1</sub> image due to lipid content. On T<sub>2</sub>, the cyst shows heterogeneous signal, mostly hyperintense, due to the mixed composition of the tumour. Fat-suppression techniques can be used to definitely demonstrate the presence of lipid within these lesions.<sup>8,9</sup> The fluid attenuation inversion recovery (FLAIR) is quite useful in diagnosing intraventricular dermoid

cyst due to revelation of hyperintense (bright) round mass on a background of suppressed fluid signal (dark).<sup>13</sup> Its use becomes more important if the internal fat content is relatively low, the lesion will reveal cerebrospinal fluid-like signal intensity. In such cases, FLAIR helps in identifying it.<sup>13</sup> In case of chemical meningitis following rupture, extensive pial enhancement may be seen after gadolinium T<sub>1</sub> weighted MRI.<sup>8,9,13</sup> The scattered contents and fat droplets can be seen as multiple hyperintensities on T<sub>1</sub> and mixed intensities on T<sub>2</sub> weighted images.

While managing such case, the priority should be to control intracranial pressure and ongoing inflammation. Intracranial pressure is controlled by draining CSF using extraventricular drain (EVD). Large dose of steroid, dexamethasone 24 mg/day in 60 kg person, is needed in pre-operative period to control ongoing inflammation and meningitis. The excision of lesion must be done as soon as patient is stabilized.

While excising dermoid cyst, the ventricular cavity must be thoroughly washed with ringer lactate solution till CSF becomes clear. It removes inflammatory cytokines. Dexamethasone must be given in post-operative period till meningitis cures. After excision, an EVD should be left in ventricular cavity. It can be used to prevent postoperative severe collapse of ventricular cavity, know about CSF pressure and color. When CSF becomes clear and pressure remains normal, it can be removed. If pressure remains high, shunt surgery should be done. Patient must be closely followed up for few months, to know about delayed hydrocephalus or chemical meningitis. The scattered contents can persist for long time without causing any side effects.<sup>14</sup>

## Conclusion

Intraventricular dermoid cyst usually presents after rupture. It is a very rare lesion. MRI brain with FLAIR image should be used to confirm the diagnosis. The management strategies should focus on treating intracranial pressure and controlling inflammation. During surgery, thorough ventricular wash should be done after excising lesion. Steroids play an important role in controlling inflammation. EVD in postoperative period prevents complications, control intracranial pressure and may guide about need of shunt for hydrocephalus. Regular follow up is needed to rule out delayed hydrocephalus.

## Disclosure statement

No potential conflict of interest was reported by the authors.

## References

1. Rubin G, Scienza R, Pasqualin A, Rosta L, Da Pian R. Craniocerebral epidermoids and dermoids. A review of 44 cases. *Acta Neurochir (Wien)* 1989;**97**:1–16.
2. Liu JK, Gottfried ON, Salzman KL, Schmidt RH, Couldwell WT. Ruptured intracranial dermoid cysts: clinical, radiographic, and surgical features. *Neurosurgery* 2008;**62**:377–84.
3. Stendel R, Pietilä TA, Lehmann K, Kurth R, Suess O, Brock M. Ruptured intracranial dermoid cysts. *Surg Neurol* 2002;**57**:391–8.
4. Lunardi P, Missori P. Supratentorial dermoid cysts. *J Neurosurg* 1991;**75**:262–6.
5. Miller D. Case report: dermoid cyst of the frontal lobe with intraventricular rupture. *J Neurol Neurosurg Psychiatry* 1950;**13**:63–5.
6. Hash CJ, Ritchie DJ. Ruptured intraventricular dermoid cyst without clinical inflammation. *Arch Neurol* 1978;**35**:61.
7. Martin R, Knone A, Schuknecht B, Kuhn W. Rapid development of occlusion hydrocephalus by intraventricular fat possibly derived from a ruptured dermoid cyst. *J Neurol Neurosurg Psychiatry* 1989;**52**:134–5.
8. Kim YJ, Won YD, Kim KT, Chang ED, Huh PW. Parenchymal neurocutaneous melanosis in association with intraventricular dermoid and Dandy-Walker variant: a case report. *Korean J Radiol* 2006;**7**:145–8.
9. Smirniotopoulos JG, Chiechi MV. Teratomas, dermoids, and epidermoids of the head and neck. *Radiographics* 1995;**15**:1437–55.

10. Funke M. Ruptured intracranial dermoid as an incidental finding. *Aktuelle Radiol* 1995;**5**:232–4.
11. Lutterbey G, Lülldorf P. Ruptured intraventricular dermoid cyst. *Rofo* 2004;**176**:417–8.
12. A. Wani A, Raswan US, Malik NK, Ramzan AU. Posterior fossa ruptured dermoid cyst presenting with hydrocephalus. *Neurosciences* 2016;**21**:358–60.
13. Ray MJ, Barnett DW, Snipes GJ, Layton KF, Opatowsky MJ. Ruptured intracranial dermoid cyst. *Proc (Bayl Univ Med Cent)* 2012;**25**:23–5.
14. Majchrzak K. The presence of intraventricular fat in a case of dermoid cyst. *Neurol Neurochir Pol* 2004;**38**:147–51.

## AUTHOR QUERIES

Query: AQ1: Please review the table of contributors below and confirm that the first and last names are structured correctly and that the authors are listed in the correct order of contribution. This check is to ensure that your names will appear correctly online and when the article is indexed.

Sequence	Prefix	Given name(s)	Surname	Suffix
1		Ishu	Bishnoi	
2		Sheikhoo	Bishnoi	
3		Nisha	Gahlawat	
4		Lalit	Bhardwaj	
5		Geetika	Duggal	
6		Gopal	Singal	
7		Pardaman	Singh	

Response: Resolved