


**Provided for non-commercial research and education use.
Not for reproduction, distribution or commercial use.**

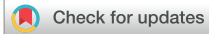

This article appeared in a journal published by Elsevier. The attached copy is furnished to the author for internal non-commercial research and education use, including for instruction at the author's institution and sharing with colleagues.

Other uses, including reproduction and distribution, or selling or licensing copies, or posting to personal, institutional or third party websites are prohibited.

In most cases authors are permitted to post their version of the article (e.g. in Word or Tex form) to their personal website or institutional repository. Authors requiring further information regarding Elsevier's archiving and manuscript policies are encouraged to visit:

<http://www.elsevier.com/authorsrights>



A Worst-Case Scenario—Undiagnosed Ruptured Arteriovenous Malformation Managed with Limited Resources

Ishu Bishnoi¹, Vikram Saini², Pallavi Chugh³, Sheikho Bishnoi⁴, Geetika Duggal³, Anamika Adib¹

Key words

- AVM
- Clip
- Hematoma

Abbreviations and Acronyms

AVM: Arteriovenous malformation

CT: Computed tomography

From the Departments of ¹Neurosurgery, ²General Surgery, ³Anesthesia, and ⁴Psychiatry, Maharaja Agrasen Medical College, Agroha, India

To whom correspondence should be addressed:
Ishu Bishnoi, M.B.B.S., M.S., M.Ch.
[E-mail: ishubishnoi@gmail.com]

Citation: *World Neurosurg.* (2018) 120:430-434.
<https://doi.org/10.1016/j.wneu.2018.09.068>

Journal homepage: www.WORLDNEUROSURGERY.org

Available online: www.sciencedirect.com

1878-8750/\$ - see front matter © 2018 Elsevier Inc. All rights reserved.

INTRODUCTION

Treatment of arteriovenous malformations (AVMs) is currently performed at specialized neurosurgical centers that are well equipped with microscopes with green filters, neurosurgical catheterization laboratories, and experienced neurosurgical teams.^{1,2} Patients in whom AVMs are diagnosed at smaller hospitals should be referred to such specialized centers. This case report describes the unavoidable worst-case scenario of an emergency unplanned surgical excision of an undiagnosed ruptured AVM with large hematoma.

CASE DESCRIPTION

A 26-year-old man experienced 2 episodes of seizures followed by headache, vomiting, and sudden loss of consciousness. He was brought to the emergency department about 4 hours after loss of consciousness. He had a history of intermittent headache and left-side focal seizures. On examination, he was in a deep coma with labored breathing. His Glasgow Coma Scale score was 5 (E1V1M3 [eye opening response, 1; verbal response, 1; motor response, 3]).

■ **BACKGROUND:** Treatment of arteriovenous malformations (AVMs) is currently performed at specialized neurosurgical centers well equipped with microscopes with green filters, neurosurgical catheterization laboratories, and experienced neurosurgical teams. Patients in whom AVMs are diagnosed at smaller hospitals should be referred to such specialized centers. This case report describes the unavoidable worst-case scenario of an emergency unplanned surgical excision of an undiagnosed ruptured AVM with large hematoma.

■ **CASE DESCRIPTION:** A 26-year-old man was brought to the emergency department with episodes of seizures and sudden loss of consciousness. His Glasgow Coma Scale score was 5. He had anisocoria. Computed tomography of the head showed right occipital hematoma with mass effect and herniation. Suspected diagnosis was spontaneous tumor or hypertensive bleed. Emergency surgery was performed. Intraoperatively, ruptured AVM was found. After explaining to family members about nonavailability of conventional instruments (i.e., microscope, clips, indocyanine green), we planned for excision of AVM with available resources.

■ **CONCLUSIONS:** Postoperatively the patient recovered satisfactorily with right-side vision loss. He underwent cranioplasty after 6 weeks. In such a worst-case scenario, remaining calm, following basic surgical steps, using blood transfusion, and employing lateral thinking regarding using available resources can result in satisfactory management of the patient.

His right pupil was dilated and nonreactive, and left pupil was normal size and reactive (anisocoria). The airway was immediately secured by intubation. He was sedated and paralyzed to stop further progression of cerebral edema. Non-contrast computed tomography (CT) scan of the head (**Figure 1A** and **B**) showed right occipital hematoma with mass effect and right-side tentorial herniation. The suspected diagnosis was spontaneous tumor or hypertensive bleed. Owing to rapid deterioration, urgent decompressive craniotomy and hematoma evacuation was planned.

Procedure

A right-side large parieto-occipital craniotomy was performed. The dura mater was very tense. After trying measures such as head elevation, mannitol 300-mL bolus, furosemide 40 mg, and hyperventilation,

dural tension decreased a little bit. As the dura was incised, the brain started bulging out. Tortuous bright red vessels over the parieto-occipital region were suggestive of ruptured AVM. This was a critical and nerve-racking situation, as we did not have any preoperative knowledge of arterial feeders, venous drainage, and nidus anatomy or proper instruments (nonsticky bipolar cautery, clips, clip applicator, neurosurgical microscope with green filter, indocyanine green dye, and surgical glue). The situation was worsening further as the brain was bulging too much with no pulsations. Performing a large hemispheric decompressive craniotomy might have saved us from this situation, but owing to this sudden anxious situation, the idea did not occur to us. However, we tried leaving the dura as such and approximating skin edges to cover the brain surface so that patient could be

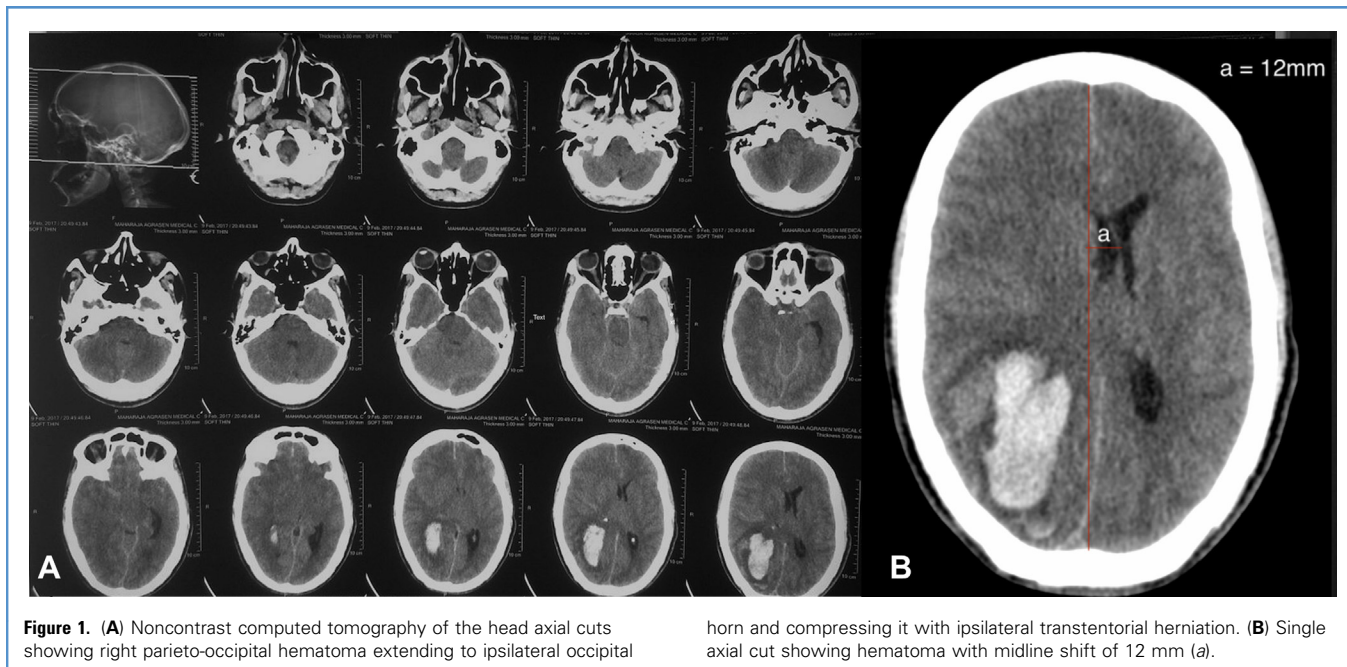


Figure 1. (A) Noncontrast computed tomography of the head axial cuts showing right parieto-occipital hematoma extending to ipsilateral occipital

horn and compressing it with ipsilateral transtentorial herniation. (B) Single axial cut showing hematoma with midline shift of 12 mm (a).

transferred to a specialized center that was fully equipped. The skin was not approximating. The closest center was about a 4- to 5-hour drive, and the patient's family members could not financially afford this transfer. After discussing every worst possibility, we planned hematoma evacuation, and if the AVM bled, surgical excision would be attempted. The situation was discussed with the family members and explained in detail, and informed consent was obtained.

Before beginning the procedure, 2 U of whole blood were released, and 1 g tranexamic acid was given intravenously. The blood bank was informed that 3–5 U of type O–positive whole blood, 4–6 U of platelets, and 4–6 U of fresh frozen plasma were needed. The hematoma was evacuated via a transgyral approach at the maximum bulge site. After some time, profuse bright red bleeding started, which was most likely due to release of pressure or injury to nidus. Owing to ongoing blood loss, the plan was changed, and it was decided to control feeders first. Blood transfusion was started after approximately 500 mL of blood loss. Circumferential resection of cortex was done around tortuous vessels (Figure 2A–D). There

were 2 large feeders at the base that could not be controlled by bipolar cauterization. We decided to ligate them with LIGACLIP EXTRA (Ethicon Inc., Somerville, New Jersey, USA) cystic duct clips using a laparoscopic cystic duct clip applicator (Figure 3A). Owing to the clip applicator's long arm, it became very difficult to clip the feeder. There was no fine control, and the first surgeon had hand tremors owing to anxiety and the long arm instrument without support. After trying for some time, used a 2-hand technique (Figure 3B). The assistant was asked to hold the handle and apply the clip when the first surgeon gave a “yes” nod while the first surgeon held the distal end of the arm in his right hand and guided it at right place. The first surgeon held suction in his left hand to clear blood and retract surrounding brain parenchyma. This was helpful, but the bleeding continued, and approximately 2 L of blood was lost. The patient developed hypotension (systolic blood pressure decreased to 70 mm Hg). The hypotension stopped ongoing blood loss, cleared the surgical field, and helped in controlling feeders. The visible portion of the nidus was then excised.

The nidus was thus excised in pieces owing to inexperience and no knowledge about its exact size and location. The rest of the hematoma was evacuated after excision of the nidus. The brain became lax, and duraplasty was performed using galea aponeurotica. The patient received a further transfusion of 3 U of whole blood, 4 U of fresh frozen plasma, and 3 U of platelets. The anesthesiologist maintained systolic blood pressure at approximately 100 mm Hg (except for the single episode of hypotension) throughout surgery. The bone flap was placed in the subcutaneous plane of the abdominal wall.

Postoperatively, sedation and paralysis were maintained with propofol and vecuronium. CT scan of the head (Figure 4A) obtained 12 hours postoperatively showed significant decompression of the hematoma and relief of herniation. The patient's Glasgow Coma Scale score was 8T (E3VTM5) on day 2; by day 3, he was following commands with a Glasgow Coma Scale score of 9T (E3VTM6). He was extubated on day 5 after regaining full consciousness. He gradually recovered satisfactorily but with some visual deficit

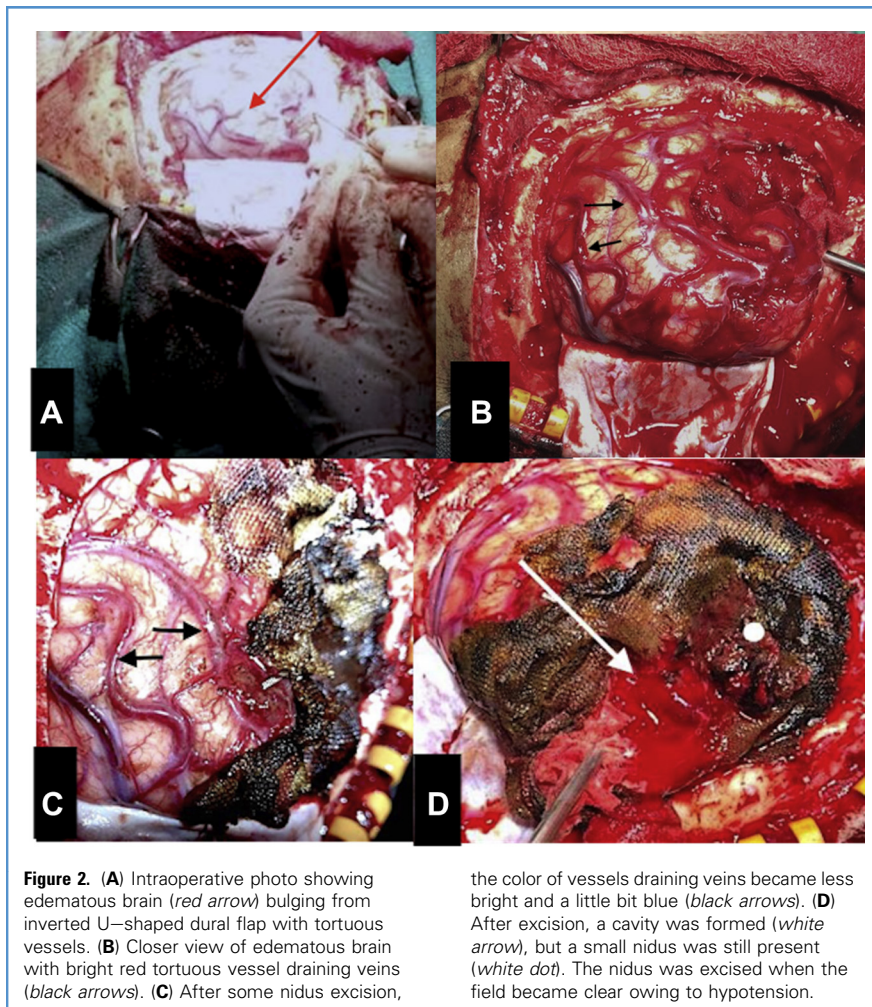


Figure 2. (A) Intraoperative photo showing edematous brain (red arrow) bulging from inverted U-shaped dural flap with tortuous vessels. (B) Closer view of edematous brain with bright red tortuous vessel draining veins (black arrows). (C) After some nidus excision,

the color of vessels draining veins became less bright and a little bit blue (black arrows). (D) After excision, a cavity was formed (white arrow), but a small nidus was still present (white dot). The nidus was excised when the field became clear owing to hypotension.

(left-side homonymous hemianopia, macular sparing). Postoperative CT angiography (Figure 4B and C) confirmed near-total excision of the nidus with a single abnormal communication of a feeder from the right posterior cerebral artery and superficial cortical vein draining into superior sagittal sinus. The choice of excision or embolization of the small residue was given to family members, but treatment was refused because of nonaffordability and risk of complications of surgery or embolization.

Follow-Up

The patient underwent cranioplasty after 6 weeks (Figure 4D). At the present time, he has had regular follow-up for the last 12 months and is doing fine. Repeat CT angiography of the brain at 2-year follow-up is planned.

DISCUSSION

Microneurosurgical excision of nidus has advanced a lot in the last 2 decades as a result of development of good diagnostic tools, anatomic knowledge, and advances in surgery.¹ At the present time, surgical excision of AVM is performed in 4 sequential steps: 1) a large craniotomy is performed to obtain adequate exposure to the AVM, including its arterial feeders and venous outflow; 2) after opening the dura mater, arterial feeders are found, isolated, and blocked (clip or coagulate); 3) the nidus is resected circumferentially from the adjacent brain parenchyma leaving venous drainage; 4) venous drainage is blocked, and the nidus is resected.^{1,5} For all AVMs, these basic steps must be followed to minimize surgical complications. Therefore, before executing surgical excision, the operating

surgeon must thoroughly evaluate AVM anatomy and its relationship with the brain (eloquent and noneloquent areas and neurovascular structure) and check surgical equipment. Unplanned surgery can result in disaster.

There are 2 reports about early surgical management (<8 hours) without much planning of acutely ruptured AVM manifesting with mass effects.^{3,4} Benifla et al.,³ using microsurgical technique and following basic steps, reported good outcomes in 3 children who presented with ruptured AVM and mass effect. Pavesi et al.⁴ reviewed 27 cases of ruptured AVMs managed with surgical excision and decompression within 6 days (21 patients on first day) with good outcomes in 23 patients. Both studies concluded that single-stage excision of ruptured AVM with mass effect results in a good

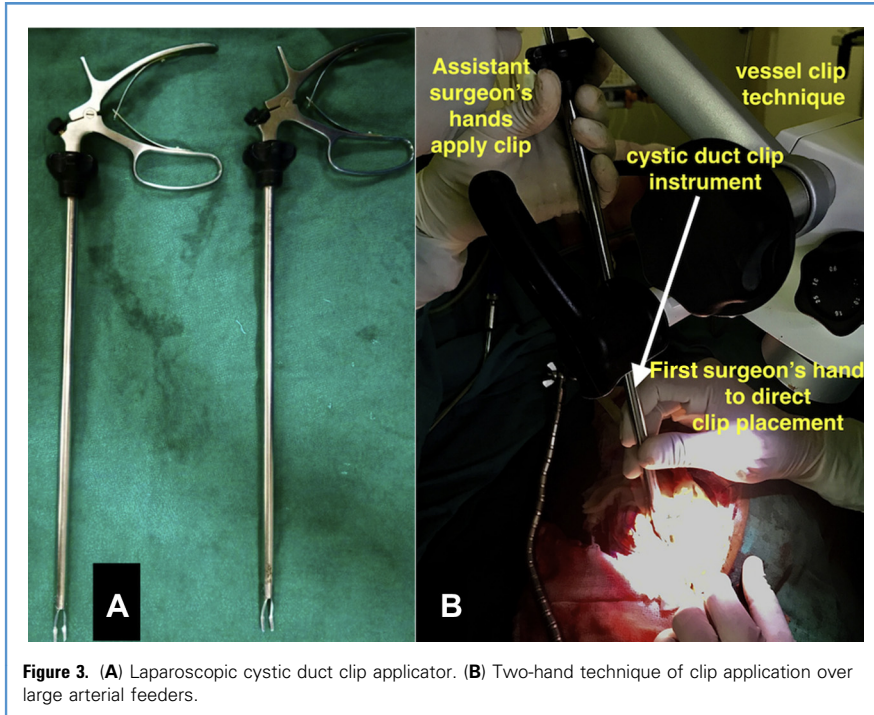


Figure 3. (A) Laparoscopic cystic duct clip applicator. (B) Two-hand technique of clip application over large arterial feeders.

microscope, no clips, no glue, no indocyanine green dye) by an inexperienced surgeon (the first surgeon had assisted on only 3 AVM excisions during his training program) with limited resources and a single aim in mind—saving the patient's life.

In our case, a large hematoma was causing tentorial herniation. Owing to lack of experience of seeing a sudden ruptured AVM, we never considered it as a possibility. We suspected a tumor, drug abuse, or hypertensive bleed. During surgery, we found an AVM. As explained earlier, the conditions were not favorable to the refer patient to a fully equipped center. The excision was begun following basic excision steps.¹⁻⁵ This critical condition necessitated alternative methods to control blood loss. Hence, we thought of using cystic duct clips to control feeders and then a 2-hand clip technique to control hand tremors while applying clips over large feeders. The anesthesiologist also plays a vital role in such a critical situation. Induced hypotension and adequate replacement of blood and blood products helped in achieving hemostasis and stability of vital signs.

outcome.^{3,4} However, these published studies are well-equipped hospitals,

whereas our case was unique in the sense that it was done at a preliminary center (no

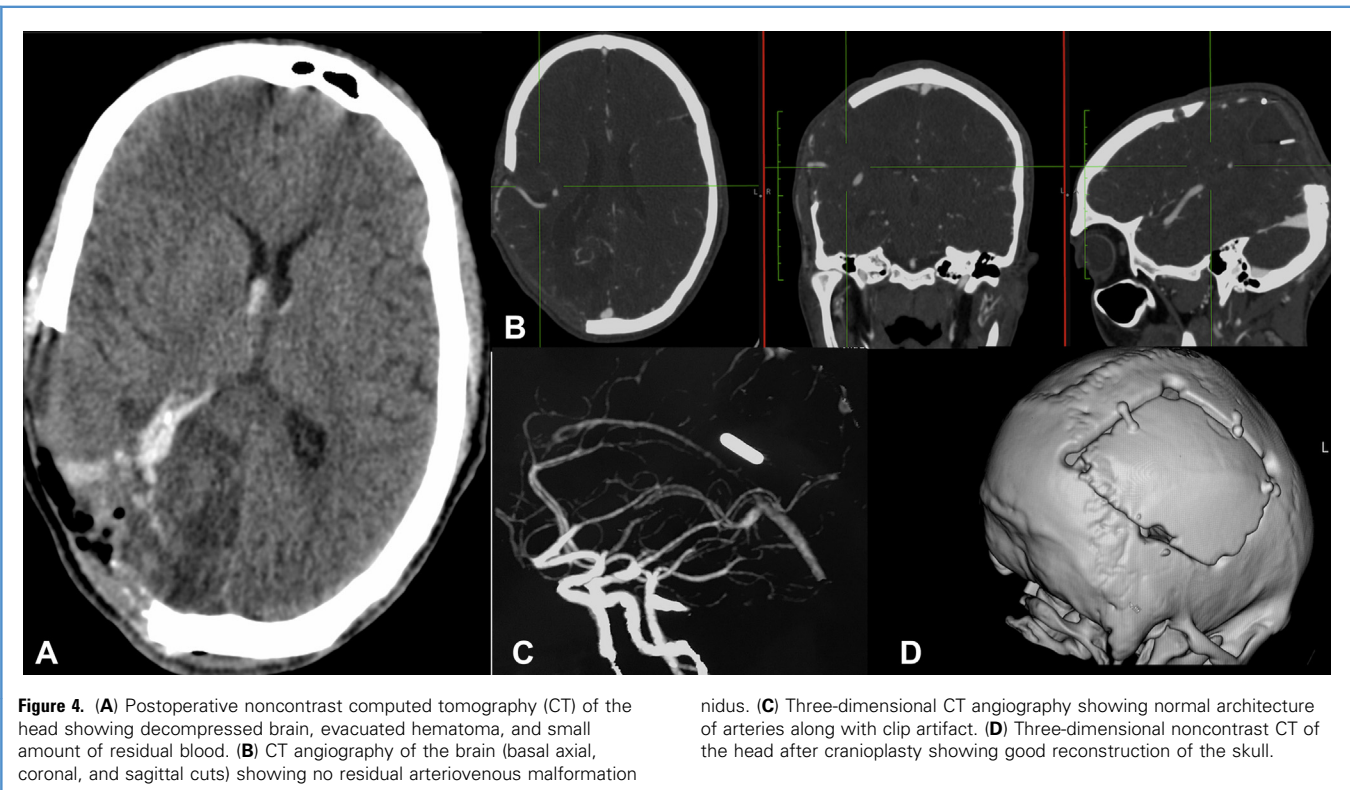


Figure 4. (A) Postoperative noncontrast computed tomography (CT) of the head showing decompressed brain, evacuated hematoma, and small amount of residual blood. (B) CT angiography of the brain (basal axial, coronal, and sagittal cuts) showing no residual arteriovenous malformation

nidus. (C) Three-dimensional CT angiography showing normal architecture of arteries along with clip artifact. (D) Three-dimensional noncontrast CT of the head after cranioplasty showing good reconstruction of the skull.

CONCLUSIONS

An undiagnosed spontaneous parenchymal bleed can be due to AVM rupture. The treating neurosurgeon should include it in the differential diagnosis and be prepared to face such a critical condition after performing craniotomy. In a small hospital or operating room with limited resources, the right way of handling such situation is to remain calm, use alternative methods such as cystic duct clips or sutures, proceed gradually and meticulously, follow basic rules of AVM surgery (i.e., control arterial feeders first, then veins), and use wide resection to control feeders at a safe distance from the nidus even if in an eloquent location (first goal should be control of bleeding rather than avoiding an eloquent region).

ACKNOWLEDGMENTS

We are grateful to Mamta Bishnoi, who assisted this case.

REFERENCES

1. Derdeyn CP, Zipfel GJ, Albuquerque FC, Cooke DL, Feldmann E, Sheehan JP, et al. A scientific statement for healthcare professionals from the American Heart Association/American Stroke Association. *Stroke*. 2017;48:e200-e224.
2. Yamada S, Takagi Y, Nozaki K, Kikuta K, Hashimoto N. Risk factors for subsequent hemorrhage in patients with cerebral arteriovenous malformations. *J Neurosurg*. 2007;107:965-972.
3. Benifla M, Shelef I, Melamed I, Merkin V, Barrely R, Cohen A. Urgent removal of ruptured cerebral arteriovenous malformations in children [in Hebrew] *Harefuah*. 2010;149:148-152.
4. Pavesi G, Rustemi O, Berlucchi S, Frigo AC, Gerunda V, Scienza R. Acute surgical removal of low-grade (Spetzler-Martin I-II) bleeding arteriovenous malformations. *Surg Neurol*. 2009;72:662-667.
5. Toyoda K, Anderson CS, Mayer SA. New insights in intracerebral hemorrhage. *Front Neurol Neurosci*. 2016;37:166-181.

Conflict of interest statement: The authors declare that the article content was composed in the absence of any commercial or financial relationships that could be construed as a potential conflict of interest.

Received 22 July 2018; accepted 11 September 2018

Citation: *World Neurosurg.* (2018) 120:430-434.
<https://doi.org/10.1016/j.wneu.2018.09.068>

Journal homepage: www.WORLDNEUROSURGERY.org

Available online: www.sciencedirect.com

1878-8750/\$ - see front matter © 2018 Elsevier Inc. All rights reserved.