

Virtual Animal Anatomy Programs - User Guide

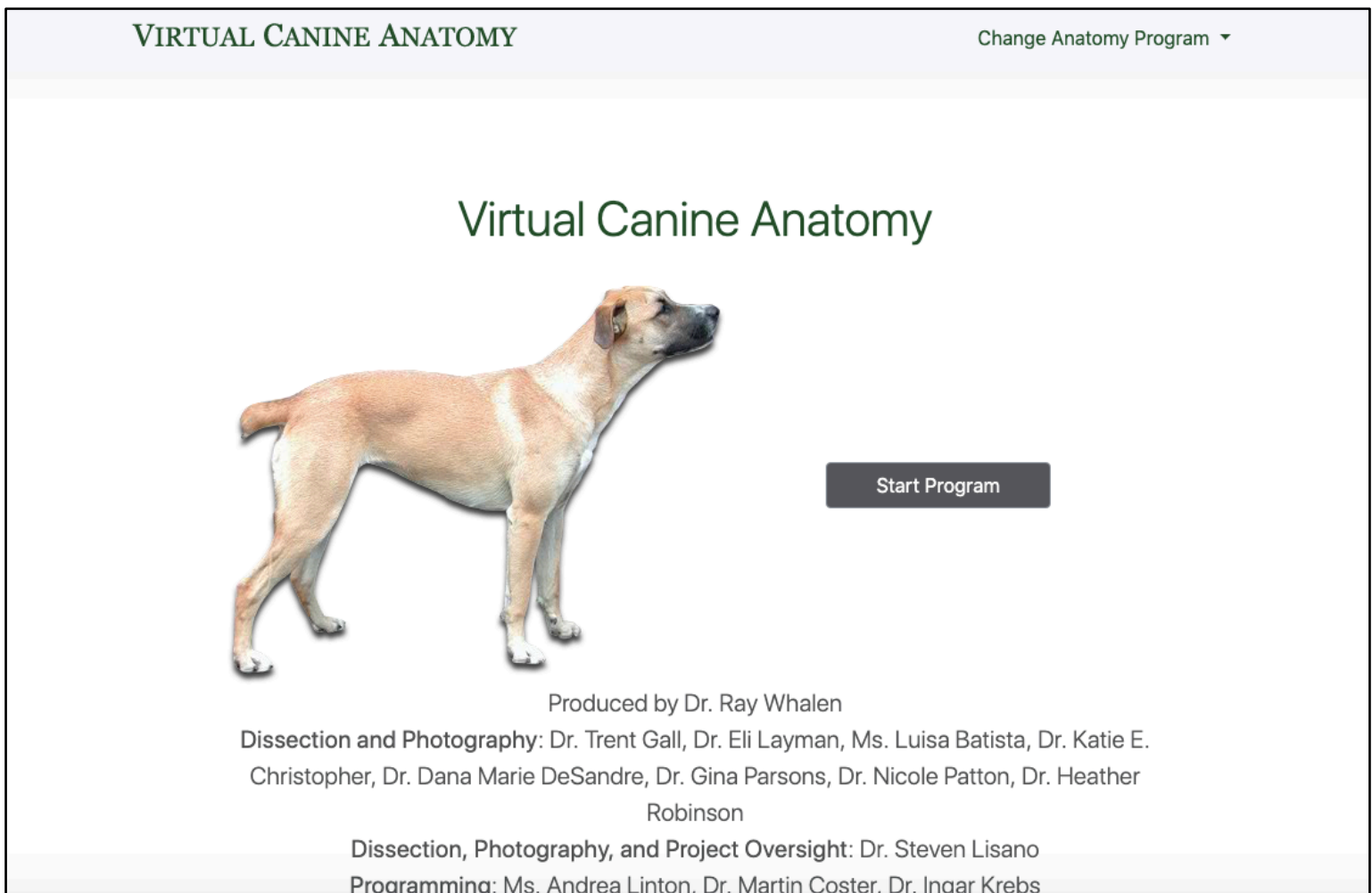Thank you for supporting the development of Colorado State University's Virtual Animal Anatomy (VAA) programs. This user guide provides an overview of the tools and features found within the VAA program suite. Most of the screenshots featured in this guide come from Virtual Canine Anatomy 4.0 (VCA4). However, the instructions and feature descriptions detailed herein are applicable to the entire suite of Veterinary Educational Tools' Virtual Animal Anatomy programs including Virtual Equine Anatomy (VEA), Virtual Feline Anatomy (VFA), and Virtual Bovine Anatomy (VBA). While each program features different species and varying levels of completeness, their navigation tools, and specimen viewing options are analogous. Content, including text and audio content, is the most complete for VCA4, but it is continually being developed for all Virtual Animal Anatomy programs.

Start the Program

Browser Version (Windows and Mac): The program will open in your default browser. We recommend that you use Chrome, Safari, Edge, or Firefox. You will first see the splash screen with development credits displayed at the bottom (Fig. 1).

Click the **"Start Program"** button on the splash screen to start VCA4 (Fig. 1). This will take you to the navigation page (Fig. 2). Note that VEA, VFA, and VBA can be accessed from the splash screen and navigation page by clicking on "Change Anatomy Program" in the top corner.

Fig. 1 - Splash Screen for VCA4



Navigation Page

A program's **navigation page** (Fig. 2) provides tabs for each anatomical section across the top. Selection of a tab will show thumbnails of localized anatomical regions for that section (the head region in VCA4 is selected below). Depending on the section, a variety of detailed categories will be shown, including directional terms, osteology, dissection, radiology, surface anatomy.

Fig. 2 - Splash Screen for VCA4

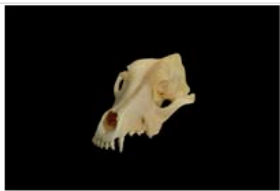
VIRTUAL CANINE ANATOMY Change Anatomy Program ▼

Sections

Head Neck ANS/CNS Thoracic Limb Pelvic Limb Thorax Abdomen and Pelvis Quizzes


Dissection Movies ▼

Head Directional Terms




Head Directional Terms


Head Osteology



External Skull Features



Internal Skull Features

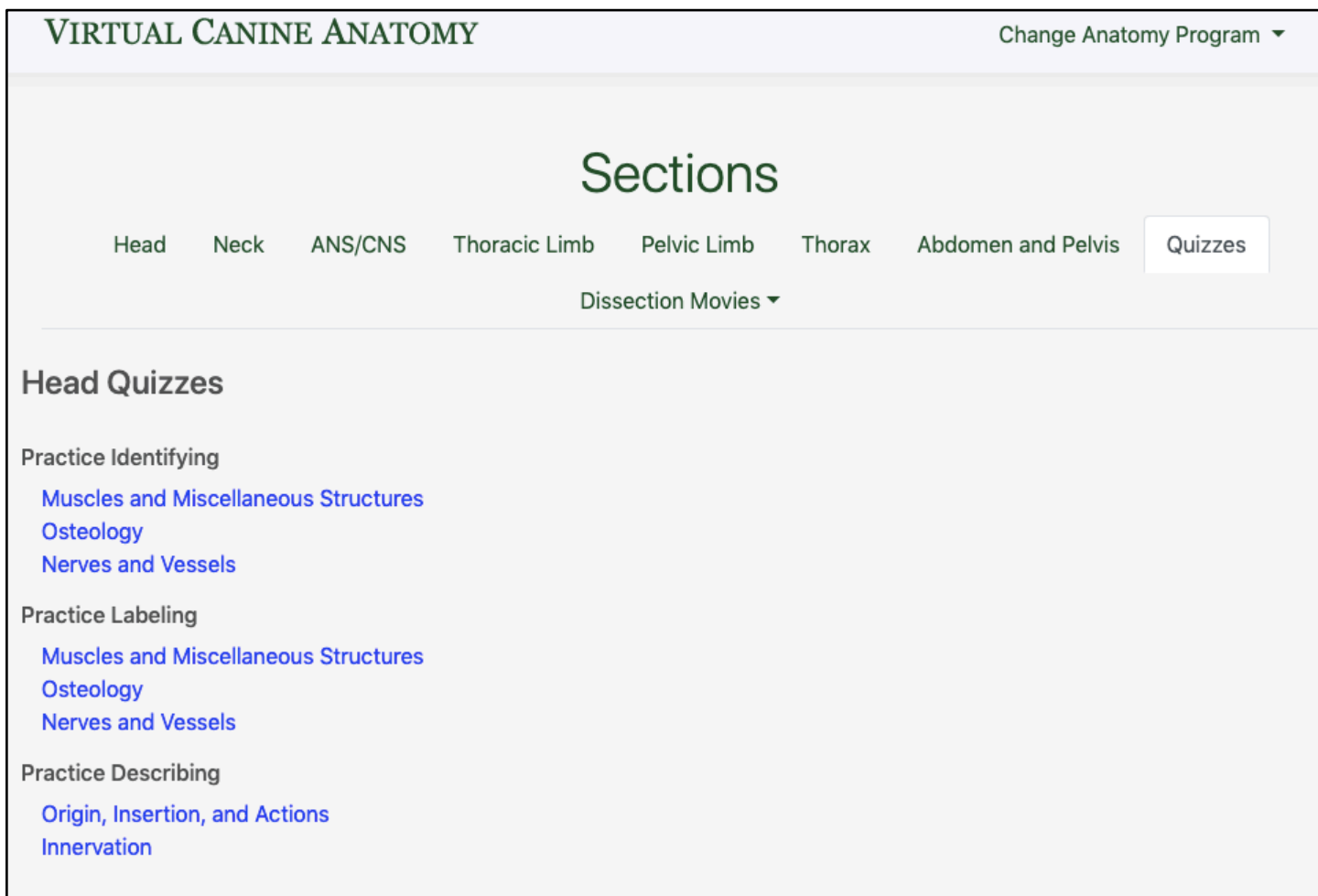


Mandible

Quizzes


Clicking on the tab labeled “Quizzes” will show quiz options for each anatomical region (Fig. 3). All of the Virtual Animal Anatomy programs include point-and-click **structure identification** quizzes (Fig. 4). VCA4 also includes fill-in-the-blank **structure labeling**, and multiple choice **structure description** quizzes. Users are always provided score results at the end of each quiz, allowing for periodic self-assessment.


Fig. 3 – Quiz Options in VCA4



The screenshot displays the 'VIRTUAL CANINE ANATOMY' interface. At the top right, there is a 'Change Anatomy Program' dropdown menu. The main heading is 'Sections', with a navigation bar below it containing tabs for 'Head', 'Neck', 'ANS/CNS', 'Thoracic Limb', 'Pelvic Limb', 'Thorax', 'Abdomen and Pelvis', and 'Quizzes'. The 'Quizzes' tab is currently selected and highlighted. Below the navigation bar, there is a 'Dissection Movies' dropdown menu. The main content area is titled 'Head Quizzes' and is organized into three categories: 'Practice Identifying', 'Practice Labeling', and 'Practice Describing'. Each category lists specific quiz topics in blue text: 'Muscles and Miscellaneous Structures', 'Osteology', and 'Nerves and Vessels' for the first two categories; and 'Origin, Insertion, and Actions' and 'Innervation' for the third category.

Fig. 4 – Structure Identification Quiz in VCA4


VIRTUAL CANINE ANATOMY Home 



Head Osteology
Identification Quiz

Please click on the cerebellar fossa.

Show Answer Continue



© 2019 Colorado State University

Dissection Movies

Clicking on the last tab in VCA4 will open a list of dissection movies (Fig. 5) that show step-by-step instructions for the dissections found in the program. These same movies can also be accessed from the individual structure selection pages described in the next section.

Fig. 5 – Dissection Movies in VCA4

VIRTUAL CANINE ANATOMY Change Anatomy Program ▾

Sections

Head Neck ANS/CNS Thoracic Limb Pelvic Limb Thorax Abdomen and Pelvis Quizzes Dissection Movies ▾

Head Dissection Movies

Larynx Dissection


- [Larynx Lateral with Cranial Laryngeal Nerve](#)
- [Thyroid Cartilage](#)
- [Thyroarytenoid Muscle](#)
- [Laryngeal Saccule](#)
- [Larynx Midsagittal Section](#)
- [Intro to Larynx Pharynx](#)
- [Laryngeal Cartilages Caudal Laryngeal Nerve](#)

Structure Selection Pages

When a thumbnail image is selected on the navigation page, users are directed to a **structure selection page** (Fig. 6) wherein anatomical structures can be studied in-depth from various perspectives.

Fig. 6 – Structure Selection Page for Skull in VCA4

VIRTUAL CANINE ANATOMY Home Change Page ▾ Alternate Views ▾ Search 🔍 ⚙️




External Skull 1: Lateral View

- external sagittal crest
- frontal bone
 - zygomatic process of the frontal bone
- incisive bone
- lacrimal bone
- maxilla
- nasal bone
- nuchal crest
- occipital bone
 - external occipital protuberance
 - jugular process
 - occipital condyle
- palatine bone
- parietal bone
- pterygoid bone
 - hamulus
- sphenoid complex
- temporal bone
 - mandibular fossa
 - mastoid process

zygomatic bone

🔊 **zygomatic bone**

The ventrolateral part of the orbit is formed by the zygomatic bone. The zygomatic bone features a dorsally projecting process, the **frontal process of the zygomatic bone**. A ligamentous connection, the **orbital ligament**, between the frontal process of the zygomatic bone and the zygomatic process of the frontal bone completes the orbit. The forward projecting zygomatic process of the temporal bone, removed in this dissection, unites with the zygomatic bone to create a complete zygomatic arch.



© 2019 Colorado State University

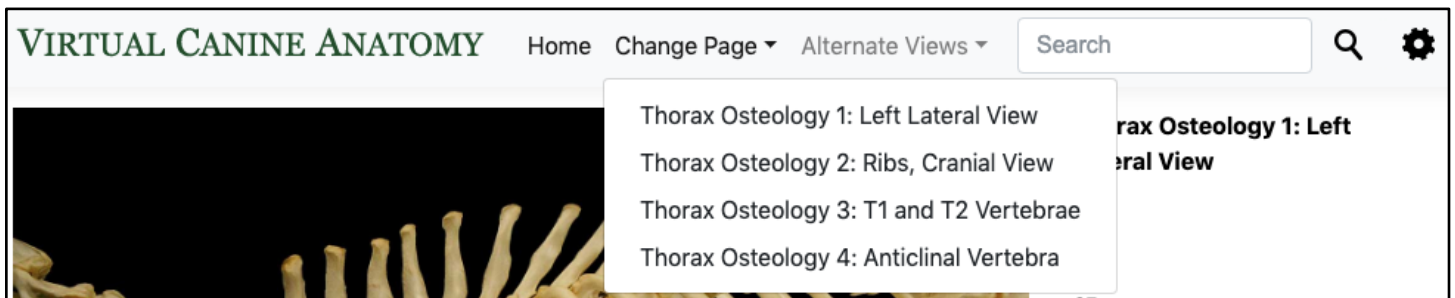
Structure Selection Page – Navigation Bar

The navigation bar on each structure selection page (Fig. 7) includes the following navigation tabs. On smaller screens, this navigation bar will collapse to three bars as shown in the upper right corner in Figure 12. Click on these three bars to access the navigation bar.

Home: This tab will take you back to the navigation page so that you can access any anatomical region in the program.

Change Page: This drop-down menu (Fig. 7) allows for quick navigation to any layer or page of the currently viewed dissection / image sequence. The pages can also be advanced by using the gray arrows underneath the main image (Fig. 6). This menu may not be available on some pages if there are no subsequent layers or images.

Fig. 7 – Navigation Bar, Change Page Drop-Down Open



Alternate Views: Depending on the page, this drop-down menu may be available (Fig. 8). Here you can access different anatomical viewpoints of the specimen (i.e. cranial view, caudal view, dorsal view, ventral view, etc.). When available, alternate dissections, views, and miscellaneous overlays, and dissection movies can also be accessed here. The **“Rotate Specimen”** button opens a separate window (Fig. 9) in which users can virtually rotate the specimen to view it from all angles by clicking and dragging on the image. To zoom in on the rotatable specimen, hold the shift key. Return to full view by holding the control key. Close the new tab to return to the program. The overlays are not available in the rotate function.

Fig. 8 – Navigation Bar, Alternate Views Drop-Down Open

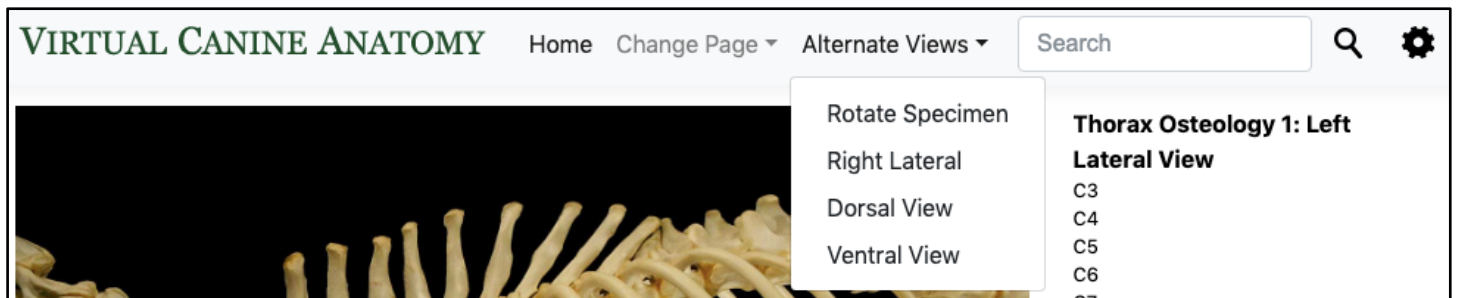
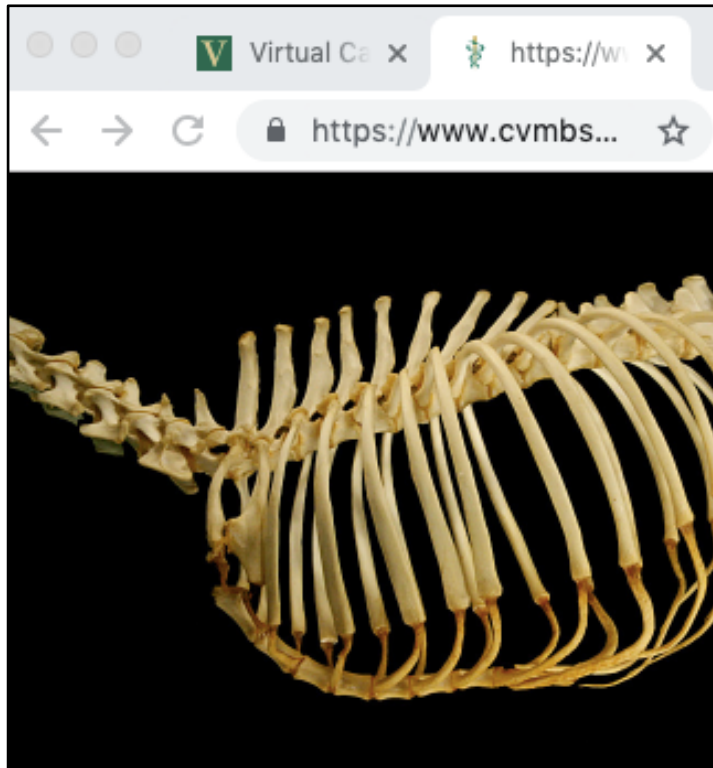
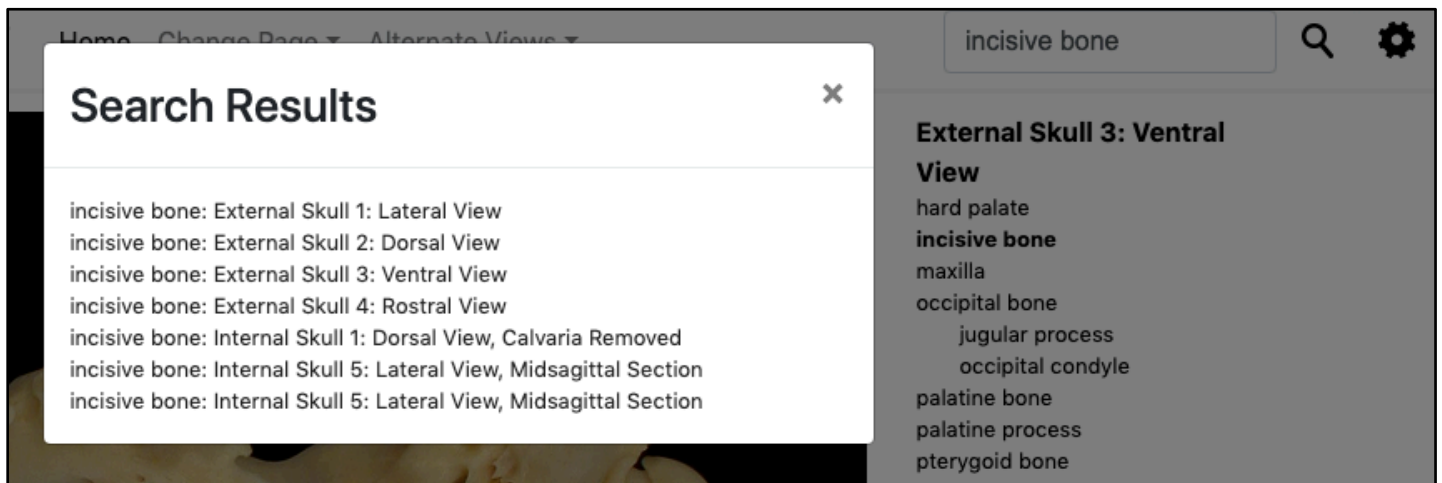


Fig. 9 – Rotate Specimen Window



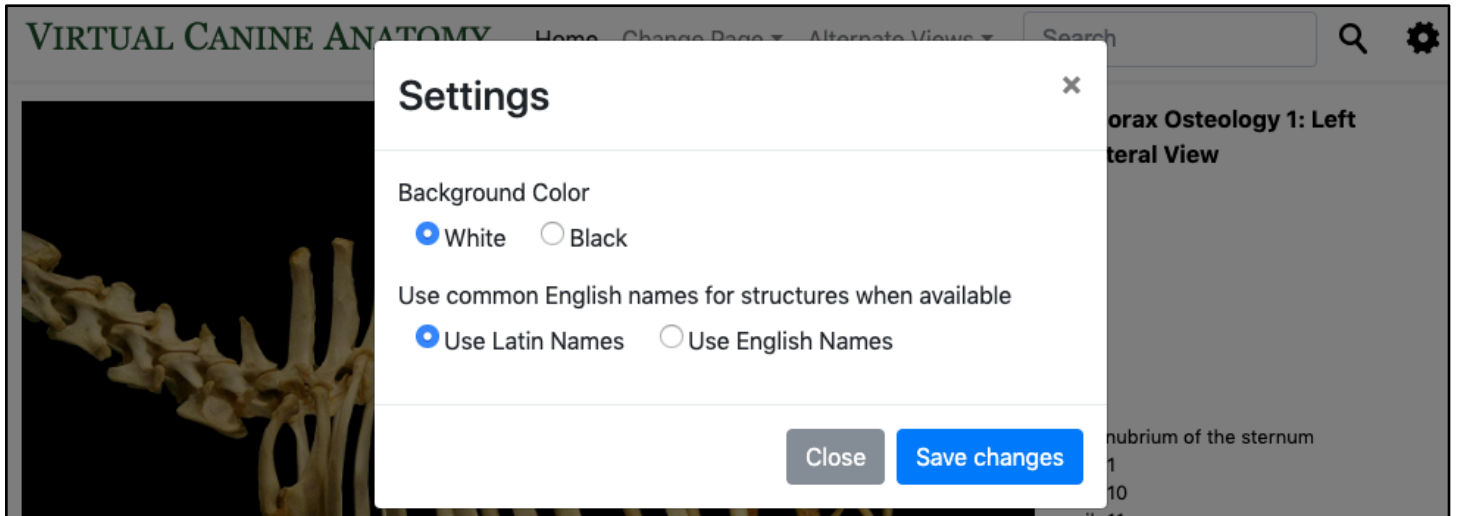
A **search bar** (Fig. 10) located in the upper right corner allows for rapid access to the location of an anatomical structure anywhere it is listed in the program.

Fig. 10 – “incisive bone” Search in VCA4



Settings Gear: Selecting the settings gear will open a modal window (Fig. 11). Here you can change the background color of the program to white or black. You can also choose to view common English names for structures when available. In general, the Virtual Animal Anatomy programs follow the naming criteria outlined in the *Nomina anatomica veterinaria*, Sixth edition – 2017.

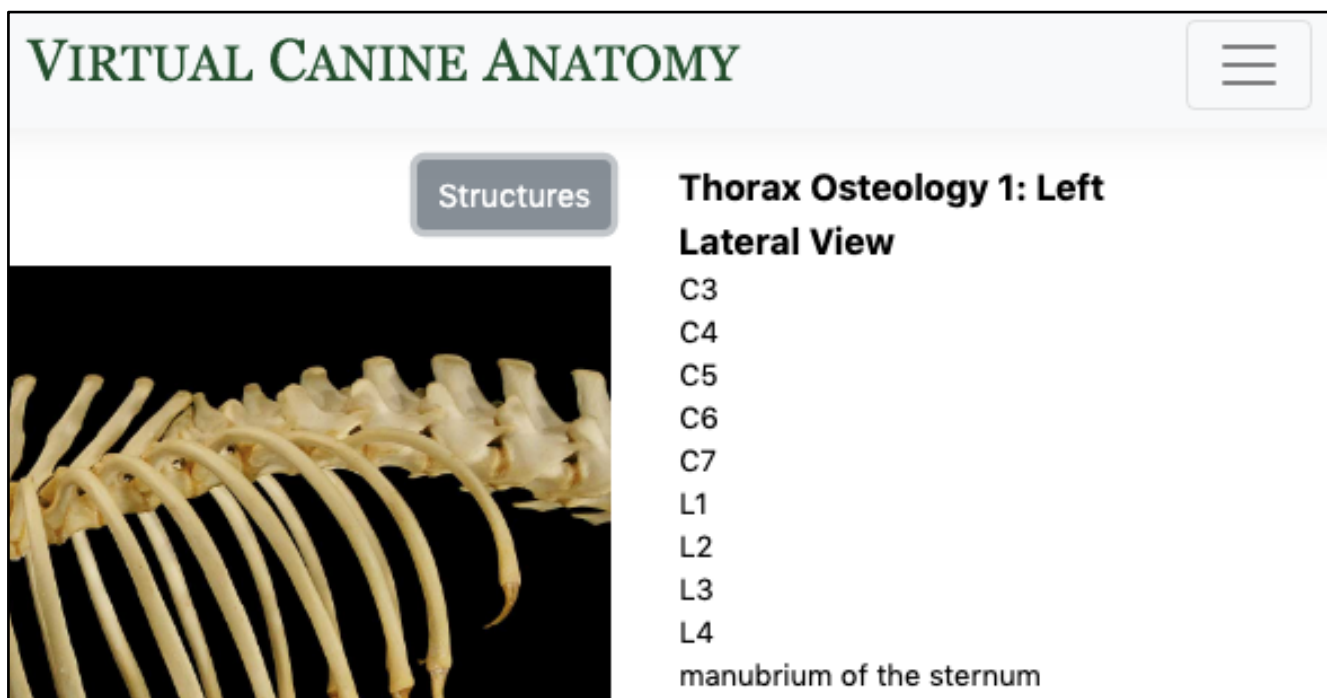
Fig. 11 – Settings Modal Window



Structure Selection Page - Structure List

To the right of the main image, there are links to each available structure in the image. This list will automatically appear on larger screens; on smaller screens it can be accessed by clicking the “Structures” button (Fig. 12).

Fig. 12 – “Structures” Button, Structure List, and Collapsed Navigation Bar



Structure Selection Page - Structure Overlays

A structure will be highlighted with an overlay when a link in the structure list is clicked, showing the visible anatomical boundaries of that structure. Users can also click directly on the main specimen image to view the structure overlays. The overlay color indicates a structure's tissue type (Table 1). A **double overlay**, consisting of two contrasting colors, can be visualized when a specific feature of a structure is selected (e.g. the temporal process of the greater zygomatic bone as shown in Fig. 13).

Fig. 13 – Double Overlay Example

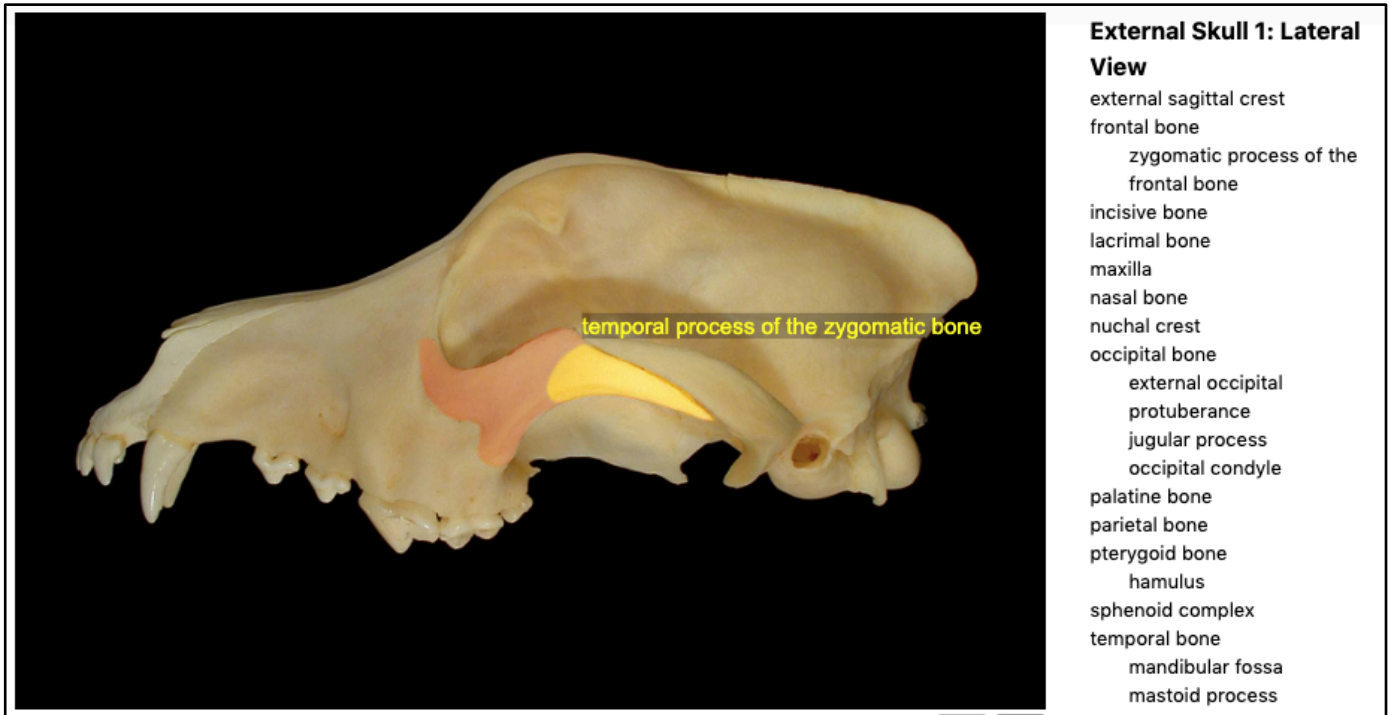




Table 1. Overlay Color – Structure Key		
Tissue Type	Primary Overlay Color	Double Overlay
muscles	brightened	orange
tendons	brightened	orange
organs	brightened	orange
bones	orange	yellow
ligaments	brightened, orange, or turquoise	yellow
nerves	yellow	turquoise
arteries	red	NA
veins	blue	NA
glands, lymph nodes, & ducts	brightened or purple	NA
foramina & passageways	green	NA

Structure Selection Page – Anatomical Description Textbox

Upon selection of a structure link or an overlay, the **anatomical description** (Fig. 14) for that structure is displayed underneath the main specimen image. By clicking on the audio icon adjacent to the anatomical term, the user can listen to pronunciation audio files.

Fig. 14 – Anatomical Description from VCA4

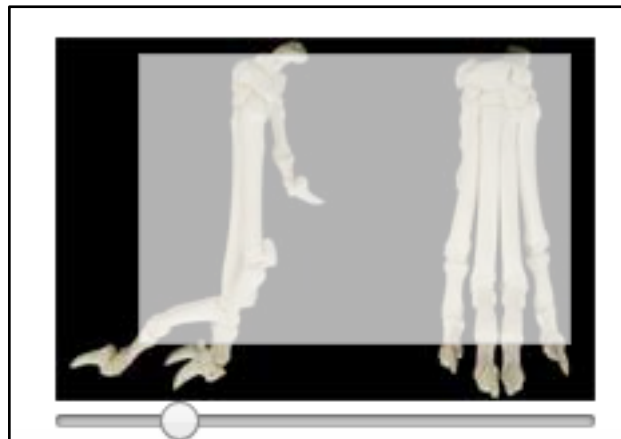


 **temporal process of the zygomatic bone**

The zygomatic bone forms the rostral half of the zygomatic arch. Its arcing, pointed **temporal process** articulates with the zygomatic process of the temporal bone. A dorsally projecting enlargement, the frontal process, gives attachment to the **orbital ligament** that spans between it and the zygomatic process of the frontal bone, completing the canine orbit.

To zoom in on the main specimen image in the structure selection window, click and drag the **zoom slider** (Fig. 15) located below the small thumbnail image on the lower right side of the screen. You may need to click on the “Structures” button (Fig. 12) to view the zoom window. Zooming in produces a white boundary box representing the area now viewable in the main specimen image. **Click and drag the white zoom box** to view different portions of the main image.

Fig. 15 – Zoom Window Example from VCA4

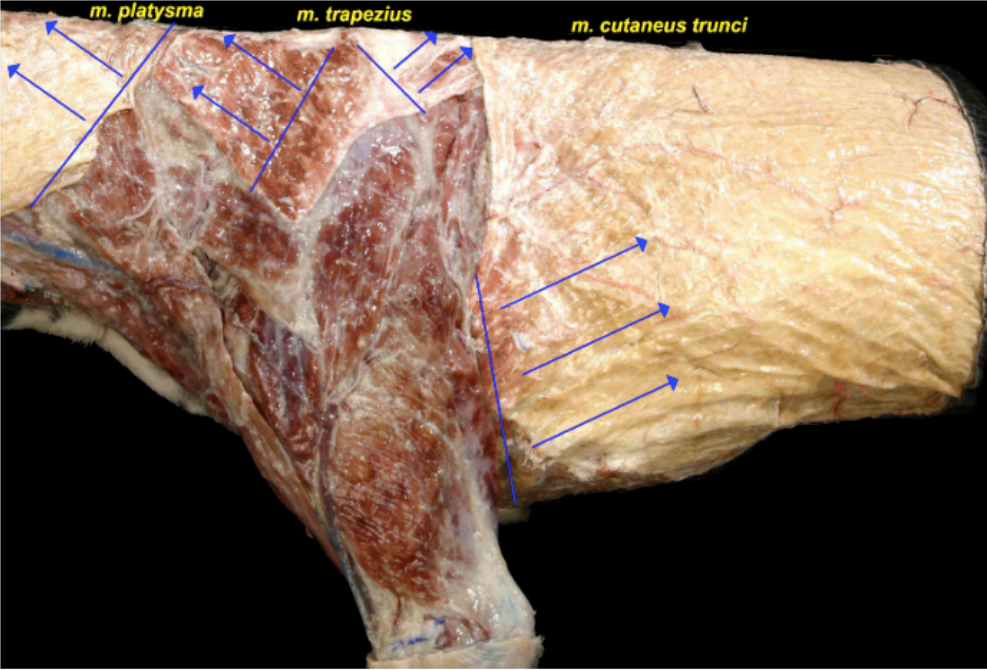


Structure Selection Window – Dissection Instructions

In VCA4, dissection instructions can be accessed via a “**Dissection Instructions**” link at the top of the structure selection list. Selecting the link generates structure overlays as well as step-by-step dissection instructions shown in the structure description textbox below the main image (Fig. 16).

Fig. 16 – Dissection Instructions in VCA4

VIRTUAL CANINE ANATOMY Home Change Page ▾ Alternate Views ▾ Search 🔍 ⚙️




Thoracic Limbs 2: Muscle Dissection
Dissection Instructions

- m. brachiocephalicus*
 - clavicular intersection
- m. cleidobrachialis*
- m. cleidocephalicus*
- m. cutaneus trunci*
- m. deltoideus*
 - pars acromialis*
 - pars scapularis*
- m. omotransversarius*
- m. platysma*
- m. sternocephalicus*
- m. trapezius*
 - pars cervicalis*
 - pars thoracis*
- m. triceps brachii*
 - caput laterale*
 - caput longum*

Transect the *m. trapezius*

1. Transect the *m. trapezius* with an arching incision that begins on the cranial border of the muscle and parallels the dorsal border of the scapula. Leave sufficient muscle attached to the spine of the scapula to identify the insertion.
2. Section the *m. cutaneus trunci* just as it passes deep to the thoracic limb on its caudal aspect.



© 2019 Colorado State University

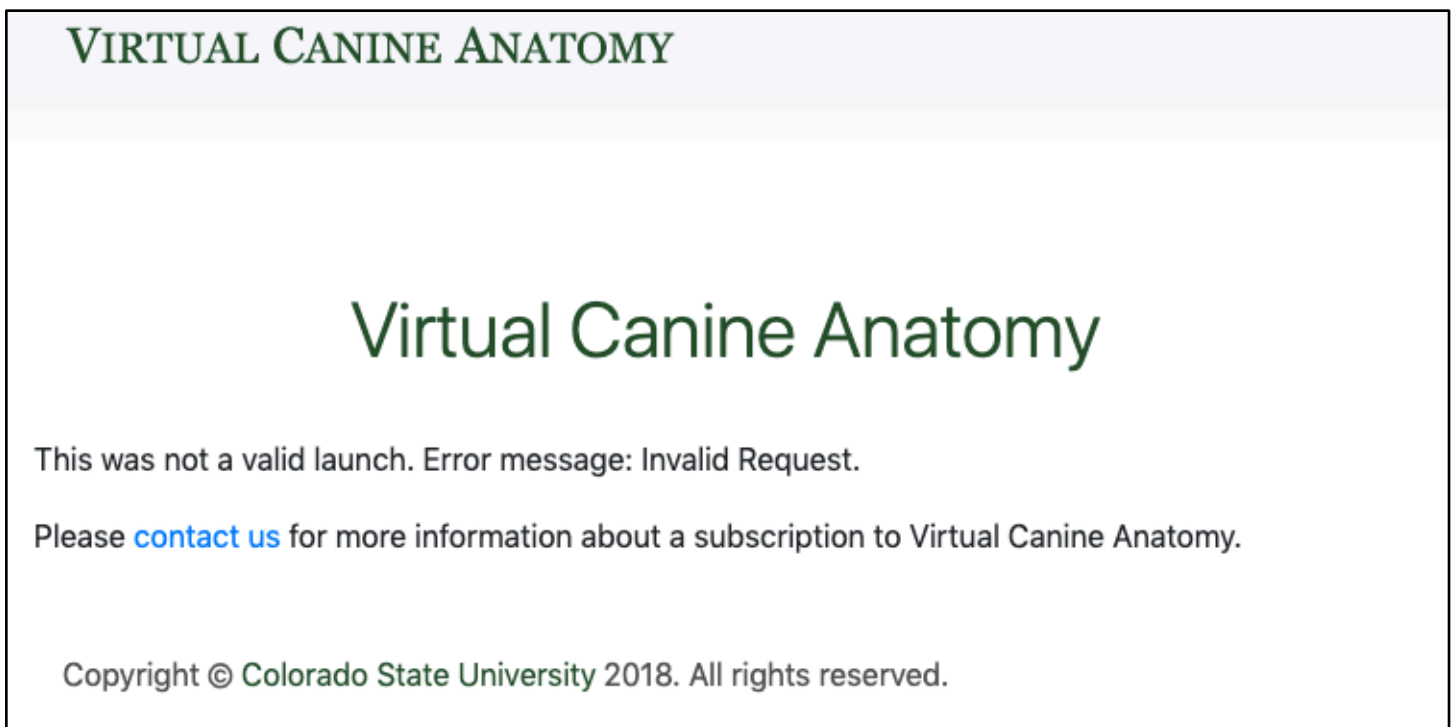
Error Pages

Invalid Request

In invalid request (Fig. 17) error occurs can occur for several reasons:

1. **The external learning tool must be opened in a new tab** or this error will show after the splash screen. When adding the tool, look for an option to “Load in a new tab,” “Open as External Resource,” or “Open in new window,” depending on your learning management system (LMS).
2. This error will also show if program is opened outside of an external learning tool in an LMS. For example, you will receive this error if you click on <https://www.cvmbs.colostate.edu/vca4> directly. If you do not have a subscription to Virtual Animal Anatomy or if you have a subscription and need assistance setting up the external learning tool please contact vvet.csu@gmail.com for more information.
3. This error may also occur if the program is left open for an extended period of time and the session times out. Close the program tab and reopen the program from the LMS.

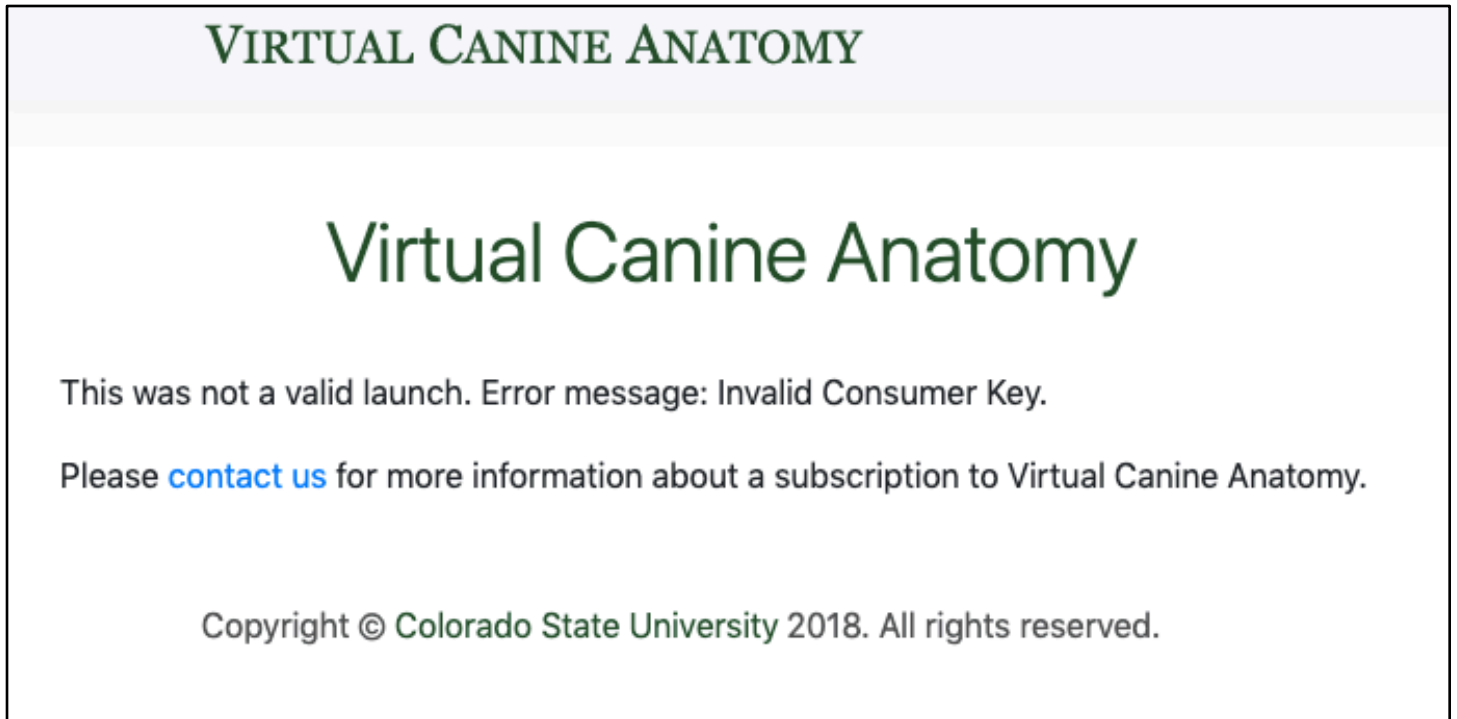
Fig. 17 – Invalid Request



Invalid Consumer Key / Invalid Secret

An invalid consumer key (Fig. 18) or invalid secret key error will occur if the consumer key or secret for your subscription is not correct. Please verify your credentials and contact us at vvet.csu@gmail.com if you continue to receive this error.

Fig. 18 – Invalid Consumer Key



Invalid Date

An invalid date error occurs if your subscription has ended. Please contact us at vvet.csu@gmail.com to renew your subscription.

Creating Assessment or Lecture Content Using the VAA

As a licensed user of the VAA, you are welcome to use images from the VAA for teaching and assessment purposes. Editing the images can be accomplished in Powerpoint, Paint, Google Docs, Word, and many other programs. Editing images in Powerpoint is preferred by the CSU team as it allows us to create questions on a single slide for presentation in class or in an assessment. We use Google Docs to initially create/edit these questions as a team in real time before finalizing the images/slides in Powerpoint and exporting it as an image file to the test software. If you are interested in using the images for a textbook or other high-resolution process, please contact us directly (vvet.csu@gmail.com) for permission and access to the high-resolution files. The videos referenced below can be viewed here: https://drive.google.com/drive/folders/1QPN9OC_TdG7s9w_k9P51M1mV1yCkmz3j?usp=sharing

Taking VAA screenshots

We recommend that if you are doing several screenshots at a time, then it is best you name them before exporting to another file system. **Always enlarge/zoom-in on images as much as possible before taking screenshots** to maximize the final image resolution.

For Mac: Press "command+shift+4" at the same time on the Mac to bring up the screenshot tool (crosshair mouse icon). Screenshots are automatically saved with a date/time stamp to the Desktop on Mac. See video

For PC: Use the Snipping Tool app "rectangular" mode to capture your images. See video

Using PowerPoint to remove text labels from highlighted VAA screenshots

Use the insert tool to insert a black color filled rectangle over the structure name. This works best if the structure name is against the black background of the image. If the structure name is on the specimen, then take your screen shot without the structure identified and use the "highlight" mechanism below to ID your structure. See video

Using PowerPoint to improve structure highlights in VAA screenshots

When the structure highlighting within the VAA programs needs more "pop" to allow students to see what is being indicated, feel free to create your own overlays by hand.

You can also include an arrow or two to help indicate tiny structures. We prefer using standard arrow shapes in colors that contrast well. Black, yellow, and sometimes white are good arrow color options. Recall that students who have vision limitations will have difficulty distinguishing certain color combinations. (black/red) and it is best to use high contrast (black with white/yellow) when developing these image sets. Students who have difficulty with high contrast images and text (ex. Irlen's syndrome) can use a screen shield as part of their accommodations to improve image quality. See video

Videos can be viewed here:

https://drive.google.com/drive/folders/1QPN9OC_TdG7s9w_k9P51M1mV1yCkmz3j?usp=sharing