

ORIGINAL RESEARCH ARTICLE – CLINICAL SCIENCE

Use of amniotic membrane transplantation in the treatment of venous leg ulcers

Isabelle Mermet, MD¹; Nathalie Pottier, MSc²; Jean Marie Sainthillier, MSc³; Carole Malugani, MSc²; Sandrine Cairey-Remonnay, MD¹; Stéphane Maddens, PhD^{2,4}; Didier Riethmuller MD, PhD^{5,6}; Pierre Tiberghien, MD, PhD^{2,4}; Philippe Humbert, MD, PhD^{1,3}; François Aubin, MD, PhD^{1,6}

1. Université de Franche Comté, Department of Dermatology, University Hospital and Medical School,
2. Cell and Tissue Engineering Department, Etablissement Français du Sang de Bourgogne-Franche-Comté,
3. EA 3183, Université de Franche Comté, IFR 133,
4. Inserm U645, Université de Franche-Comté, Etablissement Français du Sang, IFR133,
5. Université de Franche Comté, Department of Obstetrics and Gynecology, University Hospital and Medical School, and
6. EA 3181, Université de Franche-Comté, IFR 133, Besançon, France

Reprint requests:

François Aubin, Department of Dermatology, 2 Place Saint-Jacques, 25030 Besançon, France. Tel: 33 381218483; Fax: 33 381218482; Email: francois.aubin@univ-fcomte.fr

Manuscript received: October 2, 2006
Accepted in final form: March 17, 2007

DOI:10.1111/j.1524-475X.2007.00252.x

ABSTRACT

Amniotic membrane (AM), the most internal placental membrane, has unique properties including antiadhesive effects, bacteriostatic, wound protection and pain-reduction properties, as well as epithelialization initialization capacities. Furthermore, AM is widely available and less costly than other bioengineered skin substitutes. In a prospective pilot study, we evaluated the safety, feasibility, and the effects on healing of AM graft in 15 patients with chronic venous leg ulcers. AM grafts were prepared from placentas harvested during cesarean section. All grafted AM had adhered to the wound bed 7 days after being applied with a 100% engraftment rate. The percentage of granulation tissue increased significantly (from 17% on day 0 to 69% on day 14, $p < 0.0001$), along with a significant decrease of fibrinous slough (from 36% at day 0 to 16% at day 14, $p < 0.001$). A significant clinical response occurred in 12 patients (80%) including complete healing (20%) in three during the 3-month follow-up period. The ulcer surface area decreased significantly from a mean value (\pm standard deviation) of $4.59 \pm 2.49 \text{ cm}^2$ at baseline to $2.91 \pm 2.01 \text{ cm}^2$ on day 30 ($p < 0.001$). All patients experienced a significant reduction of ulcer-related pain rapidly after AM transplantation. No adverse events were recorded. AM transplantation seems to function as a safe substrate, promoting proper epithelialization while suppressing excessive fibrosis. Further advantages of biotherapy with AM are its easy and low-cost production, and that it can be applied as an ambulatory treatment without immobilization. AM transplantation may thus be considered to be an alternative method for treating chronic leg ulcers.

Healing of chronic leg ulcers constitutes a major clinical challenge not only because of their high prevalence, refractory nature, impact on patients' quality of life, morbidity, and mortality but also because of their economic consequences on the health care system.¹ For these recalcitrant leg ulcers, the current invasive treatment of choice is autologous skin graft (meshed split-thickness or pinch grafts). Despite possible ambulatory application, this usually requires hospitalization for several days and has risks of morbidity at the donor site.² Allogeneic and autologous skin substitutes have been successfully tested and approved by the US Food and Drug Administration.³ However, the costs of treatment with these skin substitutes remain too high for routine clinical use.

Fetal membranes are tissues of particular interest for several reasons, including their role in preventing rejection of the fetus and their early embryologic origin. These results may be explained by the peculiar immunologic characteristics and mesenchymal stem cell-like phenotype of

these cells. Amnion and chorion cells may represent an advantageous source of progenitor cells, with potential applications in a variety of cell therapy and transplantation procedures.⁴ The amniotic membrane (AM), the most internal placental membrane, is collected upon delivery by elective cesarian section and can be cryopreserved until its use as a biological bandage or as a substrate for epithelial growth in the management of various ocular surface conditions.⁵ AM may thus be considered as a biotherapeutic product composed of a single layer of epithelial cells that lie on a basement membrane, and of a nonvascular collagenous stroma. These three components give AM its beneficial properties, including antiadhesive effects, bacteriostatic properties, wound protection, pain reduction, epithelialization effects, and seems not to induce immunological reactions.⁵⁻⁸

Based on the efficiency observed in ophthalmology,⁵⁻⁸ we wished to evaluate the use of AM as a wound dressing in chronic leg ulcers. We thus performed a prospective pilot

feasibility study on 15 patients with chronic leg ulcers to evaluate the effects and the safety of AM transplantation.

MATERIALS AND METHODS

Patients

With the approval of our local ethics committees (Besançon University Hospital, France) and a written informed consent from the patients, 15 patients (five males and 10 females with a mean age of 79 years [range 74–82 years]) presenting with a venous leg ulcer were included in a prospective uncontrolled study. Inclusion criteria included: age 18 years or older; the presence of at least one venous ulcer with a reference surface of 5–25 cm²; no tendency for healing in the past 3 months despite conventional medical treatment; established venous insufficiency confirmed by venous duplex ultrasound; and the absence of significant arterial insufficiency assessed at clinical examination and by the presence of a systolic homolateral ankle-brachial index >0.85.⁹ Two patients with moderate arterial disease who had an ABPI of 0.85 were included. All the remaining patients had an ABPI >0.9. Patients were excluded if they had an unstable study ulcer (>30% reduction change in the wound area in the last month). Exclusion criteria were also inflammatory angiopathy and severe neuropathy in the reference leg, tendon, or bone exposure in the reference ulcer, abnormal hematologic parameters or severe systemic disease. The primary objective of our study was to evaluate the take rate of AM. The secondary objectives were the evaluation of the effect on different healing parameters (ulcer assessment), and the effects on ulcer-related symptoms.

AMs

AM grafts were prepared from placentas harvested during Cesarean section. Eligible mothers were accepted for AM donation after a medical interview and a written informed consent. Under sterile conditions, the amnion was separated from the chorion by blunt dissection and washed and stored for a minimum of 12 hours with a saline solution containing gentamicin 0.32 mg/mL (Panpharma, Fougères, France). The tissues were processed inside the clean room of the Cell, Tissue and Gene Therapy Unit (Etablissement Français du Sang, Besançon, France). Under a laminar air hood, the amnion was flattened onto sterile nitrocellulose paper (Schleider and Schuell microscience, Dassel, Germany), with the basement membrane surface up. The paper with the adherent membrane was then cut into 5 cm × 5 cm segments and stored at –80 °C in a sterile vial containing glycerol and modified Dulbecco's modified Eagle's medium (Cambrex, Verviers, Belgium), Penicilin/Streptomycin 1% (Cambrex, Verviers, Belgium), and dimethyl sulfoxide (DMSO) 10% (Braun Medical, Ludres, France). The risk of infectious disease transmission by the use of amnios membrane is considered to be similar as to blood products. However, due to processing in an "open" system from the recovery at maternity to the end of processing before delivery to the transplant center, three bacteriology tests were performed: one on the transport medium used to recover and ship the tissue, the washing

medium used before processing, and the conditioning medium used for cryopreservation. Quality controls included microbiological tests on all liquid media entering in contact with the tissue, histology analysis, testing maternal blood samples for infectious markers (HIV, HCV, HBV, HTLV, syphilis) and the presence of immunoglobulin G (IgG) and IgM antibodies against toxoplasmosis, Epstein-Barr virus (EBV), and cytomegalovirus (CMV), on the day of birth and after a quarantine period of at least 60 days.

Treatment procedure

Patients were treated as outpatients at the Wound Care Clinic (SCR, University Hospital, Besançon, France). The ulcer was cleaned and irrigated with saline. No debridement was performed. For the transplantation, AM was placed epithelium on the top and the basal membrane facing the surface of the ulcer (downward on the ulcer bed). The graft was then covered with a lipidocolloid dressing, Urgotul (Laboratoires Urgo, France). Compression bandages or compression stockings of level II or III were replaced after each application. Dressings were changed once weekly until either complete healing (full epithelialization) or 12 weeks of treatment. The study period duration was 3 months.

Ulcer assessment

The take rate of AM was documented 7 days after grafting by counting the number of AM adhering to the wound bed. Ulcer evaluation was performed at the time of transplantation and days 7, 14, 21, 30, 60, and 90 after AM transplantation. The parameters recorded during each visit included: diameters of the ulcer, percentages of granulation tissue and fibrinous slough on the ulcer bed, and aspect of the surrounding skin. Surface evaluation was calculated using Visitrak* (Smith and Nephew, Hull, UK) digital planimetry at each evaluation.¹⁰

Ulcer-related symptom assessment

Local pain score was assessed using a 101-point (0–100) visual analogue scale, with 0 indicating no pain and 100 the worst pain imaginable. In addition, analgesic drugs required were recorded and classed into three levels according to the WHO analgesic ladder.¹¹ Any adverse reactions were also recorded. Swabs for bacterial cultures were taken during each dressing change. Detection of serum antibody against class I human leukocyte antigen (HLA) antigen was performed monthly during the 3-month study period.

Statistical analysis

Because of the low number of patients ($n=15$) and the lack of normal distribution of values, we used a nonparametric ranking test, i.e., Friedman's test (paired data at each time point). A value of $p < 0.05$ was considered to be statistically significant (Statistica* software: www.statsoft.fr). The error bars in the graphs represent the standard deviation.

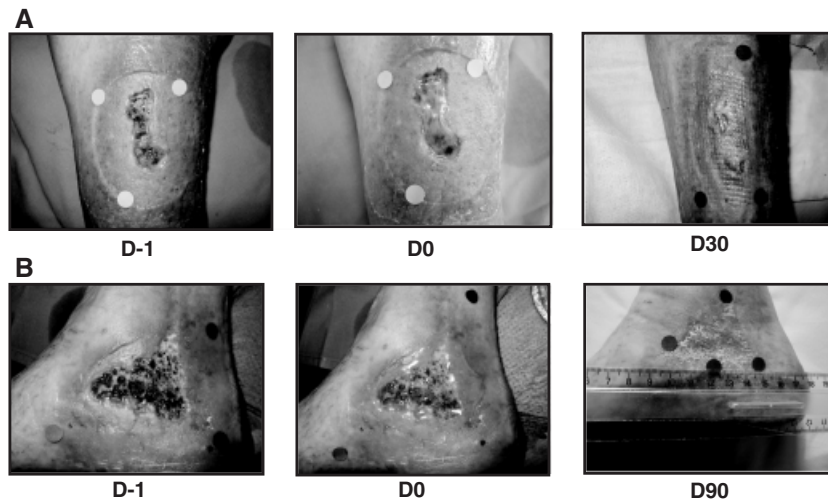


Figure 1. Use of amniotic membrane (AM) on leg ulcers: (A) patient 2, (B) patient 8. D-1, before AM transplantation; D0, immediately after AM transplantation.

RESULTS

Effect of AM on healing

In total, 15 AM were applied on 15 chronic venous leg ulcers. All these AM had adhered to the wound bed by 7 days after transplantation and the take rate of AM was 100% (Figure 1). All patients were followed up for 90 days after AM transplantation. The percentage of fibrinous tissue (mean \pm standard deviation) decreased significantly and rapidly (from $36 \pm 28\%$ on day 0 to $25 \pm 22\%$ by day 30, $p < 0.001$), and then increased to $37 \pm 28\%$ by day 90 (Figure 2A). Simultaneously, the percentage of granulation tissue increased significantly (from $16 \pm 24\%$ on day 0 to $56 \pm 33\%$ on day 30, $p < 0.0001$), and then decreased to $25 \pm 24\%$ by day 90 (Figure 2B). No significant effect was seen at day 7, but the greatest effect was observed at day 14 for both parameters (16 ± 18 and $69 \pm 28\%$, respectively). The percentages of fibrinous and granulation tissues at days 60 and 90 did not significantly differ from the baseline values. A significant clinical response, defined as at least a 50% reduction of the baseline ulcer surface area, occurred in 12 patients (80%), including three complete healing (20%) during the 3-month follow-up period. Treatment failure defined as an increase in ulcer size during the study period was observed in three patients (20%). The ulcer surface area decreased significantly from a mean value of $4.59 \pm 2.49 \text{ cm}^2$ at baseline to $2.91 \pm 2.01 \text{ cm}^2$ on day 30 ($p < 0.001$). Reepithelialization occurred from the wound margins, the so-called edge effect. In addition, despite an increase of fibrinous tissue along with a decrease of granulation tissue observed after day 30, the effect on healing stabilized, and there were no significant changes in ulcer dimensions from day 30 to 90 (Figure 2C).

Ulcer-related symptoms

After AM transplantation, the reduction in the level of pain (Figure 3A) was significant ($p < 0.0001$) from day 0 to 90 (36 ± 22.9 to 10 ± 13.6) as the level of analgesia

required by the patients (1.6–0.8) (Figure 3B). Pain relief was rapid and maximal at day 7 and then stabilized.

Safety of AM

No adverse events were recorded. AM was well tolerated and the surrounding skin did not show any irritative dermatitis in all patients. Bacterial colonization was not modified during the study and no wound infection was observed during the study period. Antibody to class I HLA antigen was detected in one patient (day 30) but was found to be negative 1 month later.

DISCUSSION

To our knowledge, there is no reported prospective study evaluating the potential of the AM in the treatment of chronic venous leg ulcers. However, the role of AM in the healing of ulcers of different origin has already been demonstrated.¹² Our study was designed as a proof-of-concept study with the intentions of testing the safety and the effect on healing of AM. Although the design of our study is not appropriate to conclude on the efficacy of AM, we demonstrate that AM transplantation can be useful and safe to promote epithelial healing of chronic venous leg ulcers. Indeed, compression bandages or compression stockings were applied after each AM application and it is well known that these procedures are effective in ulcer healing. The only conclusion that can be drawn is that AM graft is not deleterious in terms of promoting ulcer healing. As observed previously with other allogeneic skin substitutes,^{13,14} AM transplantation on the ulcer bed markedly and rapidly reduced fibrinous slough without any other debridement, promoted the formation of granulation tissue, and reepithelialization from the wound edges.¹⁵

In our study, a significant reduction (defined as at least 50%)¹⁶ of the baseline ulcer surface area occurred in 80% of the patients, including 20% of complete healing during the 3-month follow-up period. However, nine patients still had ulcers at the end of the study. In three patients, treatment failure could be related to a lack of observance of compression bandages or ulcer chronicity (duration > 2

years) and/or associated arterial disease. However, as shown previously,¹⁷ all patients experienced a rapid significant reduction of ulcer-related pain after AM transplantation.

During the 3-month follow-up, it was remarkable to note that the beneficial effect of AM on all the above parameters was maximal between days 14 and 30 after trans-

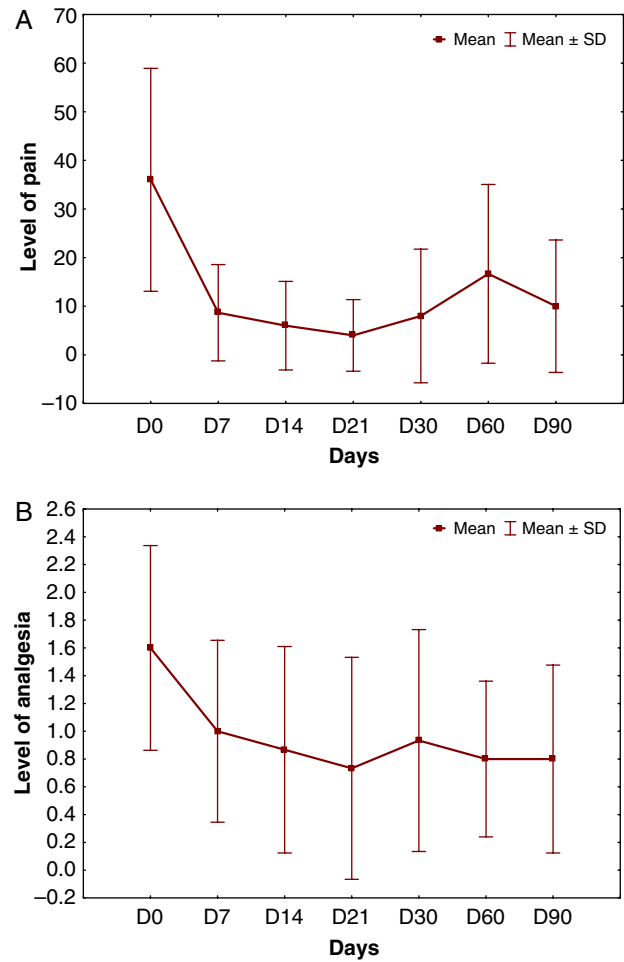
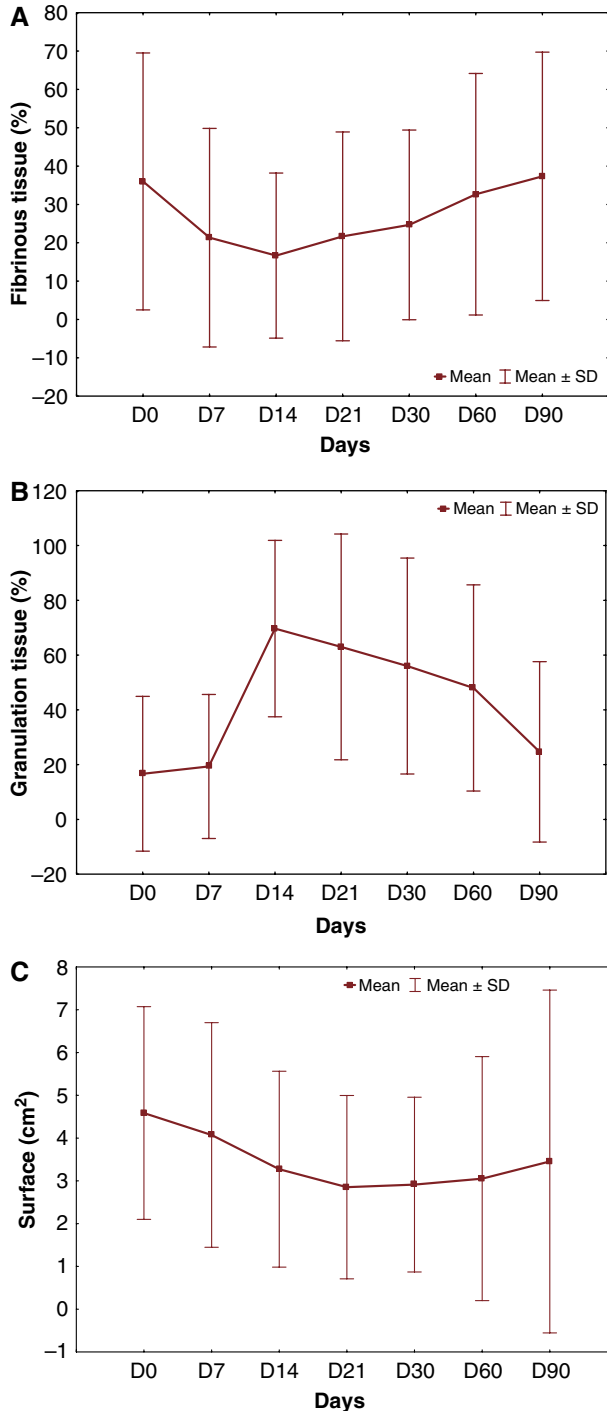


Figure 3. Pain-related assessment. The difference between the baseline values and values at days 7, 14, 21, 30, 60, and 90 was statistically significant ($p < 0.001$ by analysis of Friedman’s test). (A) level of pain; (B) level of analgesia according to the WHO ladder.⁸ The error bars in the graphs represent the standard deviation.

plantation and did not improve afterward. In addition, despite an increase of fibrinous tissue along with a decrease of granulation tissue after day 30, the reduction of the ulcer surface persisted. We do not have any clear

Figure 2. Evaluation criteria before and after amniotic membrane transplantation ($n=15$) in the period of 90 days. (A) fibrinous tissue; (B) granulation tissue; (C) ulcer area. The difference between the baseline values and values at days 14, 21, and 30 was statistically significant ($p < 0.001$ by analysis of Friedman’s test), but not with values at days 7, 60, and 90. As shown, despite an increase of fibrinous tissue along with a decrease of granulation tissue observed after day 30, the reduction of ulcer surface persisted. This suggested the initiation of a persistent wound-healing process induced by an amniotic membrane graft. The error bars in the graphs represent the standard deviation.

explanation for this observation but we can hypothesize that allogeneic AM does not survive in chronic wounds after 2–4 weeks. The longevity of another allogeneic skin substitute in venous leg ulcers has been investigated previously.¹⁸ Allogeneic DNA was detected 1 month after grafting but did not persist at 2 months. Altogether, these results indicate that allogeneic skin substitutes may benefit chronic leg ulcers as a temporary wound coverage or as a stimulus for wound healing.¹⁸ The fact that the healing benefit still persists after 4 weeks suggests the initiation of a persistent wound-healing process induced by an AM graft. The stimulatory effect on epithelialization from the ulcer bed and/or the wound edge is considered to be mediated by growth factors and progenitor cells released by AM.^{4,19} The lack of long-term persistence of AM in chronic leg ulcers might be mostly in relation to the highly inflammatory environment of the leg ulcer, although immune-mediated rejection could also be contributory. Despite a transient class-I HLA antibody response detected in one patient and strong class I expression observed in the amniotic epithelium, mesenchymal cells, and fibroblasts in cryopreserved AM,²⁰ AM seems to be an immune-privileged tissue and to contain immunoregulatory factors, including HLA-G and Fas ligands which may account for the fact that immunological rejection after AM transplantation has not yet been observed in an immune-privileged site: the eye^{6,20} vs. the skin here.

In conclusion, AM transplantation seems to function as a safe substrate, promoting proper epithelialization while suppressing excessive fibrosis. Further advantages of biotherapy with AM are its easy and low-cost production, and that it can be applied as an ambulatory treatment without immobilization. The cost of each 25 cm² AM was 120 Euros including processing, microbiological testing, and storing (i.e., 4.8 Euros/cm²). The market price of either autologous or allogeneic epidermal sheets graft varies from 5 to 15 Euros/cm² as compared with 0.03 Euros/cm² for hydrocolloid or alginate dressings. In addition, the longevity of AM is supposed to be about 3 weeks as compared with 5 days for conventional dressings. AM transplantation may thus be considered as an alternative method for treating chronic leg ulcers. However, because of the lack of long-term persistence of AM in the ulcer bed, it would be worth testing repeated applications of AM every 2–4 weeks as there is no associated morbidity. Altogether, the advantages and the wide availability of AM should allow cost-effective and efficient management of chronic leg ulcers. After treatment optimization (i.e., evaluation of repeated applications), a randomized study comparing AM with alternative allogeneic or autologous skin substitutes will be warranted to firmly establish the therapeutic potential associated with the use of AM to treat leg ulcers.

ACKNOWLEDGMENTS

We thank Dr. Brigitte Faivre for her clinical advice and methodological expertise regarding the design of this study. The authors confirm that there are no known conflicts of interest associated with this publication and there has been no significant financial support for this work that could have influenced its outcome.

REFERENCES

1. Patel NP, Labropoulos N, Pappas PJ. Current management of venous ulceration. *Plast Reconstr Surg* 2006; 117: 254S–60S.
2. Jones JE, Nelson EA. Skin grafting for venous leg ulcers. *Cochrane Database Syst Rev* 2005; 1: CD001737.
3. Horch RE, Kopp J, Kneser U, Beier J, Bach AD. Tissue engineering of cultured skin substitutes. *J Cell Mol Med* 2005; 9: 592–608.
4. Bailo M, Soncini M, Vertua E, Signoroni PB, Sanzone S, Lombardi G, Arienti D, Calamani F, Zatti D, Paul P, Albertini A, Zorzi F, Cavagnini A, Candotti F, Wengler GS, Parolini O. Engraftment potential of human amnion and chorion cells derived from term placenta. *Transplantation* 2004; 78: 439–48.
5. Gomes JA, Romano A, Santos MS, Dua HS. Amniotic membrane use in ophthalmology. *Curr Opin Ophthalmol* 2005; 16: 233–40.
6. Azuara-Blanco A, Pillai CT, Dua HS. Amniotic membrane transplantation for ocular surface reconstruction. *Br J Ophthalmol* 1999; 83: 399–402.
7. Dua HS, Azuara-Blanco A. Amniotic membrane transplantation. *Br J Ophthalmol* 1999; 83: 748–52.
8. Alio JL, Abad M, Scorsetti DH. Preparation, indications and results of human amniotic membrane transplantation for ocular surface disorders. *Expert Rev Med Devices* 2005; 2: 153–60.
9. Haute Autorité de Santé, Paris, France. Prise en charge de l'ulcère de jambe à prédominance veineuse hors pansement. Available at <http://www.has-sante.fr>. Accessed on November 30, 2006.
10. Gethin G, Cowman S. Wound measurement comparing the use of acetate tracings and Visitrak digital planimetry. *J Clin Nurs* 2006; 15: 422–7.
11. Ventafridda V, Saita L, Ripamonti C, De Conno F. WHO guidelines for the use of analgesics in cancer pain. *Int J Tissue React* 1985; 7: 93–6.
12. Singh R, Chouhan US, Purohit S, Gupta P, Kumar P, Kumar A, Chacharkar MP, Kachhawa D, Ghiya BC. Radiation processed amniotic membranes in the treatment of non-healing ulcers of different etiologies. *Cell Tissue Bank* 2004; 5: 129–34.
13. Phillips TJ, Gilchrist BA. Cultured epidermal grafts in the treatment of leg ulcers. *Adv Dermatol* 1990; 5: 33–48.
14. Kirsner RS, Falanga V, Eaglstein WH. The development of bioengineered skin. *Trends Biotechnol* 1998; 16: 246–9.
15. Limat A, French LE, Blal L, Saurat JH, Hunziker T, Salomon D. Organotypic cultures of autologous hair follicle keratinocytes for the treatment of recurrent leg ulcers. *J Am Acad Dermatol* 2003; 48: 7–14.
16. Tausche AK, Skaria M, Bohlen L, Liebold K, Hafner J, Friedlein H, Meurer M, Goedkoop RJ, Wollina U, Salomon D, Hunziker T. An autologous epidermal equivalent tissue engineered from follicular outer root sheath keratinocytes is as effective as split-thickness skin autograft in recalcitrant vascular leg ulcers. *Wound Repair Regen* 2003; 11: 248–52.
17. Martinez Pardo ME, Reyes Frias ML, Ramos Duron LE, Gutierrez Salgado E, Gomez JC, Marin MA, et al. Clinical application of amniotic membranes on a patient with epidermolysis bullosa. *Ann Transplant* 1999; 4: 68–73.
18. Phillips TJ, Manzoor J, Rojas A, Isaacs C, Carson P, Sabolinski M, Young J, Falanga V. The longevity of a

- bilayered skin substitute after application to venous ulcers. *Arch Dermatol* 2002; 138: 1079–81.
19. Beele H, de la Brassine M, Lambert J, Suys E, De Cuyper C, Decroix J, Boyden B, Tobback L, Hulstaert F, De Schepper S, Brissinck J, Delaey B, Draye JP, De Deene A, De Waele P, Verbeken G. A prospective multicenter study of the efficacy and tolerability of cryopreserved allogenic human keratinocytes to treat venous leg ulcers. *Int J Low Extrem Wounds* 2005; 4: 225–33.
 20. Kubo M, Sonoda Y, Muramatsu R, Usui M. Immunogenicity of human amniotic membrane in experimental xenotransplantation. *Invest Ophthalmol Vis Sci* 2001; 42: 1539–46.