COMPANION ANIMAL HEALTH

Laser Therapy for Acute Conditions

enovis™

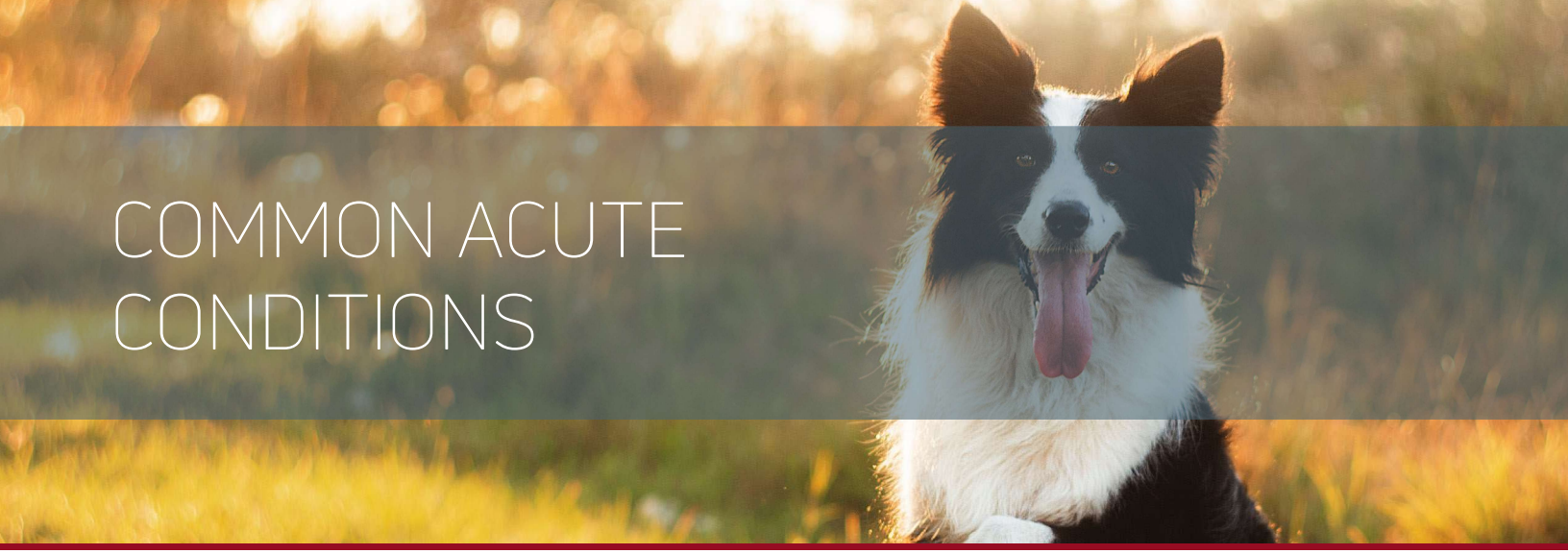

COMMON ACUTE CONDITIONS

Laser therapy quickly reduces inflammation and can produce impressive results for acute conditions. For those new to laser therapy, the easiest way to get started implementing the technology is with acute conditions (especially wounds and post-surgical incisions) because of how fast and easy treatments are to administer and how significantly they impact recovery.

Photobiomodulation is one of the most versatile tools in the pain management toolbox. Here is a long list of common acute conditions that laser therapy can help with:

- Abscesses
- Amputation (post-op)
- Aural hematoma (post-op)
- Burns
- Cranial cruciate ligament repair (post-op)
- Cystotomy (post or intra-op)
- Declaw (post-op)
- Degloving injury
- Enterotomy (post or intra-op)
- Hematoma (post-op)
- Incisional healing
- Orthopedic/Fracture repair (post-op)
- Post-operative pain relief
- Ischemia/reperfusion injury
- Skin graft (post-op)
- Spay/Neuter (post-op)
- Wounds
- Post-dental cleaning (pain management)
- Tooth extractions (pain management)
- Cystotomy (post or intra-op)
- Lower urinary tract infection
- Urinary tract obstruction (pain management)
- Fracture healing (delayed or nonunion)
- Anal sacculitis
- Demodicosis (pain management)
- Eosinophilic granuloma complex
- Feline acne
- Hygroma
- Infections (bacterial and fungal)
- Interdigital cyst
- Juvenile cellulitis
- Lick granuloma
- Mastitis
- Non-inflammatory alopecia
- Otitis
- Perianal fistula
- Pododermatitis
- Pyoderma
- Pyotraumatic dermatitis
- Skin graft (post-op)
- Vasculitis
- Diarrhea
- Anal gland sacculitis
- Upper respiratory infection

CASE STUDY

Necrotizing Wound, Domestic Short Hair

Author(s): "Ms. Polly Keene, RVN, VPAC, CET, Bridwater, United Kingdom"

Signalment: Feline, 5yo, M/N, Domestic Short Hair

History: The patient presented with necrosis and tissue loss involving the lower back and tail base after disapppearing for seven days

Exam Findings & Initial Treatment: Physical examination revealed a cat bite abscess at the base of the tail. The patient was sedated to clean the wounds, given Convenia (cefovecin sodium) and sent home with intraoral buprenorphine and NSAID for 24 hours.

Laser Treatment: The preset "superficial wound" protocol was used, delivering a fluence of - 6J/cm^2 with a non-contact technique.

Frequency of Treatment: Once weekly for the first six weeks, then tapered to every other week as wounds improved

Other Treatments: Systemic antibiotics, wound lavage, and hydrogel was used in the deeper wounds near the tail base.



CASE STUDY

Laser Therapy Siamese Cat Recovers From Lip Ulceration

Case courtesy of: Dr. Huseman, Bluffton Animal Clinic, Bluffton, IN

Signalment: Feline, 1yo, FS, Siamese

History: Patient visited a spay/neuter clinic and came home after procedure sneezing, rapidly progressed to lethargy, inappetence, and ulceration of the nose and lips. Patient was uncomfortable and only able to lay sternly at rest.

Diagnostics and Exam Findings: Due to owner financial constraints, initial diagnostics were limited. Upper respiratory infection (likely viral) was main rule-out as cause of symptoms.

Laser Treatment Details: 360 total joules administered at 3-4W to entire area of nose, sinuses, mouth, and gums in off-contact manner.

Laser Treatment: Daily for three consecutive days

Frequency of Treatment: A total of 34 treatments have been done so far, ranging from daily to every 2 to 3 days.

Other Treatments: Subcutaneous fluid therapy; antibiotics (Excenel®); supportive care (cleaning/wiping face and nose); tube feeding until patient started eating on her own.

Comments: Two hours after the first laser treatment, nasal discharge stopped and dried up, the patient was breathing noticeably easier, and was even taking a nap in lateral recumbency. By day two, the patient was active, vocalizing, and eating.

CASE STUDY

Osteomyelitis, Doberman Pinscher

Author(s): "Mile High Veterinary Hospital, Aurora, CO"

Signalment: 2yo, M/N, Doberman Pinscher, "Dax"

Presentation: History of neglect (foot injury originally from strangulation with chain); third and fourth toes had previously been amputated, but the surgery site never healed and painful granulation tissue was now present. Dog was significantly lame on right hind leg. Radiographs suggested osteomyelitis. Surgeon recommended amputation, but owners wished to try laser therapy as a last resort to save the limb.

Treatment Details: Bacterial C&S was submitted and pending results, patient was started on Clavamox and laser therapy was instituted. 196 total joules were delivered to affected area at 2W; EOD for five treatments, then every five days for six additional treatments.

Ultimately, C&S grew multiple severe antibiotic resistant bacteria including Methicillin Resistant Staph, Pseudomonas aeruginosa, and Morganella morganii. All were resistant to Clavamox. Patient was started on appropriate antibiotic therapy 7 days later, after clinical improvement already noted

Treatment Results: "*Dax's exceptional recovery was most likely due to a combination of therapies, but since he did not start appropriate antibitic therapy until seven days after the beginning of our treatment course and we saw significant improvement only two days after the first use of the Class IV Therapy Laser, we suspect that the Companion Laser was primarily responsible for his dramatic response to treatment.*" -Dr. Waskow



CASE STUDY

Otitis, Mixed Breed Canine

Author(s): "Woodland Springs Veterinary Hospital, Ft. Worth, TX"

Signalment: 10yo, M/N, Mixed Breed Canine, 30 lbs

Presentation: Left ear canal swollen with yellow discharge.

Diagnostics: Cytology revealed bacterial and yeast otitis.

Treatment Details: 307.5 total Joules administered to superficial component and 690 total Joules delivered to deep component at 3.5W; Frequency of two treatments, two consecutive days. Appropriate topical therapy was used as well.

Treatment Results: Otitis resolved with ear much less swollen and pruitic after treatment.

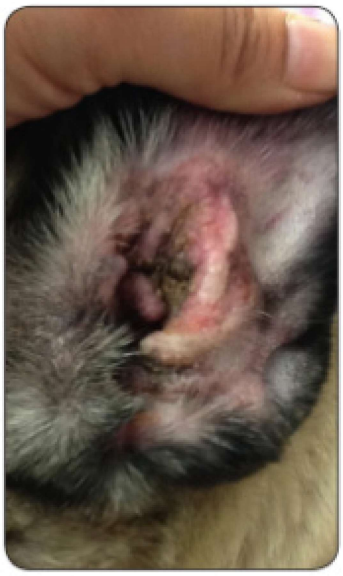

Day 1

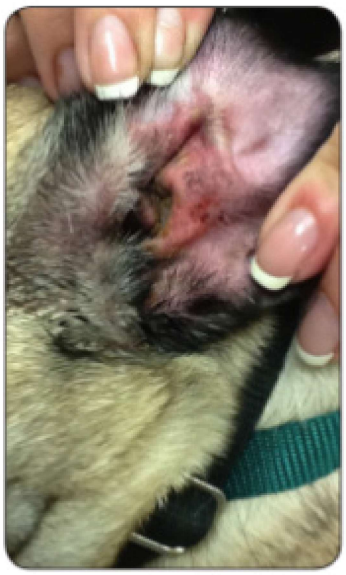

Day 2

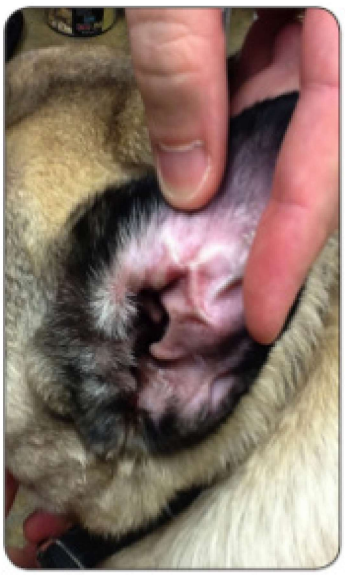

Day 14

CASE STUDY

Severe Demodicosis, American Staffordshire Terrier

Author(s): "Baring Boulevard Veteinary Hospital, Reno, NV"

Signalment: 2yo, M/N, American Staffordshire Terrier, "Bosley"

Presentation: Presented after being taken in by Animal Control, received single dose of Ivermectin SC injection and had received Prednisone 20mg PO SID for unknown duration. DVM diagnosed severe Demodicosis and discontinued steroids, started Cephalexin and benzoyl peroxide bathing/shampoo, daily Ivermectin PO and laser therapy.

Treatment Details: Started laser therapy on 1/29. Approximately 85% of total skin surface treated for total dose of 16,200 J at 6W over ~3,200 cm2 (5 J/cm^2).

Every other day treatment for 5 treatments, then weekly through 3/1 when all lesions resolved.

Treatment Results: "*Patient's skin lesions/disease showed rapid reduction in erythema, crusting, and pruritis leading to marked improvement in patient's comfort level while managing/treating generalized demodicosis/pyoderma. Overall healing process was dramatically accelerated by laser therapies and most importantly comfort was markedly improved throughout laser therapy period.*" – Dr. Sara Hogel