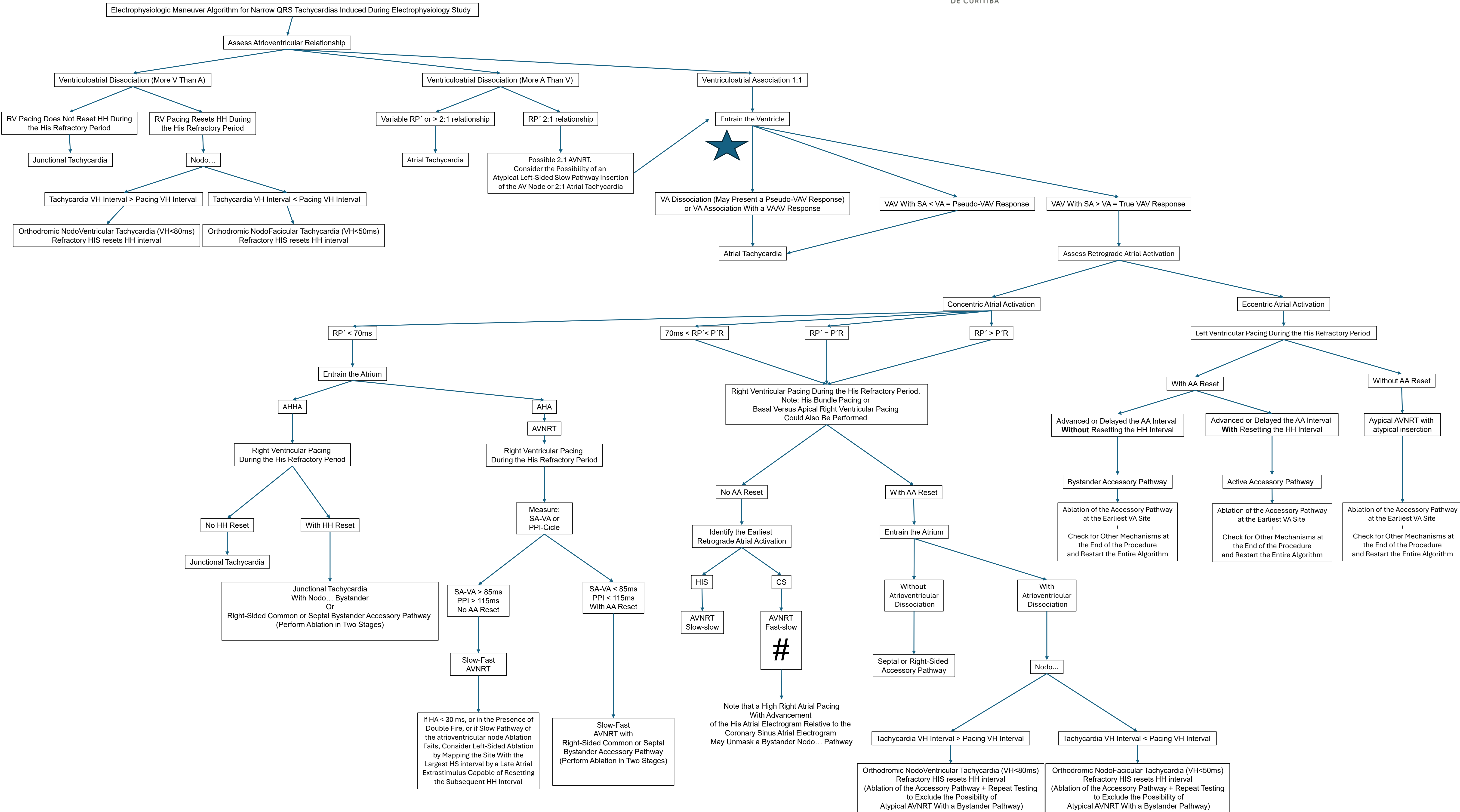


Narrow QRS Algorithm by Alessandro Kraemer



#

Note that in Fast-Slow AVNRT, the AH Interval During Tachycardia Will Be Longer Than the AH Interval During Sinus Rhythm. (An AH Interval During Tachycardia Shorter Than During Sinus Rhythm Should Raise Suspicion of a Nodofascicular Pathway Mimicking Fast-Slow AVNRT.)