



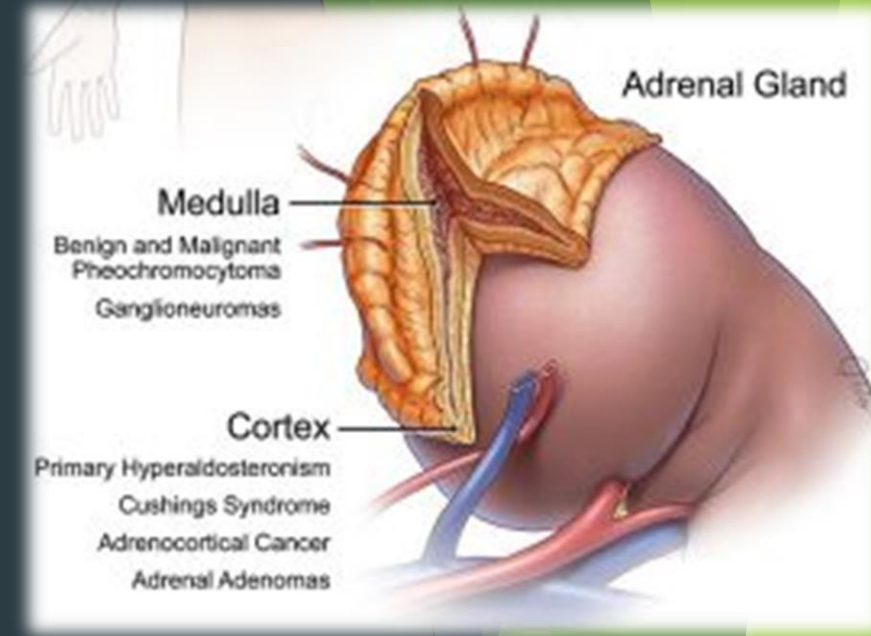
Recurrent Phaeochromocytoma

Dr NG Tam Man, Department of Surgery, Pok Oi Hospital

HKAES Aug 2022

Introduction

- ▶ Phaeochromocytoma is a type of catecholamine secreting tumour arising from chromaffin cells of the adrenal medulla
- ▶ Common presentation
 - ▶ Young onset hypertension
 - ▶ Incidentaloma
- ▶ Diagnosis based on biochemical test together with imaging
- ▶ Treatment
 - ▶ Always for resection after appropriate medical preparation if resectable.
- ▶ What if it is difficult to resect?



Our case

▶ Ms Su, F/37

- ▶ Known history of right pheochromocytoma with open operations done in 2006 and 2008 (age 22 & age 24) in China
- ▶ No evidence of recurrence from CT in 2011
- ▶ No detail or report available
- ▶ No genetic test was performed

- ▶ Defaulted all FU since 2014
- ▶ Came to Hong Kong in 2016

- ▶ Had an uncomplicated vaginal delivery in 2014

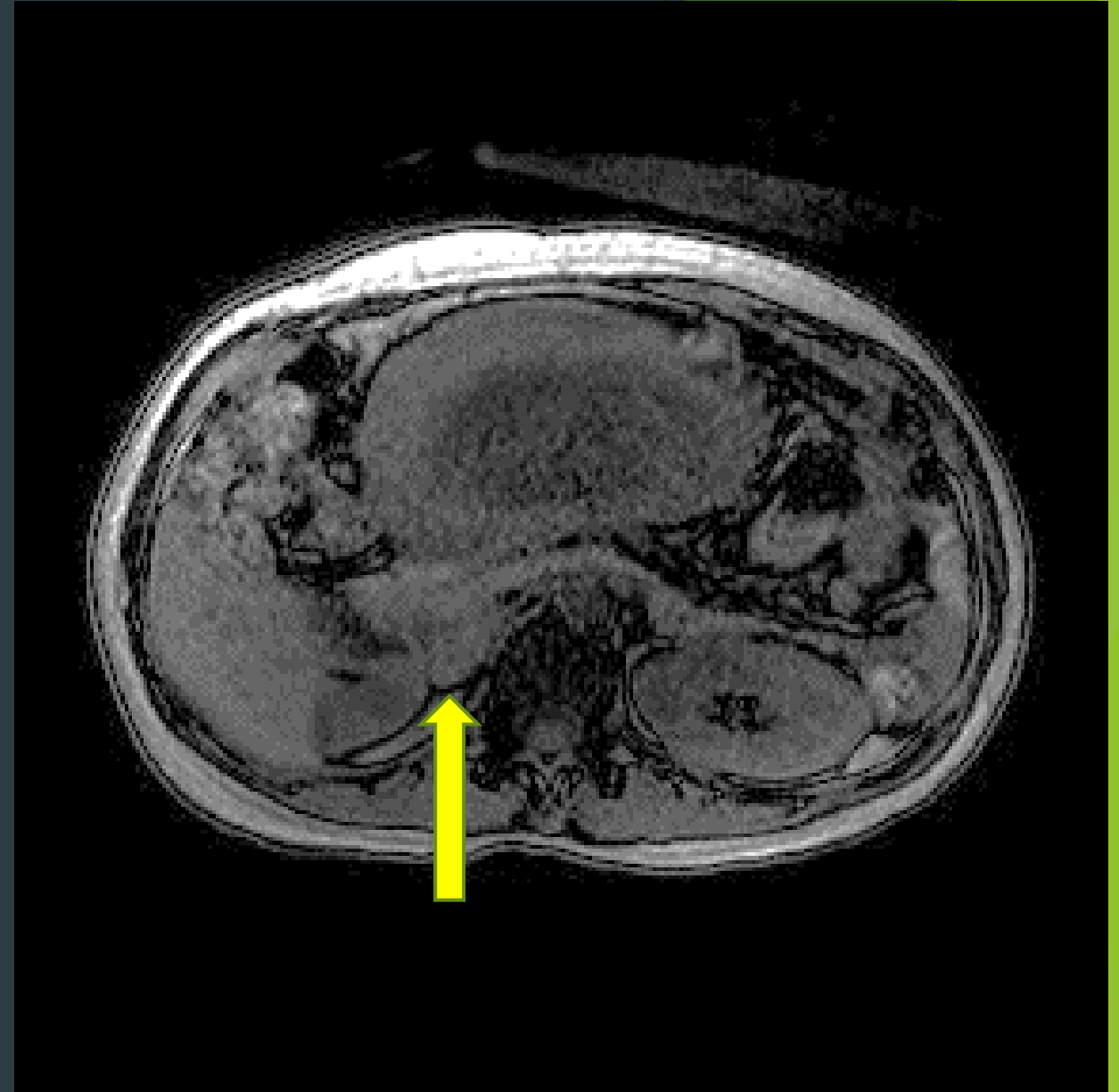
- ▶ c/o headache during 2nd pregnancy in 2019
 - ▶ Associated with occasional palpitation
 - ▶ No sweating
 - ▶ No hypertension

Endocrine Workup

- ▶ SBP 92-94mmHg, DBP 50-60mmHg, P~70/min
- ▶ 24hr urine metanephrine 80 (<271nmol/day)
- ▶ 24hr urine normetanephrine 1218 , 3.8x upper limit (<320 nmol/day)

Imaging workup

- ▶ MRI abdomen performed (due to pregnancy): 29/10/2019
 - ▶ A ~2.1cm lesion is seen at the right suprarenal region, appearing T1/2 minimally hyperintense to muscle.
- ▶ Discussed in combined Xray meeting
 - ▶ Suspicious 2.5cm x 1cm nodule seen at R paravertebral/ sympathetic trunk region, ?paraganglioma
 - ▶ Remnant R adrenal gland tissue seen
 - ▶ Overall very suspicious for residual paraganglioma

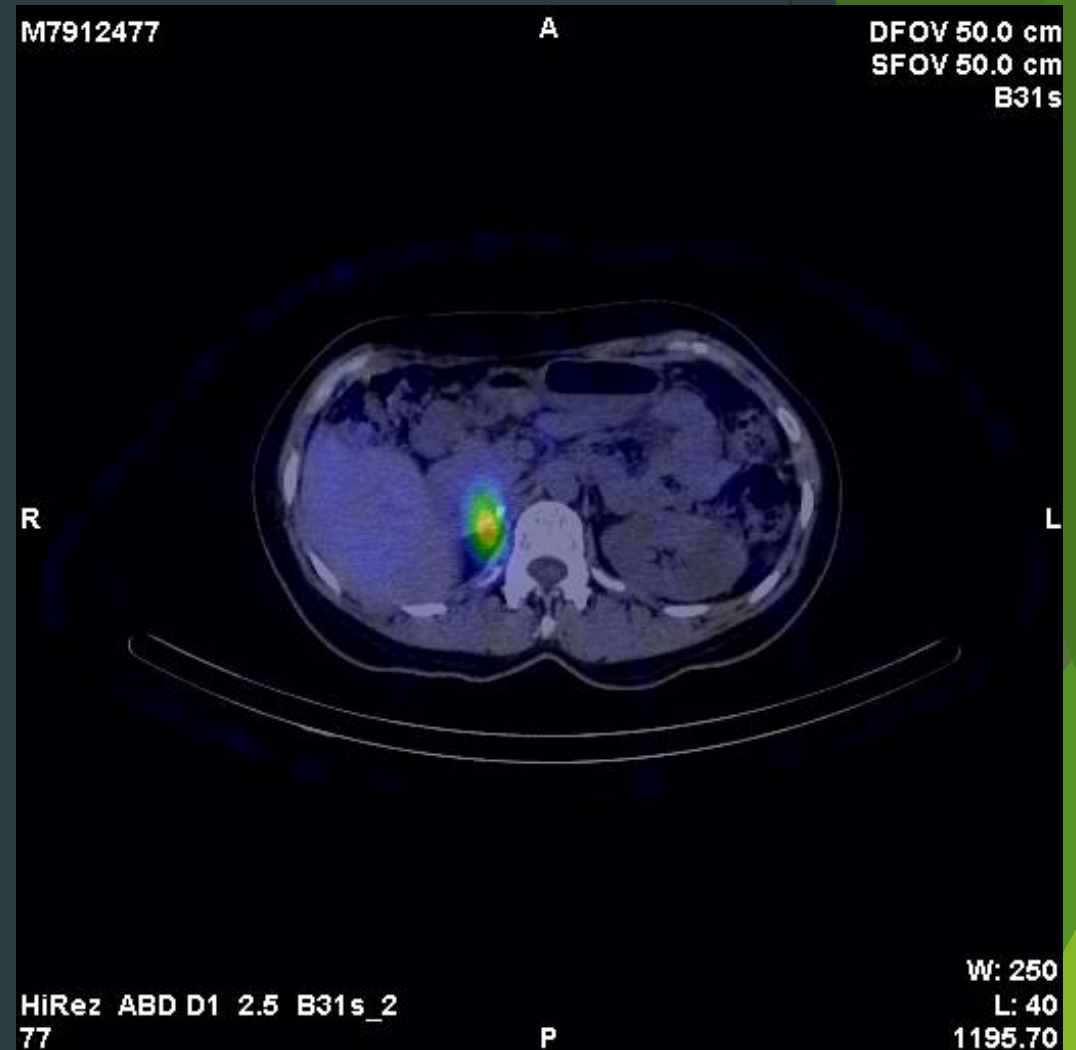


Progress during pregnancy in 2019-2020

- ▶ Discussed with patient for management plan
- ▶ However patient opted to continue the pregnancy
- ▶ Throughout the pregnancy, no symptoms and BP was on low side
 - ▶ No room for alpha blockage +/- beta blocker
- ▶ Patient eventually had an elective caesarean section in Feb 2020

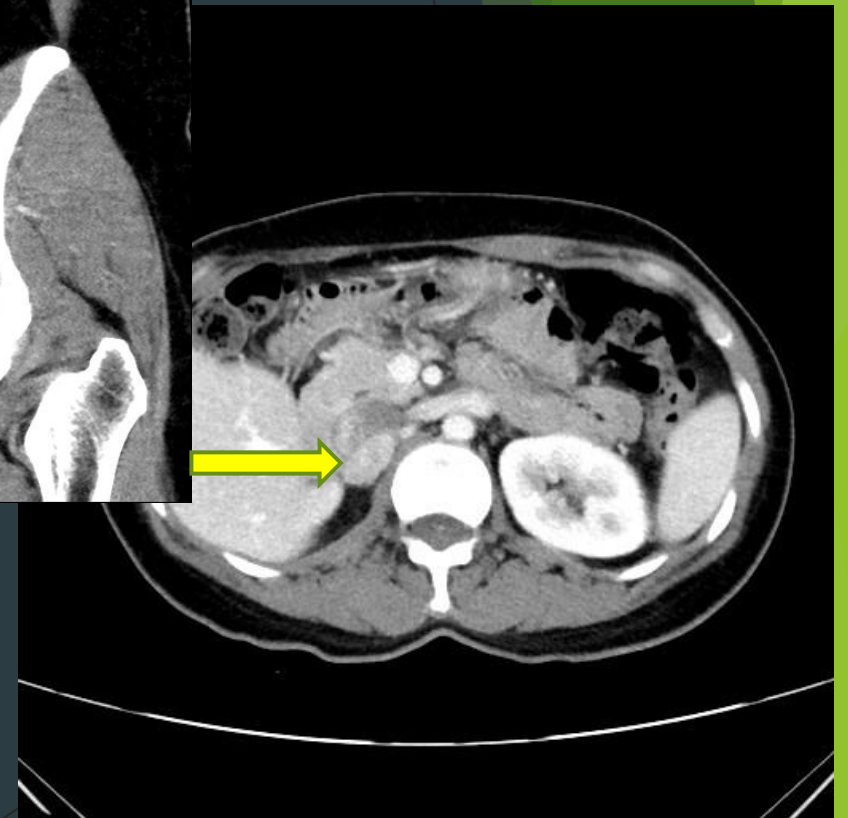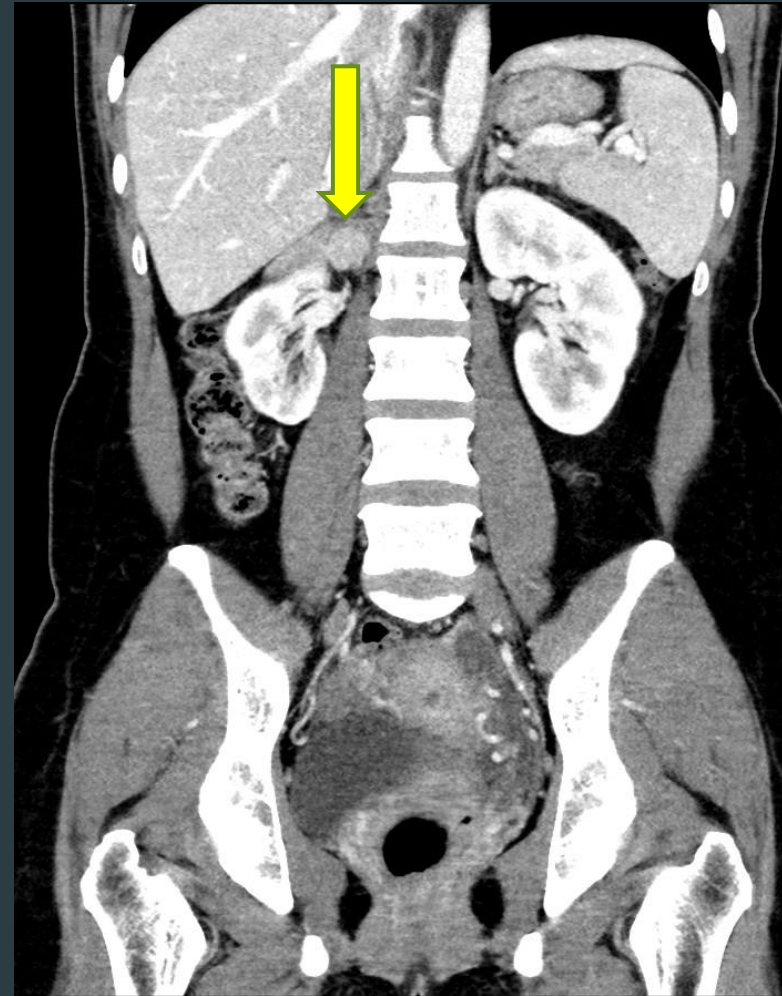
Continue Workup in 2020 after delivery

- ▶ Normetanephrine, 24hr Urine High 1162 nmol/day (<320)
- ▶ MIBG scan done in Dec 2020
 - ▶ MIBG-avid right suprarenal mass, in keeping with solitary pheochromocytoma. No MIBG-avid lesion elsewhere; no evidence of metastasis.



Progress in 2021

- ▶ Another contrast CT was performed to delineate the anatomy better before decide for possible surgical treatment
- ▶ CT 9/2021



Progress in 2022

▶ Octreotide scan in 3/2022

1. The known right suprarenal mass is marked I-131 MIBG avid and only mildly octreotide-avid. It indicates the lesion has low somatostatin receptor level. Overall finding is most compatible with residual or recurrence of right pheochromocytoma.
2. No other areas of increased uptake to suggest metastatic disease.

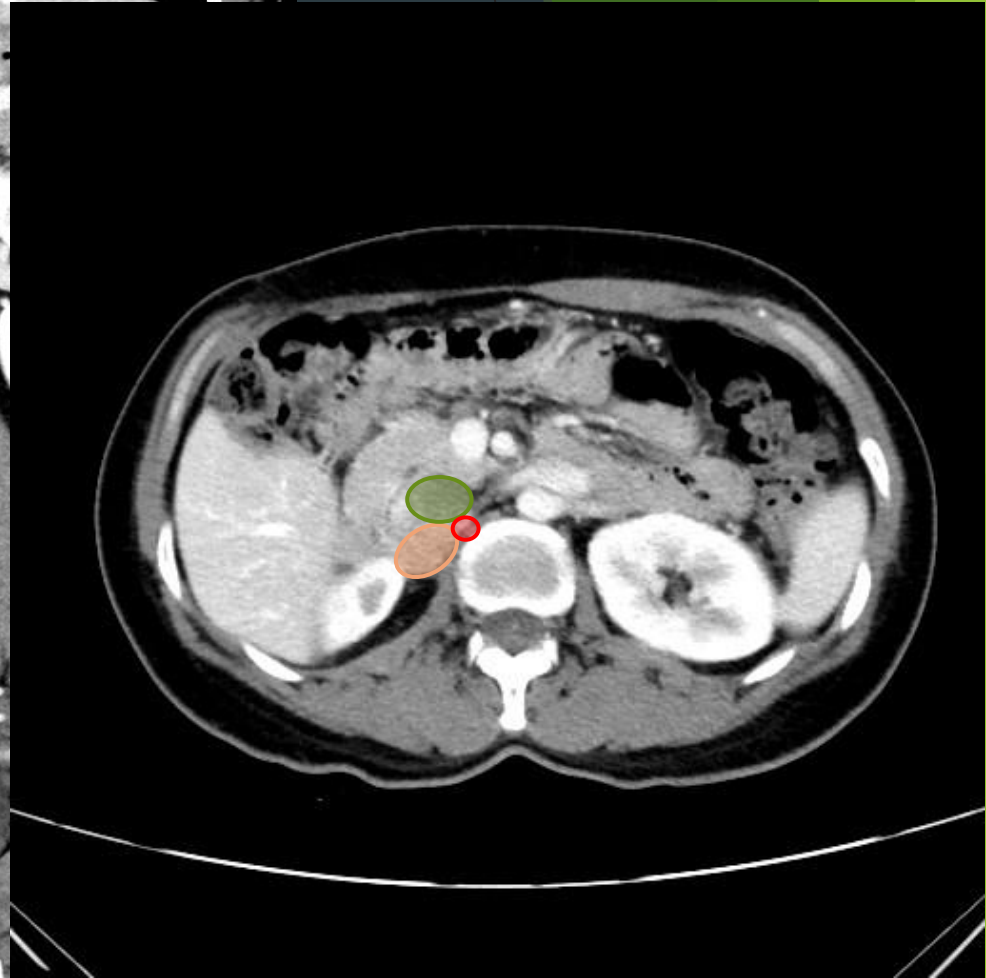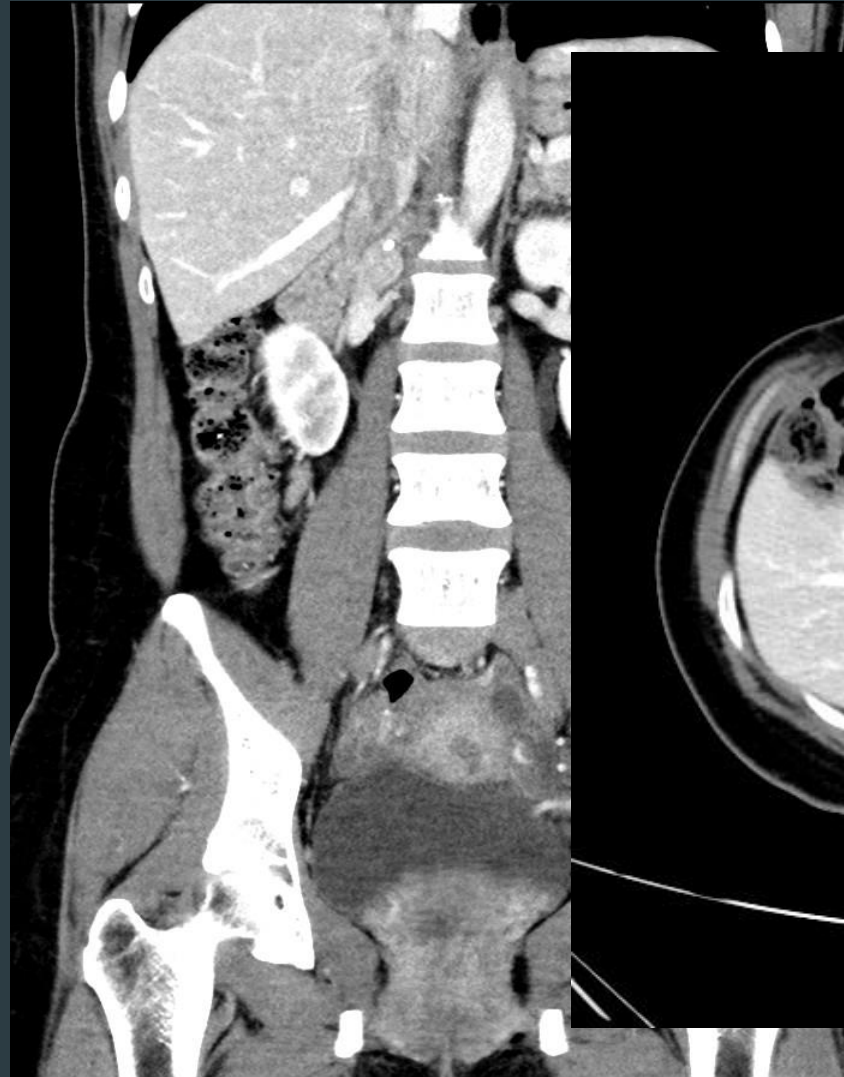
Consideration after previous workup

1. Surgery

- ▶ Anticipate major difficulty in surgery
 - ▶ Small tumour bulk
 - ▶ Two previous operations before, expected to have dense adhesion
 - ▶ Anatomically closed to IVC, R renal hilum
 - ▶ High chance of residual tumour, significant bleeding and injury to surrounding organs

Consideration for Surgery

- ▶ We were considering retroperitoneal approach if patient opted for surgery
 - ▶ Previous two operations were transperitoneal approach



Consideration after previous workup

2. Radionuclide treatment (palliative intent)

- ▶ Therapeutic MIBG (meta-iodobenzylguanidine)
 - ▶ Already confirmed MIBG avid in 12/2020
- ▶ Peptide Receptor Radionuclide Therapy (PRRT), not suitable as low somatostatin receptors

3. Cytotoxic chemotherapy

- ▶ Not indicated as now asymptomatic and low tumour load, static disease for years

4. Targeted therapy - Sunitinib

5. ?local ablative therapy

Treatment plan

- ▶ Multidisciplinary approach with endocrinologists, radiologists, Nuclear medicine radiologists and surgeons
- ▶ Surgery would be 1st line treatment
- ▶ Radionuclide treatment as 2nd line
- ▶ As patient is asymptomatic, can also have serial monitoring by imaging and biochemical test

Treatment Plan

- ▶ After discussion with patient and relatives with multiple parties
 - ▶ refused to have surgery and opted for therapeutic MIBG

Current plan - tMIBG

- ▶ Explanation from nuclear medicine
 - ▶ most of the time (95%) MIBG therapy is not curative.
 - ▶ About 25% may show tumour shrinkage. That may be seen up to 1 year after therapy
 - ▶ Overall 80% the treatment is helpful in controlling the tumour, i.e. 20% patients the treatment is not effective
 - ▶ 50% patients may show reduced hormone secretion

Therapeutic MIBG

- ▶ Principle
 - ▶ MIBG (meta-iodobenzylguanidine) has structural similarity with noradrenaline and therefore high affinity to, and uptake in, chromaffin cells.
 - ▶ Radioactive I^{131} is attached to MIBG molecule to achieve local radiation to the tumour
- ▶ Preparation
 - ▶ Need pre-treatment oral saturated solution of potassium iodide to prevent the thyroidal uptake of radioactive iodide
- ▶ Complication
 - ▶ Myelosuppression, haematological malignancy, renal impairment, hypothyroidism
- ▶ Multiple small series showed the ability of tMIBG to achieve symptoms palliation, tumour regression or stabilization of disease
- ▶ No consensus on the dosage and interval
- ▶ Response rates varies

Current progress

- ▶ Patient is still pending the tMIBG treatment
- ▶ We will continue to review on her progress

Point to discuss

- ▶ Any other treatment option
- ▶ Surgical approach if proceed with surgery
- ▶ Possibility for local ablative therapy