



Owner's Copy

## PennHIP Report

Referring Veterinarian: Dr Daniel Kelleher	Clinic Name: Broadview Animal Hospital of Dover
Email: info@broadviewdover.com	Clinic Address: 67 Knox Marsh Road Dover, NH 03820
	Phone: (603) 740-1800
	Fax:

## Patient Information

Client: Levesque, Becca	Tattoo Num:
Patient Name: FINLAYSON'S BETTY BOOP BLACK BEAUTY	Patient ID: 255828
Reg. Name: FINLAYSON'S BETTY BOOP BLACK BEAUTY	Registration Num: SS37348401
PennHIP Num: 185239	Microchip Num: 900235000130625
Species: Canine	Breed: LABRADOR RETRIEVER
Date of Birth: 14 Aug 2022	Age: 6 months
Sex: Female	Weight: 50.8 lbs/23 kgs
Date of Study: 20 Feb 2023	Date Submitted: 20 Feb 2023
Date of Report: 21 Feb 2023	

## Findings

Distraction Index (DI): Right DI = 0.46, Left DI = 0.42.

Osteoarthritis (OA): **No radiographic evidence of OA for either hip.**

Cavitation/Other Findings: No cavitation present.

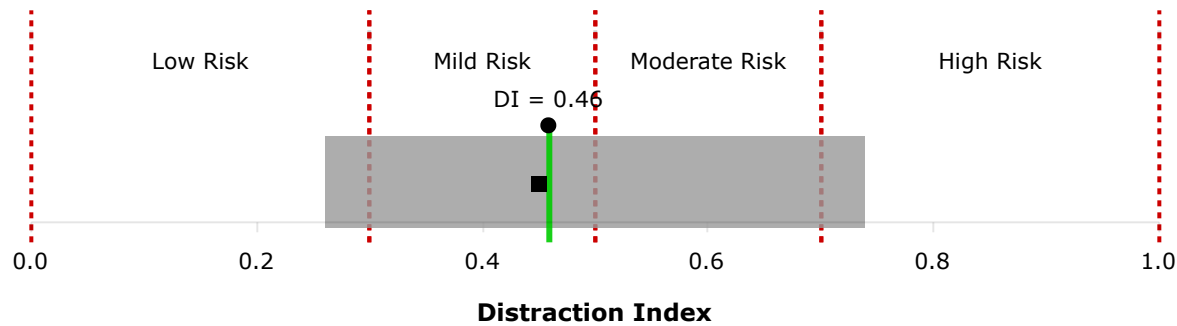
## Interpretation

Distraction Index (DI): The laxity ranking is based on the hip with the greater laxity (larger DI). In this case the DI used is 0.46.

OA Risk Category: The DI is between 0.31 and 0.49. This patient is at mild risk for hip OA.

Distraction Index Chart:

### LABRADOR RETRIEVER



**BREED STATISTICS:** This interpretation is based on a cross-section of 40511 canine patients of the LABRADOR RETRIEVER breed in the AIS PennHIP database. The gray strip represents the central 90% range of DIs (0.26 - 0.74) for the breed. The breed average DI is 0.45 (solid square). The patient DI is the solid circle (0.46).

**SUMMARY:** The degree of laxity (DI = 0.46) falls within the central 90% range of DIs for the breed. This amount of hip laxity places the hip at a mild risk to develop hip OA. **No radiographic evidence of OA for either hip.**