

Preclinical Evaluation of the Novel Small-Molecule Integrin $\alpha 5 \beta 1$ Inhibitor JSM6427 in Monkey and Rabbit Models of Choroidal Neovascularization

Grit Zahn, PhD; Dörte Vossmeier, PhD; Roland Stragies, PhD; Margaret Wills, MS; Corinne G. Wong, PhD; Karin U. Löffler, MD; Anthony P. Adamis, MD; Jochen Knolle, PhD

Objective: To evaluate the pharmacologic activity and tolerability of JSM6427, a potent and first selective small-molecule inhibitor of integrin $\alpha 5 \beta 1$, in monkey and rabbit models of choroidal neovascularization (CNV).

Methods: JSM6427 selectivity for $\alpha 5 \beta 1$ was evaluated by in vitro binding assays while the ability of JSM6427 to inhibit CNV was investigated in a laser-induced monkey model and a growth factor-induced rabbit model. Intravitreal injections of JSM6427 (100, 300, or 1000 μg) or vehicle were administered immediately after the CNV induction procedure and at weekly intervals for 4 weeks. Fluorescein angiography was performed weekly. Ocular tolerability was evaluated ophthalmoscopically and histologically in both models; additional assessments in monkeys included electroretinography, biomicroscopy, pathological examination, and analysis of JSM6427 pharmacokinetics.

Results: JSM6427 was highly selective for the $\alpha 5 \beta 1$ -fibronectin interaction. Weekly intravitreal injections of JSM6427 resulted in a statistically significant dose-dependent inhibition of CNV in laser-induced and growth factor-induced models without any ocular JSM6427-related adverse effects. JSM6427 was cleared through the systemic circulation with no evidence of systemic accumulation.

Conclusions: Intravitreal JSM6427 provided dose-dependent inhibition of CNV in monkey and rabbit experimental models.

Clinical Relevance: JSM6427 may provide a new approach for the treatment of ocular neovascular diseases such as age-related macular degeneration in humans.

Arch Ophthalmol. 2009;127(10):1329-1335

Author Affiliations: Jerini AG, Berlin, Germany (Drs Zahn, Vossmeier, Stragies, and Knolle); Jerini Ophthalmic, New York, New York (Drs Zahn and Adamis); Charles River Laboratories, Preclinical Services, Sparks, Nevada (Ms Wills); Sclera LLC, Carlsbad, California (Dr Wong); and Department of Ophthalmology, University of Bonn, Bonn, Germany (Dr Löffler). Dr Knolle is now in private practice in Frankfurt, Germany.

THE MORE VISUALLY DISABLING neovascular form of age-related macular degeneration (AMD) is defined by choroidal neovascularization (CNV) and associated vascular leakage, retinal pigment epithelial (RPE) cell atrophy, and fibrosis. In CNV, angiogenesis is believed to reflect many causes, including genetic risk factors, subclinical inflammation, oxidative injury, and local changes in blood flow.¹⁻³

Integrins, which are transmembrane receptors composed of α and β subunits that mediate binding to extracellular matrix or other cellular receptors, have long been known to have a role in angiogenesis.⁴ In particular, $\alpha 5 \beta 1$ (the only known $\alpha 5$ integrin) has been defined most clearly as proangiogenic in that genetic ablation of $\alpha 5$ in mice was embryonically lethal because of severe vascular defects.⁵ Ablation of the $\beta 1$ subunit, as well as the $\alpha 5 \beta 1$ ligand fibronectin, also was embryonically lethal because of major vascular de-

fects.⁶⁻⁸ In contrast, genetic ablation of the integrin subunits $\alpha \nu$, $\beta 3$, and $\beta 5$ not only failed to block but in some instances enhanced angiogenesis.⁹⁻¹³

Normal vessels express low levels of $\alpha 5 \beta 1$, while expression is significantly up-regulated on tumor vessels¹⁴⁻¹⁶ and in response to angiogenic factors such as transforming growth factor $\beta 1$ and basic fibroblast growth factor (bFGF).¹⁷ In the eye, $\alpha 5 \beta 1$ was highly expressed on experimentally induced CNV membranes.¹⁸ The interaction between $\alpha 5 \beta 1$ and fibronectin has been found to promote adhesion, proliferation, and cell signaling in primary human retinal endothelial cells¹⁹ and to induce signaling in human RPE¹⁸ and vascular endothelial²⁰ cells. Moreover, these effects were inhibited by blocking the interaction of $\alpha 5 \beta 1$ with fibronectin, supporting a predominant role of these interactions in endothelial cell survival.¹⁸⁻²⁰

JSM6427 is a highly selective, small-molecule inhibitor of $\alpha 5 \beta 1$ ²¹ that has been shown to induce apoptosis of endothelial

cells cultured on fibronectin and to inhibit fibronectin-mediated signaling in cultured RPE cells.¹⁸ Systemic administration of JSM6427 induced regression of neovascular lesions in a murine model of CNV,¹⁸ while an $\alpha 5\beta 1$ -blocking monoclonal antibody inhibited laser-induced CNV in a monkey model.²² Together these findings support a role for $\alpha 5\beta 1$ in ocular neovascular diseases such as AMD. This article extends these findings by assessing the specificity of JSM6427 in blocking the $\alpha 5\beta 1$ -fibronectin interaction and in evaluating the tolerability and dose response of intravitreally administered JSM6427 in 2 animal models of CNV, including a laser-induced monkey model and a vascular endothelial growth factor (VEGF)/bFGF-induced rabbit model.

METHODS

COMPETITIVE INTEGRIN BINDING ASSAY

The selectivity of JSM6427 for $\alpha 5\beta 1$ was assessed by means of a previously described competitive binding assay in which soluble integrins ($\alpha 5\beta 1$, $\alpha v\beta 3$, $\alpha v\beta 5$, $\alpha IIb\beta 3$, and $\alpha 3\beta 1$) were incubated with the corresponding bound ligands (fibronectin, vitronectin, fibrinogen, or laminin) in the presence of varying concentrations of JSM6427.²¹ The inhibition curves were analyzed using a commercially available software program (SoftMaxPro, version 4.0; Molecular Devices Corp, Sunnyvale, California) to determine the 50% inhibitory concentration (IC₅₀).

LASER-INDUCED CNV IN MONKEYS

Twenty adult cynomolgus monkeys (10 males and 10 females) were assigned to groups by a stratified randomization scheme. For all procedures except ophthalmoscopic examinations (in which only intramuscular ketamine hydrochloride was used), monkeys were sedated with intramuscular ketamine and intravenous ketamine/diazepam to effect. After instillation of 1% tropicamide and proparacaine hydrochloride in each eye, CNV was induced by laser photocoagulation (OcuLight GL 532 with IRIS Medical Portable Slit Lamp Adaptor; Iridex Corp, Mountain View, California). A fundus contact lens was used for the laser treatment. Nine lesions (75 μ m, 500-700 mW, 100-200 milliseconds) were placed perimacularly in a grid formation; a vaporization bubble indicated the disruption of Bruch's membrane. Tobramycin ophthalmic solution was applied topically after photocoagulation.

Four groups of 4 monkeys each (2 males and 2 females) received weekly 50- μ L intravitreal injections (27-g needle) of JSM6427 (100, 300, or 1000 μ g per eye) or vehicle (sterile buffered saline; 130mM sodium chloride, 10mM sodium phosphate buffer, pH 7.2) in each eye. The first dose was given immediately after laser treatment, with additional injections on days 8, 15, and 22. Tobramycin was applied topically immediately after injection and on posttreatment day 2. A fifth group of 4 monkeys served as uninjected controls.

Fluorescein angiography was conducted before the study start and each week thereafter. Fluorescein sodium (10% solution; Alcon, Fort Worth, Texas) was injected via an implanted femoral vein catheter routed to a subcutaneous access port. Photographs were taken with a retinal camera (TRC-50EX; Topcon Medical Systems, Paramus, New Jersey) and captured with an imaging system (IMAGENet; Topcon) during the arterial phase, the early arteriovenous phase, and several late arteriovenous phases; images were assessed by a masked investigator. Grading for lesion leakage was as follows: 0 (no hy-

perfluorescence), 1 (mild speckled hyperfluorescence), 2 (moderate hyperfluorescence), 3 (mild lesion leakage), 4 (moderate, clinically significant lesion leakage), or 5 (extensive, clinically significant lesion leakage). The total number of lesions with grade 4 or 5 leakage and the percentage of lesions with grade 4 or 5 leakage in relation to the total were determined.

Indirect ophthalmoscopic examinations were performed after each injection (days 1, 8, 15, and 22). Before the study and on days 2, 9, 16, 23, and 30, both slitlamp biomicroscopy and indirect ophthalmoscopy were performed. Eyes were scored by means of a modified Hackett-McDonald scale.²³ Intraocular pressure was measured before the study and approximately 2 hours after injection by pneumatonometer (Model 30 Classic; Medtronic, Jacksonville, Florida) after application of proparacaine.

Electroretinograms (Epic 2000 with Ganzfeld apparatus; LKC Technologies, Gaithersburg, Maryland) were recorded before the study and on days 3 and 31. Monkeys were dark-adapted for 20 to 30 minutes before sedation, and tropicamide and proparacaine were administered topically. Electroretinogram probes were placed subcutaneously beneath each eye and posterior to the brow; contact lenses were placed on the eye with carboxymethylcellulose. Four light sequences (blue, red, white scotopic, and white flicker) were repeated at least 5 times, with the instrument averaging the conductance signals. The electroretinogram recordings were evaluated by a veterinary ophthalmology consultant.

All monkeys were killed on study day 32; complete gross and histopathological examinations were performed. Eyes were injected with and stored in Davidson fixative and transferred to 10% neutral-buffered formalin within 24 to 48 hours for at least 48 hours and then paraffin embedded. Five step-sections (approximately 30 μ m) were stained with hematoxylin-eosin and examined by a veterinary pathologist.

Blood samples were collected before dosing and at 1, 4, 8, 12, and 24 hours after dosing on days 1 and 22. Plasma was evaluated for JSM6427 by a high-performance liquid chromatographic-mass spectrometric assay with a detection limit of 3 ng/mL. Individual plasma concentration-time data were analyzed by noncompartmental pharmacokinetic methods via modeling and analysis software (WinNonline 1.5, Model 200; Pharsight Corp, Mountain View, California) with the use of nominal time points. Areas were calculated by the linear trapezoidal rule.

GROWTH FACTOR-INDUCED CNV IN RABBITS

Choroidal neovascularization was induced by implanting VEGF/bFGF pellets²⁴ as previously described.²⁵ Briefly, 15 μ g of human recombinant VEGF₁₆₅ and 15 μ g of recombinant bFGF (PeproTech, Rocky Hill, New Jersey) or a phosphate-buffered saline control were incorporated into polymer pellets (Hydron type NCC; HydroMed Sciences, Cranbury, New Jersey). Four groups of 6 adult Dutch-belted rabbits each were anesthetized (intramuscular ketamine hydrochloride/xylazine plus topical tropicamide, phenylephrine hydrochloride, and proparacaine) and VEGF/bFGF pellets were implanted in their right eye, while a fifth group of 6 rabbits received control pellets. Povidone iodine was used for asepsis. The pellets were implanted in the suprachoroidal space. After a conjunctival peritomy in the supraotemporal quadrant, a full-thickness sclerotomy (avoiding the choroid) was performed concentric to and 3 mm posterior to the limbus. The implant was placed between the 9- and 10-o'clock positions in an artificial suprachoroidal space created by passing a cyclodialysis spatula between the choroid and sclera.^{26,27} Immediately after implantation of the active pellets and on days 7, 14, and 21, the 4 groups of rabbits received in the same eye a midvitreal 50- μ L intravit-

Table. The IC₅₀ of JSM6427 for Each of the Integrin-Ligand Pairs

Integrin	JSM6427 Concentration, Mean (SD), nmol/L	Ligand	Selectivity Factor ^a
α5β1	0.57 (0.35)	Fibronectin	NA
αvβ3	980 (700)	Vitronectin	1700
αvβ5	4300 (3900)	Vitronectin	7500
αIIbβ3	>50 000	Fibrinogen	>50 000
α3β1	53 000	Laminin	≈100 000

Abbreviations: IC₅₀, 50% inhibitory concentration; NA, not applicable.

^aSelectivity was calculated according to the following formula: IC₅₀ for other integrin-ligand combinations/IC₅₀ of JSM6427 for α5β1-fibronectin.

real injection (30-g needle, between the 1- and 2-o'clock positions) of JSM6427 (100, 300, or 1000 μg per eye) or vehicle alone followed by topical 0.3% ciprofloxacin (Alcon).

Rabbits were examined by indirect ophthalmoscopy preoperatively, postoperatively, and weekly thereafter for 4 weeks; observations were graded by the McDonald and Shadduck system.²⁸ Standard color fundus photography and fluorescein angiograms using a retinal camera (TRC 50EX; Topcon Medical Systems) were performed before the study and weekly thereafter. Fluorescein sodium (10% solution) was administered intravenously through the ear vein, and photographs were taken during a 30-second period for up to 10 minutes. Grading for lesion leakage was as follows: (1) total area of the lesion; (2) severity of leakage/exudation over time on a scale of 0 (no leakage), 1 (mild), 2 (moderate), and 3 (robust); and (3) a binary assessment of CNV presence (0, no; 1, yes). Histopathology of formalin-fixed tissues was performed.

ANIMAL USE STATEMENT

All procedures were conducted in accord with the Association for Research in Vision and Ophthalmology Statement for the Use of Animals in Ophthalmic and Vision Research and the US Department of Agriculture Animal Welfare Act as well as conditions specified in the Guide for the Care and Use of Laboratory Animals (1996). The protocol was approved by the facility institutional animal care and use committees (North American Science Associates Inc, Irvine, California, and Charles River Laboratories Preclinical Services, Sparks, Nevada).

STATISTICAL ANALYSIS

Statistical differences between groups were determined by 1-way analysis of variance. If significant, analysis of variance was followed by the Newman-Keuls multiple comparison test using statistical software (Prism 4; GraphPad Software, San Diego, California). All lesions (grades 1-5) were included in the calculation, with *P* < .05 considered statistically significant.

RESULTS

JSM6427 COMPETITIVE BINDING ASSAY

JSM6427 showed highly selective inhibition of the α5β1-fibronectin interaction in vitro, with an IC₅₀ of 0.57 nmol/L (Table). JSM6427 was at least 1700-fold less potent in inhibiting the binding of other integrins to their corresponding ligands.

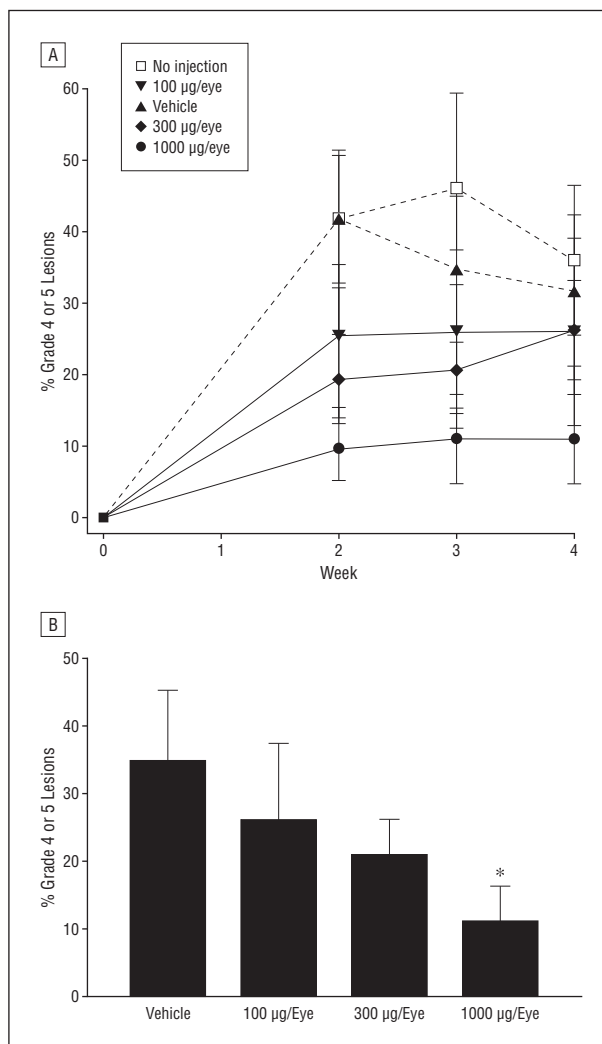


Figure 1. Percentages of lesions with grade 4 or 5 leakage in relation to the total number of lesions after laser-induced disruption of Bruch's membrane followed by weekly intravitreal injections of JSM6427 (100, 300, or 1000 μg/eye), vehicle control, or no injection. A, Percentage of grade 4 or 5 lesions by treatment group at each weekly evaluation. B, Percentage of grade 4 or 5 lesions by JSM6427 dose compared with vehicle-treated eyes at week 3. **P* < .05.

JSM6427 INHIBITION OF LASER-INDUCED CNV IN MONKEYS

By week 2 after photocoagulation, clinically significant (grade 4/5) leakage developed in all groups (Figure 1A). While the number of grade 4/5 lesions in the untreated control group was identical to that in the vehicle-injected control group (30 each), there were reduced numbers of lesions in all JSM6427-treated groups by week 2 (*n* = 16, *n* = 14, and *n* = 7 for the 100-, 300-, and 1000-μg groups, respectively). There were similar results at weeks 3 and 4 (data not shown). Representative fluorescein angiographic photographs of eyes treated with vehicle or 1000 μg of JSM6427 during the 4-week time course are shown in Figure 2.

By week 2, the percentage of clinically significant lesions in JSM6427-treated eyes in relation to the total number of lesions was lower than in uninjected control or vehicle-injected eyes (42% for both untreated and

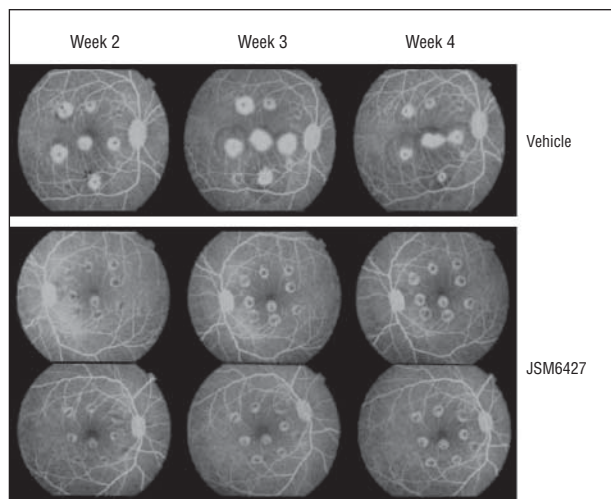


Figure 2. Representative fluorescein angiograms of monkey eyes treated with intravitreal injections of vehicle or JSM6427 (1000 μg per eye) after induction of choroidal neovascularization during weeks 2, 3, and 4.

vehicle-treated controls and 25%, 19%, and 10% for the 100-, 300-, and 1000- μg groups, respectively; Figure 1A). These effects were maintained through weeks 3 (Figure 1B) and 4 and were statistically significant for the high-dose group compared with the vehicle-treated group ($P < .05$) for all measured time points.

OCULAR AND SYSTEMIC TOXIC EFFECTS IN MONKEYS

No ophthalmologic findings were attributed directly to JSM6427 administration. Findings attributed to the injection procedure were posterior subcapsular cataract (1 of 8 eyes in both the 100- and 300- μg treatment groups and 3 of 8 in the vehicle group) and severe inflammation (2 of 8 in the 100- μg treatment group after the second and third injections). Two eyes receiving 1000 μg of JSM6427 developed transient vitreous haze (mild in 1 and moderate in 1) that resolved by day 9. Mild conjunctival congestion/discharge, white opacities resembling cells on the posterior lens capsule, and mild hemorrhage associated with laser burns also occurred across treatment groups. Intraocular pressure levels were maintained within normal limits (15-30 mm Hg).

No abnormalities in electroretinogram responses attributable to intravitreal JSM6427 were noted (data not shown). At day 31, individual eyes in the vehicle-treated group exhibited decreases in amplitudes greater than 25% of the baseline values, which were attributed to individual variability and the injection procedure. Abnormal responses at day 31 in 2 eyes in the 100- μg group were considered secondary to procedure-related inflammation.

There were no gross or microscopic pathological ocular findings related to the administration of JSM6427. Focal/multifocal laser-induced lesions were as expected after retinal laser photocoagulation. Histologic findings believed related to laser-induced retinal and choroidal lesions included small numbers of erythrocytes in the vitreous or optic nerves, and findings attributable to the injection procedure included minimal to mild fibroplasia/fibrosis of the ciliary body or choroid. Incidental lesions included mini-

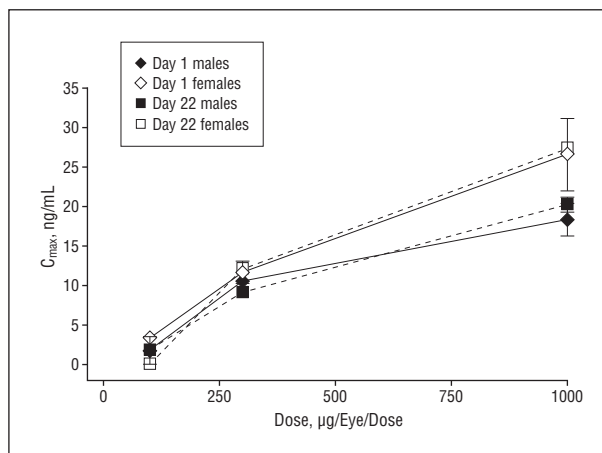


Figure 3. Dosage relationships for JSM6427 mean maximum concentration (C_{max}) in plasma during weekly intravitreal administration to monkeys. Mean plasma C_{max} was determined on days 1 and 22 for the 3 dose groups (100, 300, and 1000 μg per eye).

mal to mild, focal/multifocal infiltrates of mixed mononuclear inflammatory cells in the ciliary body, choroid, sclera, cornea, and conjunctiva of numerous animals, including the controls. Injection-related unilateral panophthalmitis was observed in 2 of 8 eyes in the 100- μg treatment group. There were no JSM6427-related nonocular clinical, toxicologic, or histopathological findings.

PHARMACOKINETICS OF JSM6427 AFTER INTRAVITREAL ADMINISTRATION IN MONKEYS

Weekly intravitreal injections of JSM6427 resulted in very low plasma levels on days 1 and 22. JSM6427 was detected consistently only in plasma samples of animals given 300 or 1000 μg per eye. After administration of JSM6427 at 300 and 1000 μg per eye per dose, mean plasma concentrations reached C_{max} at a mean time of 6 or 8 hours on both days 1 and 22 and then declined. The mean time through which concentrations were measurable on each day was 12 hours at 300 μg per eye per dose and 24 hours at 1000 μg per eye per dose. The mean terminal plasma half-life after dosing of 1000 μg per eye per dose, estimated for a limited set of animals, was approximately 15 hours on days 1 and 22. The mean plasma C_{max} on days 1 and 22 ranged between 10.6 and 11.7 ng/mL and between 9.1 and 12.1 ng/mL, respectively, for 300 μg per eye per dose and between 18.4 and 26.6 ng/mL and between 20.3 and 27.4 ng/mL, respectively, for 1000 μg per eye per dose (Figure 3). Mean C_{max} (Figure 3) and mean area under the plasma concentration-time curve from time zero to the time of the last measurable concentration (AUC_{last}) (data not shown) were slightly different between males and females. Mean C_{max} increases were slightly less than the relative increase in dose, while the increases in mean AUC_{last} were approximately proportional (for males) or slightly greater (for females) than the relative 3.3-fold increase in dose.

Mean C_{max} and mean AUC_{last} values on day 22 were comparable with values on day 1, indicating the absence of accumulation in this study. Earlier studies (data not shown) demonstrated a very rapid elimination of JSM6427 after

intravenous administration in the monkey (half-life, 9 minutes), while JSM6427 exhibited flip-flop kinetics after intravitreal injection, with the rate of distribution from the eye being slower than systemic elimination.

JSM6427 INHIBITION OF GROWTH FACTOR-INDUCED CNV IN RABBITS

In the growth factor-induced rabbit model, which produces stable CNV lesions in which edema is distinct from CNV leakage,²⁹ eyes implanted with VEGF/bFGF-containing pellets developed florid CNV and leakage in vehicle-treated eyes after 2 weeks, increasing through week 3 (Figure 4A and Figure 5). Eyes with control pellets showed no leakage on fluorescein angiography (Figure 4A and Figure 5). At week 3 (Figure 4B), there was a dose-dependent suppression of choroidal vascular leakage in eyes treated with JSM6427 ($P < .05$ for control vs 100-, 300-, and 1000- μg groups [Figure 5], respectively). Week 4 differences also were significant (data not shown).

Ophthalmologic and histopathological examinations showed no evidence of JSM6427-related toxic effects. Sporadic minimal or mild focal histologic findings, including retinal disorganization, keratitis, and the presence of macrophages within the retina or choroid, were seen across all treatment groups and were attributed to the injection or implantation procedures.

COMMENT

JSM6427 (or a related molecule) was previously shown to inhibit neovascularization in murine CNV,¹⁸ hypoxia-induced,³⁰ and corneal^{31,32} models, suggesting that the $\alpha 5\beta 1$ -fibronectin interaction is an active contributor to angiogenesis in ocular neovascular disease. The present study extends these findings by demonstrating that JSM6427 blocks this interaction with high selectivity and potency, providing a dose-dependent reduction in CNV without evidence of ocular or retinal toxic effects; the efficacy at the highest dose was comparable with that of an $\alpha 5\beta 1$ -blocking monoclonal antibody.²² These findings are consistent with mechanistic studies showing that JSM6427 inhibited the proliferation,³² migration,^{30,32} and sprouting^{30,32} of endothelial cells in vitro and induced apoptosis of endothelial cells in vitro and in CNV tissues.¹⁸

In neovascular AMD, clinical studies have identified RPE cells in subretinal membranes outside the normal RPE layer.³³⁻³⁵ These activated "transdifferentiated" RPE cells may contribute to the development of CNV by generation of angiogenic and inflammatory growth factors.³⁵ Previous work has shown that $\alpha 5\beta 1$ is highly ex-

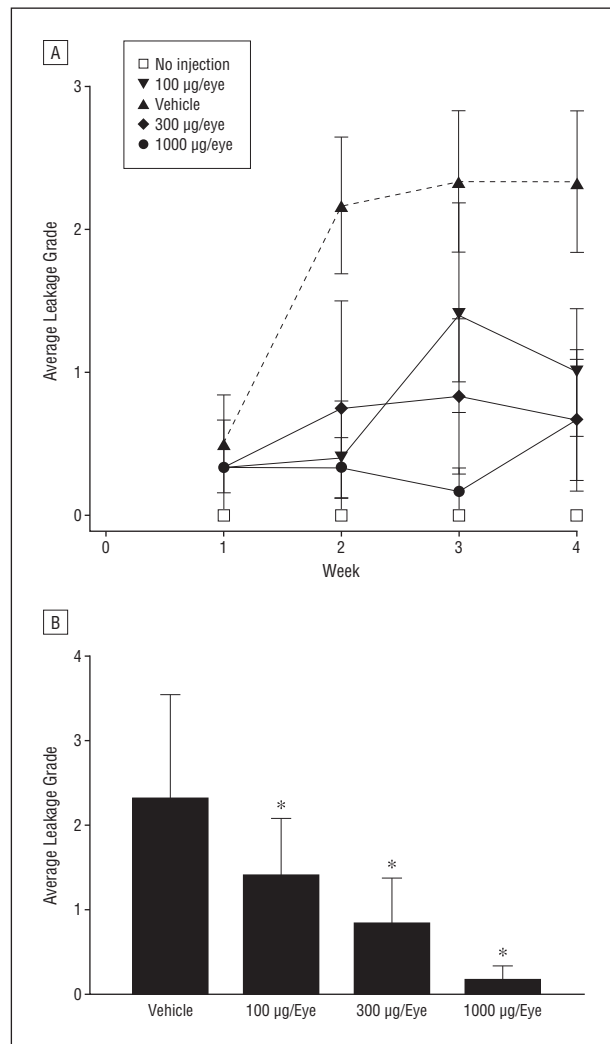


Figure 4. Average leakage grade during weekly intravitreal injections of JSM6427 (100, 300, or 1000 μg) or vehicle administered to rabbit eyes after implantation of vascular endothelial growth factor/basic fibroblast growth factor pellets or control pellets without growth factor. A, Average leakage grade for each of the dose groups at each weekly evaluation. B, Average leakage grade at week 3 for each of the dose groups. * $P < .05$.

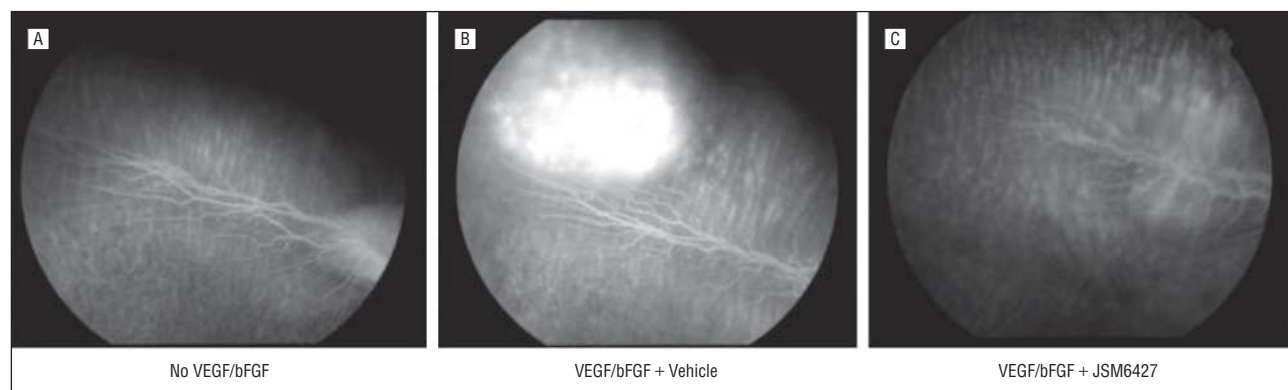


Figure 5. Representative fluorescein angiograms of rabbit eyes treated with control pellets without growth factor and no injection (A), vascular endothelial growth factor/basic fibroblast growth factor (VEGF/bFGF) pellets and vehicle injections (B), or VEGF/bFGF pellets and 1000- μg JSM6427 injections (C).

pressed on proliferating and migrating, but not quiescent, RPE cells³⁶ and that JSM6427 was able to inhibit the migration of ARPE-19 cells (unpublished data) and fetal RPE cells.³⁷ Moreover, expression of the $\alpha 5$ subunit was found to be significantly upregulated on RPE cells by tumor necrosis factor α ,³⁸ which has been found to be highly expressed on CNV membranes.³⁹ By inhibiting RPE proliferation and migration, JSM6427 might have additional effects on the growth of subretinal membranes independent of its effects on endothelial cells.

In addition to being expressed on proliferating RPE cells, $\alpha 5\beta 1$ expression is upregulated on activated monocytic cells,⁴⁰ which are believed to play a key role in CNV by producing growth factors and cytokines,^{41,42} and on myofibroblasts.⁴³ Therefore, both anti-inflammatory and antifibrotic effects of JSM6427 may have contributed to the inhibition of neovascularization by JSM6427 in our laser model, which approximates CNV related to AMD.^{44,45} In AMD, fibrosis can lead to destruction of the sensory retina, RPE, and inner choroid with the formation of a fibrovascular disciform scar, resulting in profound vision loss.⁴⁶ Furthermore, ocular neovascular diseases such as AMD are suspected to have an inflammatory component,^{41,42,47,48} suggesting that the anti-inflammatory and antifibrotic properties of JSM6427 warrant further investigation.

A notable function of integrins is that they provide a linkage between extracellular molecules and the actin-based microfilament system; in many cases, proliferative responses to soluble growth factors are dependent on integrin-mediated adherence to extracellular substrates.¹² Blocking angiogenesis through inhibition of integrin-mediated signaling has the potential to inhibit the cellular responses to growth factors as well as cytokines and other inflammatory mediators. The findings of the present study demonstrating that JSM6427 reduced the formation of CNV induced by sustained suprachoroidal release of VEGF and bFGF support a new mode of action for JSM6427 that differentiates it from recent therapeutic approaches based on VEGF inhibition.

The results of the pharmacokinetic analysis showed that there was detectable systemic exposure after intravitreal injection of JSM6427 in monkeys, rapidly declining over 24 hours. For application in clinical trials, it is expected that there will be limited systemic effects because of the very short systemic exposure to low concentrations of JSM6427. In addition, $\alpha 5\beta 1$ integrin expression in normal tissues is very limited.^{14,16,49} A sustained-release formulation of JSM6427 that will enable a continuous low-dose delivery with no significant systemic exposure is currently under development and is expected to be the targeted method of administration.

Subsequent to the positive results of these preclinical studies, a phase 1 clinical trial evaluating intravitreal JSM6427 in treating neovascular AMD is under way (clinicaltrials.gov identifier: NCT00536016). The trial includes a single-dose study (ranging from 0.15-1.5 mg per eye) and a repeated-dose study in which 4 weekly injections with the same dose range will be administered. In addition, due to its mechanism of action, JSM6427 may show promise not only as a treatment for AMD but also for other ocular neovascular diseases such as proliferative diabetic retinopathy and proliferative vitreoretinopathy.

Submitted for Publication: November 14, 2008; final revision received March 16, 2009; accepted April 13, 2009.
Correspondence: Grit Zahn, PhD, Jerini AG, Invalidenstrasse 130, 10115 Berlin, Germany (grit.zahn@gmx.net).

Author Contributions: Dr Zahn had full access to all the data in the study and takes responsibility for the integrity of the data and the accuracy of the data analysis.

Financial Disclosure: Dr Zahn is an employee of Jerini AG and is a patent designee; Dr Vossmeier is an employee of Jerini AG; Dr Stragies is an employee of Jerini AG and is a patent designee; Ms Wills is a consultant for Jerini AG; Dr Wong is a consultant for Jerini AG; Dr Löffler received financial support from Jerini AG; Dr Adamis is an employee of Jerini Ophthalmic Inc; Dr Knolle is a former employee of Jerini AG and is a patent designee.

Funding/Support: Jerini AG provided support for all aspects of this work, including design and conduct of the study; collection, management, analysis, and interpretation of the data; and preparation, review, and approval of the manuscript. Assistance in manuscript preparation was provided by Linda Whetter, DVM, PhD, of Zola Associates.

Additional Contributions: We thank Alfred Wegener, PhD (University of Bonn), Mark Sutherland, FRCPATH (Fulcrum Pharma), and Andrew Harker, PhD (Fulcrum Pharma), for fruitful discussions of tolerability and pharmacokinetic studies. We also thank Seike Gericke and Thorsten Lanz (Jerini AG) for technical assistance in integrin-binding assays and Nilo Davila, MBA (Sclera LLC), for photography.

REFERENCES

1. Ambati J, Ambati BK, Yoo SH, Ianchulev S, Adamis AP. Age-related macular degeneration: etiology, pathogenesis, and therapeutic strategies. *Surv Ophthalmol.* 2003;48(3):257-293.
2. Jager RD, Mieler WF, Miller JW. Age-related macular degeneration [published correction appears in *N Engl J Med.* 2008;359(16):1736]. *N Engl J Med.* 2008;358(24):2606-2617.
3. Rattner A, Nathans J. Macular degeneration: recent advances and therapeutic opportunities. *Nat Rev Neurosci.* 2006;7(11):860-872.
4. Brooks PC. Role of integrins in angiogenesis. *Eur J Cancer.* 1996;32A(14):2423-2429.
5. Yang JT, Rayburn H, Hynes RO. Embryonic mesodermal defects in alpha 5 integrin-deficient mice. *Development.* 1993;119(4):1093-1105.
6. Fässler R, Meyer M. Consequences of lack of beta 1 integrin gene expression in mice. *Genes Dev.* 1995;9(15):1896-1908.
7. George EL, Georges-Labouesse EN, Patel-King RS, Rayburn H, Hynes RO. Defects in mesoderm, neural tube and vascular development in mouse embryos lacking fibronectin. *Development.* 1993;119(4):1079-1091.
8. Stephens LE, Sutherland AE, Klimanskaya IV, et al. Deletion of beta 1 integrins in mice results in inner cell mass failure and peri-implantation lethality. *Genes Dev.* 1995;9(15):1883-1895.
9. Bader BL, Rayburn H, Crowley D, Hynes RO. Extensive vasculogenesis, angiogenesis, and organogenesis precede lethality in mice lacking all alpha v integrins. *Cell.* 1998;95(4):507-519.
10. Hodivala-Dilke KM, McHugh KP, Tsakiris DA, et al. Beta3-integrin-deficient mice are a model for Glanzmann thrombasthenia showing placental defects and reduced survival. *J Clin Invest.* 1999;103(2):229-238.
11. Huang X, Griffiths M, Wu J, Farese RV Jr, Sheppard D. Normal development, wound healing, and adenovirus susceptibility in beta5-deficient mice. *Mol Cell Biol.* 2000;20(3):755-759.
12. Hynes RO. Integrins: bidirectional, allosteric signaling machines. *Cell.* 2002;110(6):673-687.
13. Reynolds LE, Wyder L, Lively JC, et al. Enhanced pathological angiogenesis in mice lacking beta3 integrin or beta3 and beta5 integrins. *Nat Med.* 2002;8(1):27-34.

14. Kim S, Bell K, Mousa SA, Varner JA. Regulation of angiogenesis in vivo by ligation of integrin alpha5beta1 with the central cell-binding domain of fibronectin. *Am J Pathol.* 2000;156(4):1345-1362.
15. Magnussen A, Kasman IM, Norberg S, Baluk P, Murray R, McDonald DM. Rapid access of antibodies to alpha5beta1 integrin overexpressed on the luminal surface of tumor blood vessels. *Cancer Res.* 2005;65(7):2712-2721.
16. Parsons-Wingerter P, Kasman IM, Norberg S, et al. Uniform overexpression and rapid accessibility of alpha5beta1 integrin on blood vessels in tumors. *Am J Pathol.* 2005;167(1):193-211.
17. Collo G, Pepper MS. Endothelial cell integrin alpha5beta1 expression is modulated by cytokines and during migration in vitro. *J Cell Sci.* 1999;112(pt 4):569-578.
18. Umeda N, Kachi S, Akiyama H, et al. Suppression and regression of choroidal neovascularization by systemic administration of an alpha5beta1 integrin antagonist. *Mol Pharmacol.* 2006;69(6):1820-1828.
19. Wilson SH, Ljubimov AV, Morla AO, et al. Fibronectin fragments promote human retinal endothelial cell adhesion and proliferation and ERK activation through alpha5beta1 integrin and PI 3-kinase. *Invest Ophthalmol Vis Sci.* 2003;44(4):1704-1715.
20. Kim S, Bakre M, Yin H, Varner JA. Inhibition of endothelial cell survival and angiogenesis by protein kinase A. *J Clin Invest.* 2002;110(7):933-941.
21. Stragies R, Osterkamp F, Zischinsky G, et al. Design and synthesis of a new class of selective integrin alpha5beta1 antagonists. *J Med Chem.* 2007;50(16):3786-3794.
22. Ramakrishnan V, Bhaskar V, Law DA, et al. Preclinical evaluation of an anti-alpha5beta1 integrin antibody as a novel anti-angiogenic agent. *J Exp Ther Oncol.* 2006;5(4):273-286.
23. Hackett R. Assessing ocular irritation. In: Marzulli FN, Maibach HI, eds. *Dermatotoxicology*. Washington, DC: Hemisphere Publishing Corp; 1996:557-567.
24. Wong CG, Rich KA, Liaw LH, Hsu HT, Berns MW. Intravitreal VEGF and bFGF produce florid retinal neovascularization and hemorrhage in the rabbit. *Curr Eye Res.* 2001;22(2):140-147.
25. Wong CG, Bruce TC, You TT. Experimental CNV after transscleral implantation of VEGF/bFGF-implant within the suprachoroidal space for defining potential long-term synergistic actions of ranibizumab (Lucentis) with small low cost molecules in ameliorating wet AMD [ARVO abstract 1372]. *Invest Ophthalmol Vis Sci.* 2008;49:e-abstract 1372.
26. Wong CG, Gum GG, Hagemann L, Marques L, Kuppermann BD, de Carvalho RP. Induction of choroidal neovascularization by sustained release of VEGF/bFGF in rabbits: angiographic characterization and histologic correlation on different patterns of the choroidal vascular response [ARVO abstract 1417]. *Invest Ophthalmol Vis Sci.* 2005;46:e-abstract 1417.
27. Gum GG, Wong CG, de Carvalho RP. Laser-induced models of choroidal neovascularization in rabbits associated with sustained suprachoroidal and episcleral delivery of VEGF and bFGF [ARVO abstract 1422]. *Invest Ophthalmol Vis Sci.* 2005;46:e-abstract 1422.
28. McDonald T, Shaddock J. Eye irritation. In: Marzulli FN, Maibach HI, eds. *Advances in Modern Toxicology, Volume 4: Dermatotoxicology and Pharmacology*. Washington, DC: Hemisphere Publishing Corp; 1977:579-582.
29. Rabin D, Bruce TC, You TT, Wong CG. Both edema and leakage are expressed and are separable in long-term experimental CNV via sustained simultaneous release of VEGF and bFGF within the suprachoroidal space through transscleral implantation of a delivery device [ARVO abstract 1374]. *Invest Ophthalmol Vis Sci.* 2008;49:e-abstract 1374.
30. Maier AK, Kociok N, Zahn G, et al. Modulation of hypoxia-induced neovascularization by JSM6427, an integrin alpha5beta1 inhibiting molecule. *Curr Eye Res.* 2007;32(9):801-812.
31. Muether PS, Dell S, Kociok N, et al. The role of integrin alpha(5)beta(1) in the regulation of corneal neovascularization. *Exp Eye Res.* 2007;85(3):356-365.
32. Dietrich T, Onderka J, Bock F, et al. Inhibition of inflammatory lymphangiogenesis by integrin alpha5 blockade. *Am J Pathol.* 2007;171(1):361-372.
33. Das A, Puklin JE, Frank RN, Zhang NL. Ultrastructural immunocytochemistry of subretinal neovascular membranes in age-related macular degeneration. *Ophthalmology.* 1992;99(9):1368-1376.
34. Grossniklaus HE, Martinez JA, Brown VB, et al. Immunohistochemical and histochemical properties of surgically excised subretinal neovascular membranes in age-related macular degeneration. *Am J Ophthalmol.* 1992;114(4):464-472.
35. Lopez PF, Grossniklaus HE, Lambert HM, et al. Pathologic features of surgically excised subretinal neovascular membranes in age-related macular degeneration. *Am J Ophthalmol.* 1991;112(6):647-656.
36. Proulx S, Guérin SL, Salette C. Effect of quiescence on integrin alpha5beta1 expression in human retinal pigment epithelium. *Mol Vis.* 2003;9:473-481.
37. Li R, Maminishkis A, Zahn G, Vossmeier D, Miller SS. Integrin alpha5beta1 mediates attachment, migration, and proliferation in human retinal pigment epithelium: relevance for proliferative retinal disease [published online July 15, 2009]. *Invest Ophthalmol Vis Sci.* doi:10.1167/iov.09-3591.
38. Jin M, He S, Wörpel V, Ryan SJ, Hinton DR. Promotion of adhesion and migration of RPE cells to provisional extracellular matrices by TNF-alpha. *Invest Ophthalmol Vis Sci.* 2000;41(13):4324-4332.
39. Oh H, Takagi H, Takagi C, et al. The potential angiogenic role of macrophages in the formation of choroidal neovascular membranes. *Invest Ophthalmol Vis Sci.* 1999;40(9):1891-1898.
40. Roman J, Ritzenthaler JD, Boles B, Lois M, Roser-Page S. Lipopolysaccharide induces expression of fibronectin alpha 5 beta 1-integrin receptors in human monocytic cells in a protein kinase C-dependent fashion. *Am J Physiol Lung Cell Mol Physiol.* 2004;287(1):L239-L249.
41. Grossniklaus HE, Ling JX, Wallace TM, et al. Macrophage and retinal pigment epithelium expression of angiogenic cytokines in choroidal neovascularization. *Mol Vis.* 2002;8:119-126.
42. Lopez PF, Sippy BD, Lambert HM, Thach AB, Hinton DR. Transdifferentiated retinal pigment epithelial cells are immunoreactive for vascular endothelial growth factor in surgically excised age-related macular degeneration-related choroidal neovascular membranes. *Invest Ophthalmol Vis Sci.* 1996;37(5):855-868.
43. Thannickal VJ, Lee DY, White ES, et al. Myofibroblast differentiation by transforming growth factor-beta1 is dependent on cell adhesion and integrin signaling via focal adhesion kinase. *J Biol Chem.* 2003;278(14):12384-12389.
44. Miller H, Miller B, Ishibashi T, Ryan SJ. Pathogenesis of laser-induced choroidal subretinal neovascularization. *Invest Ophthalmol Vis Sci.* 1990;31(5):899-908.
45. Husain D, Kim I, Gauthier D, et al. Safety and efficacy of intravitreal injection of ranibizumab in combination with verteporfin PDT on experimental choroidal neovascularization in the monkey. *Arch Ophthalmol.* 2005;123(4):509-516.
46. Hogg R, Curry E, Muldrew A, et al. Identification of lesion components that influence visual function in age related macular degeneration. *Br J Ophthalmol.* 2003;87(5):609-614.
47. Schlingemann RO. Role of growth factors and the wound healing response in age-related macular degeneration. *Graefes Arch Clin Exp Ophthalmol.* 2004; 242(1):91-101.
48. Tezel TH, Bora NS, Kaplan HJ. Pathogenesis of age-related macular degeneration. *Trends Mol Med.* 2004;10(9):417-420.
49. Sincock PM, Mayrhofer G, Ashman LK. Localization of the transmembrane 4 superfamily (TM4SF) member PETA-3 (CD151) in normal human tissues: comparison with CD9, CD63, and alpha5beta1 integrin. *J Histochem Cytochem.* 1997; 45(4):515-525.