

Discoid Lupus Erythematosus in Dogs

Dr Robert Hilton

BVSc(Hons) MACVSc (Canine Medicine) Cert.VD MRCVS

Mobile 0433853560

Website www.skinvet.org

Email rob@skinvet.org



***The most common immune mediated skin disease in
Australia***

***There are gross differences in how the canine and
human “discoid” lupus appears; hence, cutaneous
lupus erythematosus (CLE) is a more appropriate name
for the canine condition.***

***Collies and Shelties predisposed but may occur in a
variety of breeds.***

Severely exacerbated by UV radiation

***Target = basement membrane area. Target antigens
unclear.***

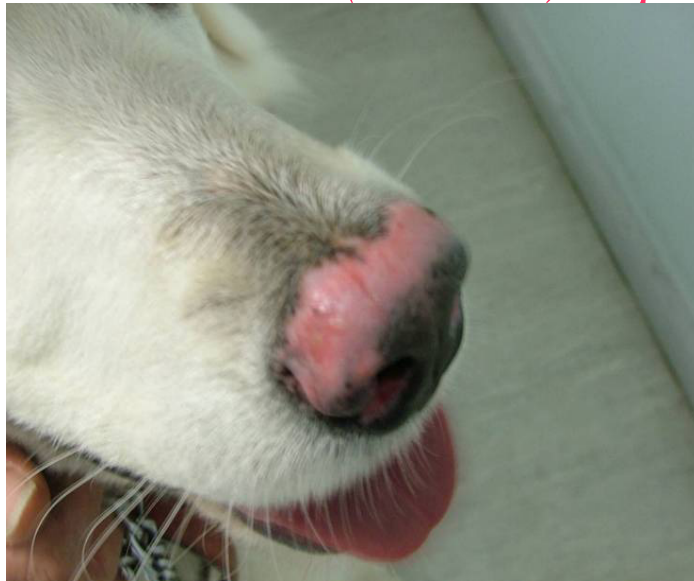Nasal planum is common target but may involve other mucocutaneous junctions, pinnae, scrotum and other sites

Inflammatory depigmentation, erosions and ulceration are typical lesions.

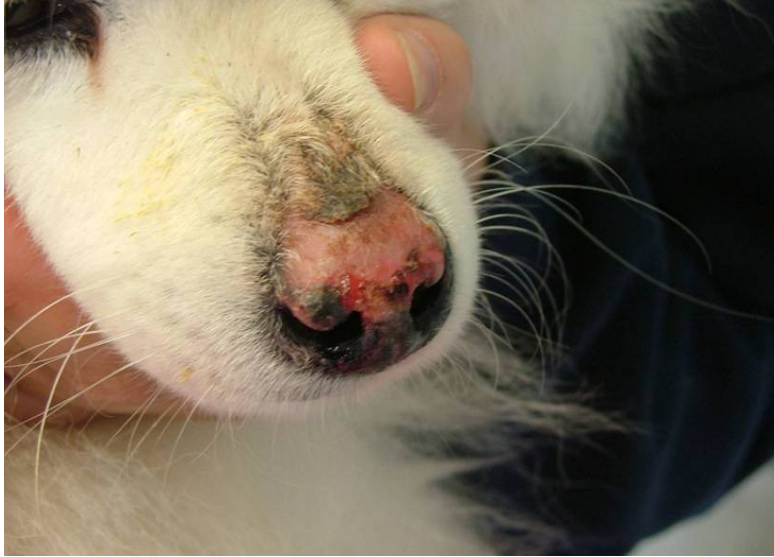Limited to skin only. ANA –ve

Severe cases are complicated by infections and occasionally severe bleeding

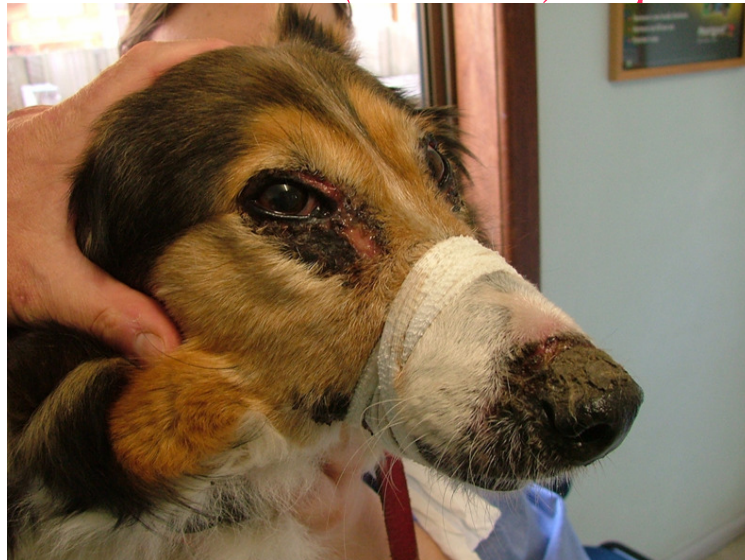Cutaneous (Discoid) Lupus

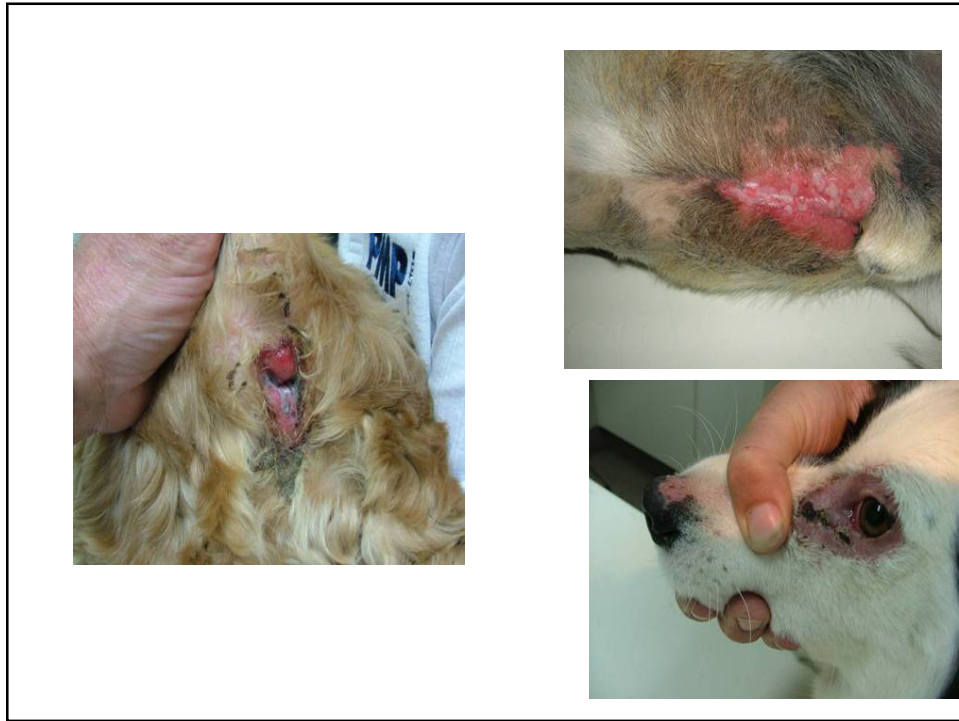

Cutaneous (Discoid) Lupus



Cutaneous (Discoid) Lupus





Differential diagnosis

Mucocutaneous pyoderma (major differential)

Other immune-mediated diseases (pemphigus, SLE, dermatomyositis, vasculitis and the uveo-dermatologic syndrome).

Nasal dermatophytosis

Solar or physical dermatitis

Neoplasia

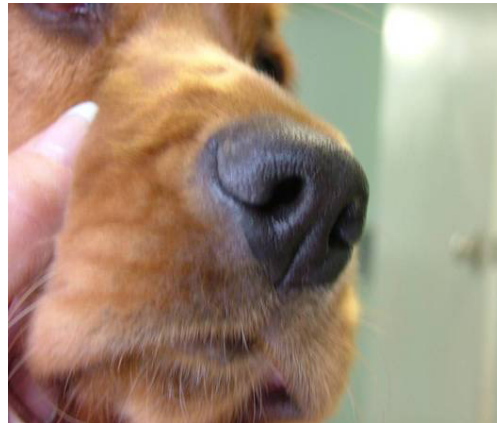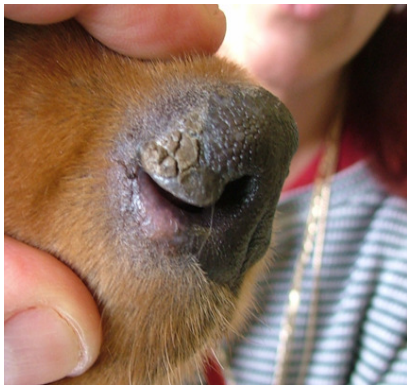CAUTION



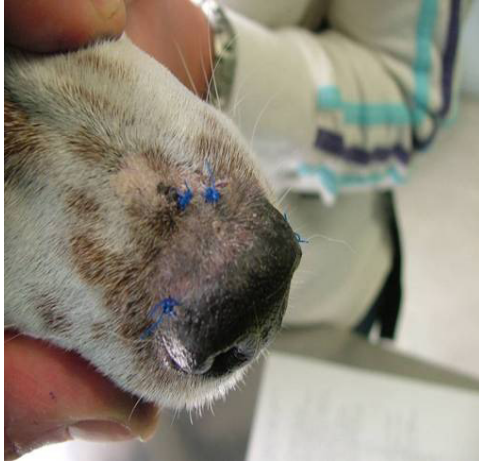Diagnosis is by histopathology
Do not submit samples less than 4mm
in diameter

Histopathology is NOT RELIABLE in
differentiating DLE from muco-
cutaneous pyoderma. Prior to biopsy,
assess response to 3 weeks of
antibiotics. If complete cure, Dx =
MCP

Mucocutaneous pyoderma pre and post antibiotics




Cutaneous (Discoid) Lupus



Areas showing depigmentation and erythema should be selected for biopsy, rather than areas of ulceration and/or crusts.

Balance the severity of cutaneous lupus against the risks of therapy.

Use the least toxic drugs and control sunlight exposure. **90% resolution is target!**



Treatment Overview

Sun Avoidance essential. Control without this almost impossible.

Short term immunosuppressive doses of prednisolone to induce remission. Long term immunosuppression, as per pemphigus foliaceus, is the last resort.

Topical Corticosteroids : **skin thinning**, calcinosis cutis and infections. Short term use OK. Long term 1-2x week but watch for skin thinning.

Apoquel (Oclacitinib) is the emerging systemic drug of choice. Given at 0.5-0.6mg /kg 2x day. Some cases can be maintained on 1x day treatment. Monitor white cell levels for neutropenia

Tetracyclines and niacinamide
Topical Tacrolimus
Hydroxychloroquine (Plaquinil)
Cyclosporine (severe refractory cases)

Ancillary therapy
- Vitamin E
- Omega 3/6 oils
- Antibiotics for secondary infection



Topical Tacrolimus or Pimecrolimus (Elidel)

Similar action but different binding site to cyclosporine

10 cases, 0.1% tacrolimus once a day , 80% responded. 75% of responding cases could be maintained on topical tacrolimus alone.

Compounded tacrolimus is the only form available in Australia and the author has NOT enjoyed success using it as monotherapy.

Valuable in reducing systemic drug usage

Tetracycline and Niacinamide (nicotinamide, nicotinic acid)

Multiple anti-inflammatory properties. Neither effective alone in dogs. Widely used.

70% success rate in maintaining. Assess after 10 weeks of use.

Dogs >10kg BW 500mg of each TID. Smaller dogs 250mg of each TID

Doxycycline (7.5-10mg/kg SID) may be substituted for tetracycline. Not cheap.

With three times a day medication, compliance is an issue. The author has had good results with doxycycline 1x day and 350-750 mg of niacinamide 2x day

Other immunosuppressants

Oral Cyclosporine

Many anecdotal reports that effective at atopic dermatitis protocol

For refractory cases

Hydroxychloroquine

(Plaquinil)

Antimalarial with immunomodulating properties

Good safety profile in dogs

5mg/kg once a day dose and cheap. Assess after 10 weeks.

This is the "go to" drug for human DLE. The author has had success in a limited number of cases.

Vitamin E and Essential Fatty Acids

Vitamin E

- » **Mild anti-inflammatory effects**
- » **500-1000 IU /day**
- » **No benefit from megadoses**
- **May take 2 months for effects**

Omega 3/6 fatty acids

- » **Mild anti-inflammatory effects**
- » **No optimum dose rate or omega 3/6 ratio determined for immune mediated disease**
- » **Indicative dose = 1ml of cold water marine fish oil/3kg.**
- **May take 2 months for effects**

A sample treatment plan

- Confirm diagnosis
- Aim for 90% symptom control. Pigment may never return.
- Keep out of sun. Non zinc sunscreens high SPF not a substitute.
- Treat secondary infection
- 4-6 weeks reducing course of corticosteroids (topical and parental to induce remission. Topical steroids no more than 1-2x week long term. Watch skin thinning.
- Same time, start Apoquel 0.5-0.6mg/kg 2x day
- Additional hydroxychloroquine, Vit E and omega-3 oil may help.

- PLAN B Doxycycline/niacinamide

- Re-assess in 10 weeks. If not good response, change systemic meds over and/or add in topical tacrolimus
- If refractory, cyclosporine