

Selected inflammatory diseases of older dogs



Dr Rob Hilton

BVSc(Hons) MANZCVS CertVD MRCVS

*RCVS (UK) Certificate Holder in
Veterinary Dermatology*

www.skinvet.org

rob@skinvet.org

0433-853560



Hens teeth

Recent onset inflammatory skin disease in an old dog

- Sudden onset of atopic dermatitis or food-related allergy in a 7+ year old dog is rare/uncommon, unless moved.
- Flea allergy, sarcoptes and adult onset demodex are more common as recent onset in older dogs

Toxic Cutaneous Immunological Drug reactions

- Drug macro-molecules may be directly antigenic
- Binding to cell membrane or nucleic acids => loss of self antigens
- Drug/antibody complexes depositing in blood vessel walls => vasculitis
- Drugs directly provoked autoantibodies

Reversible = Drug dependent
Irreversible = Drug induced

- Uncommon idiosyncratic events (except Doberman <-> sulphonamides)
- Most commonly associated with:
 - **B-lactam antibiotics** (Amoxicillin, cephalixin etc)
 - **Anti-inflammatory drugs** Carprophen
 - **Vaccines**
 - Sulphonamides, other antibiotics and antifungals (itraconazole griseofulvin)
 - **Phenobarbitone**
 - ***ANY OTHER DRUG***

Can begin at any time

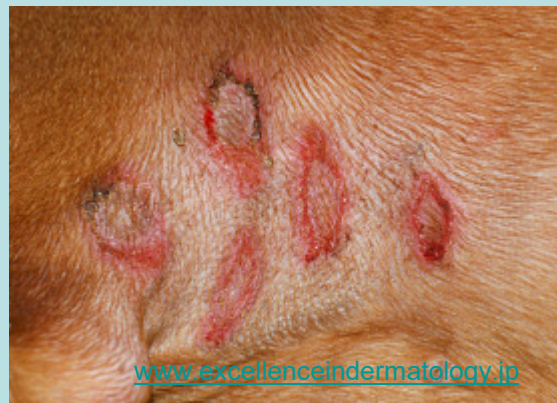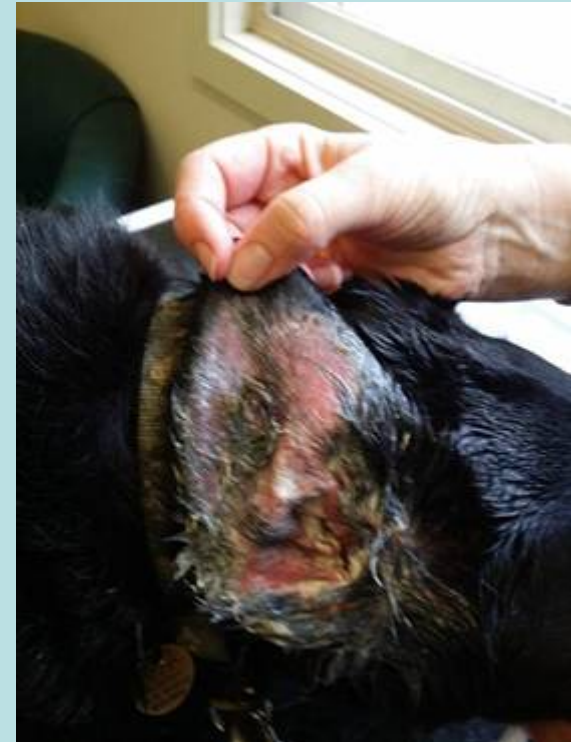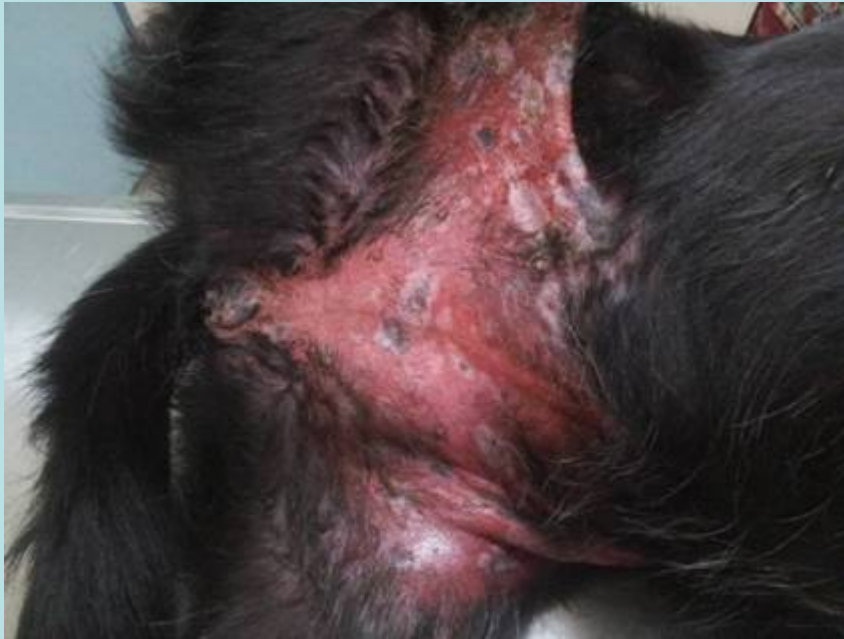- IgE mediated urticarial reactions immediate
- Commonly begin 3-14 days after drug initiated.

Wide Variety of Clinical Signs

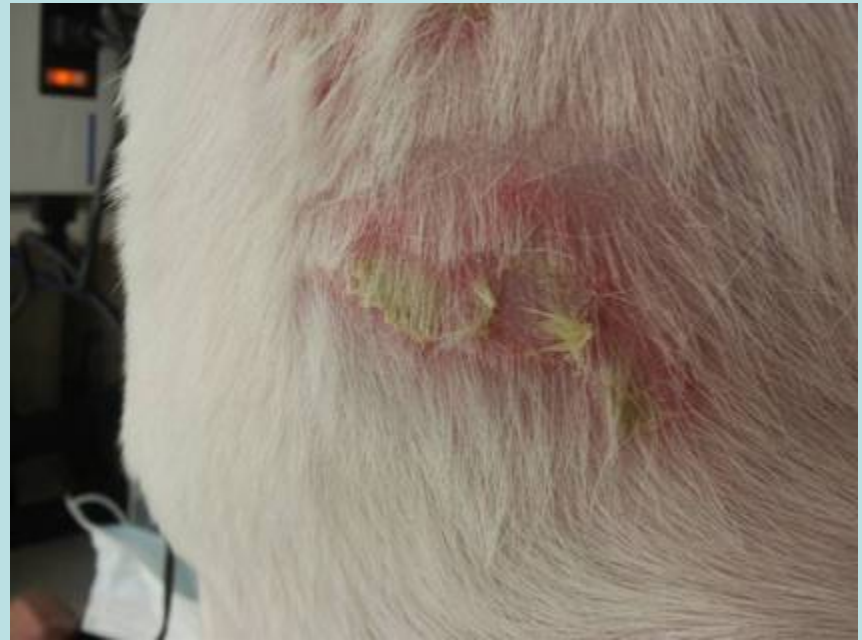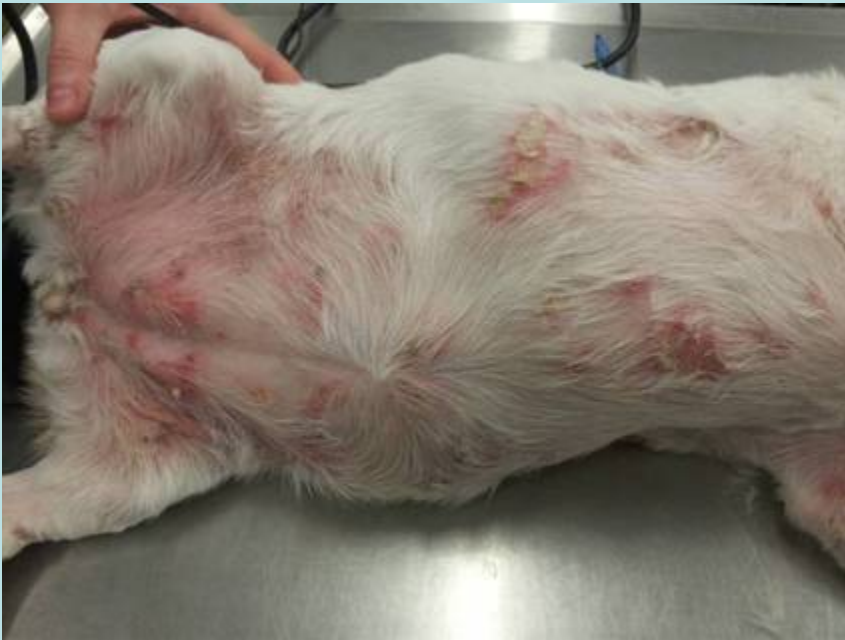Initially acute onset erythema +/- pruritus and fever

- Erythema multiforme
 - Target lesions => ulcers
 - +/- mucosal lesions (Major)
- Drug-induced pemphigus
- Fixed drug reactions
- Vasculitis
 - Oedema erythema
 - Demarcated ulcers
 - Necrosis of extremities
- Non-specific erythemaous maculo-papular reactions
- Steven-Johnson syndrome/toxic epidermal necrolysis
- Urticaria

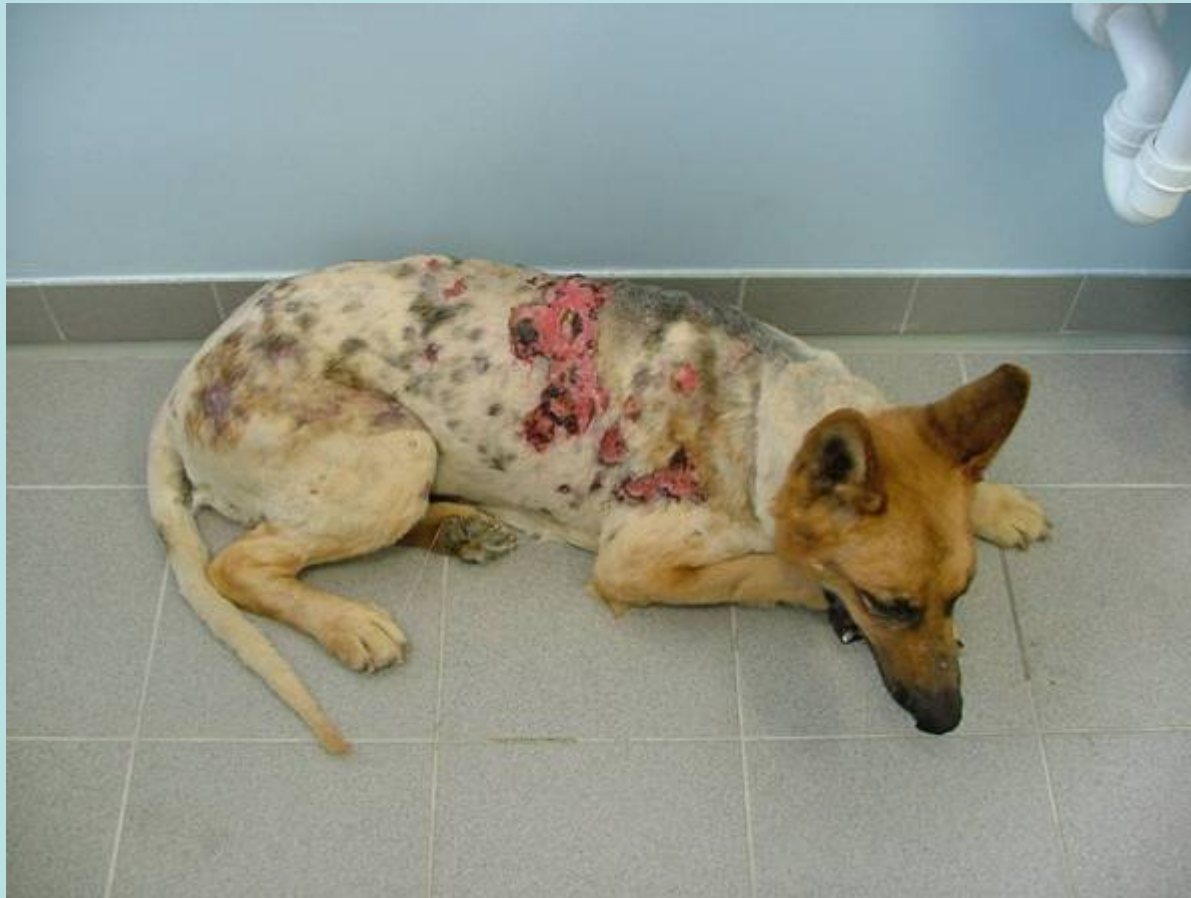Erythema Multiforme (major) Dog Cephalexin



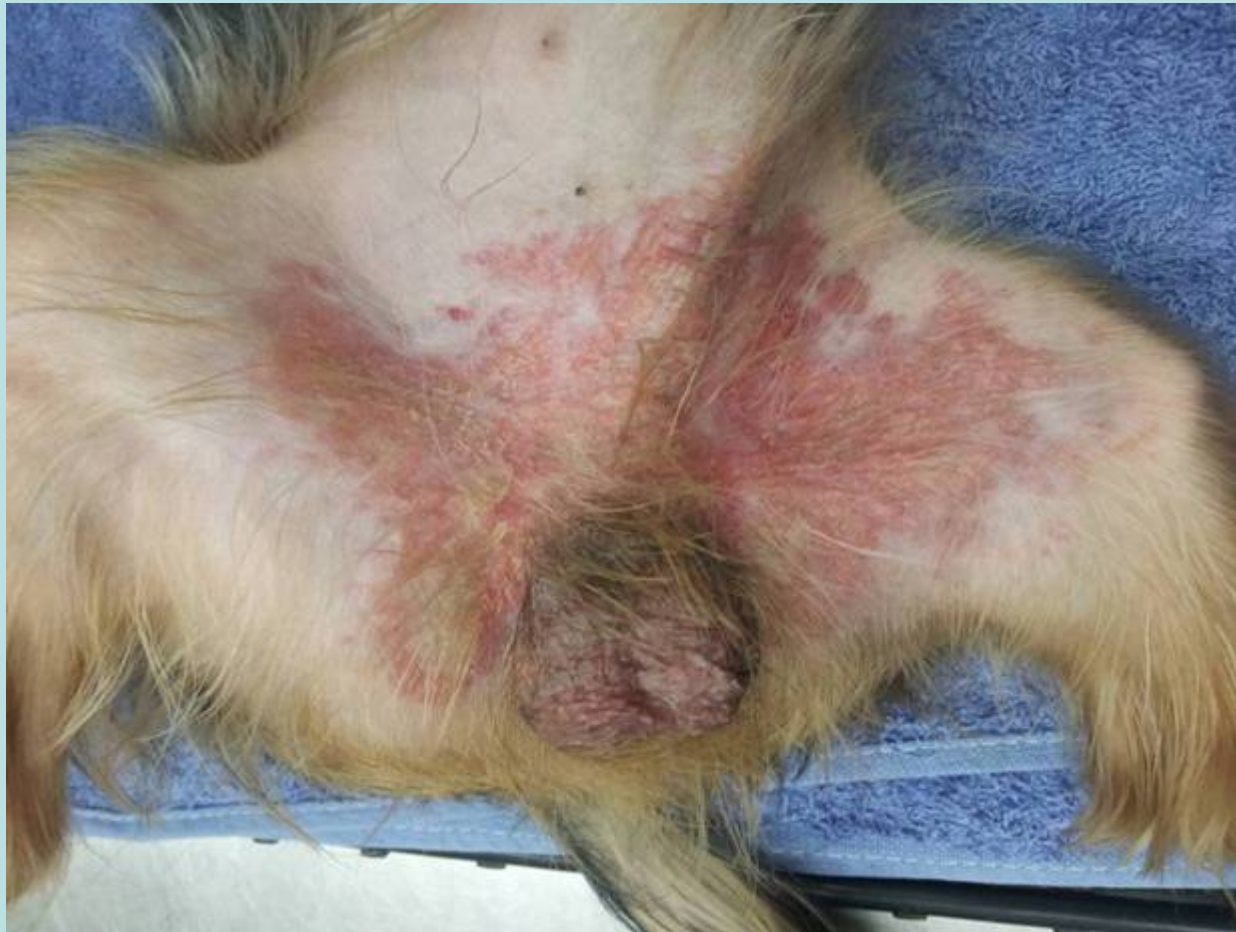Drug-induced pemphigus B-lactam antibiotics



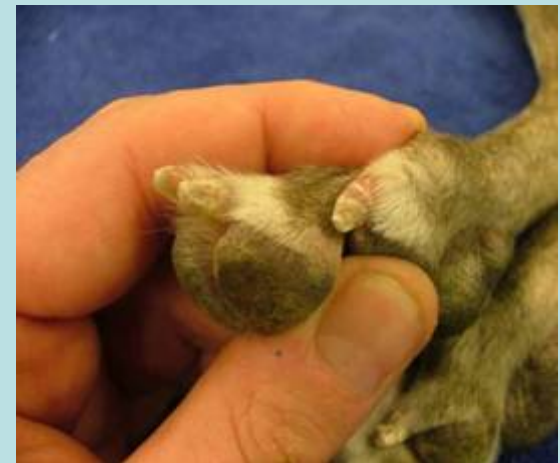
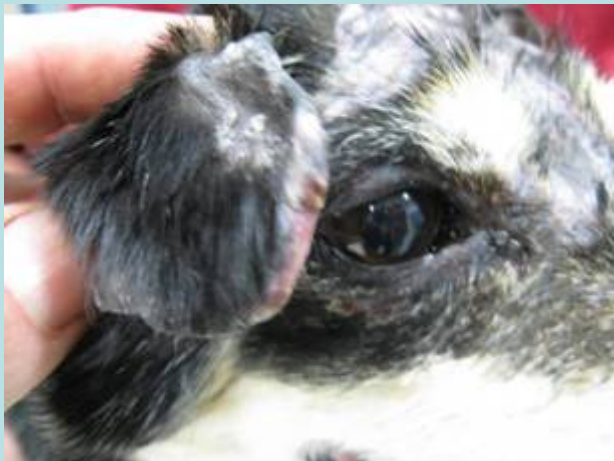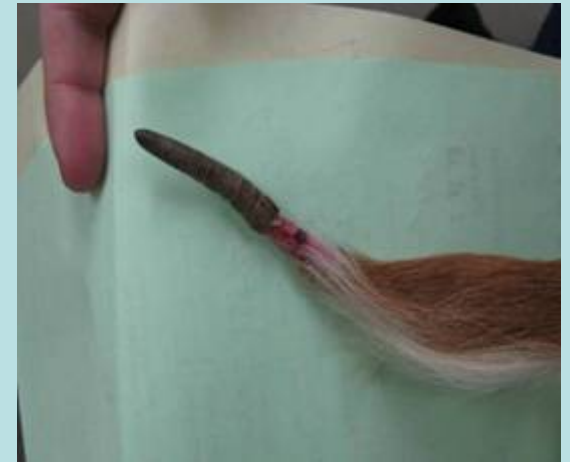Steven-Johnson syndrome/toxic epidermal necrolysis



Non-specific macular / erythrodermic
reaction
Carprofen



VASCULITIS



www.askavet.com

Diagnosis of drug reactions

- Often severe and acute onset
- History of drug administration
- Compatible clinical signs
- Compatible histological findings (Don't wait!, not always specific)
- Resolution of the symptoms on withdrawal of the drug (not always!)

Treatment of drug reactions

- Withdrawal of all suspect medications
- Short term corticosteroids. Evidence? Risk/Benefit
- Support treatment as per burns
- Antibiotics if sepsis risk (eg enrofloxacin + clindamycin)
- Long term appropriate immunosuppression if Dx confirmed and fails to resolve on drug withdrawal

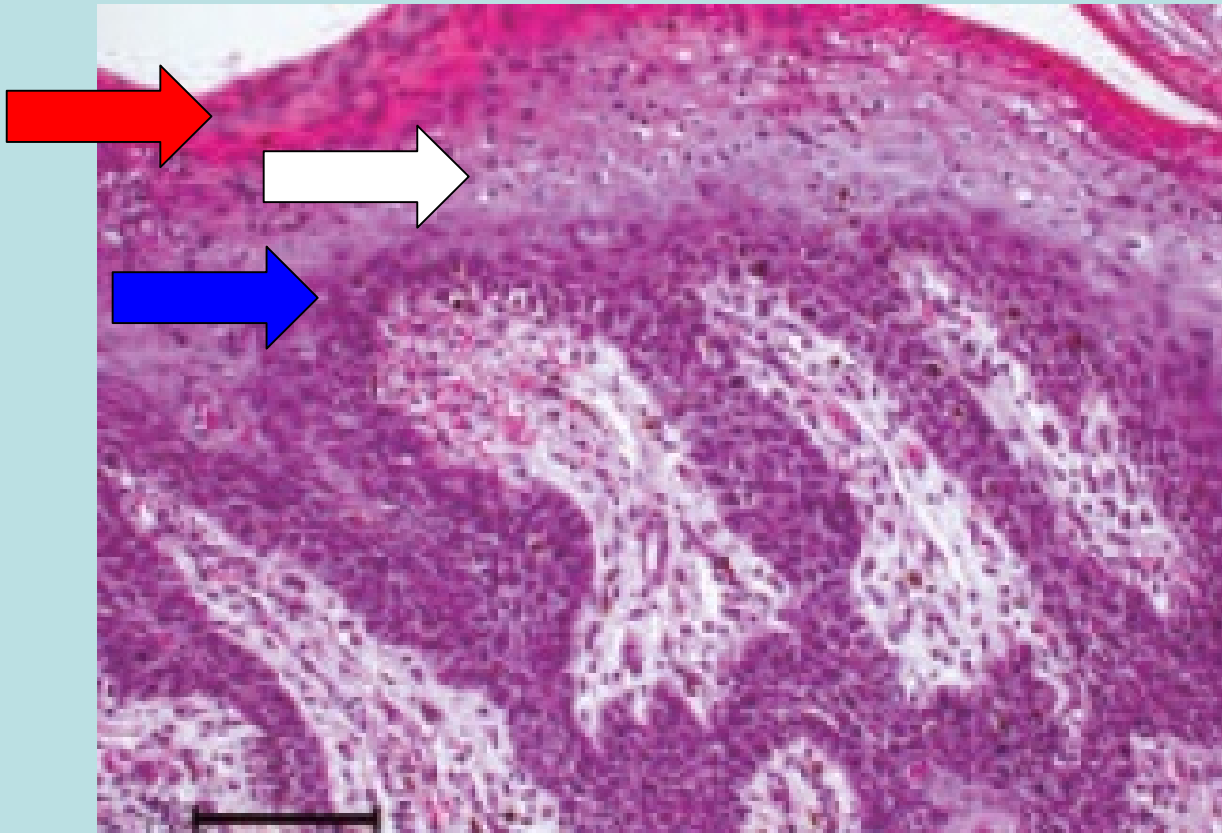
Hepatocutaneous syndrome (Metabolic epidermal necrolysis)

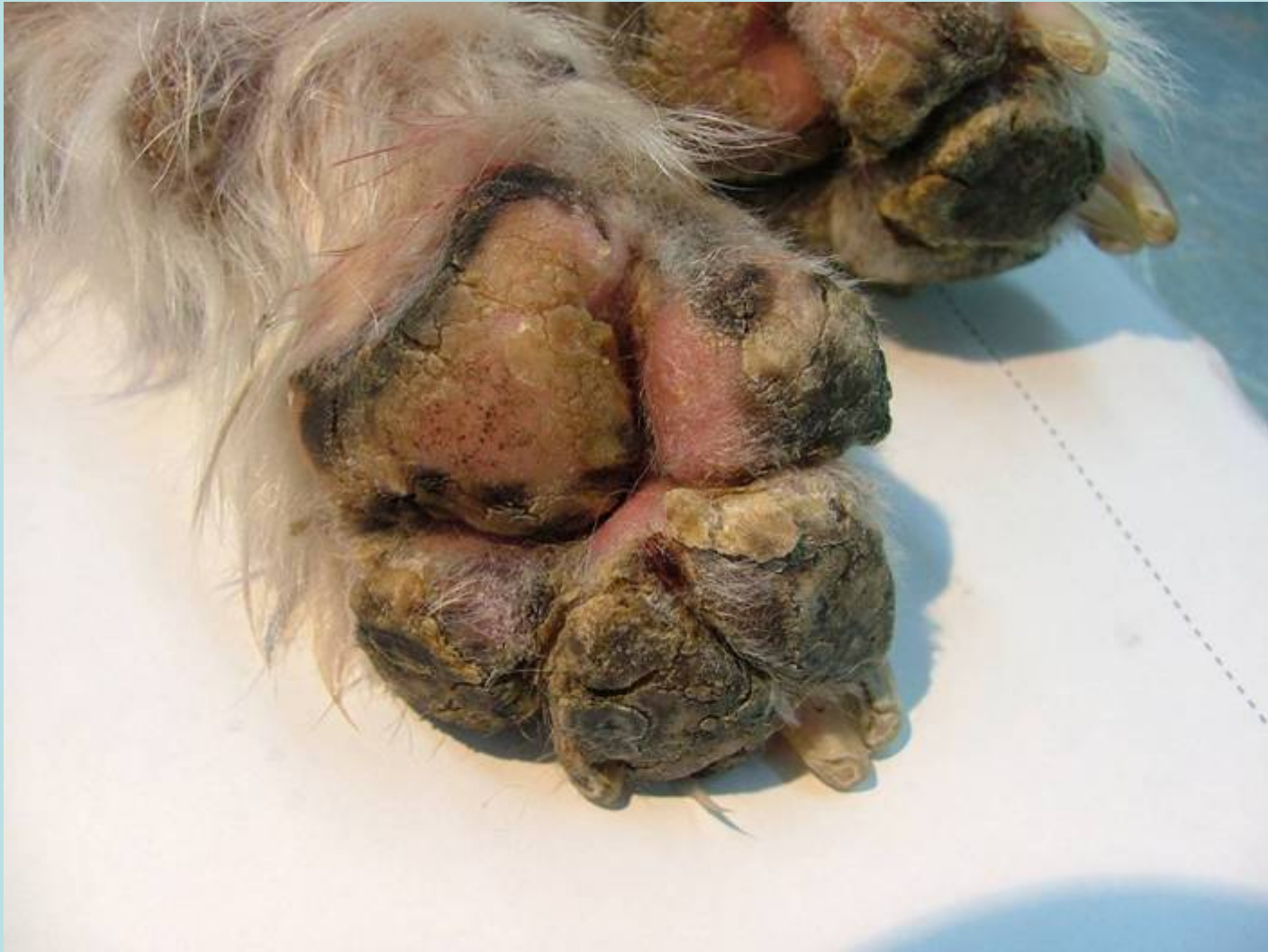- Degeneration and hyperplasia of keratinocytes associated with:
 - Chronic liver disease
 - Diabetes mellitus
 - Pancreatic glucagonoma. Less common in dogs vs humans
- Aetiopathogenesis unclear (defective protein and/or zinc metabolism???)
- May have a heritable component in Shih Tzus
- Older dogs.
- Skin signs may present before signs of liver disease

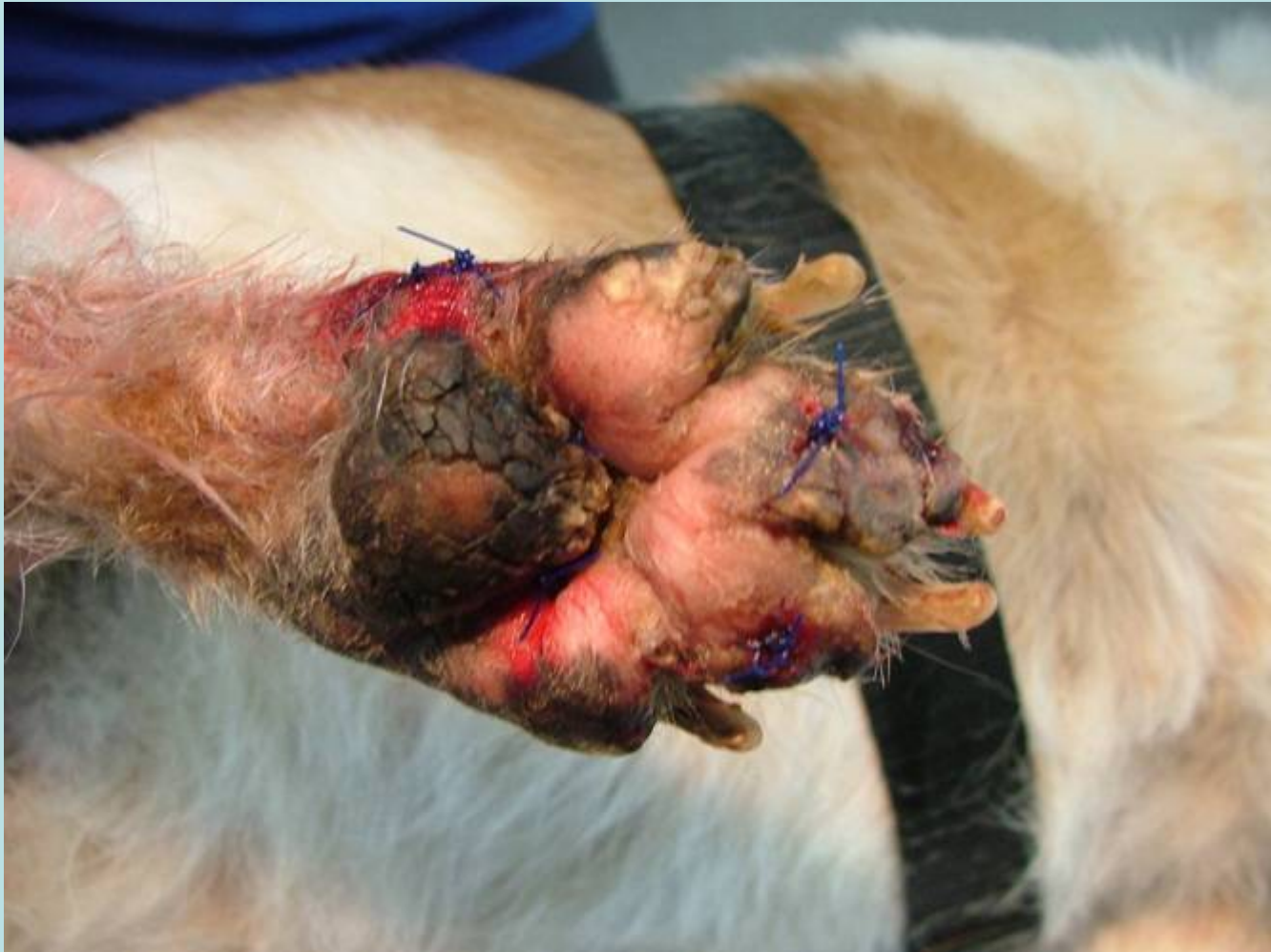Hepatocutaneous Syndrome

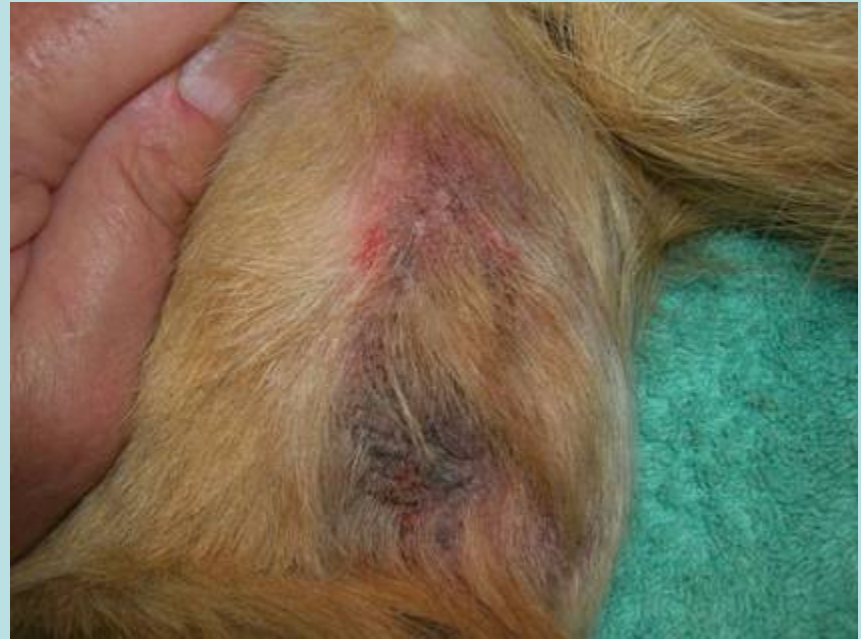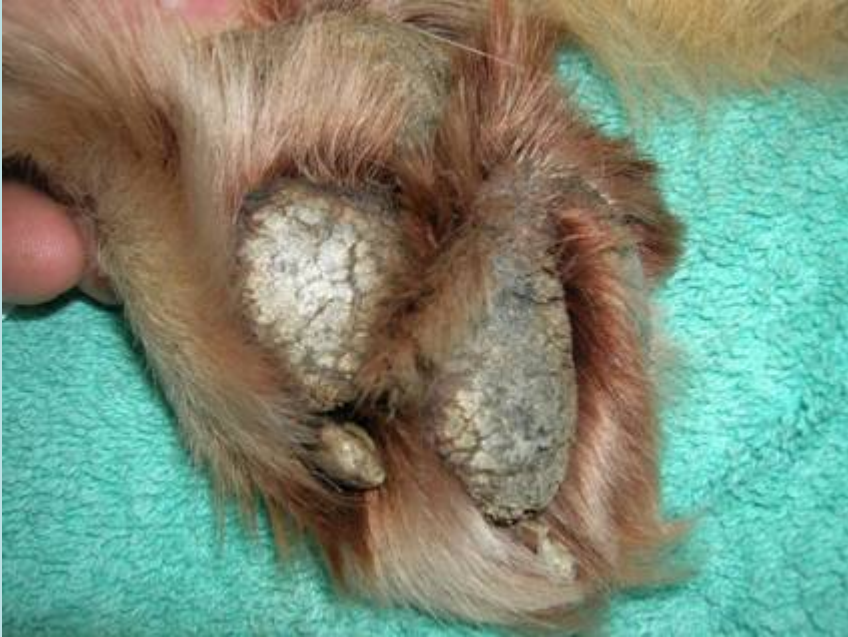- **Necrotizing dermatitis + hyperkeratosis**
- Footpad hyperkeratosis +/- fissures
- Erythema and erosion with hyperkeratosis at:
 - Mucocutaneous junctions (lips, nasal planum and genitalia)
 - Friction points (elbows, hocks and distal extremities)

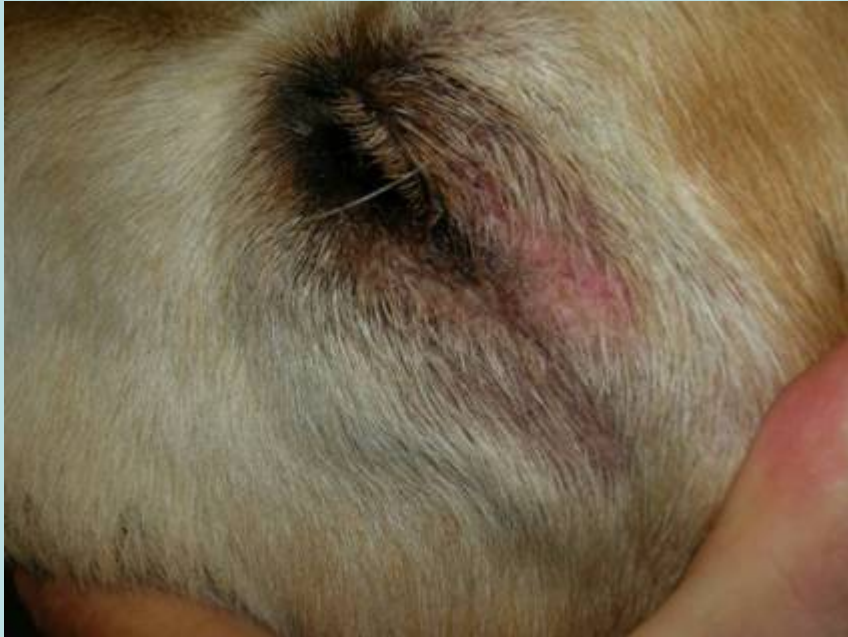Red Hyperkeratosis
White Necrosis and degeneration
Blue Basal cell proliferation



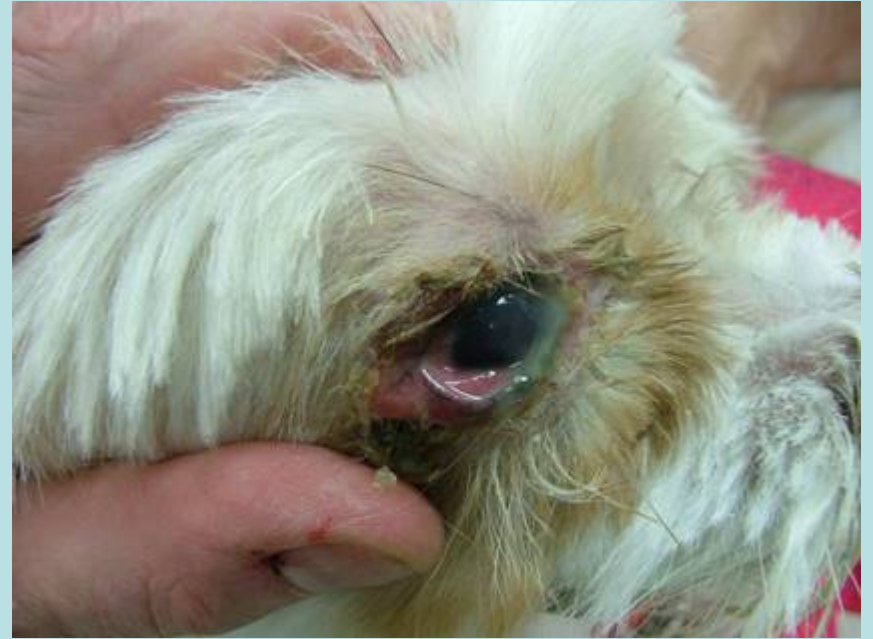







+ infection



Laboratory Findings - Variable

- Elevated liver enzymes
- **Decreased albumen**
- Elevated post-prandial serum bile acids
- Hyperglycemia
- Non-regenerative anemia.
- Ultrasound may reveal changes to the hepatic parenchyma that are more severe than suggested by biochemistry. Good sensitivity

Biochemistry values in hepatocutaneous syndrome

KOUTINAS, KOUTINAS, SARIDOMICHELAKIS, KALDRIMIDOU, ROUBIES

EJCAP - Vol. 12 - Issue 2 - October 2002

Table 4: Serum biochemistry results in six dogs with Metabolic Epidermal Necrosis.

Biochemical parameters	Cases						Reference values
	1	2	3	4	5	6	
Total proteins (g/dl)	8.4	5.5	7.8	6.8	6.5	6.8	5.8-8
Albumin (g/dl)	ND	1.70	0.5	2.1	2.1	2.8	2.5-4
Serum urea nitrogen (mg/dl)	12,1	7	30	8	12	12	7-30
Creatinine (mg/dl)	ND	0.5	1.1	1.4	0.8	1.1	0.5-1.5
Glucose (mg/dl)	84	81	185	104	122	184	60-120
Cholesterol (mg/dl)	ND	228	243	146	124	148	100-300
Total bilirubin (mg/dl)	ND	0.21	ND	0.45	0.38	0.5	0.1-0.6
Alkaline phosphatase – AP (U/L)	3135	131	40	340	390	2000	≤ 210
Alaninoaminotransferase ALT (U/L)	305	79	100	44	34	220	≤ 34
Creatine kinase – CK (U/L)	ND	ND	ND	55	45	22	30-120
Phosphorus (mg/dl)	6.2	2.5	ND	3.7	2.7	3.6	2.5-5
Calcium (mg/dl)	ND	8.4	9.8	8.0	6.6	7.6	8-12
Potassium (mEq/l)	ND	5	4.4	4	4.6	3.9	3.6-5.8

ND: Not done.

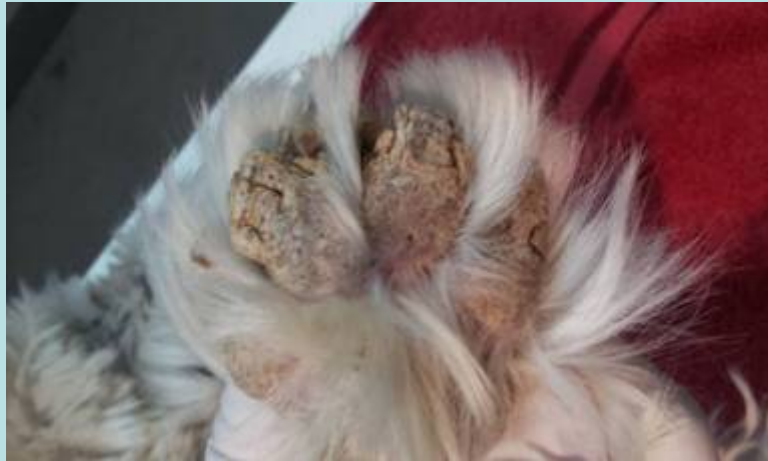Hepatocutaneous syndrome

Diagnosis

- DDX includes:
 - Zinc responsive dermatitis
 - Immune mediated disease (pemphigus, vasculitis)
 - Mucocutaneous pyoderma
 - Naso-digital hyperkeratosis
- Definitive diagnosis:
 - Histopathology (without secondary infection)
 - Demonstration of underlying cause

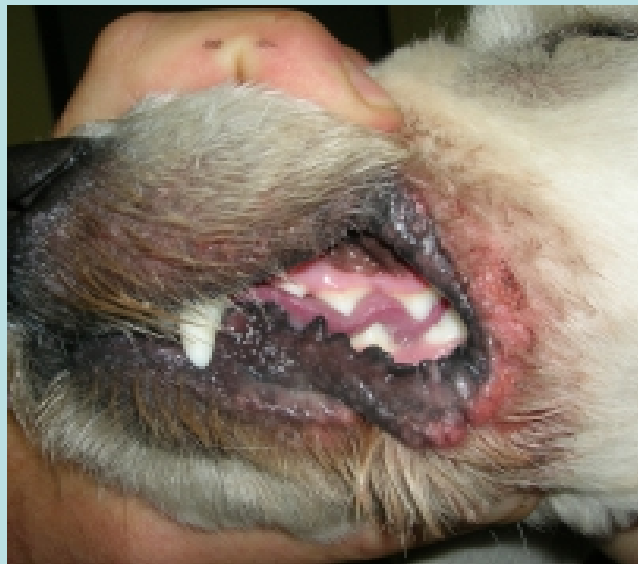Pemphigus foliaceus

Muco-cutaneous pyoderma



Idiopathic naso-disital hyperkeratosis

Zinc responsive dermatosis



Prognosis is often poor unless underlying disease can be corrected.

Treatment reports mostly single case

Amino acid supplements

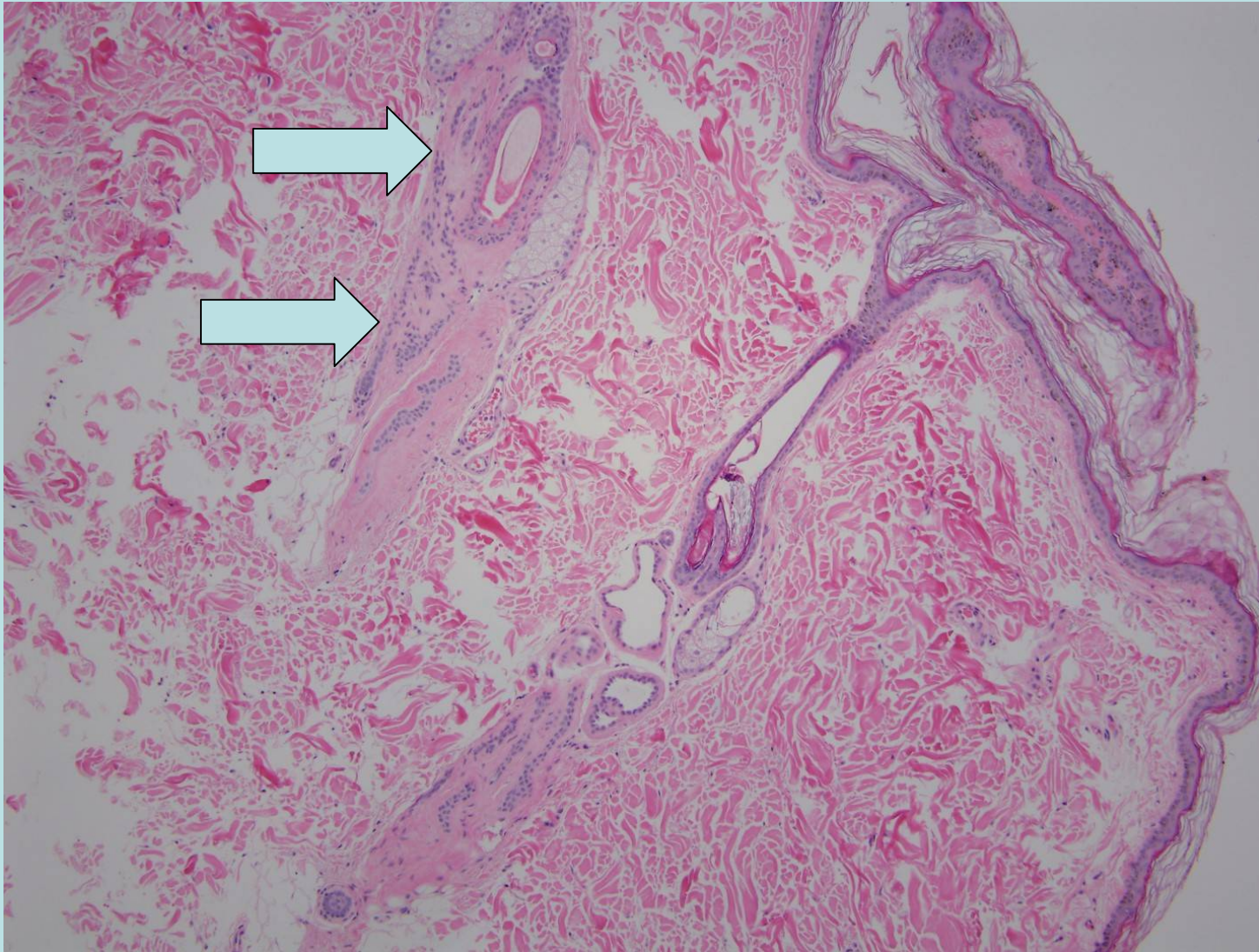
- IV infusions Hypertonic , irritating. Central line/large catheter. 25-40ml/kg slowly over 7-12 hours every 3-7 days. Then as required to maintain remission. May improve interval to add lipid supplement
- Oral body builder supplements. 1 adult dose/5kg Xylitol free! Can base on amino acid levels.
- Other supplements: Scrambled eggs, onion free chicken stock.

Other support treatment

- Zinc supplements
- Moisturizing hyperkeratosis areas
- Essential fatty acids
- Treatment of secondary bacterial and yeast infections
- Octreotide – glucagonoma Somatostatin analogue that inhibits glucagon release. 2µg/kg bid
- Corticosteroids topical and systemic
 - Decrease hyperkeratosis
 - Relieve inflammation and pain
 - May make underlying condition worse
- Apoquel (Oclacitibib) if pruritic

Epitheliotropic Lymphoma

- Majority malignant cytotoxic-T cells, probably memory cell class. Minority cases natural killer cells
- The primary target is the epidermis , in particular the hair follicles +/- mucus membranes. The dermis is later involved by invasion.
- Non-epitheliotropic lymphoma may involve the skin but involvement is primarily of the dermis. Nodular with other organ involvement



Courtesy of Dr Sherry Myers

Epitheliotropic Lymphoma

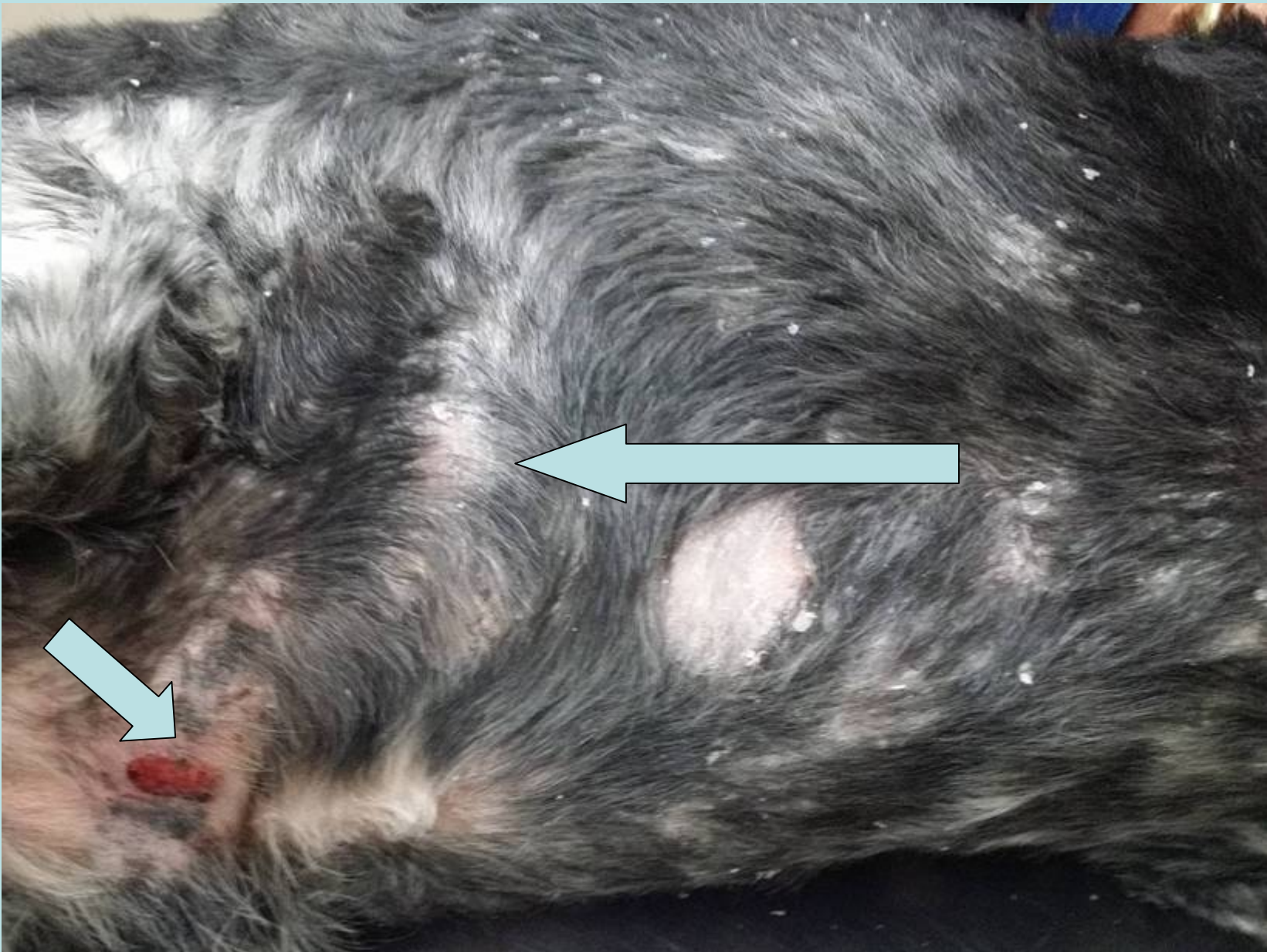
Human classification:

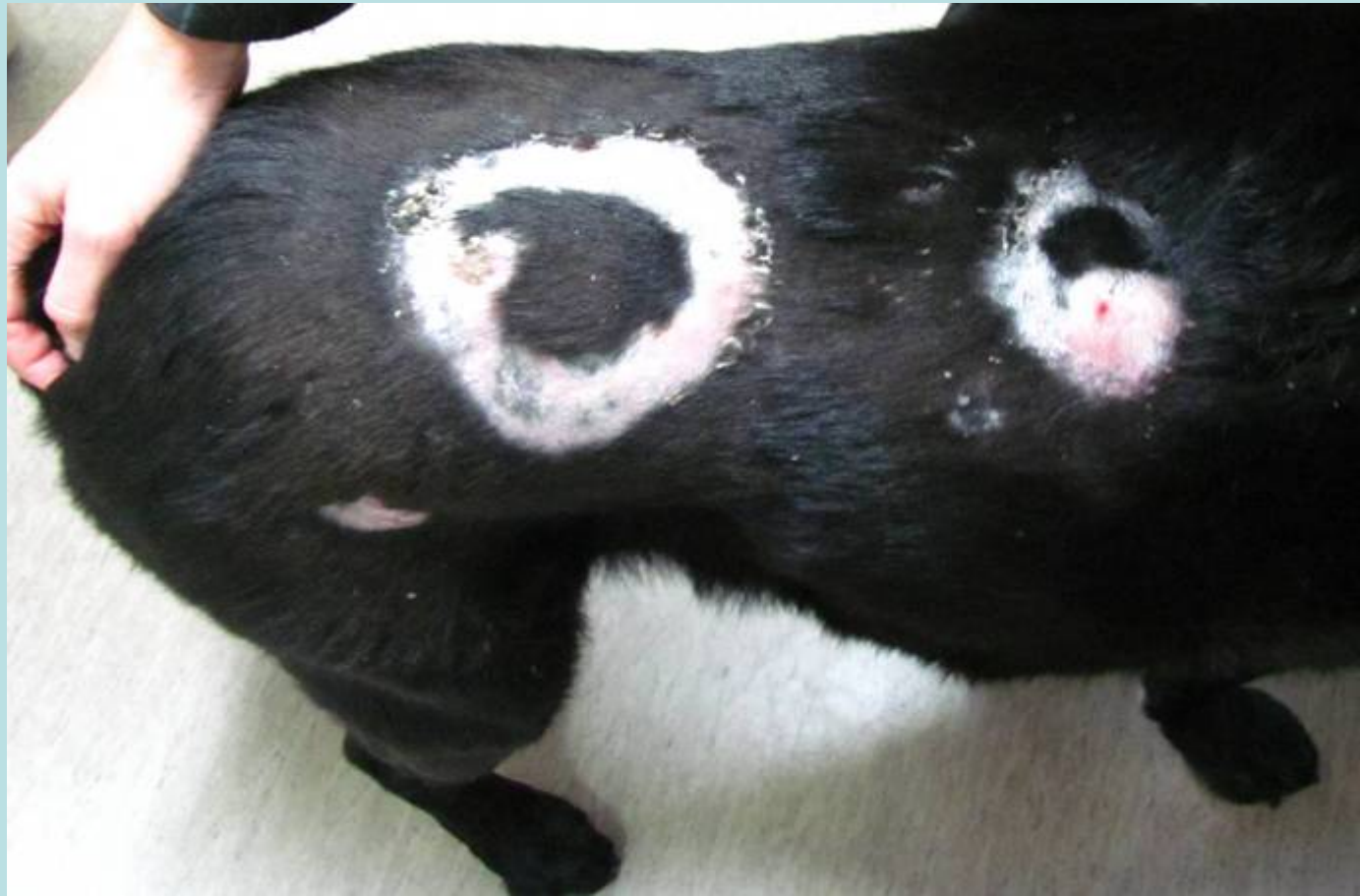- Pagetoid reticulosis. Limited to the epidermis. Localised plaque/erythema only (Woringer-Kolopp PR). Better prognosis? Not frequently diagnosed in animals.
- Mycosis fungoides involves both the epidermis, dermis +/- mucus membranes.
- Sézary's syndrome. Leukemia. Circulating malignant lymphocytes. Less common

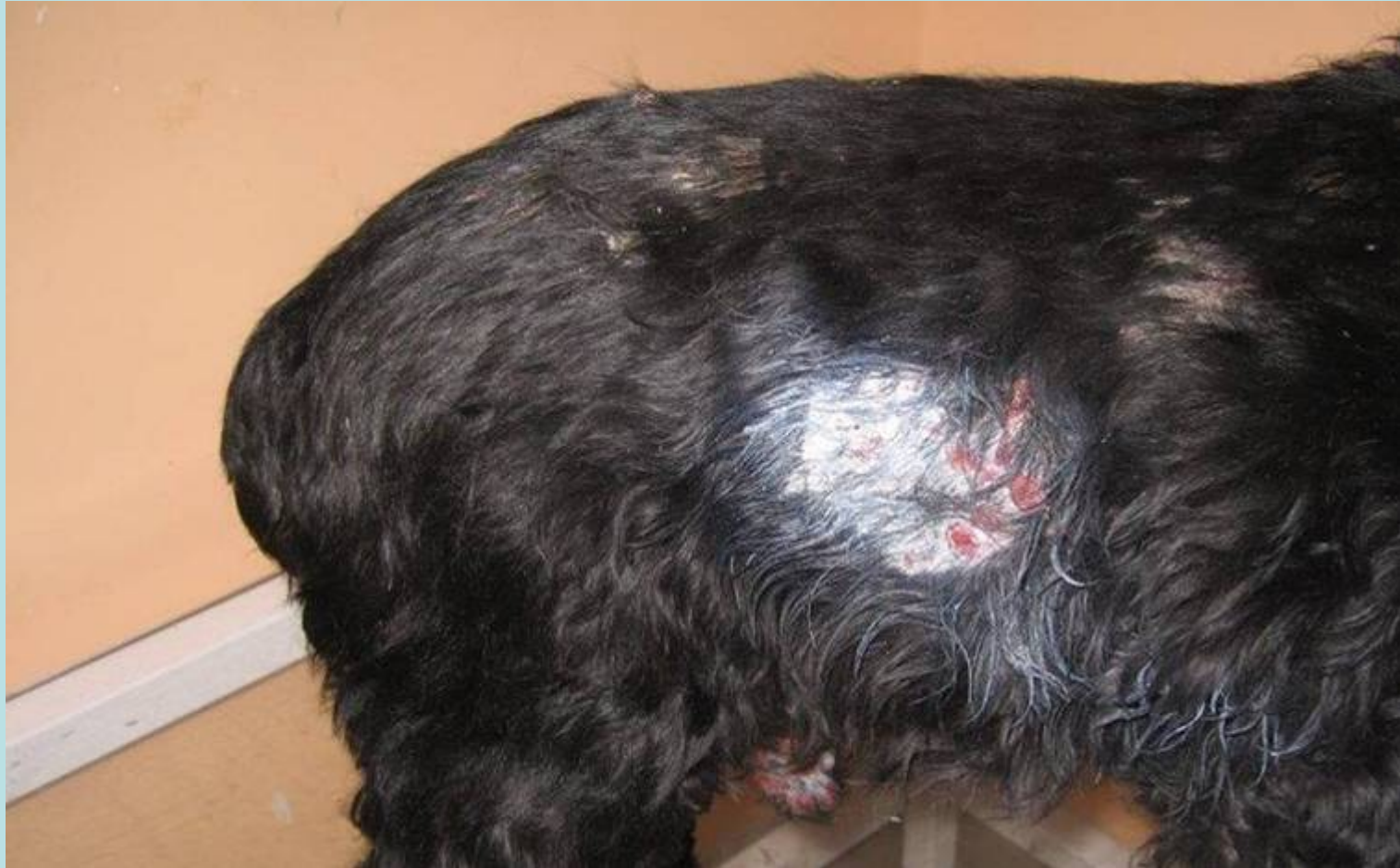Clinical picture

Pleomorphic and Variable

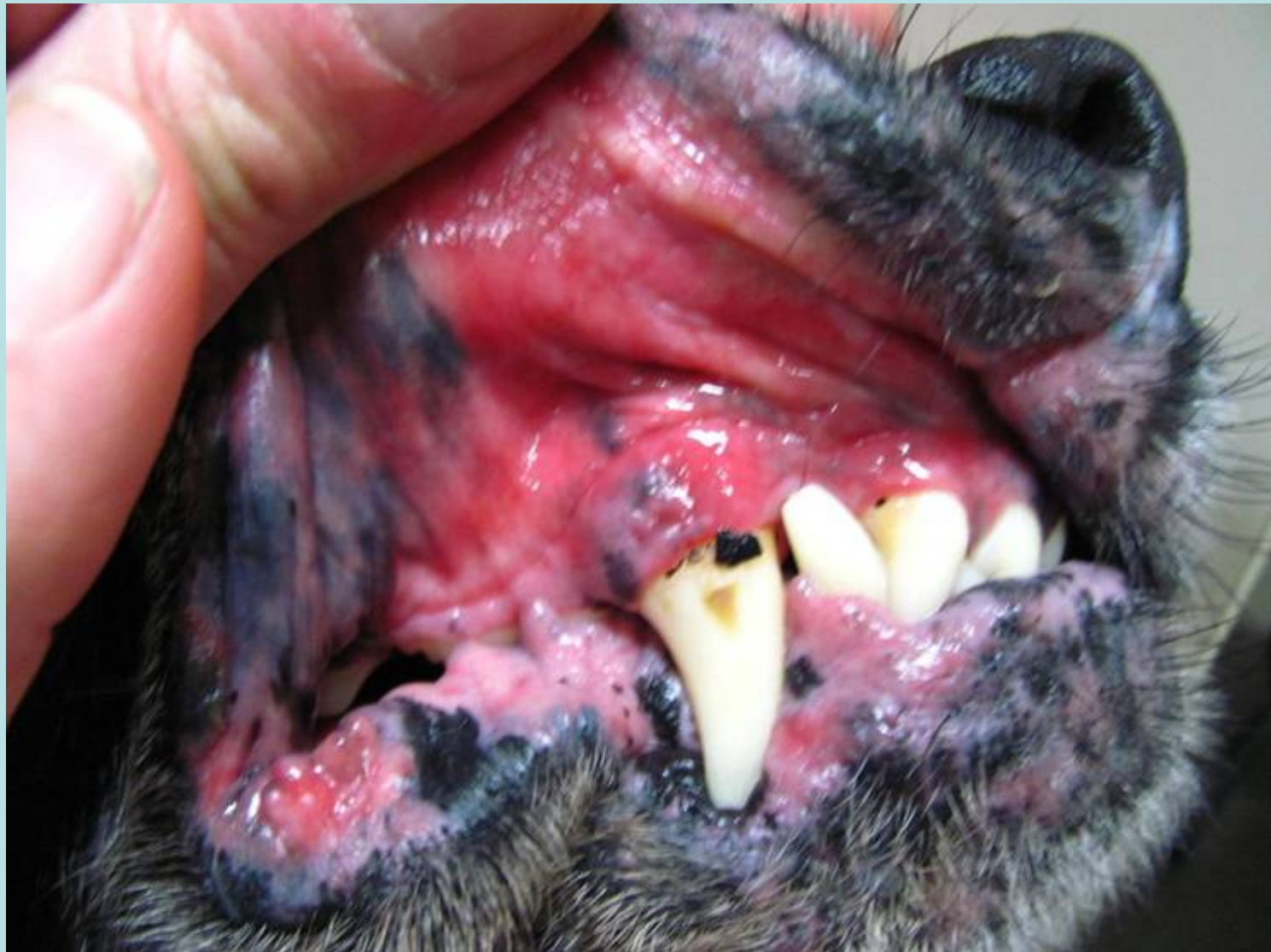- Older animals.
- Pruritus common
- Clasification based on stage. Frequent overlap
 - Erythemic macule(s)
 - Erythemic plaque
 - Exfoliative Erythroderma
 - Tumor stage (ulcers and nodules) advanced and aggressive

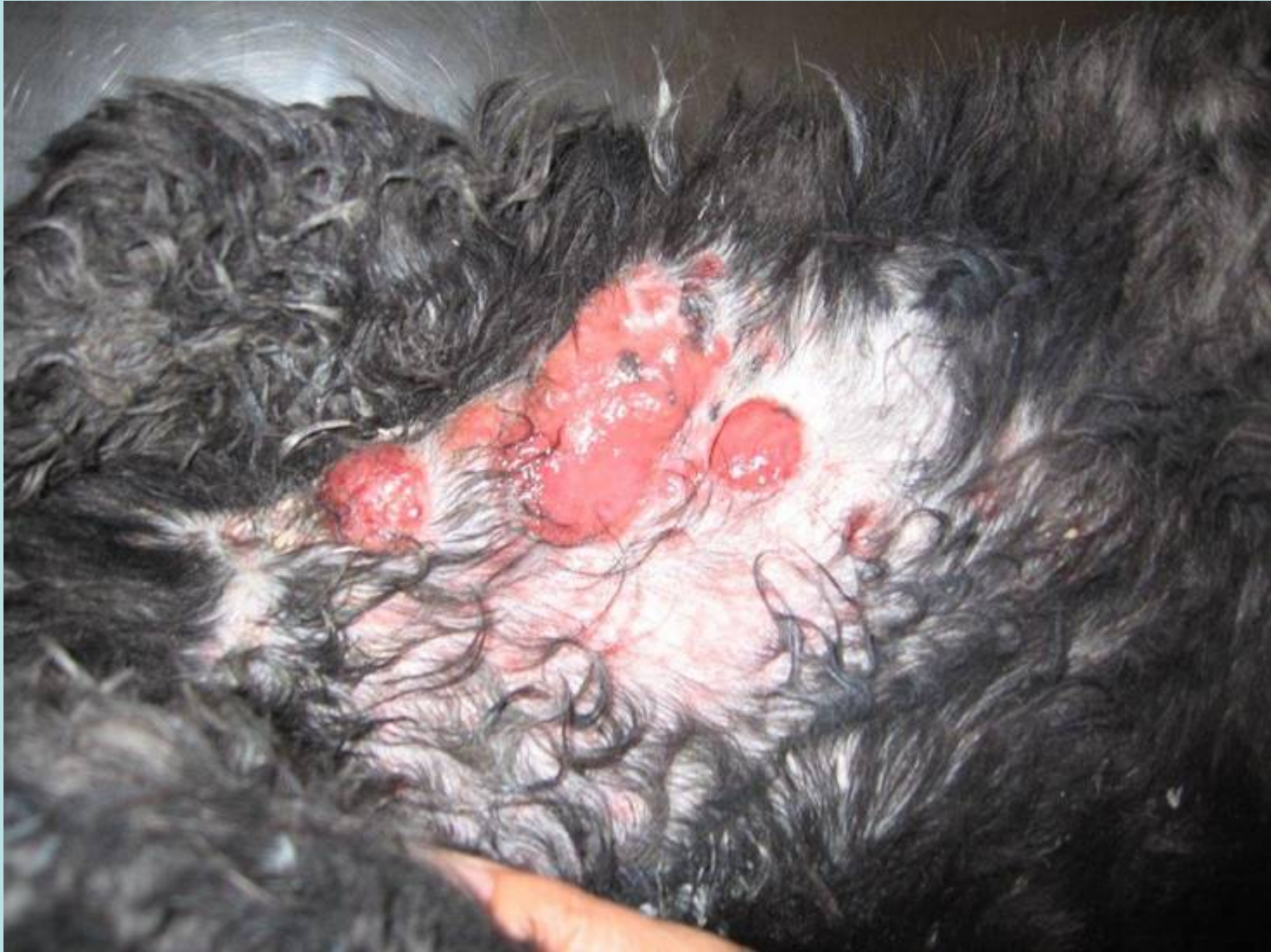




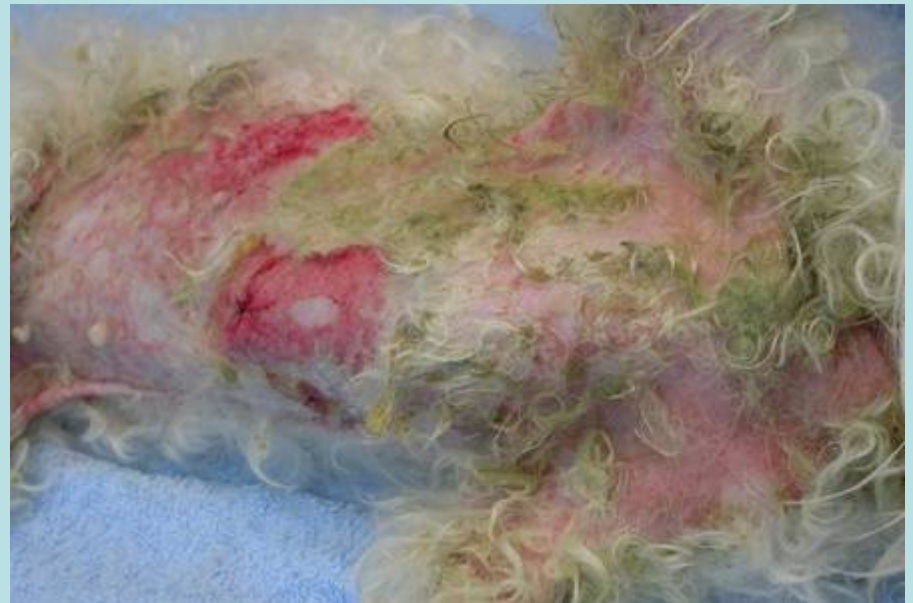
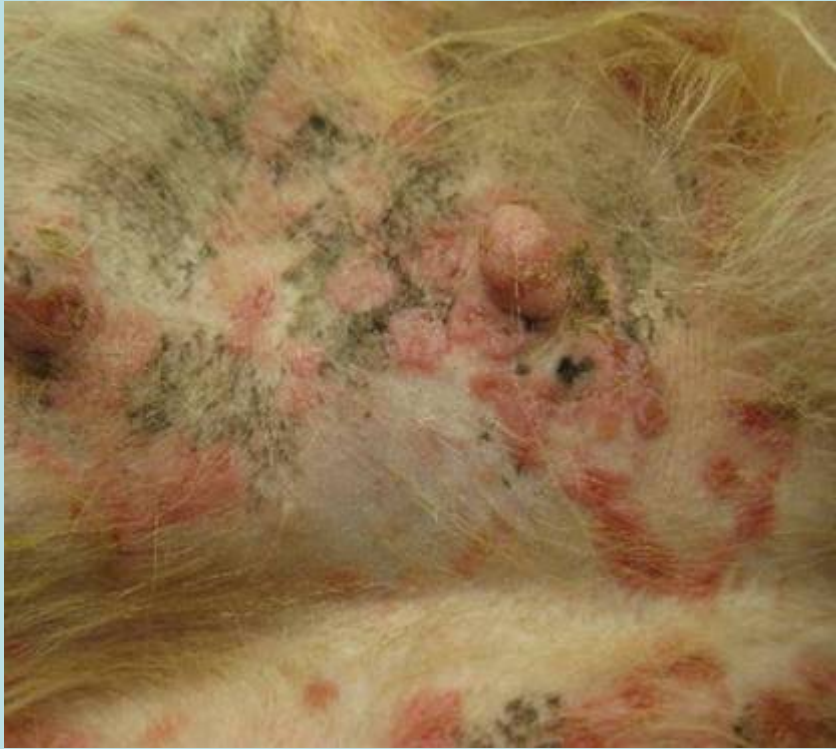Courtesy of Dr Janina Tran

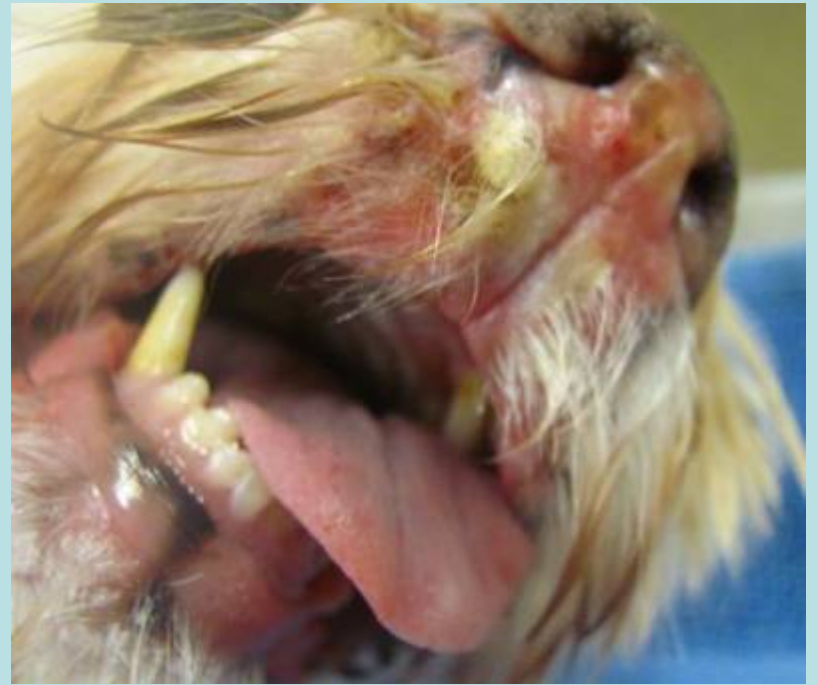
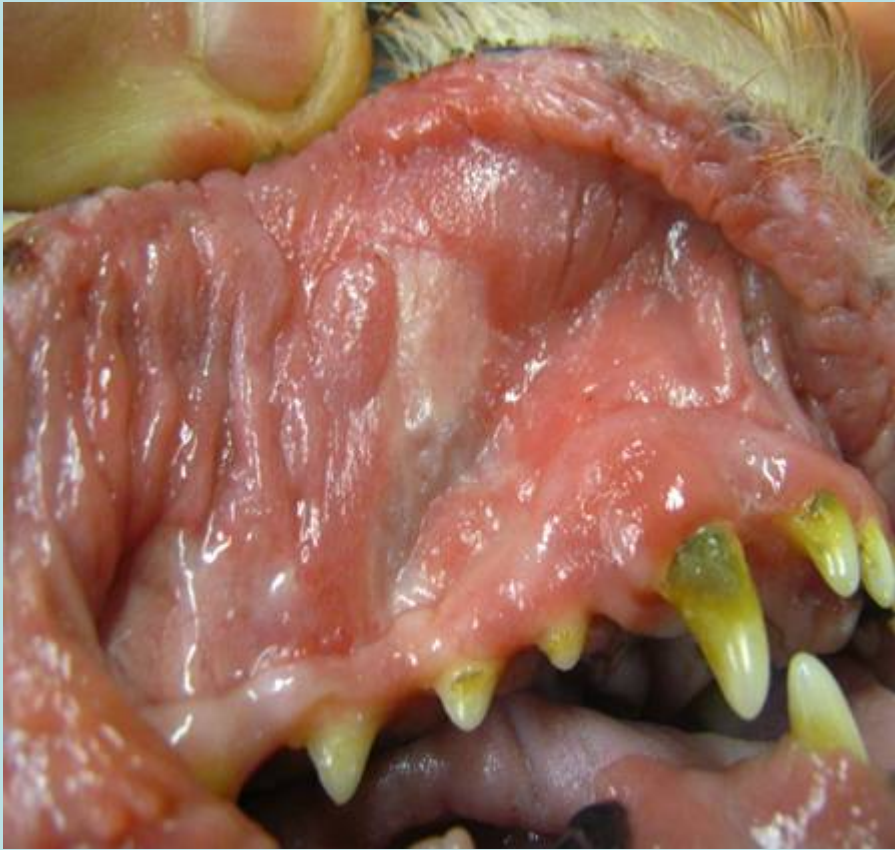


Courtesy of Dr Janina Tran



Courtesy of Dr Christian Collinot



Diagnosis of EL

The variability makes definitive visual diagnosis difficult.

- Onset of (severe) inflammatory skin disease in an older dog, possibly accompanied by pruritus
- Allergic skin disease, other than flea allergy and sarcoptes, it is uncommon to begin in older age.
- Potential differentials include:
 - Hepatocutaneous syndrome
 - Adult onset Demodex
 - Immune mediated disease (including drug reactions)
 - Pemphigus
 - Erythema multiforme
 - Nodular panniculitis
 - Other tumours
 - Nodular infections
 - Histiocytosis

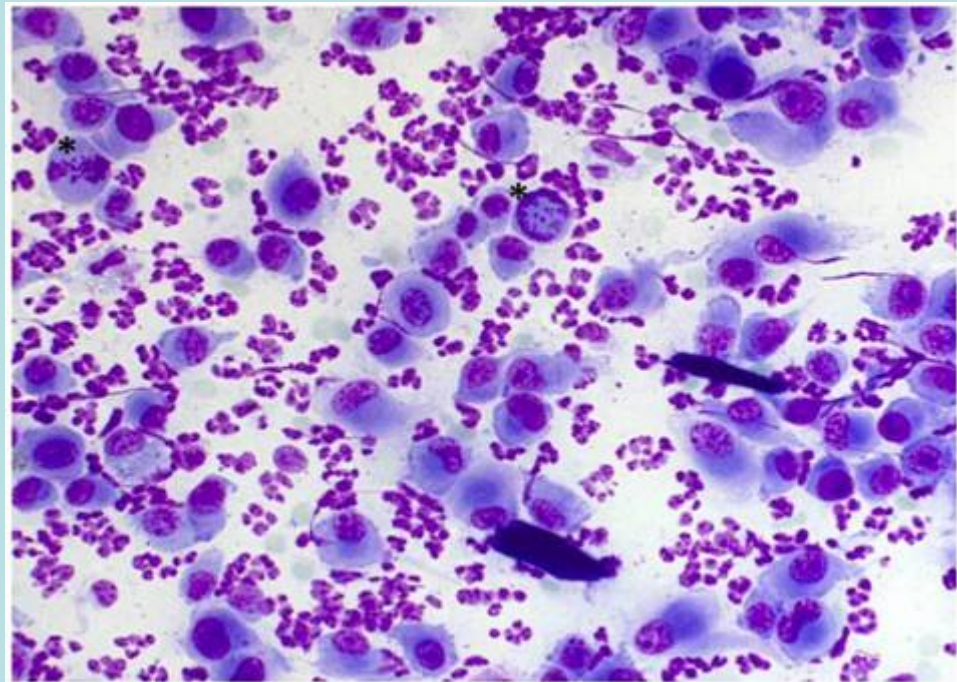
Cytology

Wipe and blot and
scrape

Round cell pattern

Often heavy presence of
neutrophils associated
with secondary infection
+/- bacteria

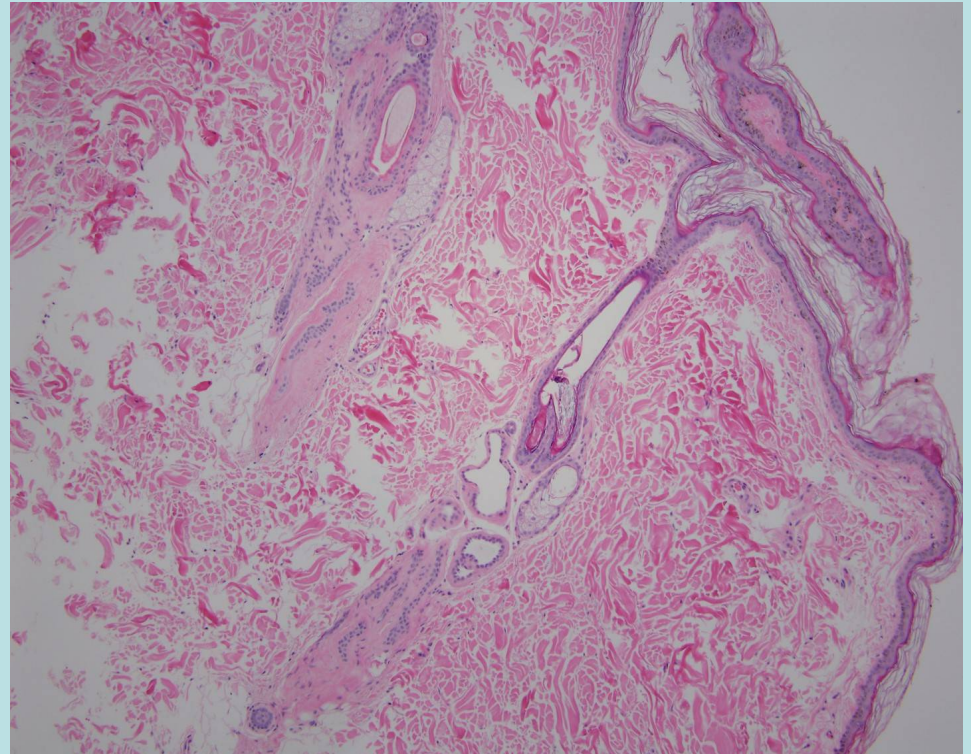
DDx cytology = other
round cell tumours or
(pyo)granuloma



Palumbo et al 2015
<http://dx.doi.org/10.1590/1678-4162-7575>

Histopathology and Immuno-histochemistry

- Epidermal and adnexal trophism
- Majority CD3+ (T cell)
 , CD79 – (B cell)
 CD8+ (cytotoxic t cell)
 CD4- (T-helper)
- Minority CD3+/CD8-
 /CD4- (natural killer
 cells)
- Not prognostic



Treatment and Prognosis

- Guarded. 3-6 months in most cases. Not related to immunohistochemistry
- Chemotherapy likely to have enhanced quality of life.

Corticosteroids

Risk = severe suppression and Cushing's syndrome.

Proton pump inhibitor or H2 Blocker (GI ulcers)

Topical in combination

Monotherapy (author's protocol)

2mg/kg prednisolone once daily for 14 days then reducing by 25% every 10-14 days to a target of 1mg/kg every 2nd day if possible

With CCNU (author's protocol)

Prednisolone 2mg/kg day 1-12 of CCNU cycle

CCNU Loumustine

- Orally every three weeks. (60 – 70 mg m²)
- Haematology and biochemical profile to beginning and 12 days after each individual dose.
- Potency between compounding pharmacies varies
- **Side effects** (Heading et al 2011 , 206 cases)
 - Neutropenia 57%
 - Anaemia 34%
 - GI signs 39%
 - Vomiting 24%
 - Potential renal toxicity 12%
 - Thrombocytopenia 14%
 - ALT increase 49%
- Suspend treatment if neutrophils <2000 , ALT > 400-500 or other critical indices indicate
- Modify dose if re-occurring

Controversies

CCNU +/-pred vs Pred monotherapy

- 46 cases, multi-institutional CCNU only
Risbon et al 2006
 - Survival time not evaluated
 - Response rate 83% with 32% complete remission and 50% partial
 - Median cycles to response = 1
 - Median response duration 94 days (22–282)
- 30 cases Fontaine et al 2009
- Median survival times (months)
 - CCNU 6
 - Prednisolone monotherapy 4.5
 - No treatment 3
- Due to small sample size, no statistical difference
- Quality of life improved regardless of which treatment

Other treatment modalities based on small numbers of cases or individual reports:

- **Retinoids: Acitretin** (1-2mg/kg SID) combined with prednisolone (2mg/kg SID) +/- CCNU. Retinoids have a relatively good safety profile in dogs but owners need to be aware of their teratogenic potential if women of child-bearing age are exposed. **Some evidence that survival times prolonged with retinoid use**

- **Fatty acid supplementation:** High doses of sunflower oil (75% linoleic acid – omega-6). If tolerated, this represents a benign, inexpensive adjunct treatment.

- **Interferon:** Anecdotal reports that human interferon- α (Roferon Roche) sub-lingual/ buccal pouch 20,000 IU daily) or recombinant feline interferon- ω at 1-3 million IU/m² body surface area three times weekly. **Benign adjunct**

- **Radiation** of spot lesions

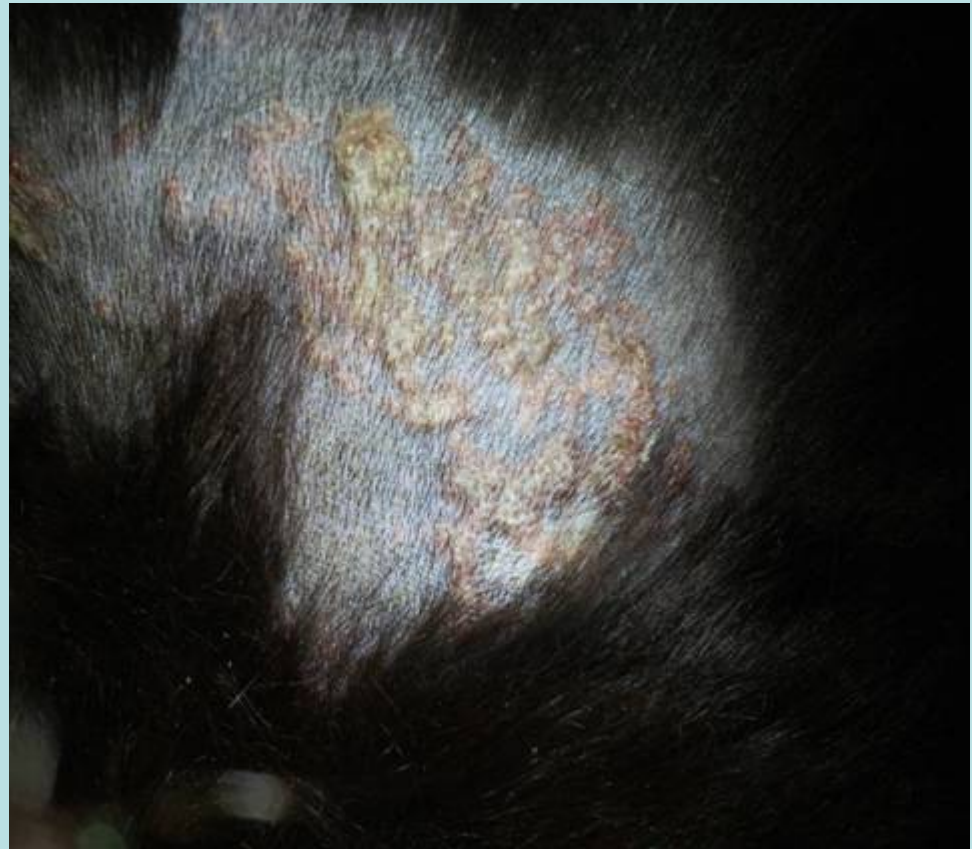
- **Topical nitrogen mustard. RISK**

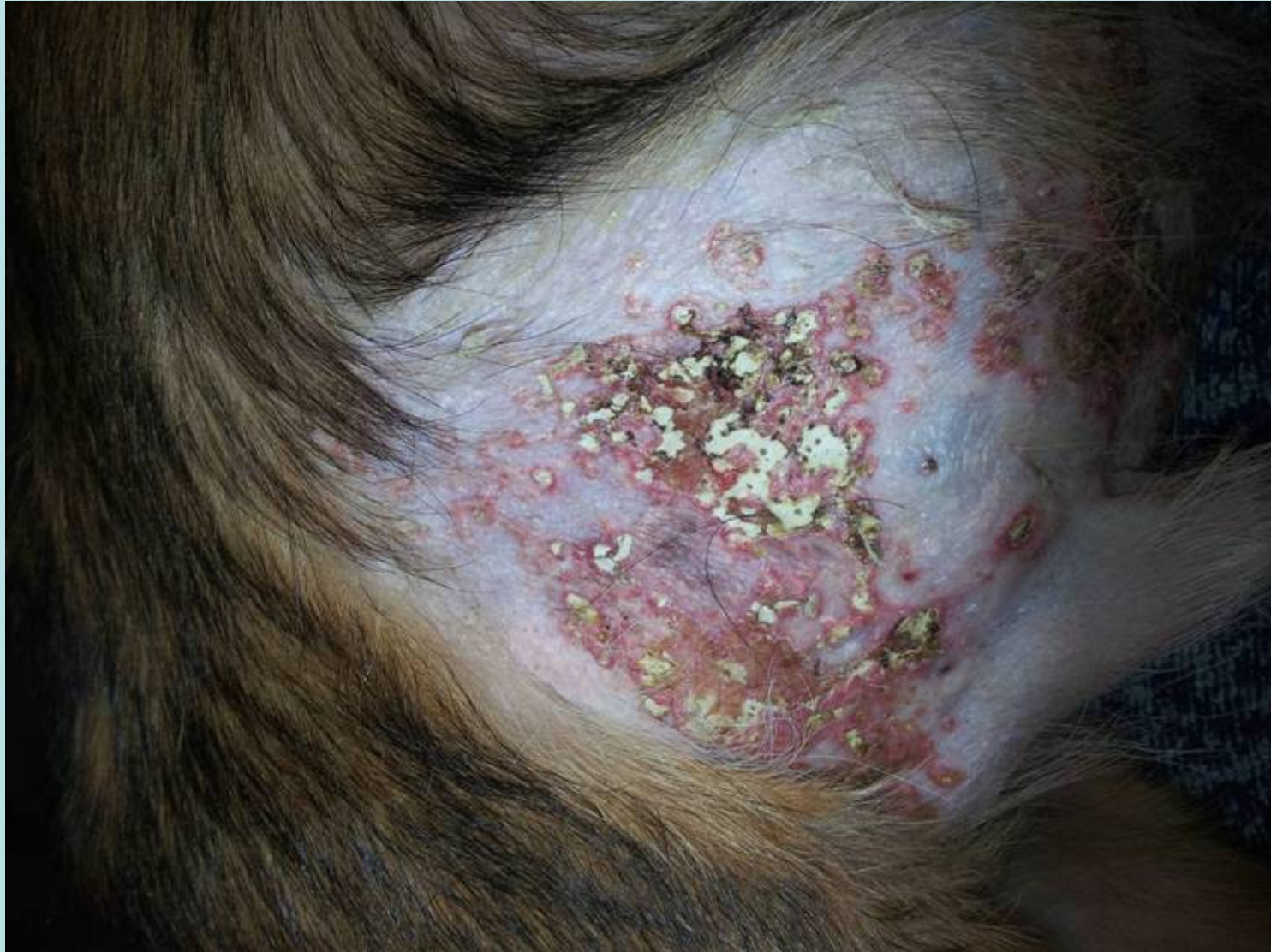Calcinosis Cutis

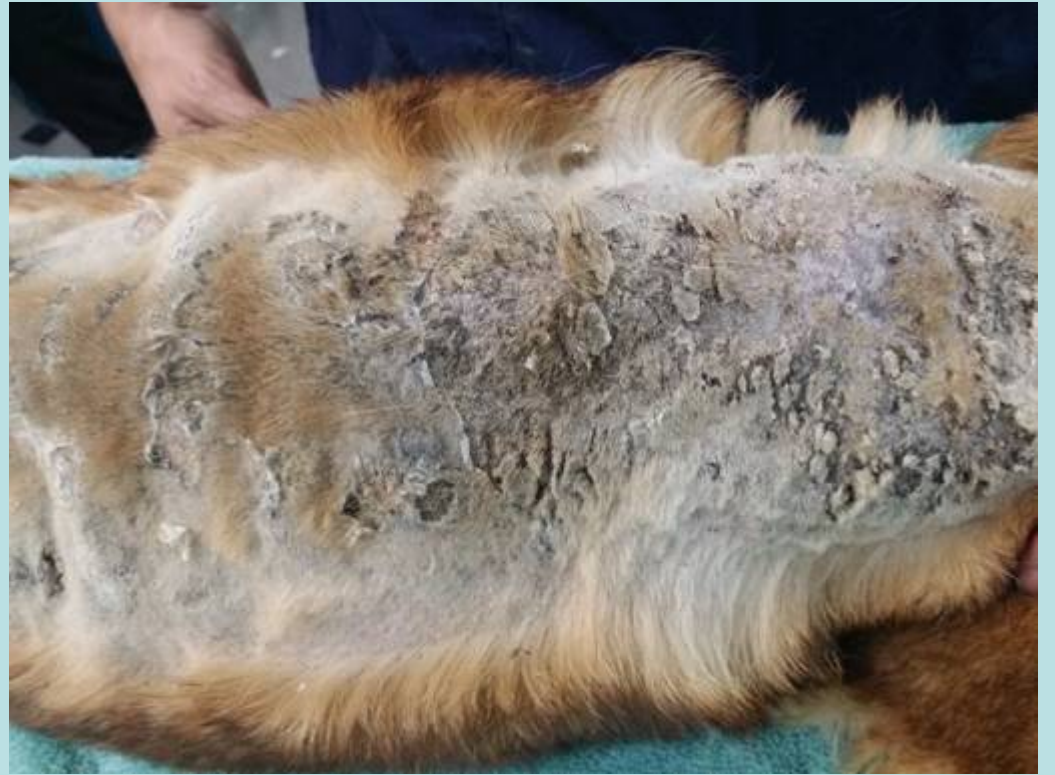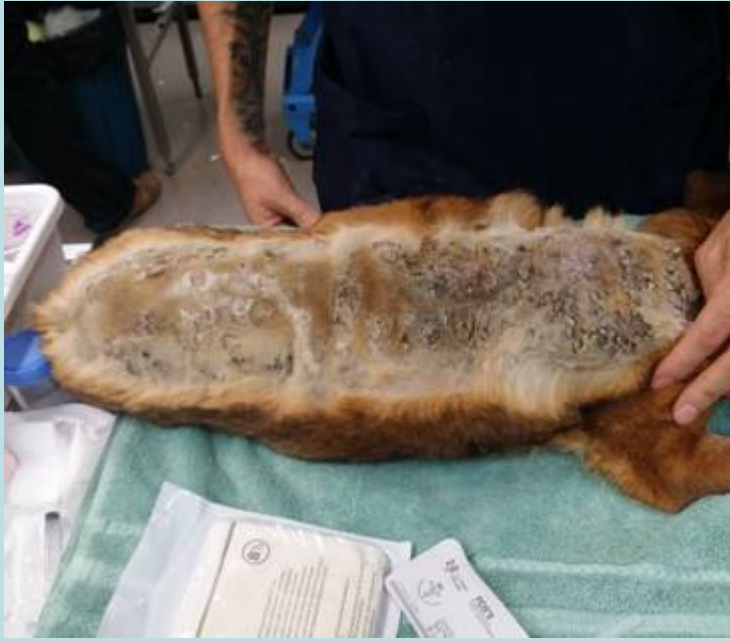- Deposition of calcium salts into all layers of the skin beginning in the perifollicular dermis
- Almost always associated with canine Cushing's syndrome
- Not specific for spontaneous (adrenal or pituitary) or iatrogenic
- Occasionally seen in hypercalcemia and hyperphosphatemia associated with renal , neoplastic or parathyroid.
- Very rarely, idiopathic

Classical lesions

- Pale pink plaque
- White areas often detectable
- Often pruritic
- May be infected



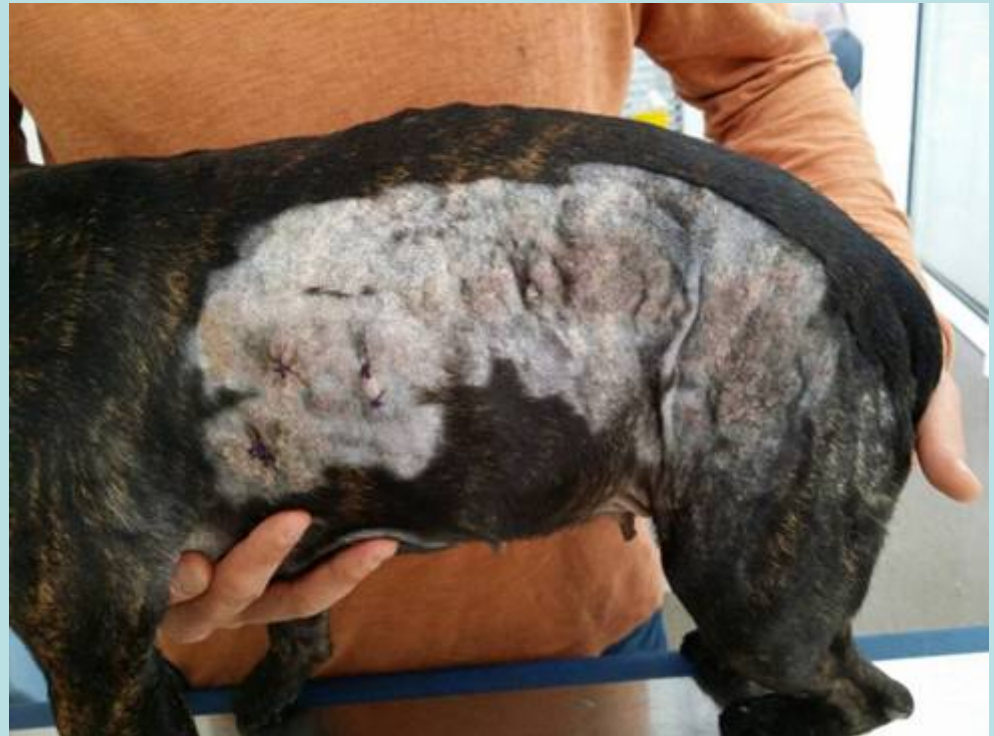
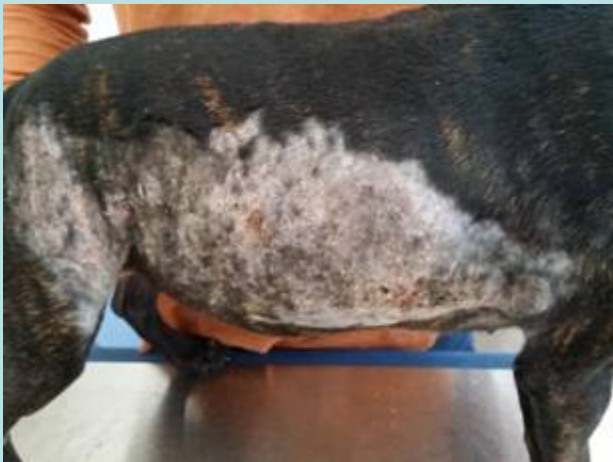


Signalment:

- Signalment: Female desexed, Staffordshire
- Bull Terrier, 3.5 years of age
- **Severe pruritus and owner complained of “lumpy” skin**
- Receiving prednisolone 10mg every second day for last 9 months.

Kiaya



Treatment of Calcinosis Cutis

- Treat the underlying disease
- Tetracyclines chelate calcium and have an antiinflammatory effect. Minocycline 5mg/kg 2x day
- DMSO topically
 - Initially twice daily (if tolerated) then daily
 - Beware drying. Use moisturiser
 - Owner protection
- Treat infections
- Oclacitinib (Aopquel) for pruritus

THANK YOU

