

# PRIMARY CARE HAWAI'I CONFERENCE

June 22–26, 2026

Kaua'i, Hawai'i

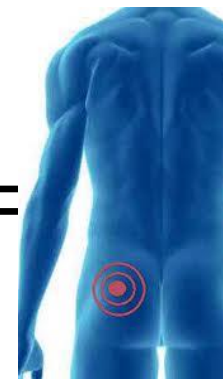
GRAND | HYATT<sup>®</sup>

KAUAI RESORT & SPA

20 hours  
AAFP  
CME Credit

BACK + HIP (Pain) =

---

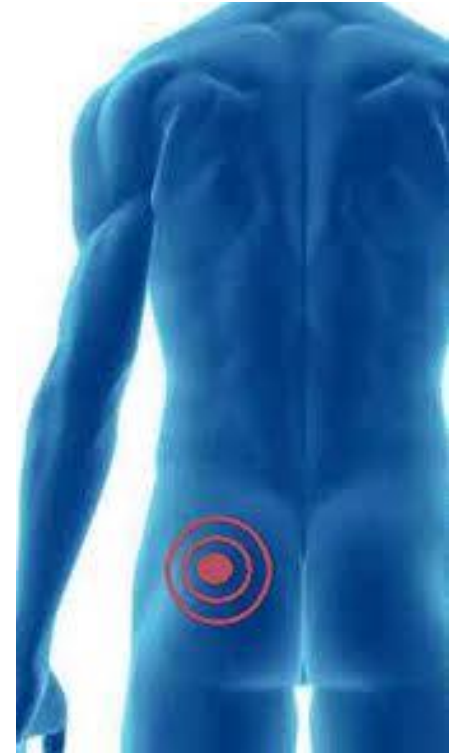

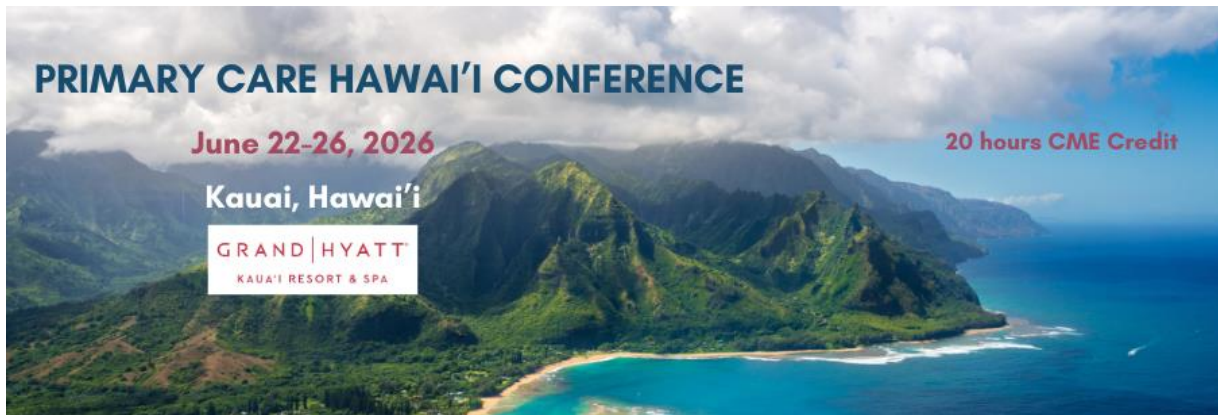Todd Weitzenberg MD

Kaiser Permanente Santa Rosa



The “HACK”





## Disclosures:

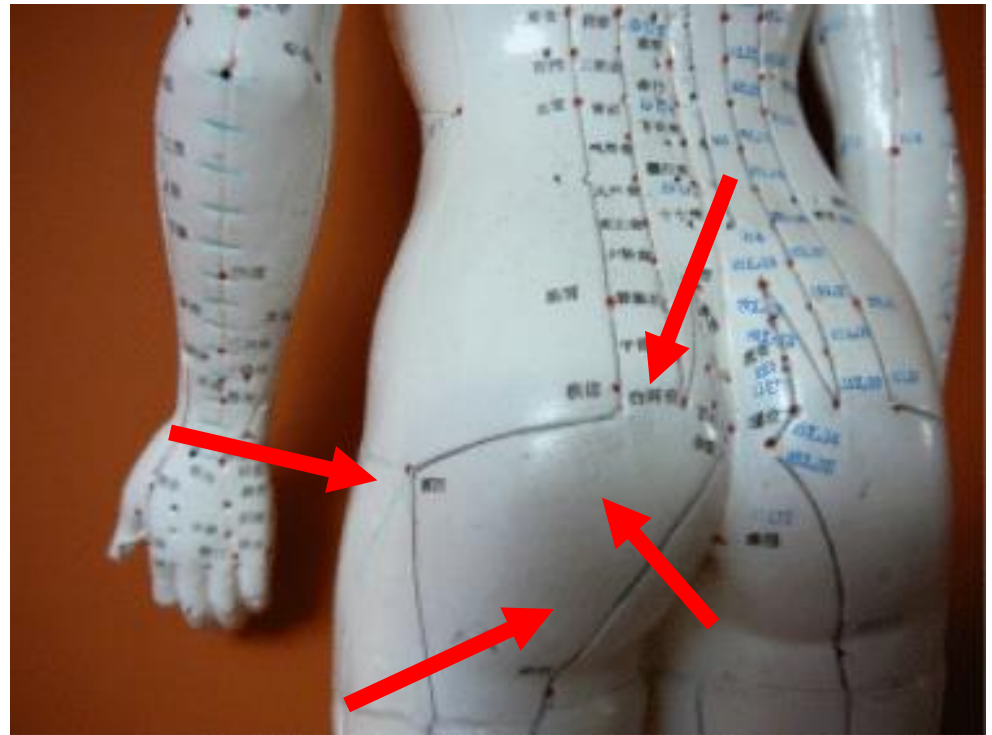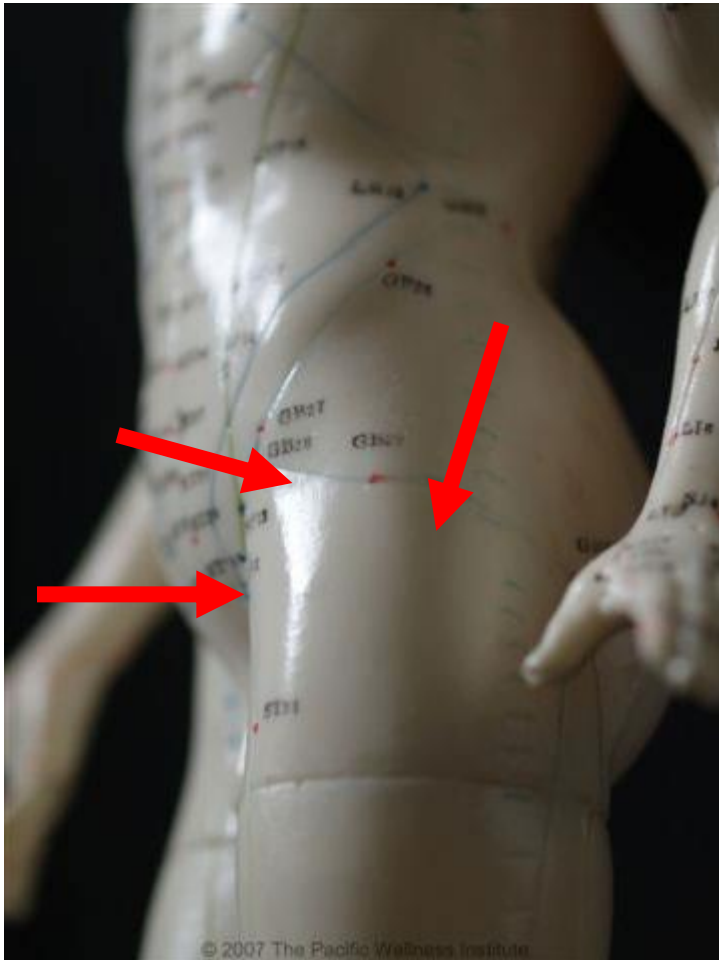- **Dr. Todd Weitzenberg has no relationships to disclose.**

# Objectives

- Accurately and efficiently manage hip pain in the primary care setting.
- Identify red flags for hip pain.
- Appropriately order imaging studies.
- Know when to refer to a specialist.

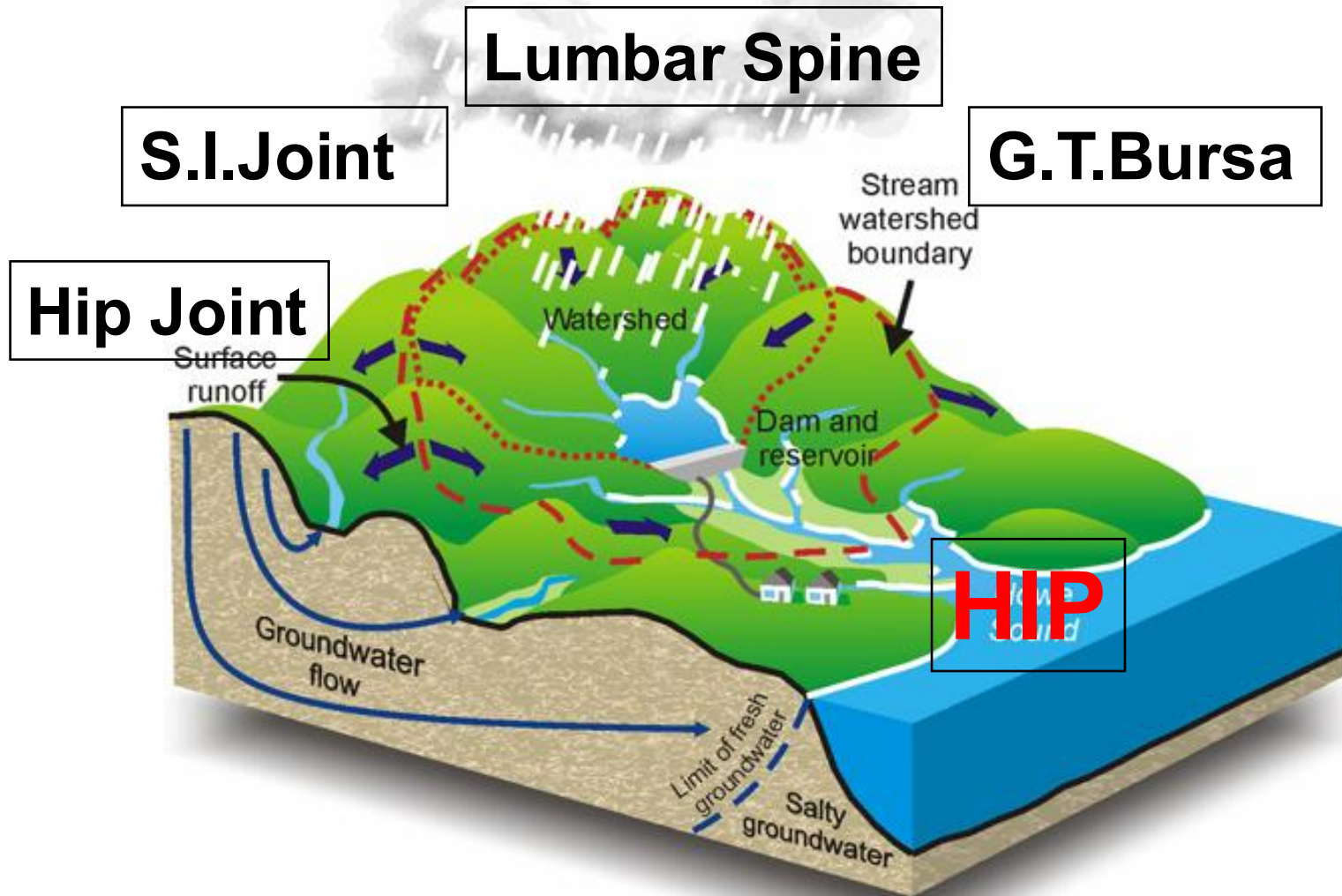
Where does it hurt?

My 'HIP'...



# “THE HACK”

Watershed Zone



# 45 y.o. female runner

- ▶ Pain in the 'hip'
- ▶ Aching, sore, some mild radiation into posterior thigh
- ▶ Some mild numbness and tingling post thigh
- ▶ Sometimes feels weak
- ▶ No known trauma
- ▶ Not better with ice, heat, stretching, ibuprofen

**KAISER PERMANENTE** Sports Medicine  
**Confidential Patient History Questionnaire**

Name	Medical Record Number	Sex
Year at school/Employer	Age 45 Height 5'5" Weight 140	<input type="checkbox"/> Male <input checked="" type="checkbox"/> Female
Sport/Athletic Activity	School/Team/Occupation	Dominant Hand
Running	Social Worker	<input type="checkbox"/> L <input type="checkbox"/> R
Approximate date injury occurred/pain began?	2 months ago	
Describe how injury occurred/pain began	Training for 1/2 marathon	

**Pain Diagram**  
Rate your pain today (mark with X's)

**Pain Scale**  
Rate your pain on this scale  
0 = No pain, 10 = Worst pain possible

**Pain Diagram**

**Past Medical History**  
Describe any chronic/acute medical conditions: Thyroid

Have you ever had this/similar injury before? If so, when? No

Have you ever had surgery before? If so, please describe type and when. Gallbladder

Which treatments have you already tried?  
 Heat  Physical therapy  Chiropractor  Medications  
 Ice  Athletic trainer  Other

List current medications and supplements: ibuprofen 600mg

Is there anything else we should know that could help us take care of you?  
Fix the problem!

What do you hope to accomplish with this consultation?  
Get an MRI

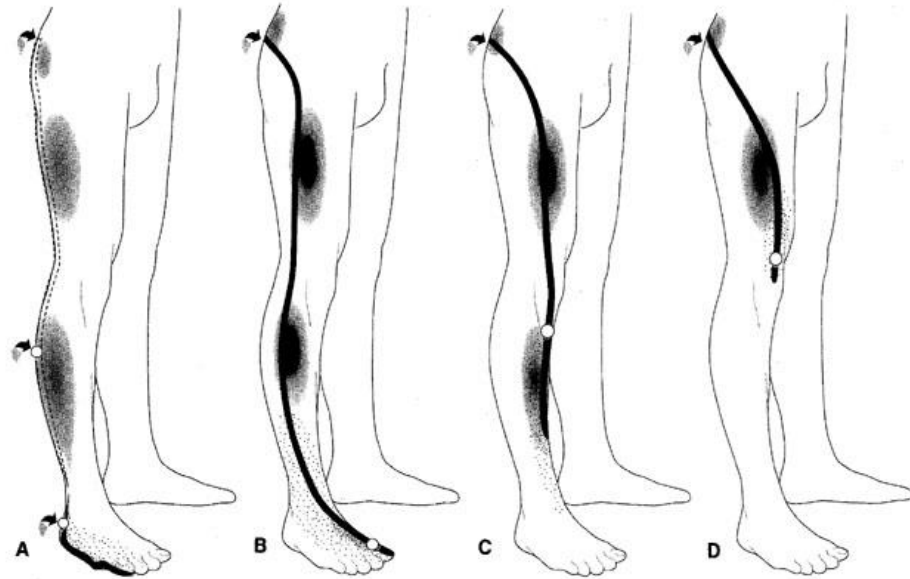
To the best of my knowledge, all of the above is true  
Signature \_\_\_\_\_ Date \_\_\_\_\_  
Signature of Parent/Guardian if under 18 years old \_\_\_\_\_ Date \_\_\_\_\_

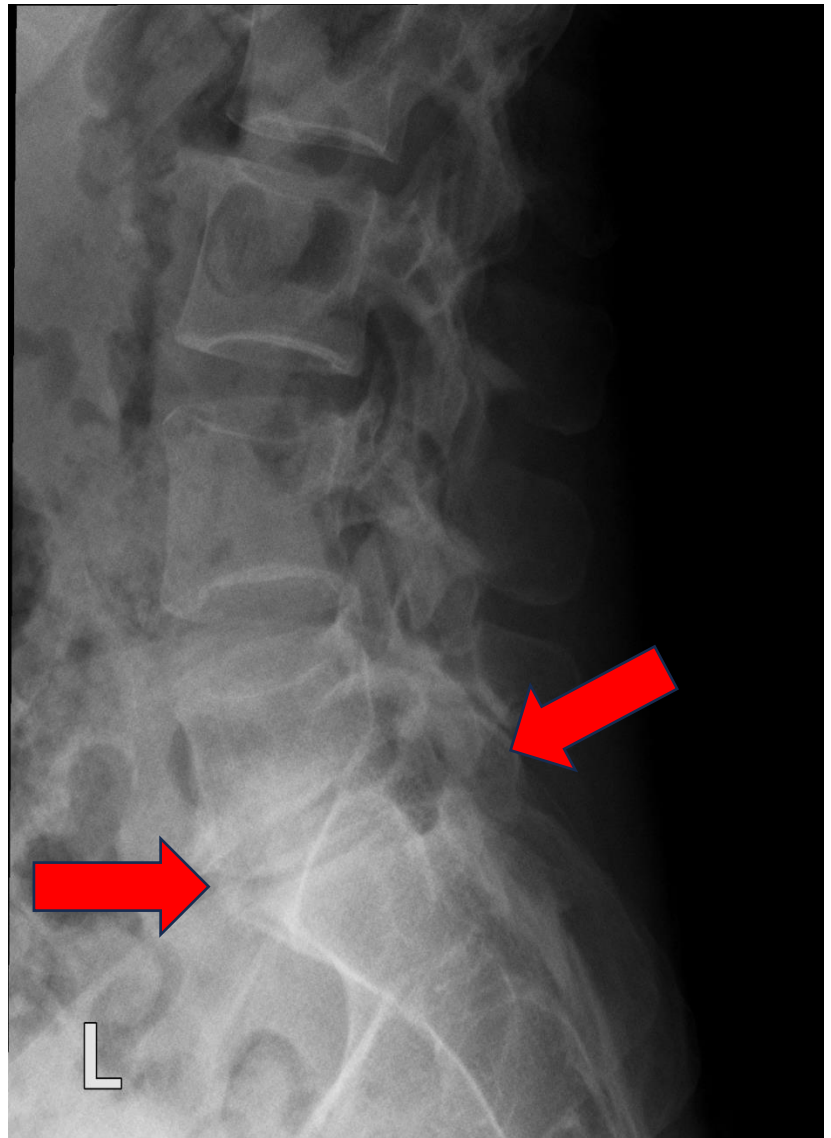
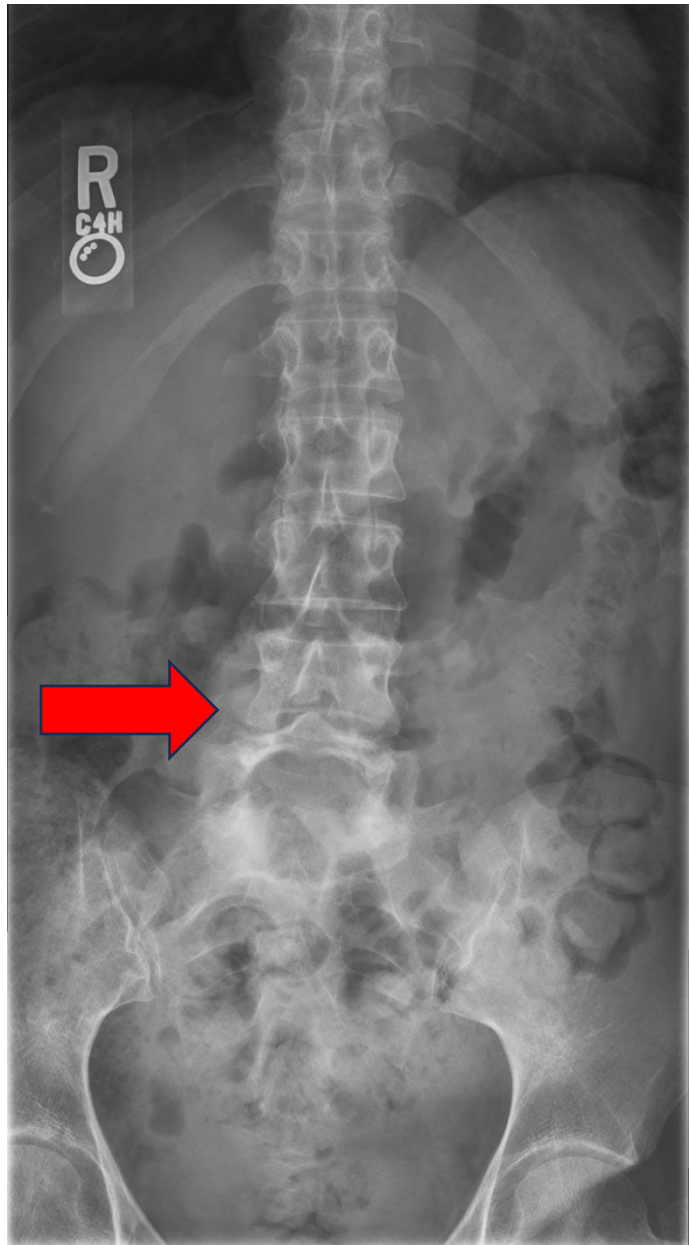
# Physical Exam

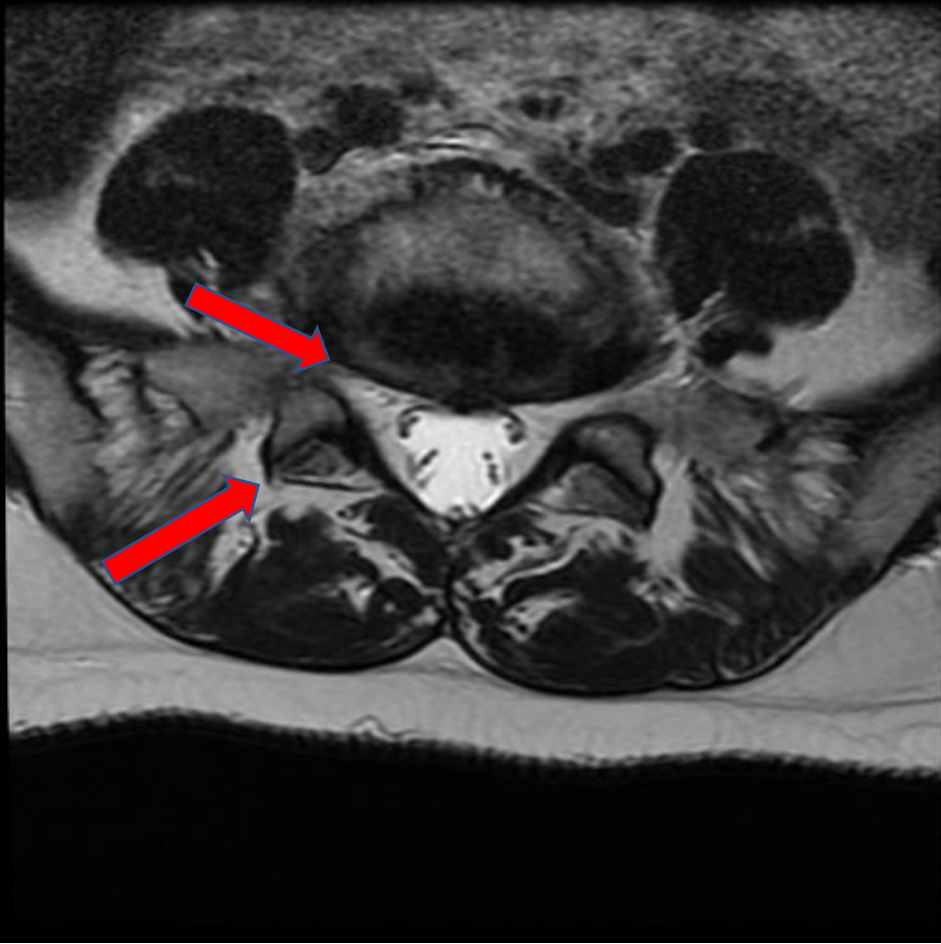
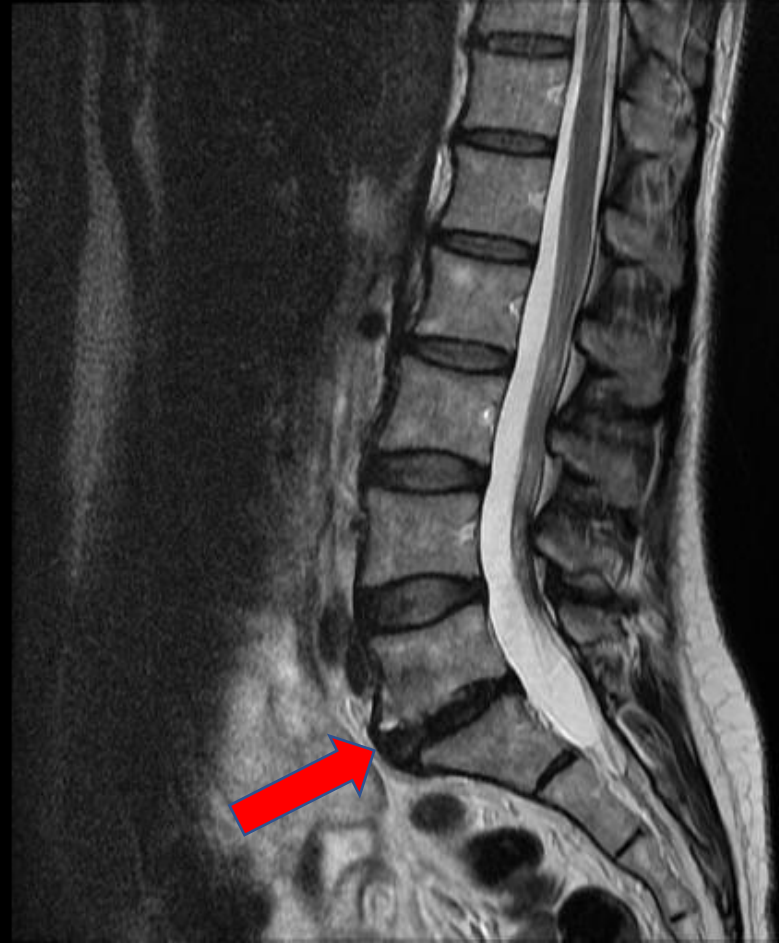- TTP over right side, lumbosacral junction, sciatic notch and superior aspect of SI.
- Pain in same location with SLR , hip internal rotation and FABER's.
- Pain with flexion and extension of Lspine, greatest with combined Ext-Lat.Rot-Right.
- Antalgic gait favoring right hip.
- Neurovascular exam intact.

## Lumbar Radiculopathy

- Pain from lumbar roots often starts in 'buttocks'
- Neural tension?
  - Pain in hip with provocation
- Neurologically intact
- Hard to tell?







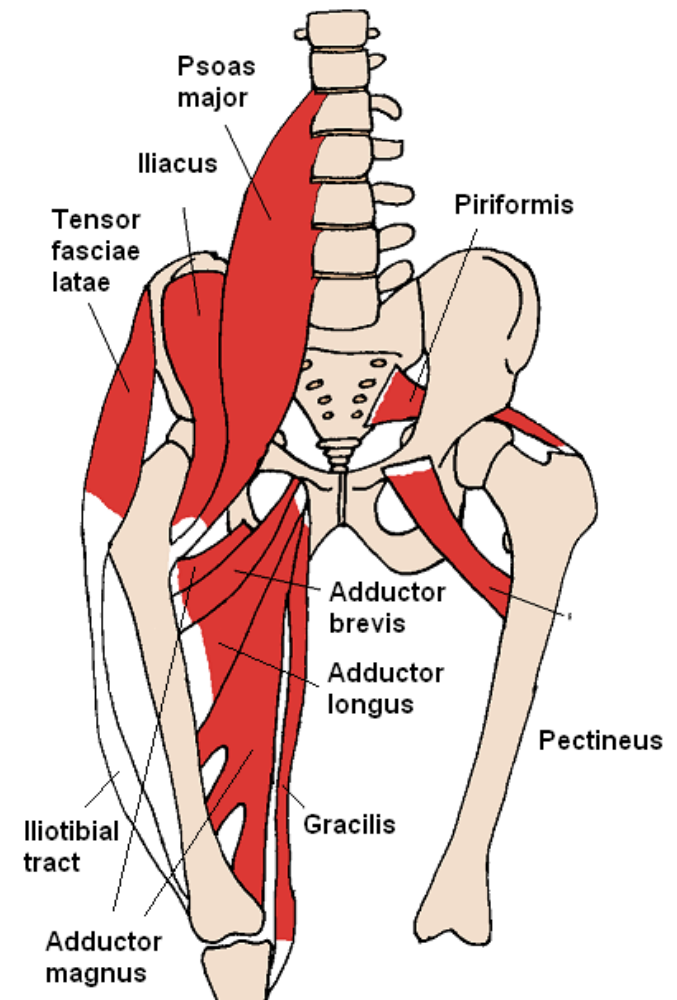
# Lumbar Etiology?

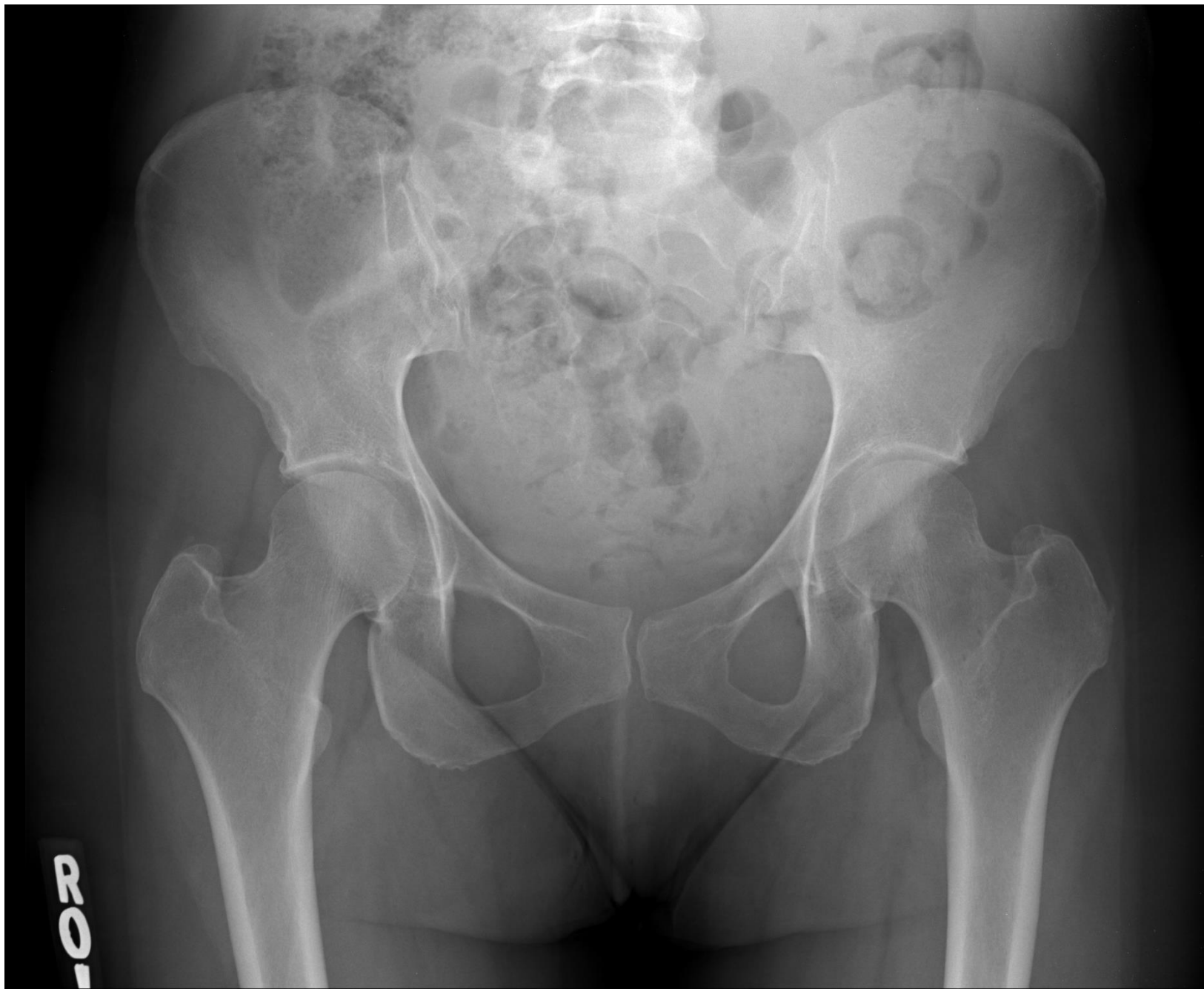- No significant symptoms in leg
- Neurologically intact
- Failed to improve with conservative treatment:
  - Rest, ice, heat, nsaids
  - Massage, chiropractor
  - Physical therapy

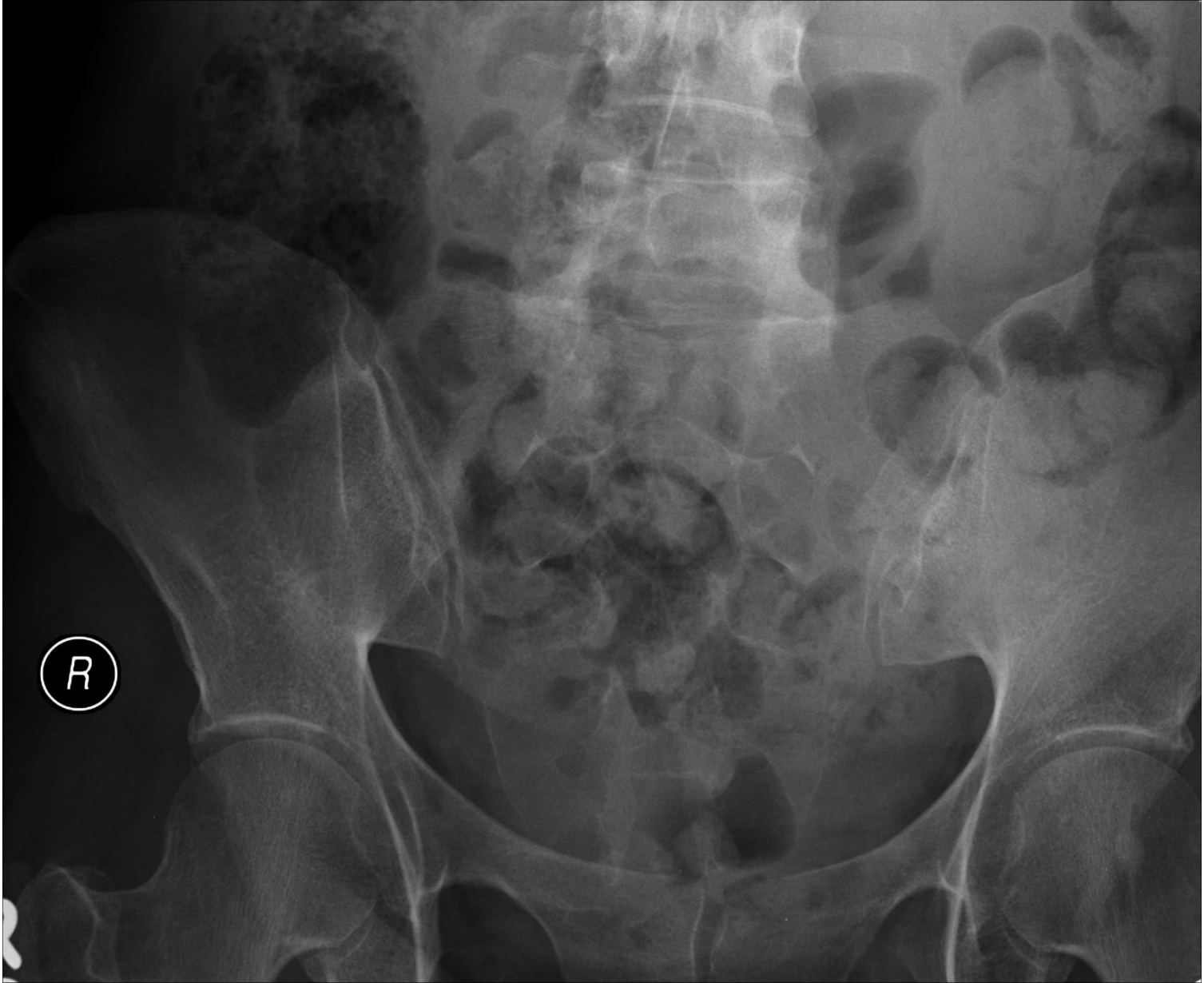
# Now What?

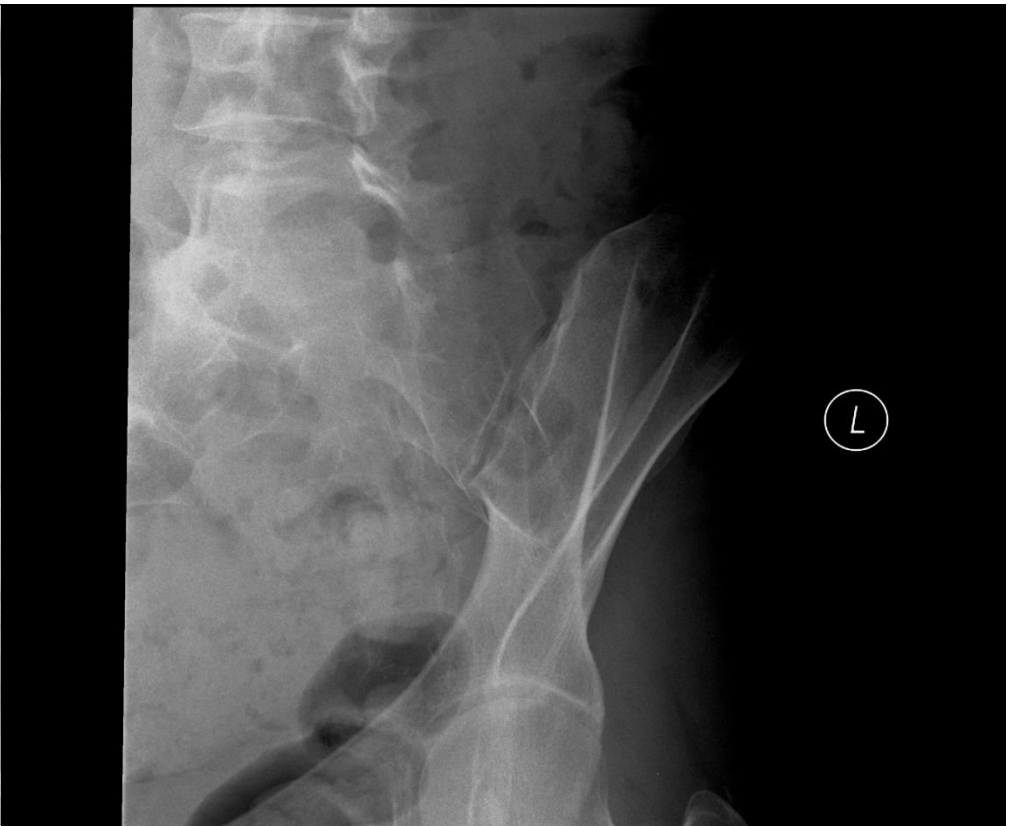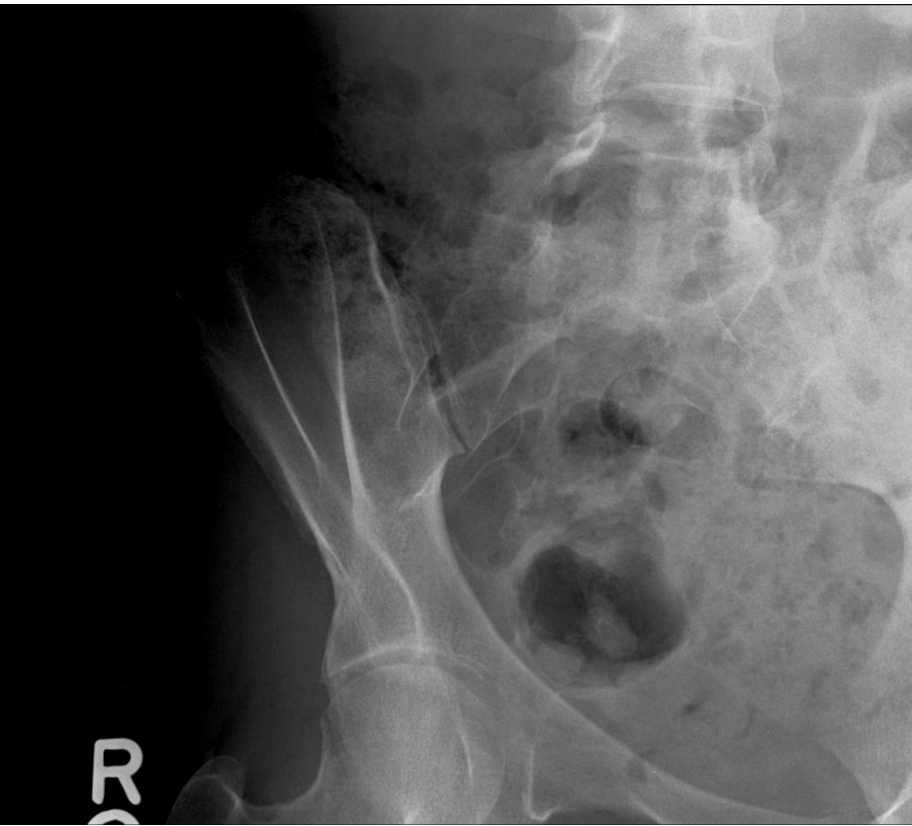
## Hip Pathology?

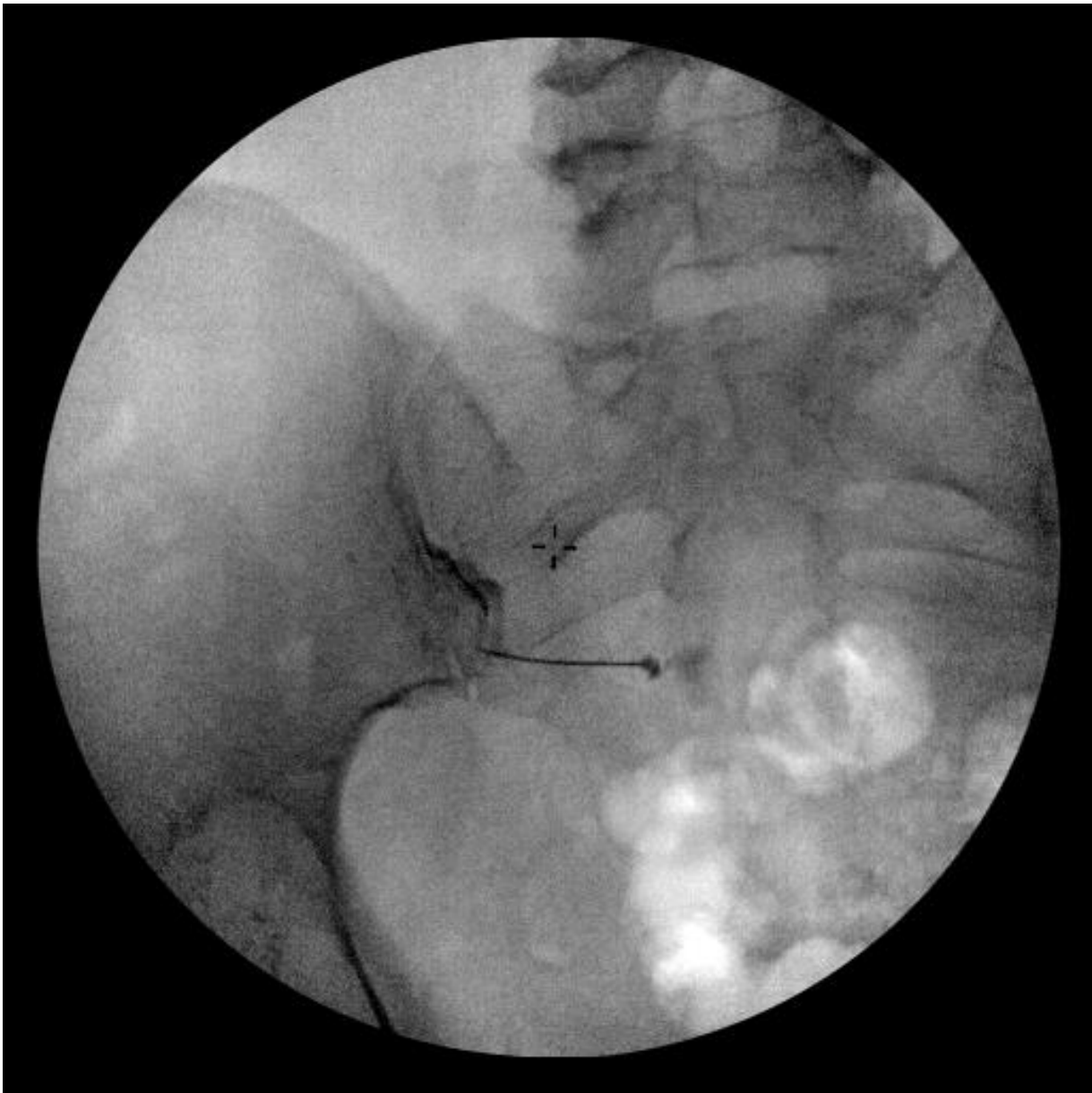
- ▶ Hip osteoarthritis
- ▶ Labral injury/FAI
- ▶ Piriformis syndrome
- ▶ Trochanteric bursitis
- ▶ I.T.Band Syndrome
- ▶ Ischialgluteal bursitis
- ▶ Sacroiliac joint pain














Let's do  
some cases  
to help you  
learn how to  
break down  
"The Hack" ...





# Case #1: History

74 y.o. woman, complains of left hip pain.



Pain on side of hip.



Burning, aching, worse lying on her side at night.




Some radiation of pain down lateral side of thigh.



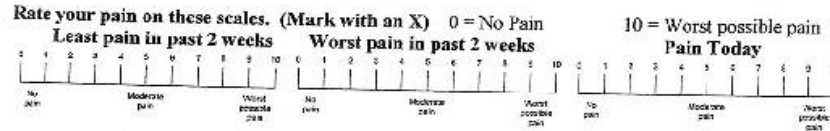
No numbness, tingling or weakness.

# Case #1 Pain Diagram

 Please fill out this form and bring it to the appointment. Name \_\_\_\_\_ MR # \_\_\_\_\_

Hip #1

**CONFIDENTIAL PATIENT HISTORY**  
 Is your pain?  Continuous  Intermittent  
 Approximate date this pain began: \_\_\_\_\_

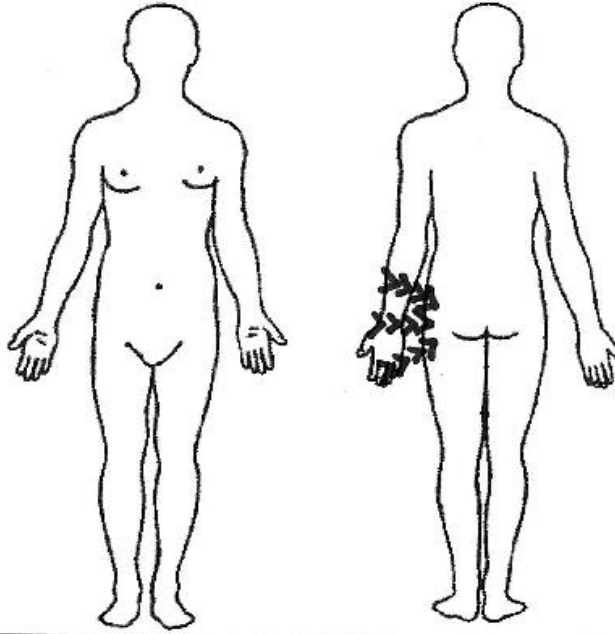


Use these symbols on the below diagram to describe your pain:

— Numbness // Stabbing >>> Aching ... Pins & Needles xxx Burning

Rate these activities on how they affect your pain:

	Better	Worse	No Change
Sitting	<input type="checkbox"/>	<input type="checkbox"/>	<input type="checkbox"/>
Standing	<input type="checkbox"/>	<input type="checkbox"/>	<input type="checkbox"/>
Bending forward	<input type="checkbox"/>	<input type="checkbox"/>	<input type="checkbox"/>
Bending backward	<input type="checkbox"/>	<input type="checkbox"/>	<input type="checkbox"/>
Lying flat on Back	<input type="checkbox"/>	<input type="checkbox"/>	<input type="checkbox"/>
Lying flat on Stomach	<input type="checkbox"/>	<input type="checkbox"/>	<input type="checkbox"/>
Lying flat on Side	<input type="checkbox"/>	<input type="checkbox"/>	<input type="checkbox"/>
Walking	<input type="checkbox"/>	<input type="checkbox"/>	<input type="checkbox"/>



List surgeries and dates:  
 \_\_\_\_\_  
 \_\_\_\_\_

Are you:  
 Currently Working Job Title: \_\_\_\_\_  
 Retired  Disabled

# Case #1: Exam

In excess of  
ideal body  
weight

Walks with  
antalgic gait

Mild pain with  
PROM of hip

SLR negative

Focal TTP over  
greater  
trochanter

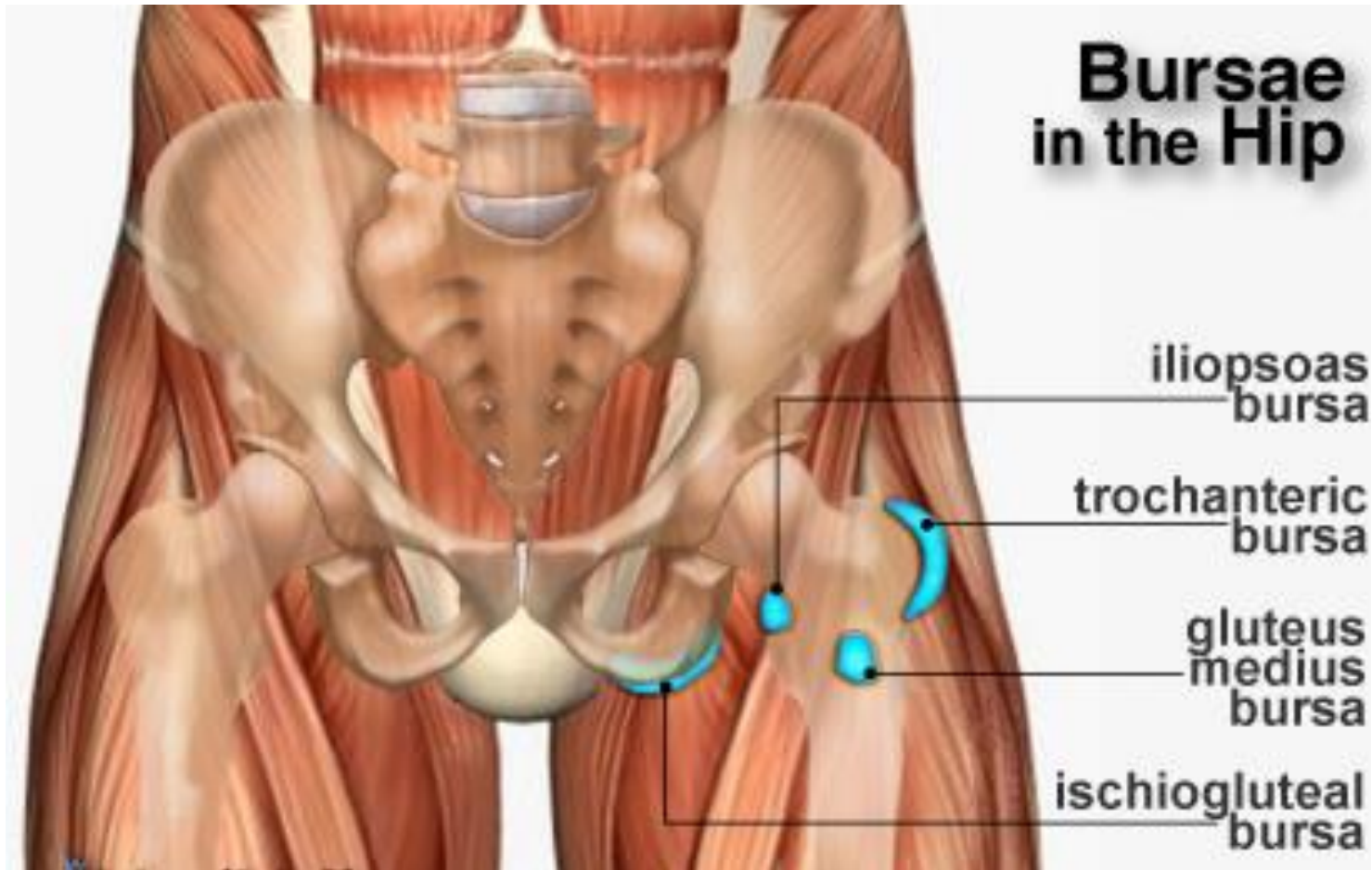
No leg length  
discrepancy

Neurovascular  
examination  
intact

# Most likely diagnosis is?

- A: Hip osteoarthritis
- B: Iliotibial band syndrome
- C: Lumbar radiculopathy
- D: Hip Strain
- E: Trochanteric Bursitis

# Trochanteric Bursitis



# Trochanteric Bursitis: Treatment



**Ice and Heat**



**NSAIDs**

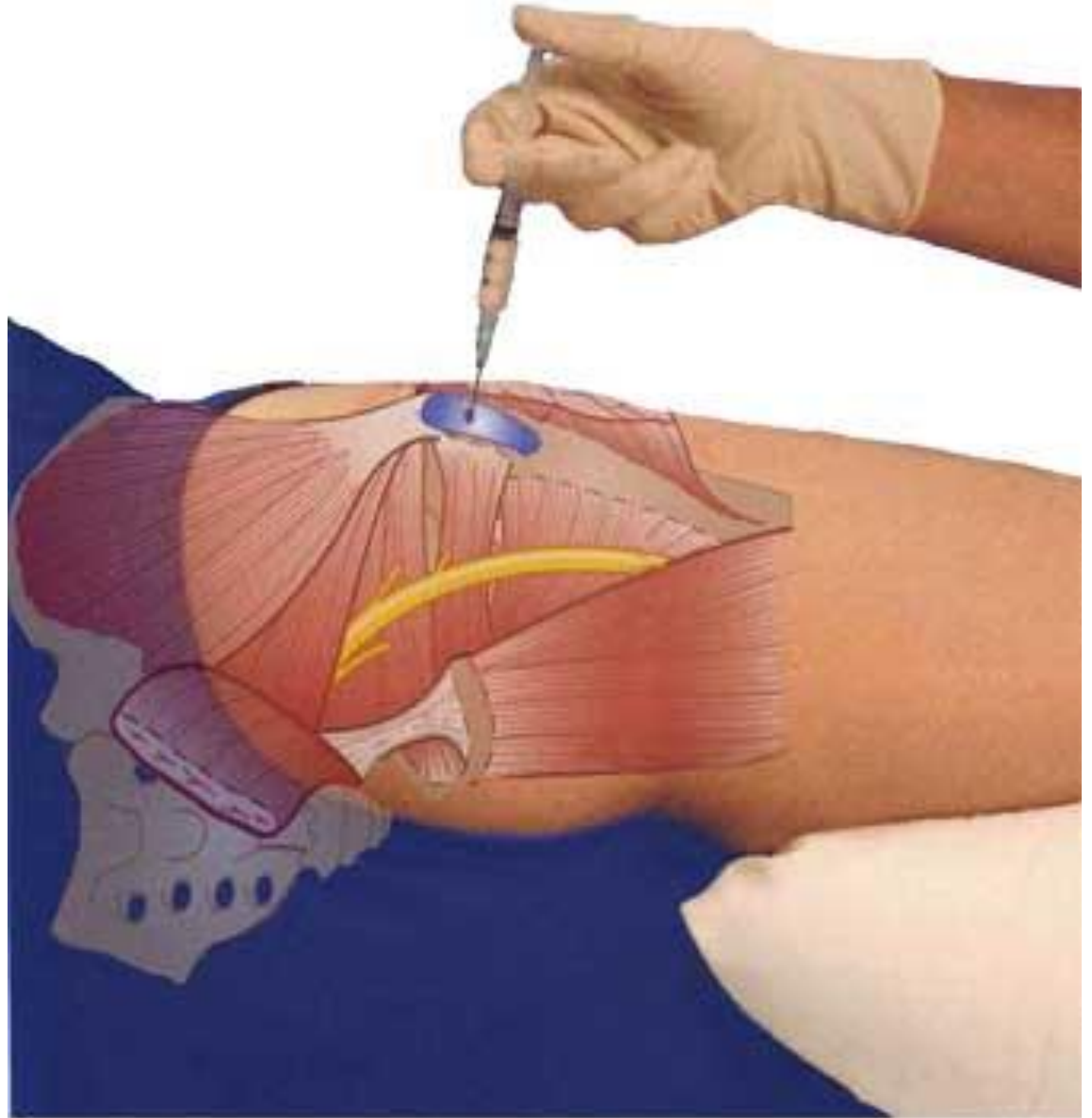



**P.T.**  
Stretching  
Strengthening



**Cortisone Injection**

# G.T.Bursa Cortisone Injection





## Case #2

66 y.o. man complains of pain in his groin

Pain started 6 mo. ago after a long hike, getting progressively worse

Has diverticulitis with left lower quadrant pain that radiates into hip during flares

Pain flared week ago after playing tennis

Accupuncturist found tender spots in groin muscle

# Case #2 Pain Diagram



KAISER PERMANENTE

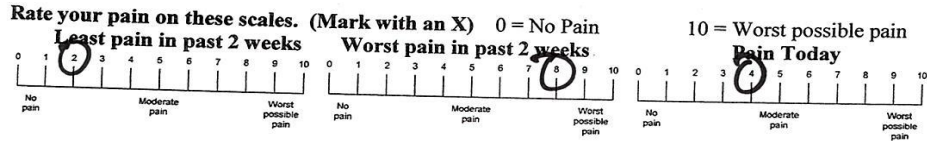
Please fill out this form and bring it to the appointment Name \_\_\_\_\_

MR # \_\_\_\_\_

**CONFIDENTIAL PATIENT HISTORY**

Is your pain?  Continuous  Intermittent

Approximate date this pain began: \_\_\_\_\_

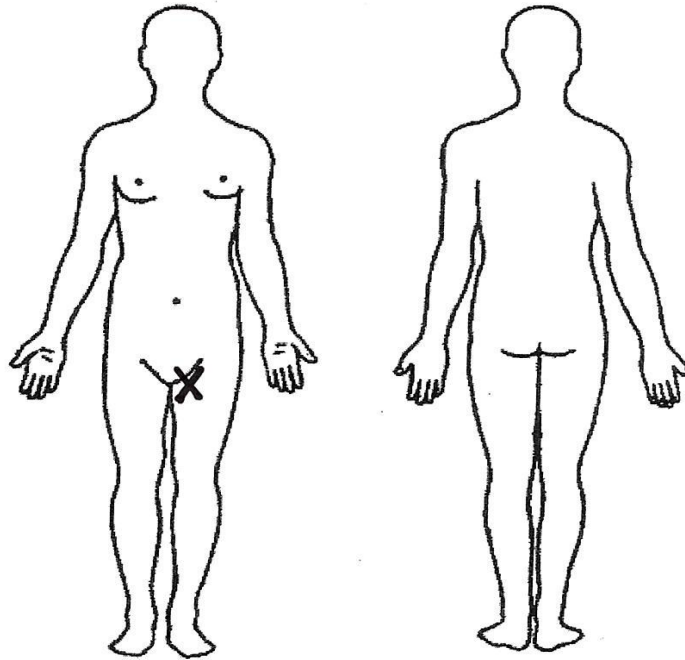


Use these symbols on the below diagram to describe your pain:

== Numbness // Stabbing >>>Aching ... Pins & Needles xxx Burning

Rate these activities on how they affect your pain:

	Better	Worse	No Change
Sitting	<input type="checkbox"/>	<input checked="" type="checkbox"/>	<input type="checkbox"/>
Standing	<input type="checkbox"/>	<input checked="" type="checkbox"/>	<input type="checkbox"/>
Bending forward	<input type="checkbox"/>	<input checked="" type="checkbox"/>	<input type="checkbox"/>
Bending backward	<input type="checkbox"/>	<input type="checkbox"/>	<input type="checkbox"/>
Lying flat on Back	<input type="checkbox"/>	<input type="checkbox"/>	<input type="checkbox"/>
Lying flat on Stomach	<input type="checkbox"/>	<input type="checkbox"/>	<input type="checkbox"/>
Lying flat on Side	<input type="checkbox"/>	<input type="checkbox"/>	<input type="checkbox"/>
Walking	<input type="checkbox"/>	<input checked="" type="checkbox"/>	<input type="checkbox"/>



List surgeries and dates:  
\_\_\_\_\_  
\_\_\_\_\_

Are you:  
 Currently Working Job Title: \_\_\_\_\_  
 Retired  Disabled

# Hip Case #2: Exam

Normal gait

Mild TTP at adductor origin (groin)

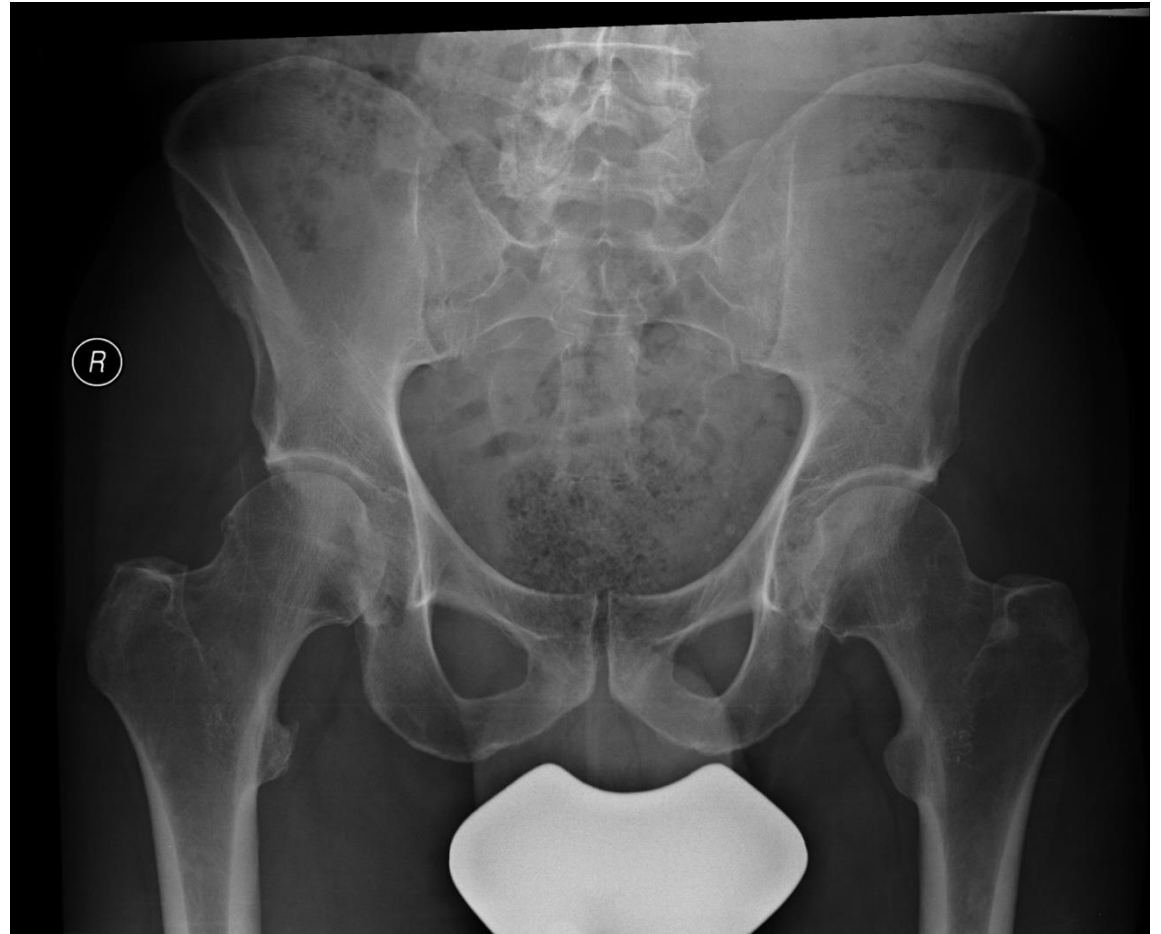No pain with active resisted hip flexion or hip adduction

Pain reproduced in groin with passive hip flexion and internal rotation, mild pain with external rotation

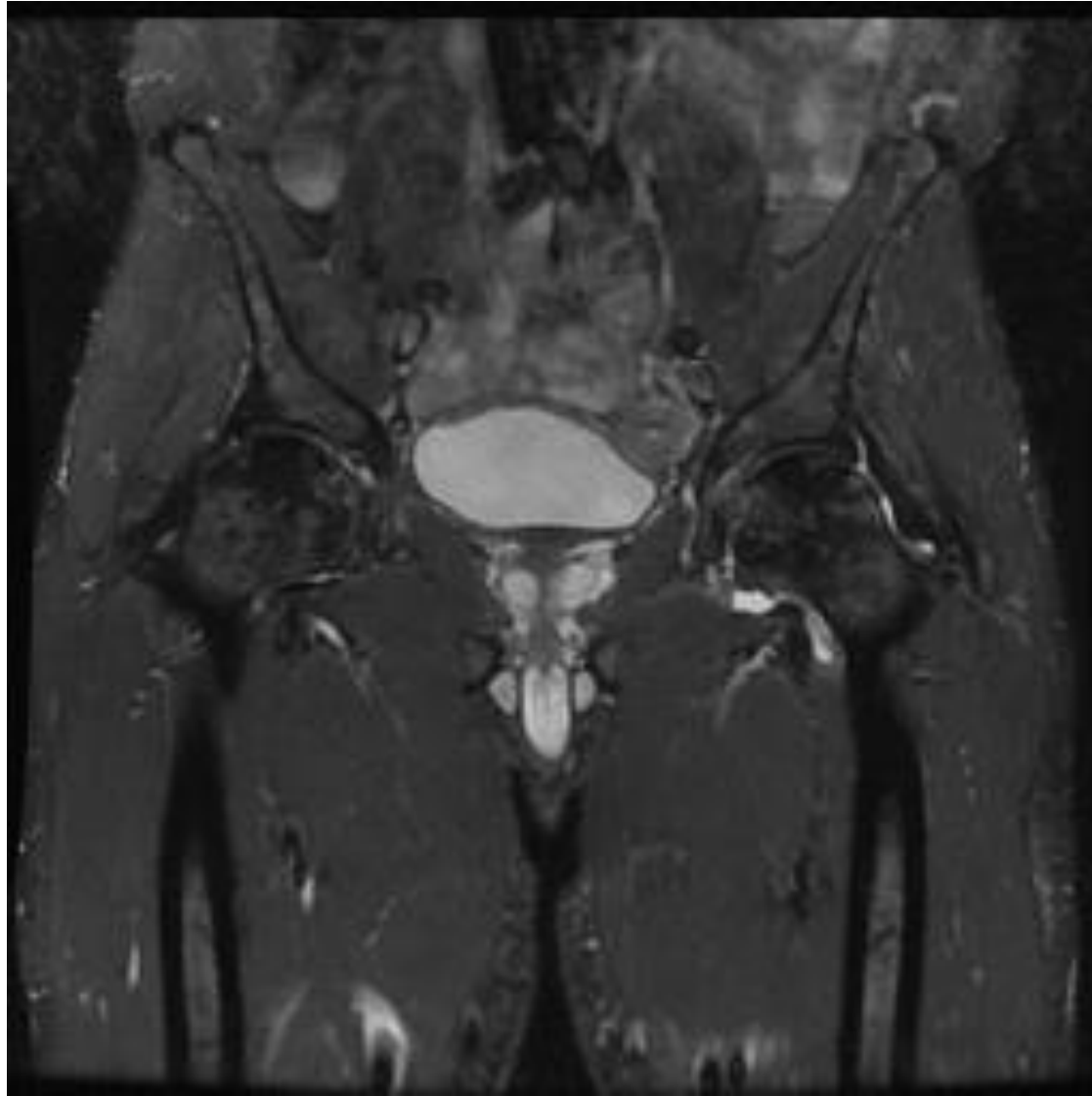
SLR negative

Neurovascular exam intact

Case #2:  
X-rays



## Hip Case #2: MRI

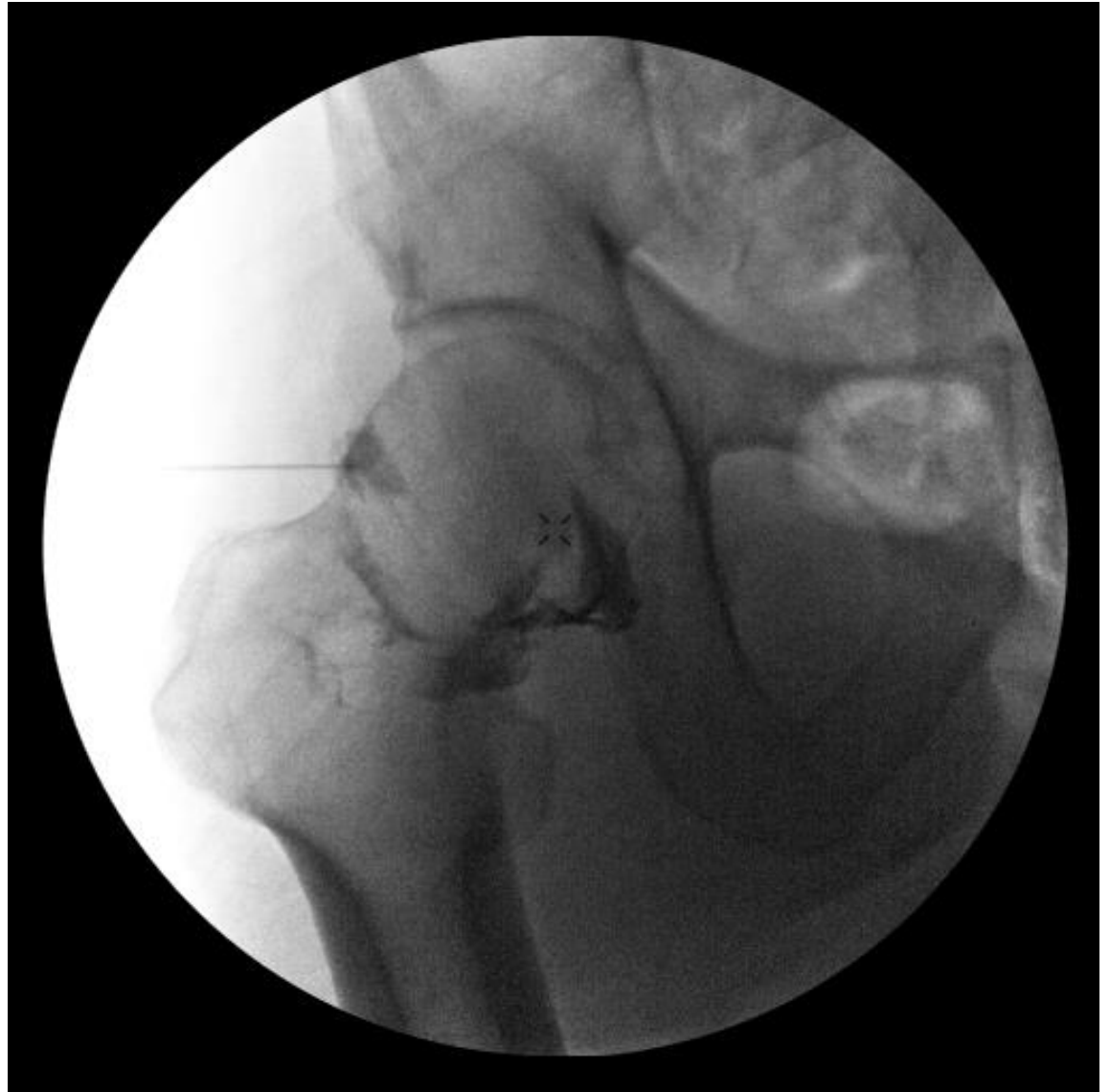

# Most likely diagnosis is?

- A: Hip osteoarthritis
- B: Iliotibial band syndrome
- C: Lumbar radiculopathy
- D: Sacroiliac Joint Dysfunction
- E: Trochanteric Bursitis

LEFT

## Case #2: Fluoro



# Hip Osteoarthritis: Treatment

Acetaminophen and NSAIDs


Activity Modification

P.T.-Hip stabilization exercises

Assistive Device: Cane

Hip Arthrogram Corticosteroid Injection

Hip Replacement Surgery



## Case #3 : History

36 y.o. woman with right lateral hip pain

Training for half marathon

Started as a slight ache, but now with runs up to 8 miles, pain is stabbing with burning pain at night.

Some numbness/tingling radiating down lateral thigh into lateral knee.

Not better with ice, heat and NSAIDs

# Case #3 Pain Diagram



Please fill out this form and bring it to the appointment Name \_\_\_\_\_

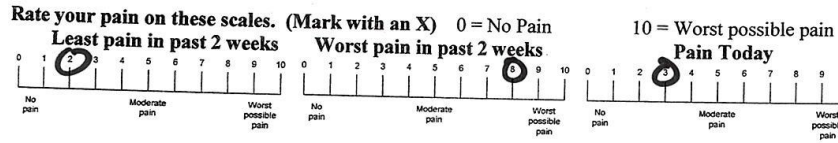
KAISER PERMANENTE

MR # \_\_\_\_\_

## CONFIDENTIAL PATIENT HISTORY

Is your pain?  Continuous  Intermittent

Approximate date this pain began: \_\_\_\_\_



Use these symbols on the below diagram to describe your pain:

= Numbness // Stabbing >>>Aching ... Pins & Needles xxx Burning

Rate these activities on how they affect your pain:

	Better	Worse	No Change
Sitting	<input type="checkbox"/>	<input type="checkbox"/>	<input type="checkbox"/>
Standing	<input type="checkbox"/>	<input type="checkbox"/>	<input type="checkbox"/>
Bending forward	<input type="checkbox"/>	<input type="checkbox"/>	<input type="checkbox"/>
Bending backward	<input type="checkbox"/>	<input type="checkbox"/>	<input type="checkbox"/>
Lying flat on Back	<input type="checkbox"/>	<input type="checkbox"/>	<input type="checkbox"/>
Lying flat on Stomach	<input type="checkbox"/>	<input type="checkbox"/>	<input type="checkbox"/>
Lying flat on Side	<input type="checkbox"/>	<input type="checkbox"/>	<input type="checkbox"/>
Walking	<input type="checkbox"/>	<input type="checkbox"/>	<input type="checkbox"/>

List surgeries and dates:

---

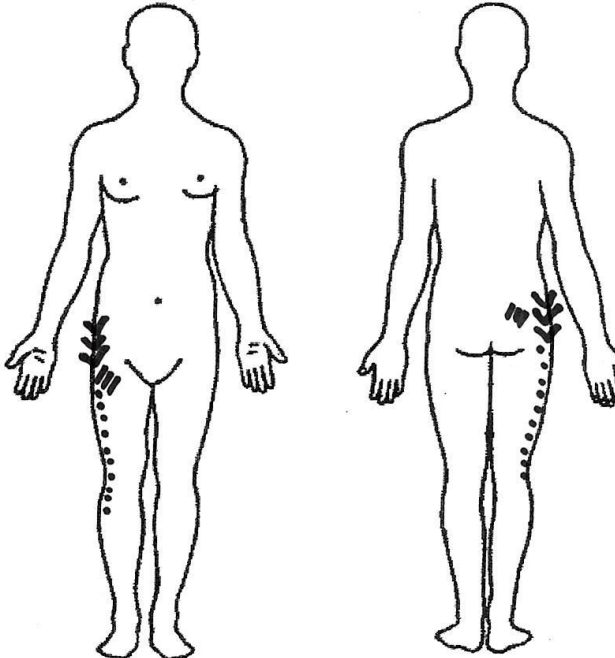


---

Are you:

Currently Working Job Title: \_\_\_\_\_

Retired  Disabled



## Case #3: Exam

No significant pain with hip passive motion

Straight leg raise negative

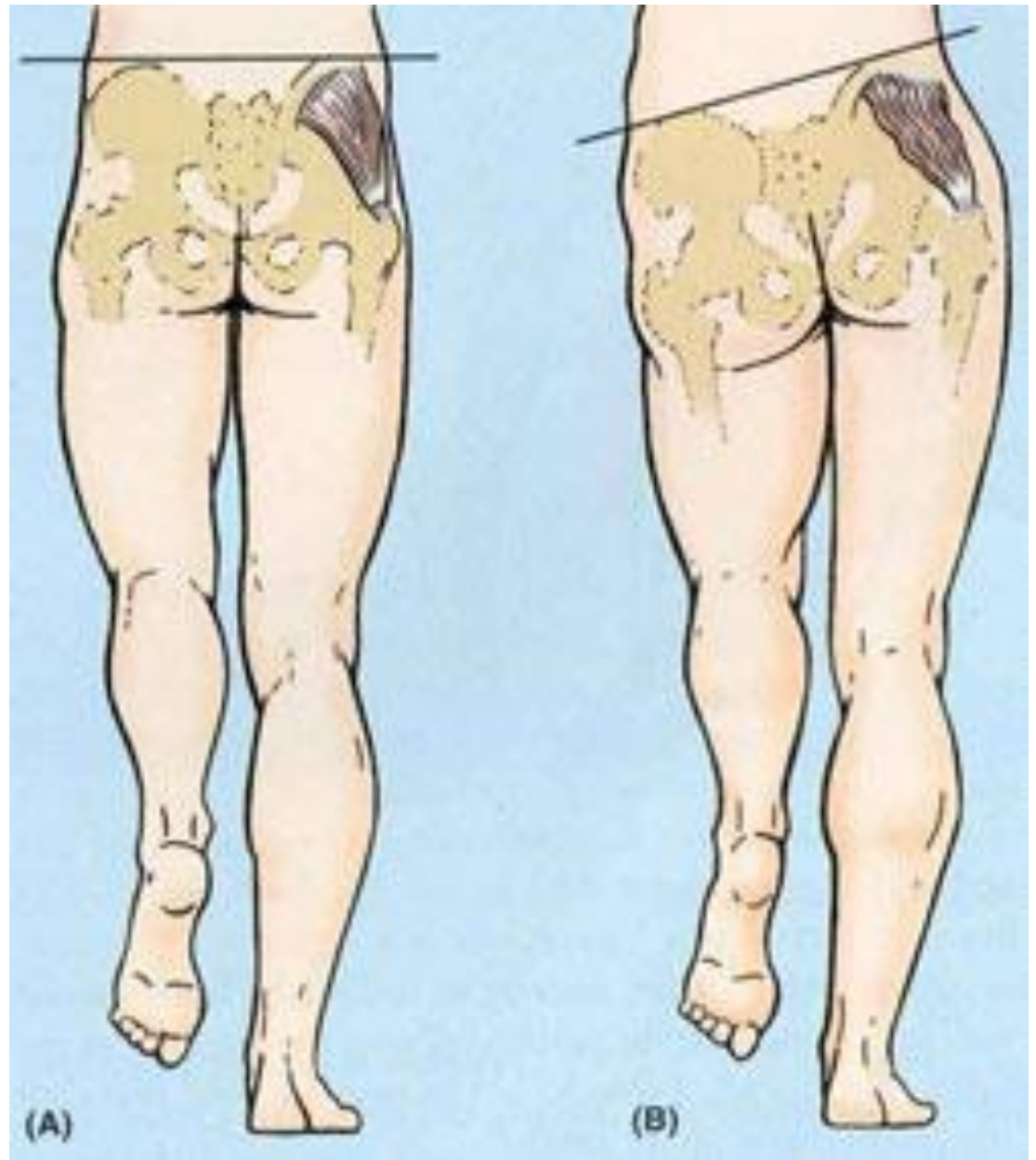
Positive TTP over GT and TFL and along the I.T.Band

Positive Tendelenburg sign

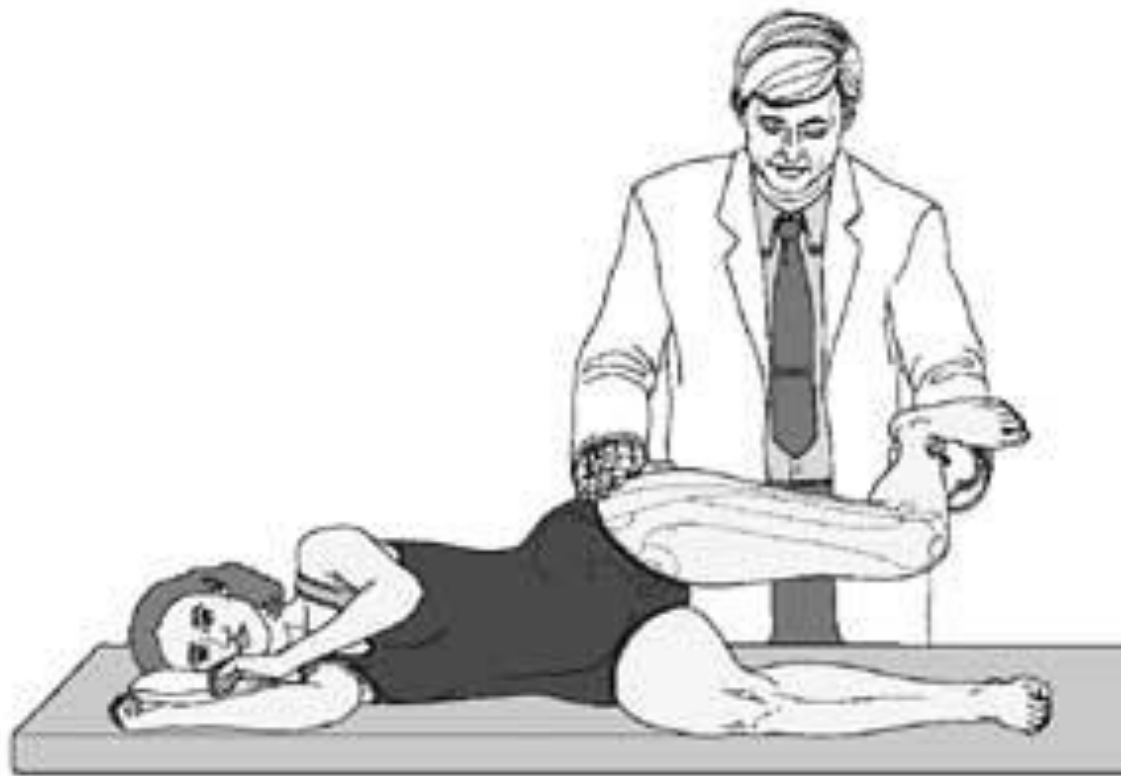Positive Ober's stretch test

Neurovascular exam intact

# Trendelenburg Sign



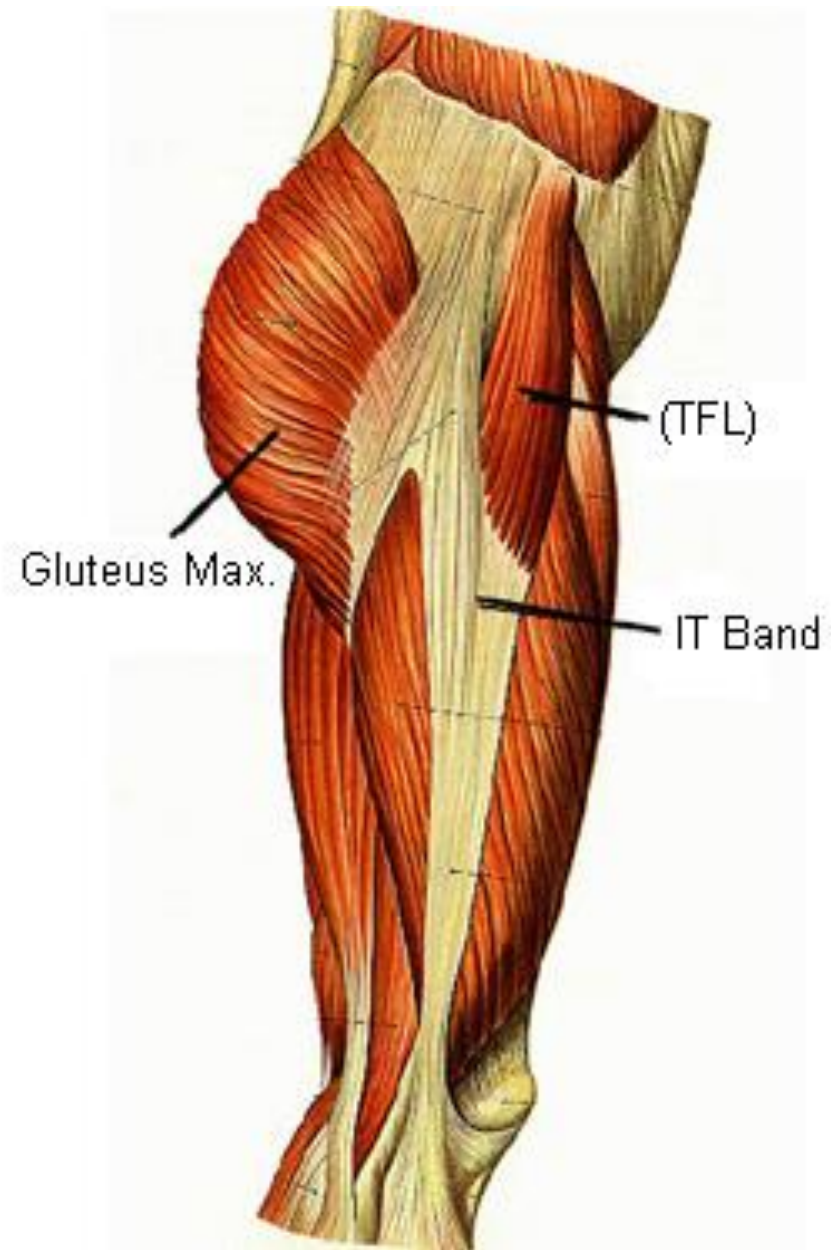
# Ober's Test



# Most likely diagnosis is?

- A: Hip osteoarthritis
- B: Iliotibial band syndrome
- C: Lumbar radiculopathy
- D: Sacroiliac Joint Dysfunction
- E: Trochanteric Bursitis

# Iliotibial Band Syndrome



# I.T.Band Syndrome- Treatment

Ice and Heat

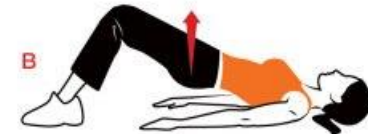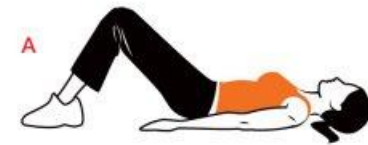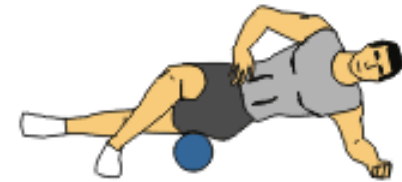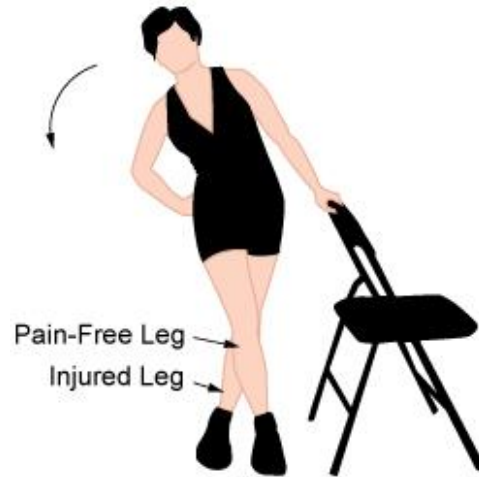Activity Modification



NSAIDs

P.T.

Cortisone injection?

# Stretch- Roller- Exercise !





## Case #4

55yo man presents with severe left hip pain. Limits function.

Deep pain in groin AND in buttocks, radiating into posterior thigh.

Worse with walking, hard to put on socks or get in/out of car.

Seen in orthopedics, recommended hip arthrogram/cortisone injection.

# Case #4 Pain Diagram



Please fill out this form and bring it to the appointment Name \_\_\_\_\_

KAISER PERMANENTE

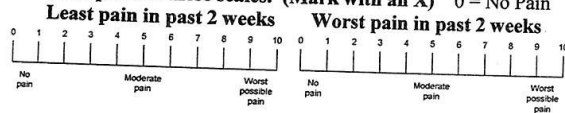
MR # \_\_\_\_\_

## CONFIDENTIAL PATIENT HISTORY

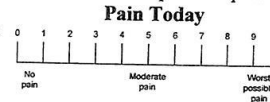
Is your pain?  Continuous  Intermittent

Approximate date this pain began: \_\_\_\_\_

Rate your pain on these scales. (Mark with an X) 0 = No Pain



10 = Worst possible pain



Use these symbols on the below diagram to describe your pain:

= Numbness // Stabbing >>>Aching ... Pins & Needles xxx Burning

Rate these activities on how they affect your pain:

	Better	Worse	No Change
Sitting	<input type="checkbox"/>	<input type="checkbox"/>	<input type="checkbox"/>
Standing	<input type="checkbox"/>	<input type="checkbox"/>	<input type="checkbox"/>
Bending forward	<input type="checkbox"/>	<input type="checkbox"/>	<input type="checkbox"/>
Bending backward	<input type="checkbox"/>	<input type="checkbox"/>	<input type="checkbox"/>
Lying flat on Back	<input type="checkbox"/>	<input type="checkbox"/>	<input type="checkbox"/>
Lying flat on Stomach	<input type="checkbox"/>	<input type="checkbox"/>	<input type="checkbox"/>
Lying flat on Side	<input type="checkbox"/>	<input type="checkbox"/>	<input type="checkbox"/>
Walking	<input type="checkbox"/>	<input type="checkbox"/>	<input type="checkbox"/>

List surgeries and dates:

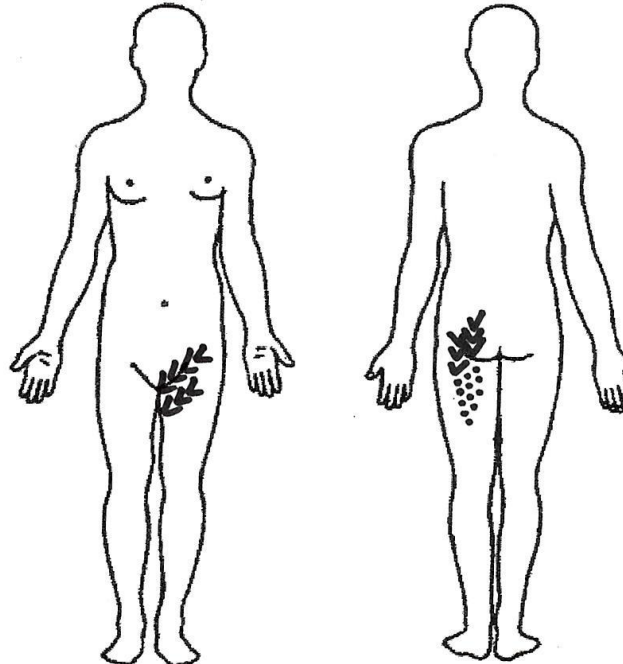
\_\_\_\_\_

\_\_\_\_\_

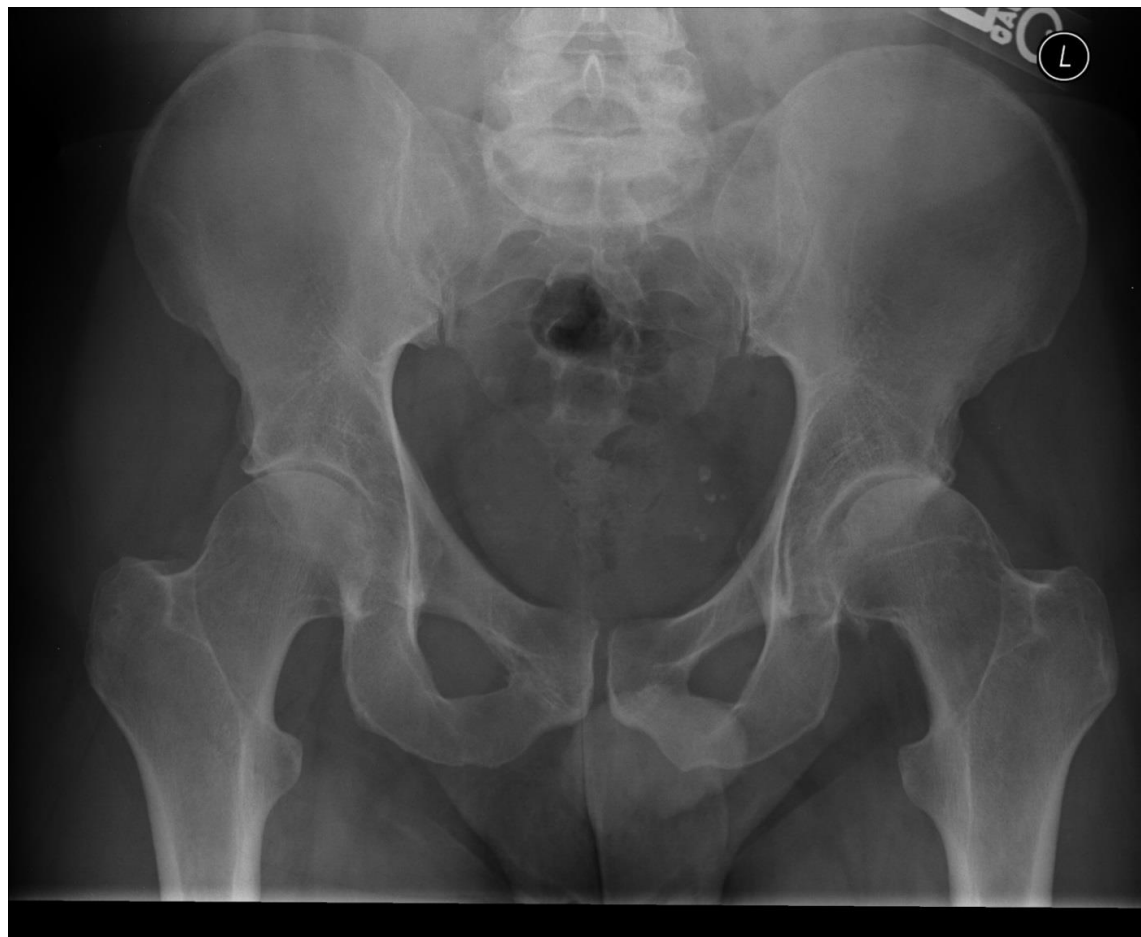Are you:

Currently Working Job Title: \_\_\_\_\_

Retired  Disabled



Case 4:  
X-ray 1

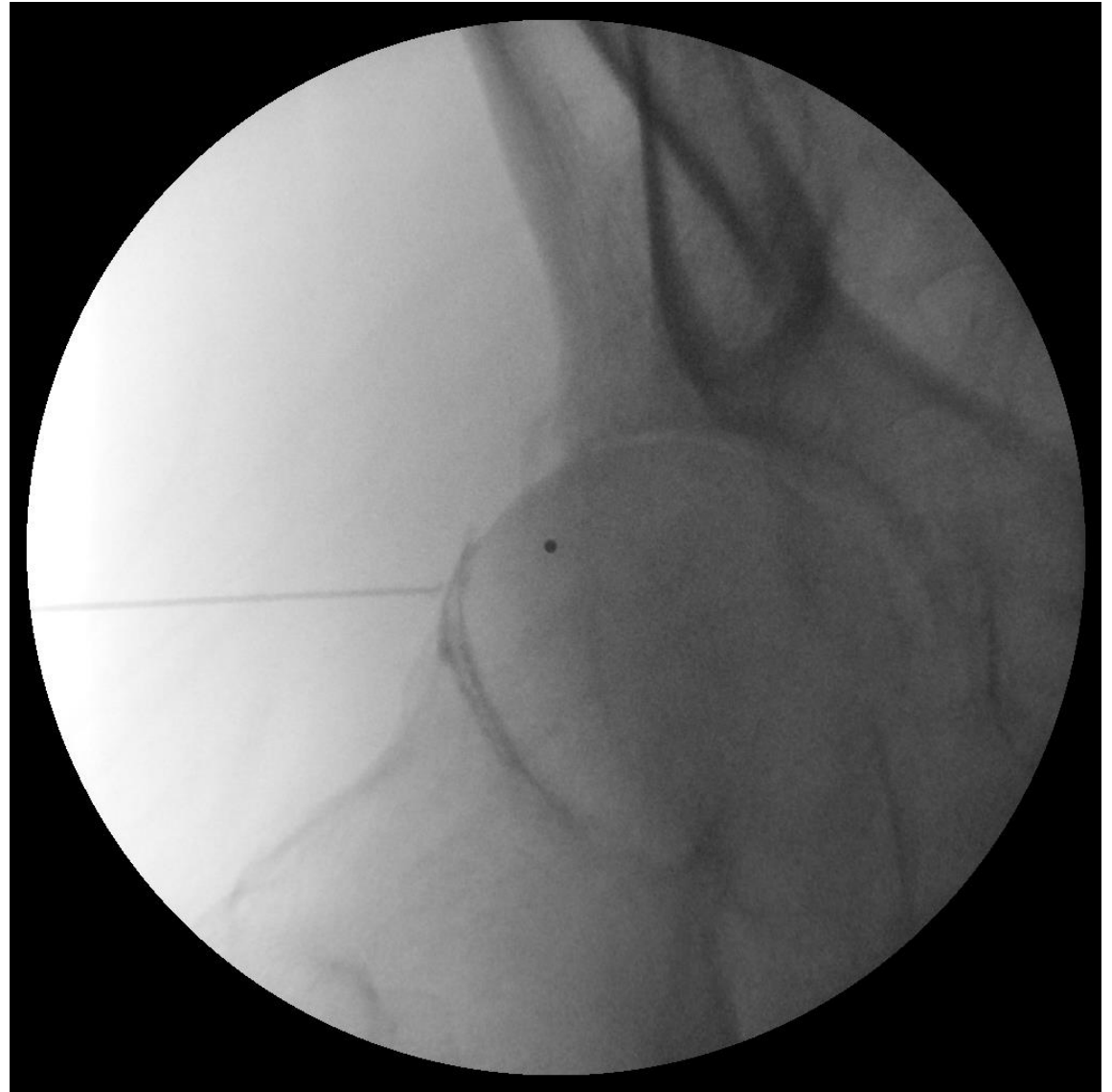

# Most likely diagnosis is?

- A: Hip osteoarthritis
- B: Iliotibial band syndrome
- C: Lumbar radiculopathy
- D: Avascular Necrosis
- E: Trochanteric Bursitis

LEFT

# Case #4: Fluoro 1



## Case #4, continued...

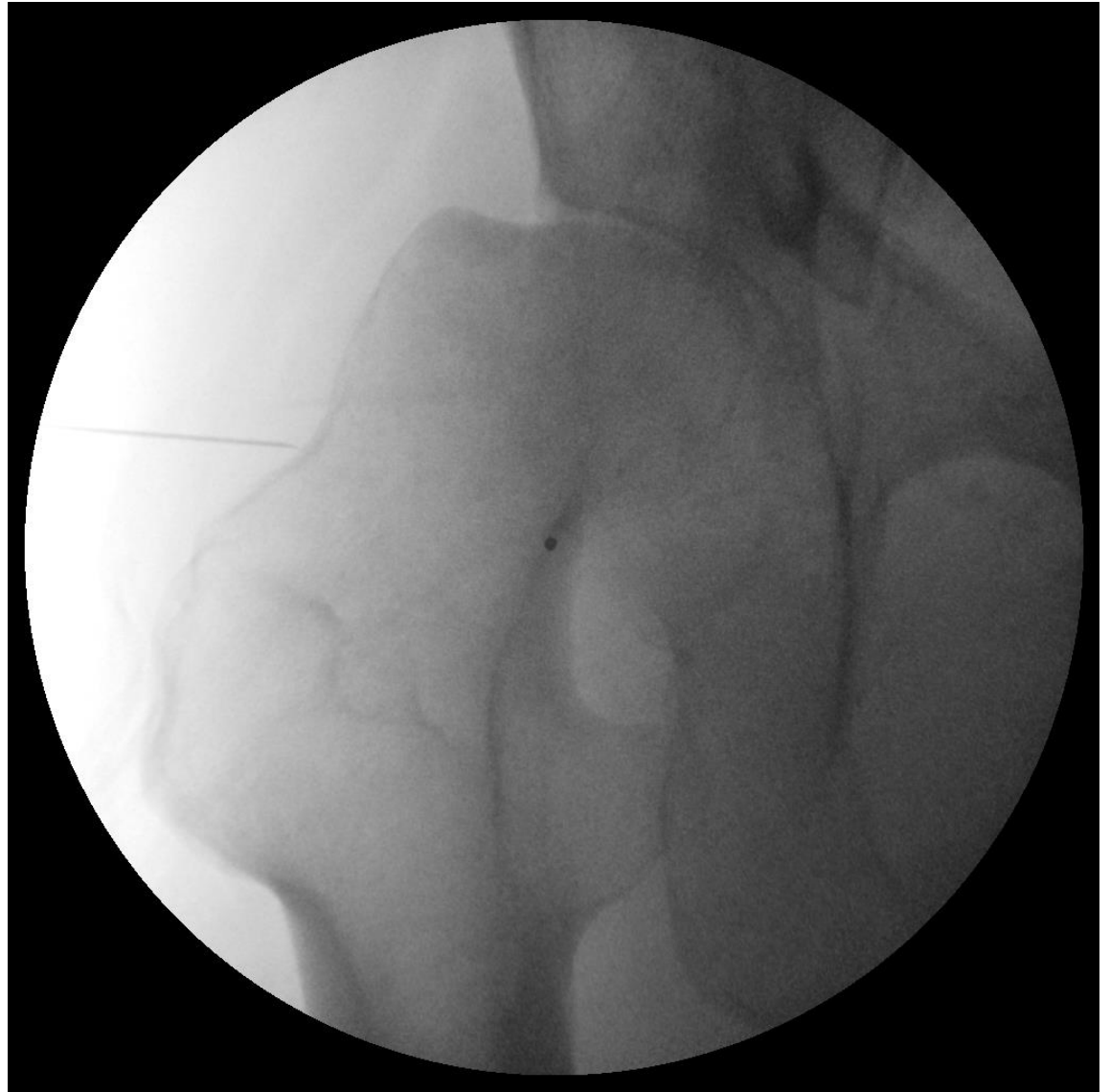Patient has significant pain relief for over 6 months after the hip arthrogram cortisone steroid injection.

His pain flares and he presents for a repeat fluoroscopically guided hip CSI

Under fluoroscopy, you see this....

LEFT

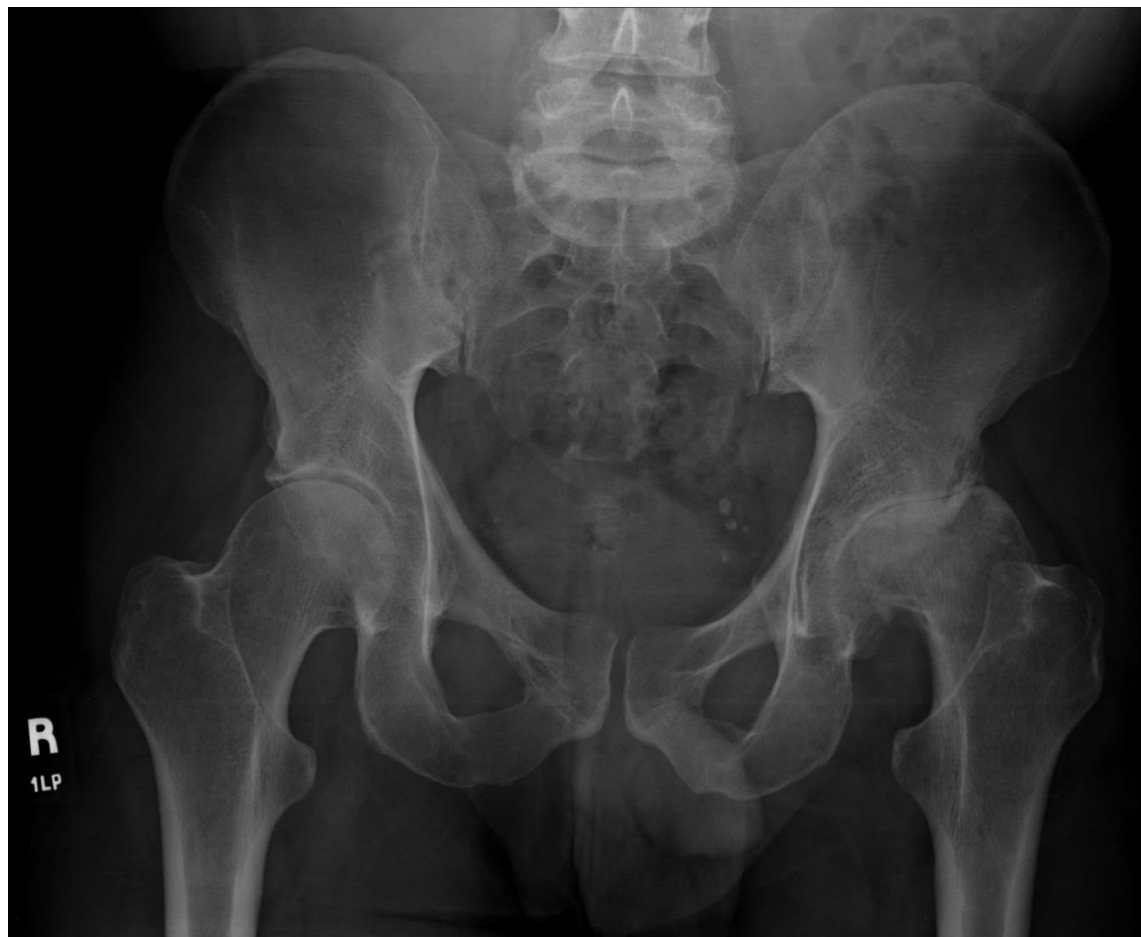## Case #4: Fluoro 2



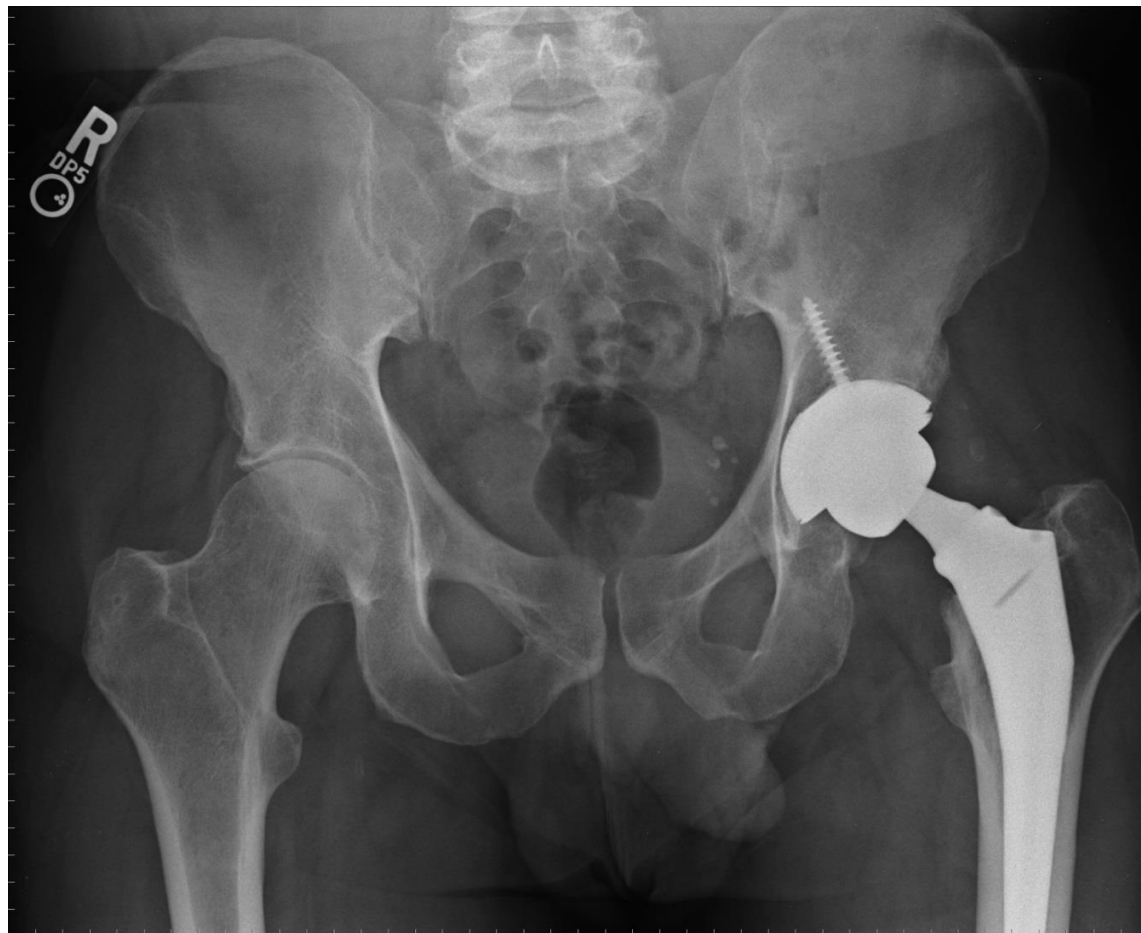
# Now, what is the diagnosis ?




- A: Hip osteoarthritis
- B: Iliotibial band syndrome
- C: Lumbar radiculopathy
- D: Avascular Necrosis
- E: Trochanteric Bursitis

Case #4:  
X-ray 2



Case #4:  
X-ray 3





## Case #5

13 Y female volleyball/soccer

4 weeks ago diving in volleyball, landing on front of left hip. Sharp pain.

Now pain with running and kicking anterior hip.

Tried ice, heat, ns aids and rest without improvement.

# Case #5 Pain Diagram



Please fill out this form and bring it to the appointment Name \_\_\_\_\_

KAISER PERMANENTE.

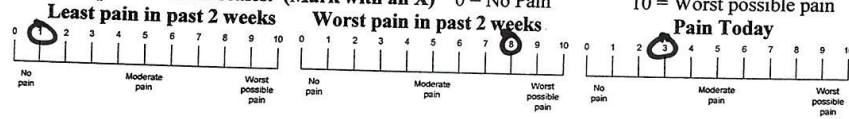
MR # \_\_\_\_\_

### CONFIDENTIAL PATIENT HISTORY

Is your pain?  Continuous  Intermittent

Approximate date this pain began: \_\_\_\_\_

Rate your pain on these scales. (Mark with an X) 0 = No Pain

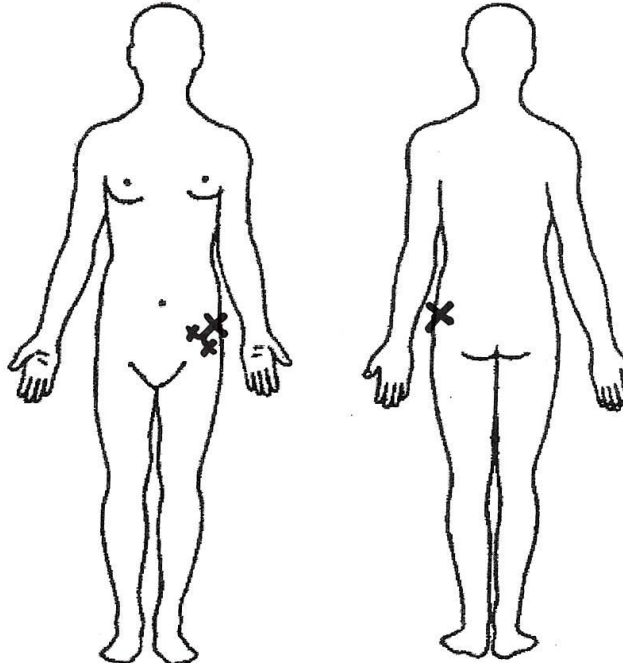


Use these symbols on the below diagram to describe your pain:

== Numbness // Stabbing >>>Aching ... Pins & Needles xxx Burning

Rate these activities on how they affect your pain:

	Better	Worse	No Change
Sitting	<input type="checkbox"/>	<input type="checkbox"/>	<input type="checkbox"/>
Standing	<input type="checkbox"/>	<input type="checkbox"/>	<input type="checkbox"/>
Bending forward	<input type="checkbox"/>	<input type="checkbox"/>	<input type="checkbox"/>
Bending backward	<input type="checkbox"/>	<input type="checkbox"/>	<input type="checkbox"/>
Lying flat on Back	<input type="checkbox"/>	<input type="checkbox"/>	<input type="checkbox"/>
Lying flat on Stomach	<input type="checkbox"/>	<input type="checkbox"/>	<input type="checkbox"/>
Lying flat on Side	<input type="checkbox"/>	<input type="checkbox"/>	<input type="checkbox"/>
Walking	<input type="checkbox"/>	<input type="checkbox"/>	<input type="checkbox"/>



List surgeries and dates:

\_\_\_\_\_

\_\_\_\_\_

Are you:

Currently Working Job Title: \_\_\_\_\_

Retired  Disabled

## Case #5: Exam

Normal gait

Significant inflexibility of lower extremities

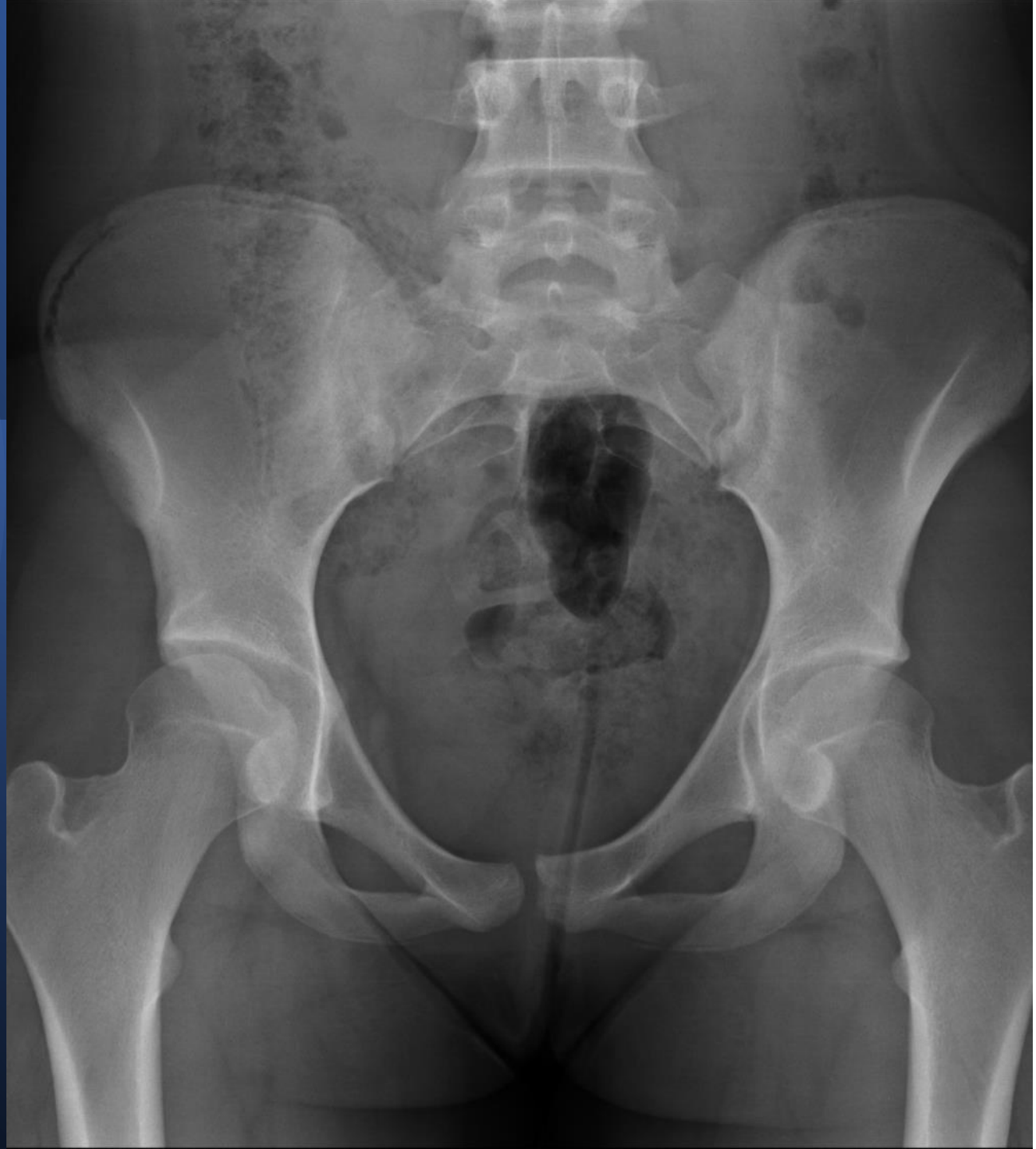
Pain in anterior hip with hip flexor stretch

Focal TTP over iliac crest just distal to ASIS

No pain with forced passive motion of hip

No leg length discrepancy

Case #5:  
X-ray






# Most likely diagnosis is?

- A: Hip osteoarthritis
- B: Iliotibial band syndrome
- C: Iliac crest fracture
- D: Avascular Necrosis
- E: Slipped Capital Femoral Epiphysis

# Iliac Crest Growth Plate Fracture

- Treatment:
- Rest
- P.T.
  - Stretching
    - Hip flexors, Quads, ITband, Hip extensors, hamstrings.
  - Exercises
    - Hip stabilization exercises
- No pain with passive stretch, No tenderness to palpation, no pain with running stairs.



## Case #6

90 y.o. woman with back and leg pain.

History of spinal stenosis, back surgery, claudication, chronic pain, and dementia.

Legs are weak, 2 months ago fell, seen in ED, xrays completed-negative for fracture.

Started P.T.

Increased pain in right hip

# Case #6 Pain Diagram



Please fill out this form and bring it to the appointment Name \_\_\_\_\_

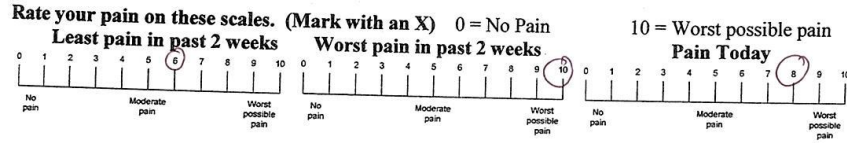
KAISER PERMANENTE

MR # \_\_\_\_\_

**CONFIDENTIAL PATIENT HISTORY**

Is your pain?  Continuous  Intermittent

Approximate date this pain began: \_\_\_\_\_

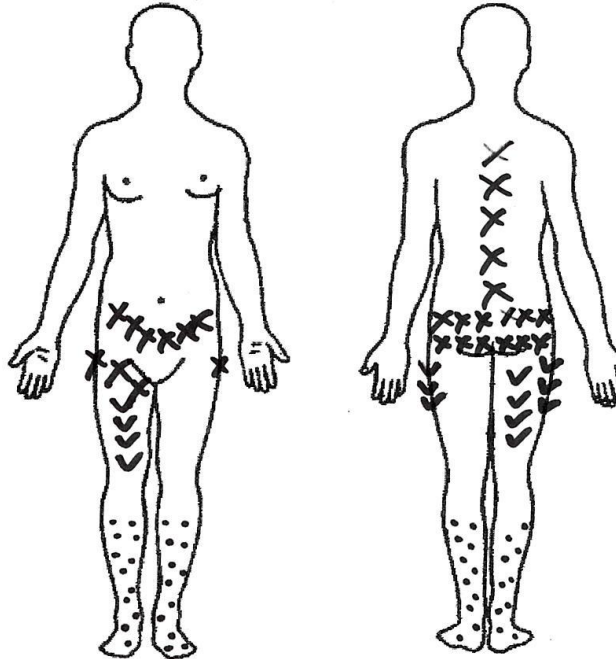


Use these symbols on the below diagram to describe your pain:

— Numbness // Stabbing >>>Aching ... Pins & Needles xxx Burning

Rate these activities on how they affect your pain:

	Better	Worse	No Change
Sitting	<input type="checkbox"/>	<input type="checkbox"/>	<input type="checkbox"/>
Standing	<input type="checkbox"/>	<input type="checkbox"/>	<input type="checkbox"/>
Bending forward	<input type="checkbox"/>	<input type="checkbox"/>	<input type="checkbox"/>
Bending backward	<input type="checkbox"/>	<input type="checkbox"/>	<input type="checkbox"/>
Lying flat on Back	<input type="checkbox"/>	<input type="checkbox"/>	<input type="checkbox"/>
Lying flat on Stomach	<input type="checkbox"/>	<input type="checkbox"/>	<input type="checkbox"/>
Lying flat on Side	<input type="checkbox"/>	<input type="checkbox"/>	<input type="checkbox"/>
Walking	<input type="checkbox"/>	<input type="checkbox"/>	<input type="checkbox"/>



List surgeries and dates:

\_\_\_\_\_

\_\_\_\_\_

Are you:

Currently Working Job Title: \_\_\_\_\_

Retired  Disabled

## Case #6: Exam

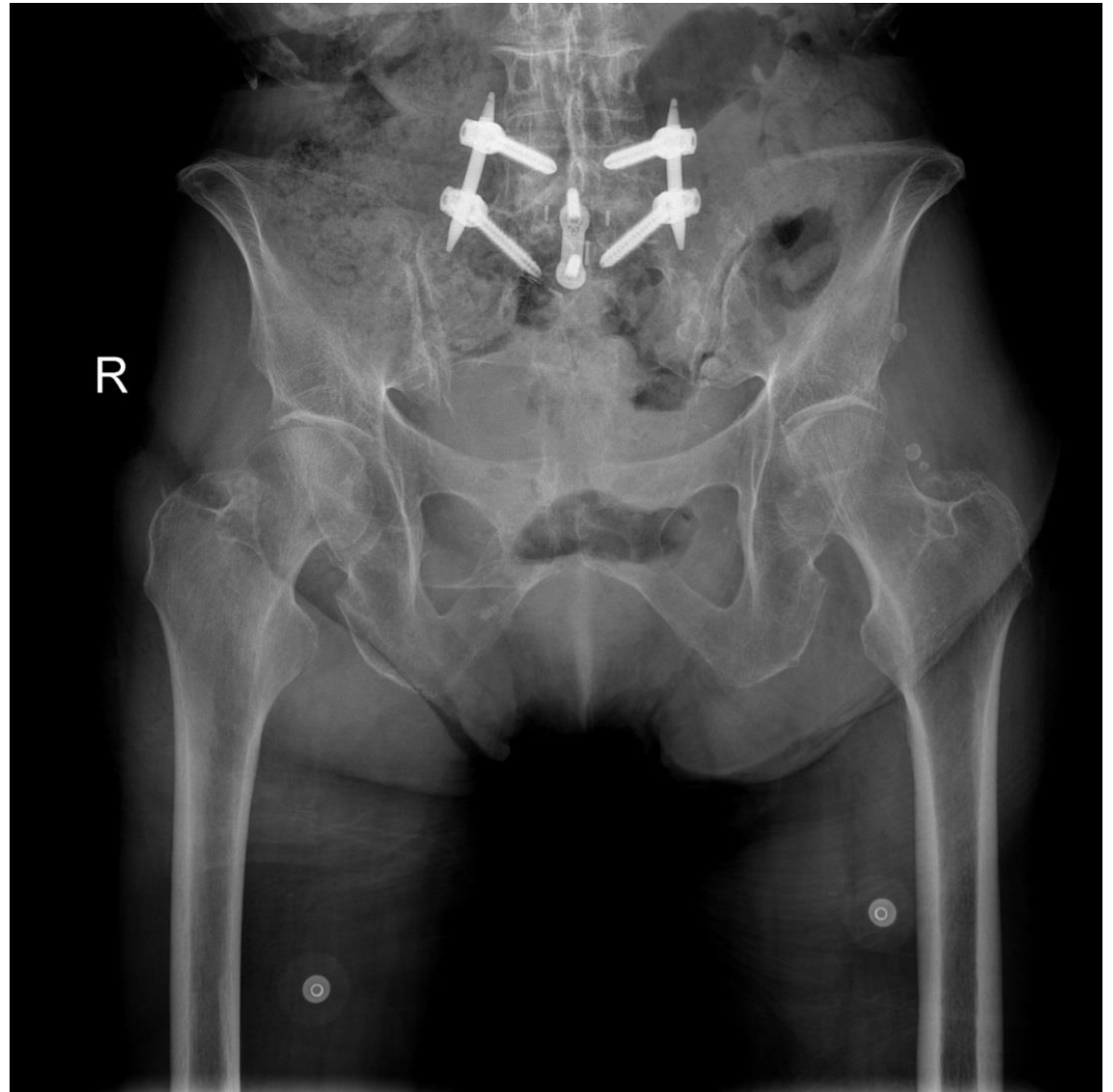Able to stand with assistance and walk few steps in exam room with right hip pain.

Noticeable leg length discrepancy with right shorter than left.

Severe right hip pain with passive motion which is limited.

Symmetric neurovascular exam.

Case #6:  
X-ray (ED)





# Most likely diagnosis is?




- A: Hip osteoarthritis
- B: Osteolysis of femoral neck
- C: Iliac crest fracture
- D: Avascular Necrosis
- E: Slipped Capital Femoral Epiphysis

# Osteolysis of femoral neck

Very  
uncommon

Variant of  
AVN

LEG LENGTH  
DISCREPENCY



## Case #7

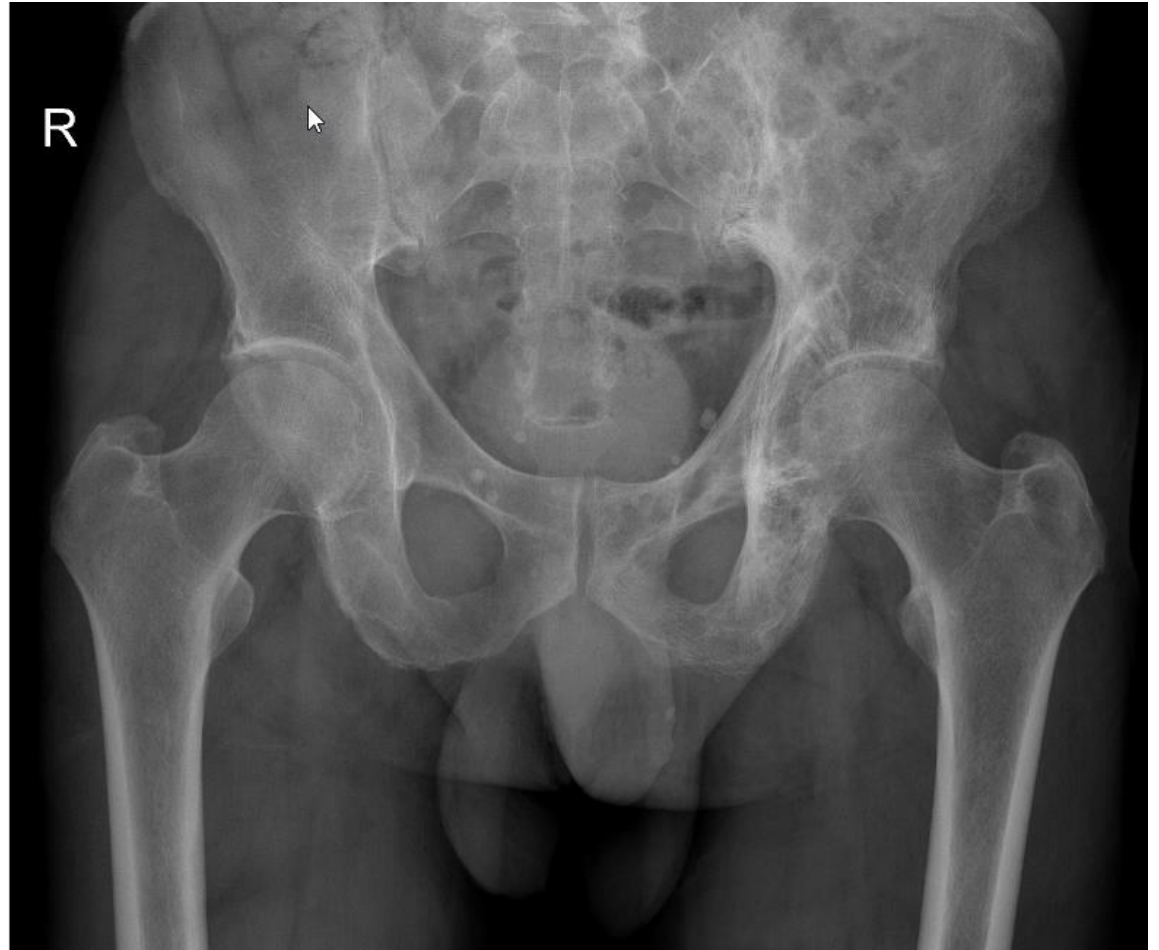65 yo man, active surfer and cyclist has on/off left hip/groin pain for over a year.

Bending forward he develops severe stabbing pain that radiates down his anterior thigh.

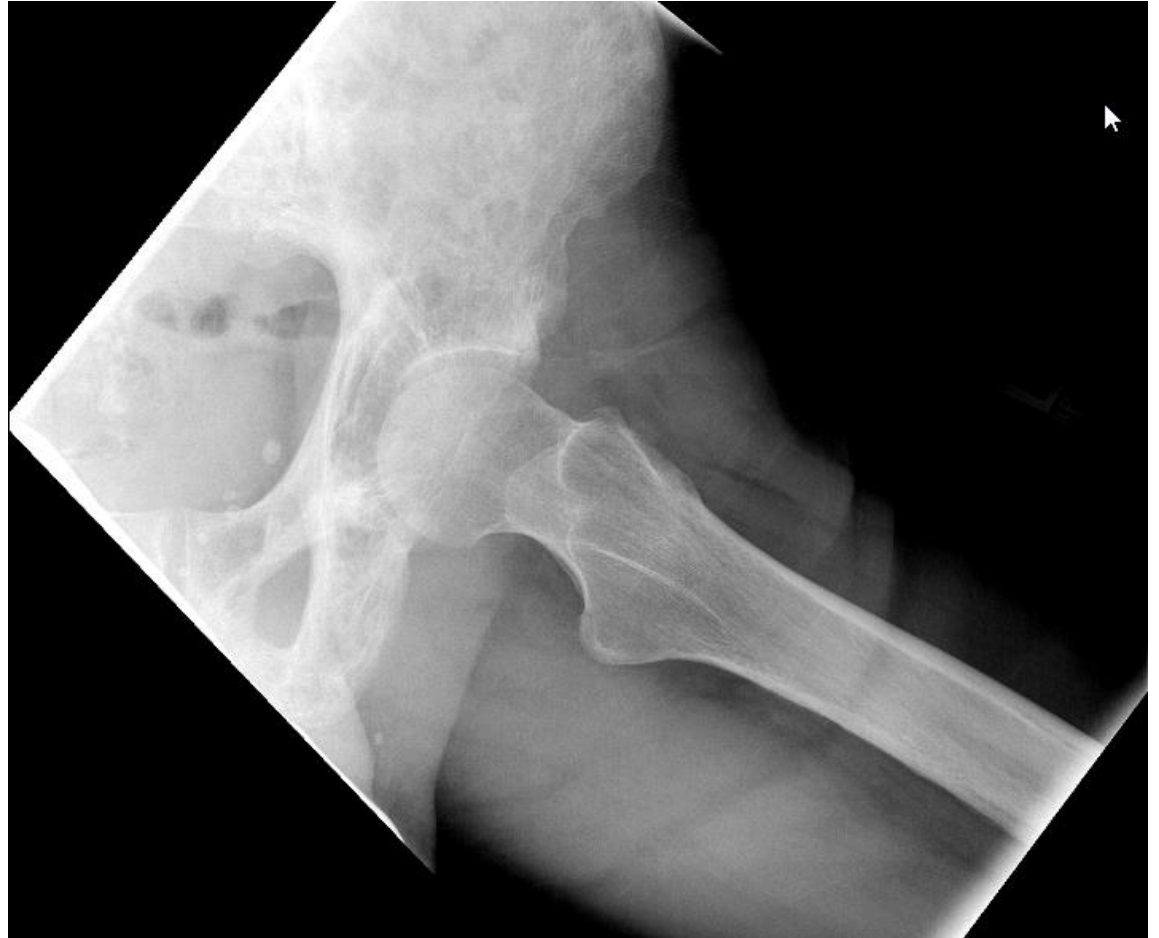Hip joint feels like it is stuck and he is unable to bear weight

You get hip x-rays...

Case #7:  
X-Rays



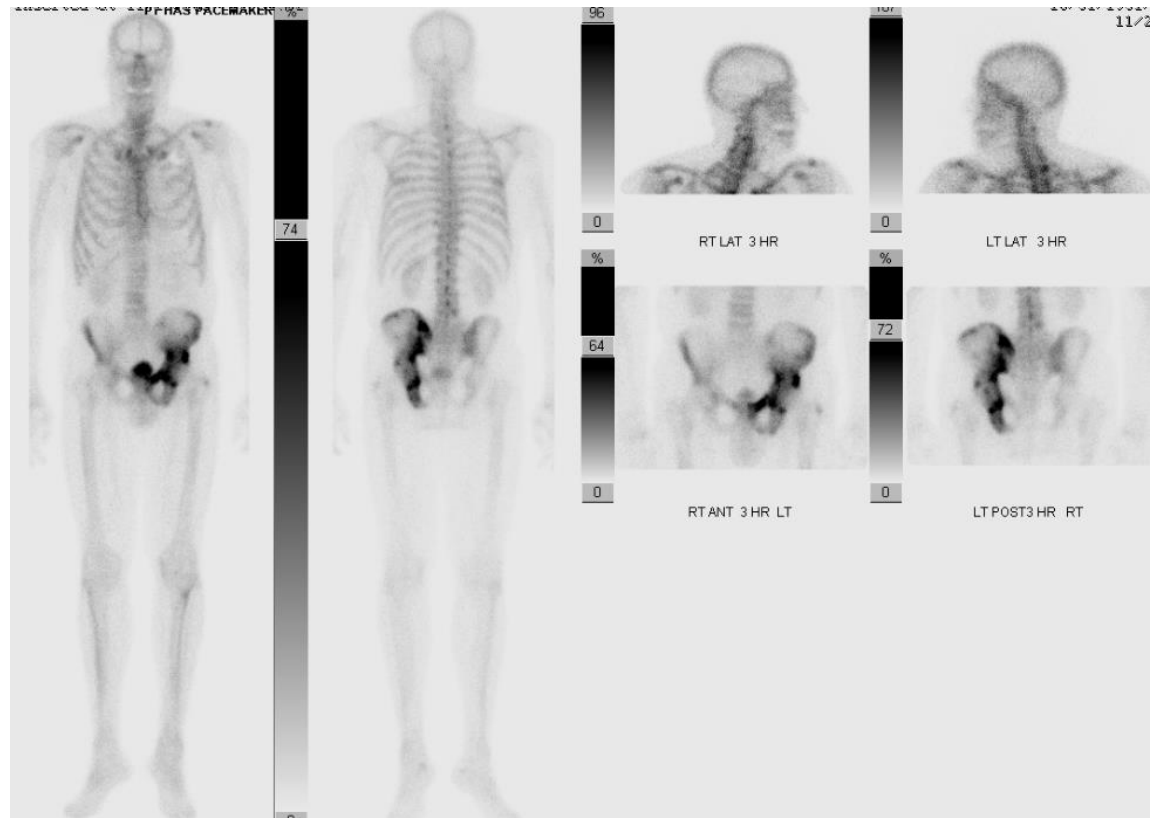
Case #7: X-  
rays  
Frog Leg  
Lateral



# Most likely diagnosis is?

- A: Hip osteoarthritis
- B: Avascular Necrosis
- C: Stress Fracture
- D: Trochanteric Bursitis
- E: Paget's Disease

# Bone Scan



# Paget's Disease of Bone “Osteitis Deformans”

Age >55, Men > Women, often asymptomatic

Accelerated rate of bone remodeling

Focal disorder of bone metabolism that occurs in the aging skeleton

Labs: Frequently elevated:

- serum alkaline phosphatase (sAP)
- bone-specific alkaline phosphatase (bAP)

Diagnosis: Radiographic + elevated sAP

Nice Job!  
KEY POINTS

- The hip is a 'watershed zone'
- Use your history and exam skills
- Encourage active recovery program
- Check x-rays if trauma or fails to improve with conservative treatment
- Consult your musculoskeletal specialist if you have questions or concerns!



Thank you!

[todd.weitzenberg@kp.org](mailto:todd.weitzenberg@kp.org)