



# Aortic Root Remodeling

Ulrich Schneider, MD and Hans-Joachim Schäfers, MD

**Valve-preserving aortic root replacement has become an attractive alternative to composite replacement leading to better quality of life and minimal valve-related complications. Root remodeling requires less surgical dissection and has been shown to lead to more physiological hemodynamics compared to valve reimplantation.**

**Over the last 2 decades, improvements have been made regarding assessment of cusp and root configuration. Aggressive correction of cusp prolapse extended the application of root remodeling to a larger patient population and has markedly improved valve stability, even in patients with connective tissue disorders. In the presence of annular dilatation, the addition of an annuloplasty has been shown to be beneficial for valve competence and repair durability.**

**Aortic root remodeling combined with cusp repair and correction of annular dilatation leads to excellent valve stability and minimal valve-related complications.**

**Operative Techniques in Thoracic and Cardiovascular Surgery 23:102–120 © 2019 Elsevier Inc. All rights reserved.**

**KEYWORDS** Root remodeling, Aortic root replacement, Aortic valve repair

## Introduction

Valve-preserving aortic root replacement has become an increasingly accepted alternative to composite of aortic valve and root, particularly for young individuals with aortic root aneurysm. Preservation of the patient's native aortic valve will avoid the need for chronic anticoagulation with its inherent complications; it is commonly experienced as the procedure with better quality of life, and it is associated with minimal valve-related complications if a durable repair result can be achieved.

Two principal techniques have been developed for this purpose, root remodeling<sup>1</sup> and valve reimplantation.<sup>2</sup> Experience has shown for both techniques that the single most important component for good aortic valve function is the form of the aortic valve at the end of the procedure.<sup>3,4</sup> This may be achieved by only selecting patients with no or only minimal aortic regurgitation for this type of surgery. Experience has shown that the incidence and degree of cusp prolapse correlates with the preoperative degree of regurgitation.<sup>5</sup>

Alternatively, the surgeon becomes familiar with more objective means of assessing cusp configuration, such as determination of effective height<sup>6</sup> in order to correct cusp prolapse reproducibly. He also has to keep in mind that cusp

stretching may be masked by dilatation of the root and will become apparent after normalizing root dimensions, that is, intercommissural distance. This mechanism explains the decreased durability of valve-preserving surgery (VPS) in patients with higher degrees of aortic regurgitation and/or larger root dimensions.<sup>3</sup> Aggressive correction of cusp prolapse, especially if guided by an objective measurement of effective height will extend the application of VPS to a larger number of patients, and it has also shown to improve functional durability of the aortic valve.<sup>3,7</sup>

Over the past 2 decades we have been increasingly satisfied with root remodeling as our VPS procedure of choice, and we have applied it with minimal patient selection. While it has less annular reduction effect than valve reimplantation, it has also been shown to reduce annular size and maintain annular stability in many patients.<sup>8,9</sup> In order to improve annular size reduction we have combined it with a suture annuloplasty.<sup>10</sup> This combination has led to a higher proportion of competent aortic valves<sup>11</sup> and a slight trend to improved freedom from reoperation also with connective tissue disease.<sup>12</sup> Compared to valve reimplantation, root remodeling requires less dissection, especially in the presence of muscle in the right sinus. Cross-clamp times have been significantly shorter than those of valve reimplantation or also remodeling combined with an extraaortic ring<sup>7,13,14</sup>; we have not seen increased incidence of hemorrhage, even in acute aortic dissection. The long-term results of root remodeling have been identical to those of valve reimplantation.

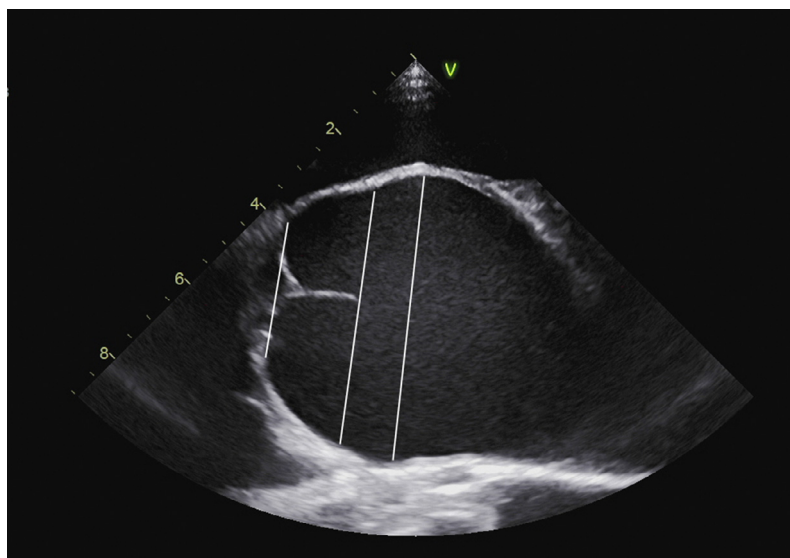
Root remodeling in conjunction with intraoperative measurement of effective height and possibly in combination with a suture annuloplasty has yielded excellent early and late results with less operative trauma than valve reimplantation.

*Abbreviations:* AR, aortic regurgitation; VPS, valve-preserving surgery; PTFE, polytetrafluorethylene; TEE, transesophageal echocardiography.

*Conflict of interest:* The authors have no conflict of interest to declare.

Department of Thoracic and Cardiovascular Surgery, Saarland University Medical Center, Homburg/Saar, Germany.

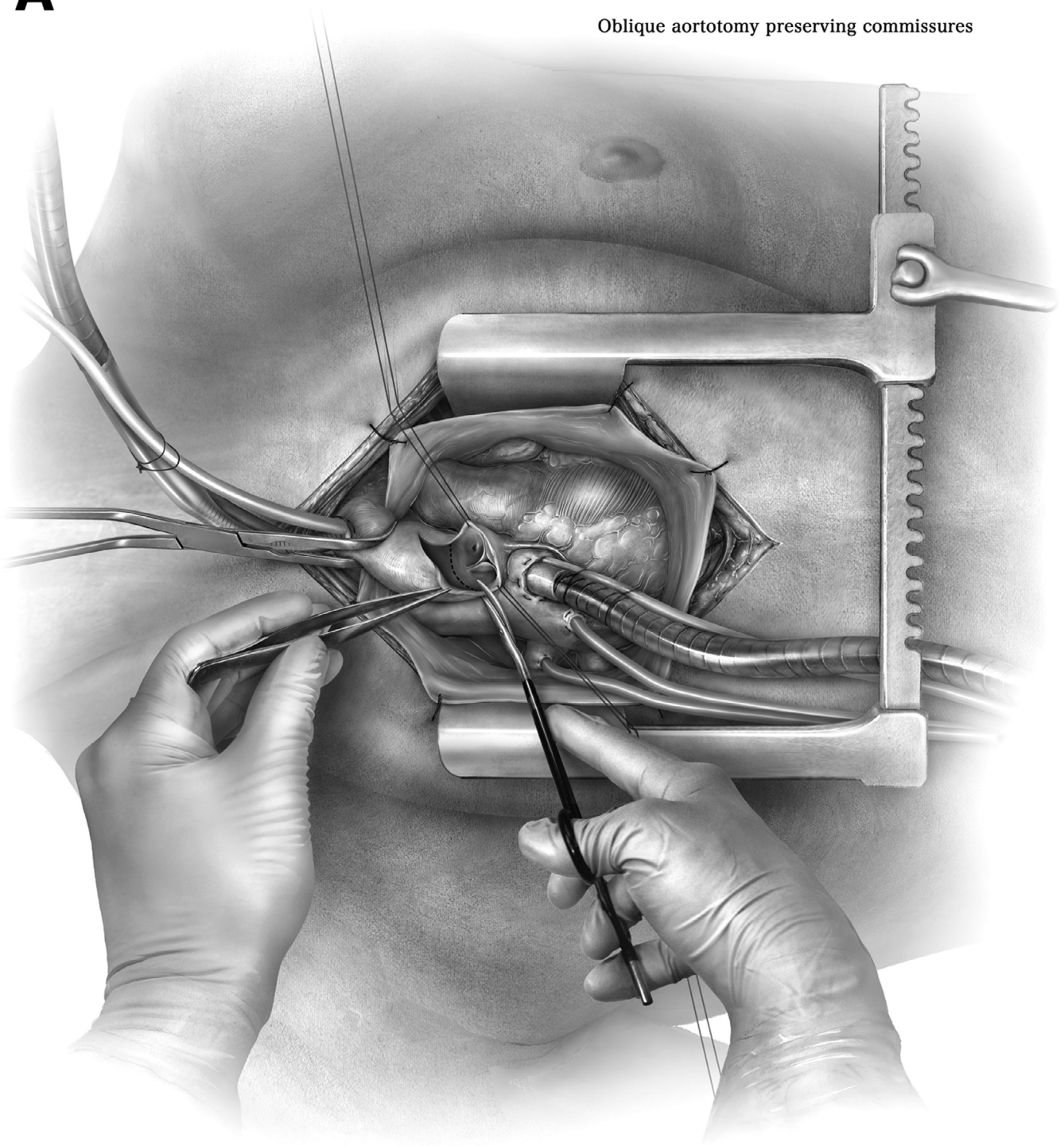
Address reprint requests to Hans-Joachim, MD Department of Thoracic and Cardiovascular Surgery, Saarland University Medical Center, Kirrberger Straße 100 D-66424, Homburg/Saar, Germany. E-mail: [h-j.schaefers@uks.eu](mailto:h-j.schaefers@uks.eu)



**Figure 1** Patient assessment and selection. Careful assessment of the echocardiogram is part of the surgical procedure. Relevant aortic regurgitation is no contraindication to root remodeling, it should simply generate awareness of an increased probability of cusp prolapse. The short axis view will show aortic valve anatomy; it may also show cusp calcification (which is generally not a good substrate for repair). The long-axis view allows measurement of aortic dimensions, such as annular and sinus size. Care must be taken in the interpretation of the data. A long-axis view which is not placed in the center may give false low readings. In addition, annular size determined by intubation with a Hegar dilator is often larger than that measured by TEE. To us no degree of AR and no annular size is a contraindication to the application of VPS, that is, root remodeling. The presence of relevant cusp calcification should carefully be looked for, keeping in mind that echocardiography tends to underestimate the degree of valve calcification. Calcified cusps are poor substrates for repair, even if cusp mobility is still preserved. These valves will have a high probability of developing relevant stenosis over the subsequent 10-15 years. AR, aortic regurgitation; VPS, valve-preserving surgery; TEE, transesophageal echocardiography.

**A**

## Oblique aortotomy preserving commissures



**Figure 2** (A and B) The aorta is best opened by a longitudinal or oblique incision, carefully avoiding the possible location of the anterior (right/noncoronary) commissure. Under vision, the incision is then extended towards the root, and the aorta is completely transected 6-10mm above the level of the commissures. Stay sutures placed in the aortic tissue above the commissures will improve exposure. The cusps are carefully inspected for structural integrity and absence of calcification. Fenestrations may be present; we commonly do not address them unless they are involved in the mechanism of prolapse. The measurement of tissue height in the center of the cusp (geometric height; 15) will help in selecting appropriate cusps for preservation, it also helps in selecting adequate sizes of vascular graft and ultimate annular diameter. Normal geometric height in an adult tricuspid aortic valve is 19-21mm. A geometric height of less than 17-18mm will place the results of VPS in question.

**B**

Measuring geometric height of left cusp

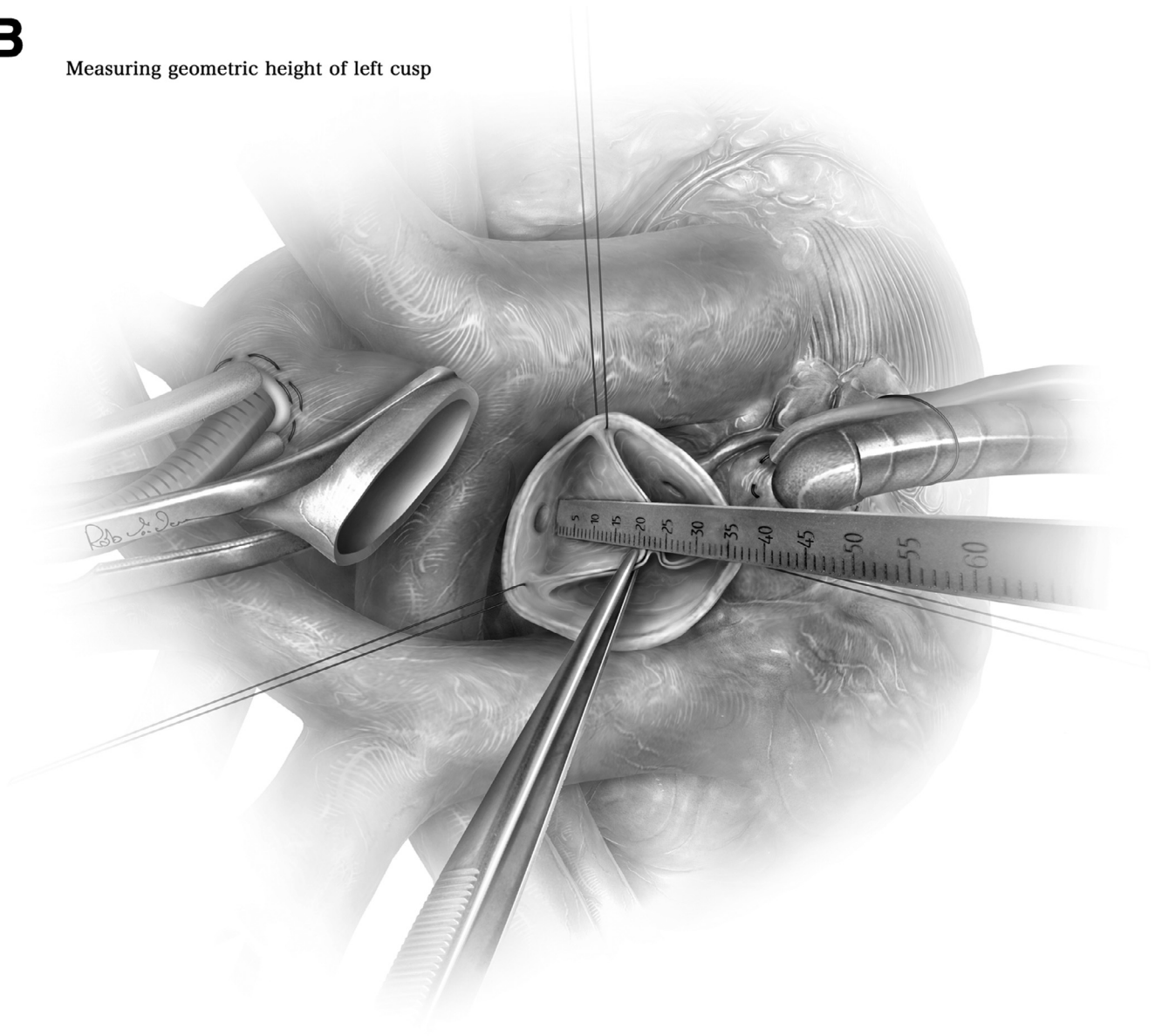
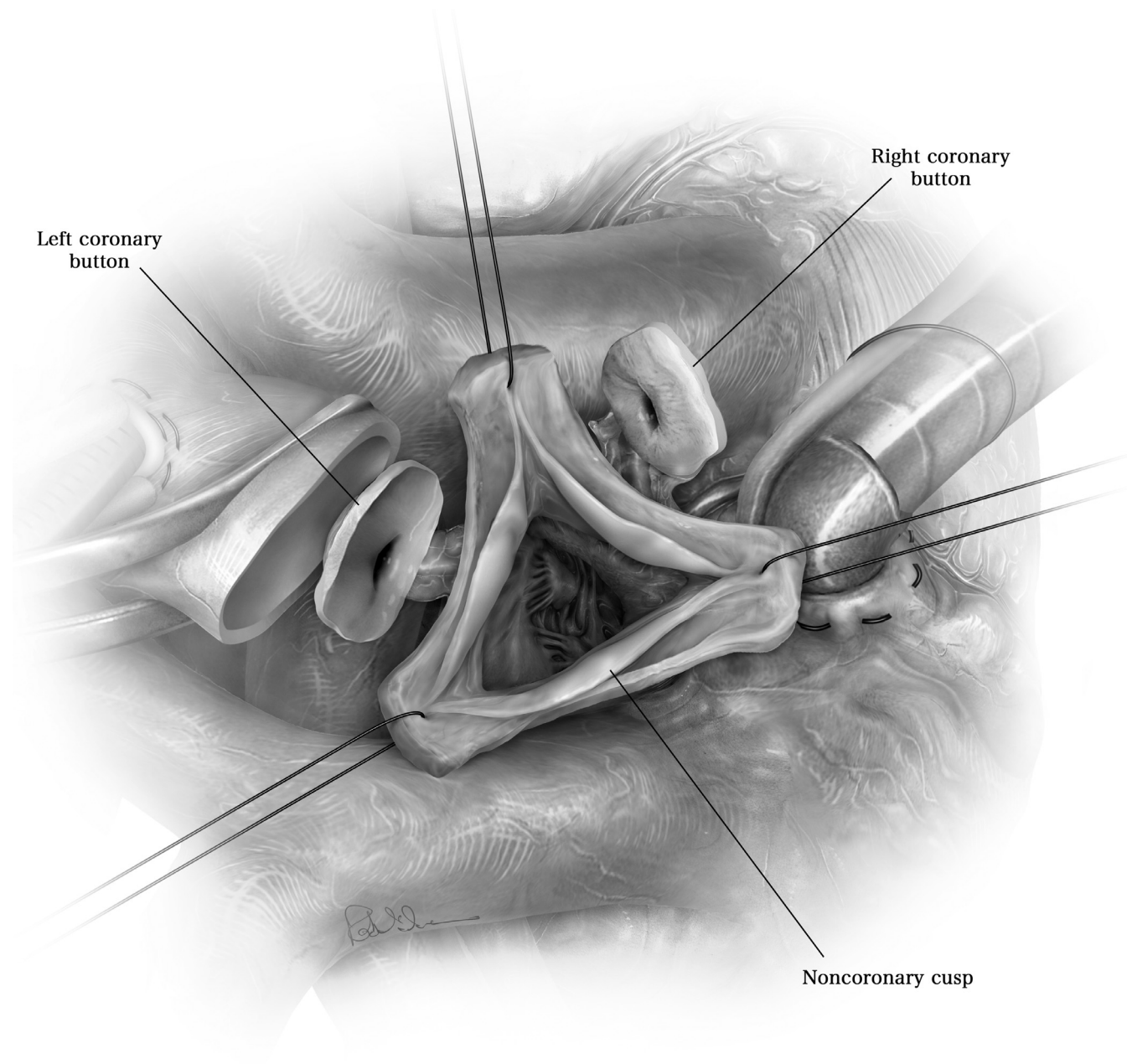
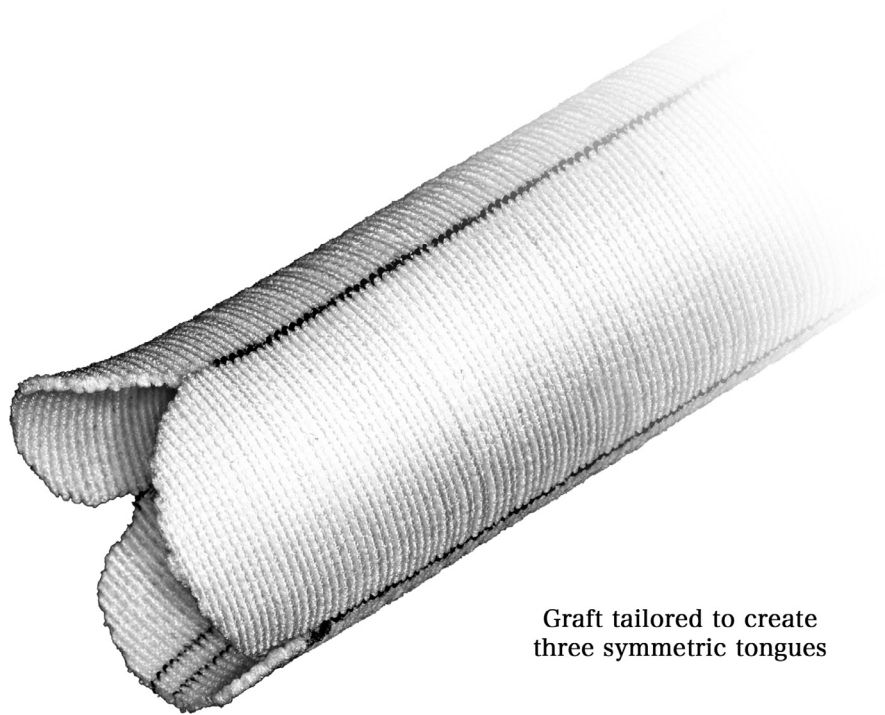


Figure 2 Continued.



**Figure 3** The aortic root is mobilized from the surrounding tissue and the sinuses are excised, leaving 5-8mm of aortic wall adjacent to the cusp insertion lines. If relevant extension of myocardium into the sinus is encountered the aortic wall may be excised completely. The suture line will later be placed into or close to the cusp insertion, also in the presence of muscle extension into sinus. The coronary ostia are mobilized just sufficiently to allow for subsequent easy and tension-free anastomosis.

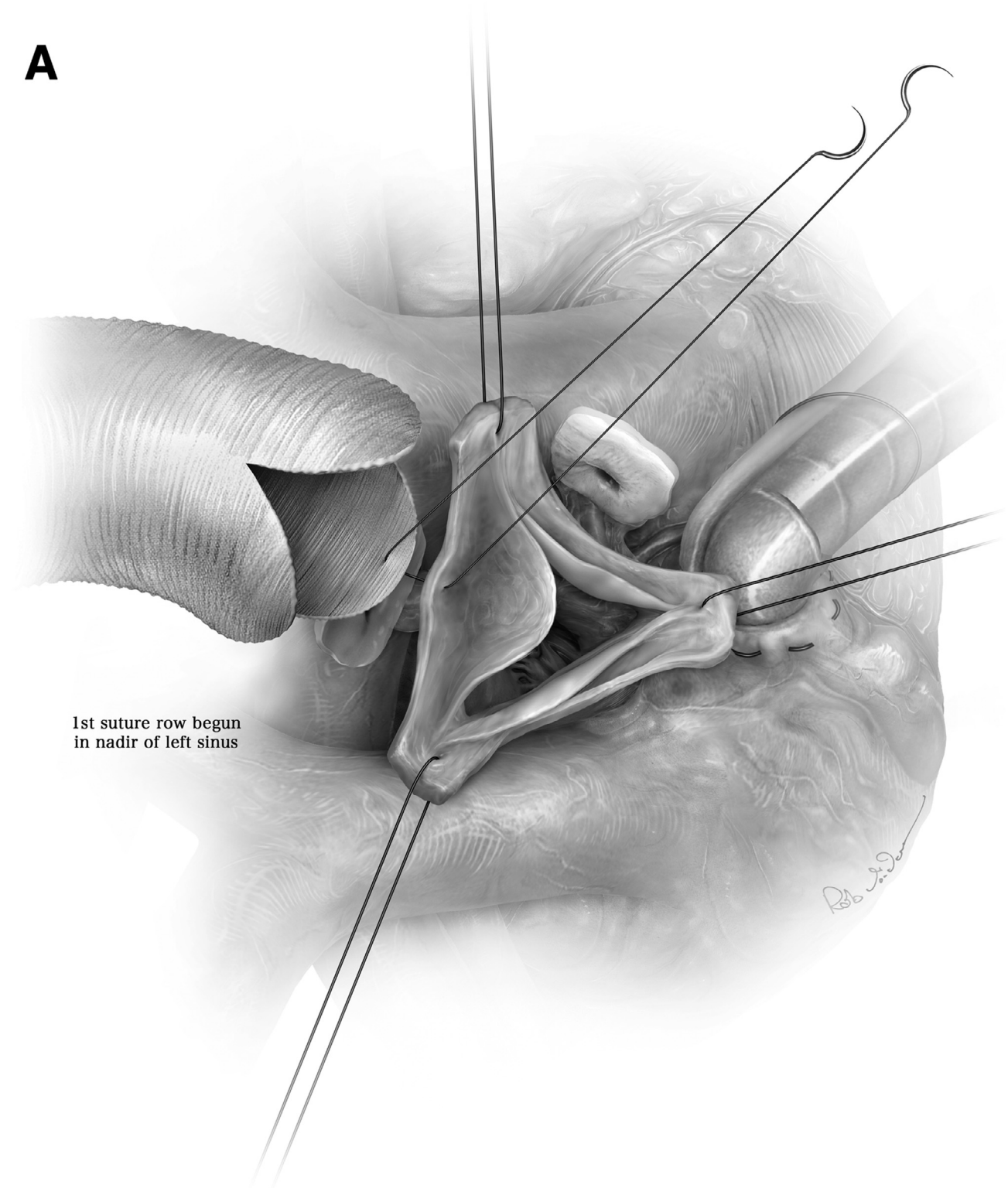


Graft tailored to create  
three symmetric tongues

**Figure 4** A vascular graft is chosen taking patient size and cusp height into consideration. We usually take body surface area of the patient into consideration; with a BSA of more than  $1.8 \text{ m}^2$  our preference is a 26mm graft, for smaller individuals we choose a 24mm tube. With a cusp geometric height of 20mm a 26mm graft will be a suitable choice; if effective height is lower than 20mm a 24 or even a 22mm graft will result in a good root configuration. The graft is tailored to create 3 symmetric tongues. This usually accommodates also somewhat asymmetric root dilatation. The incisions in the graft are made approximately 2cm long, anticipating that they will be extended later. They are rounded with the assistant holding the corners under tension. BSA, body surface area.



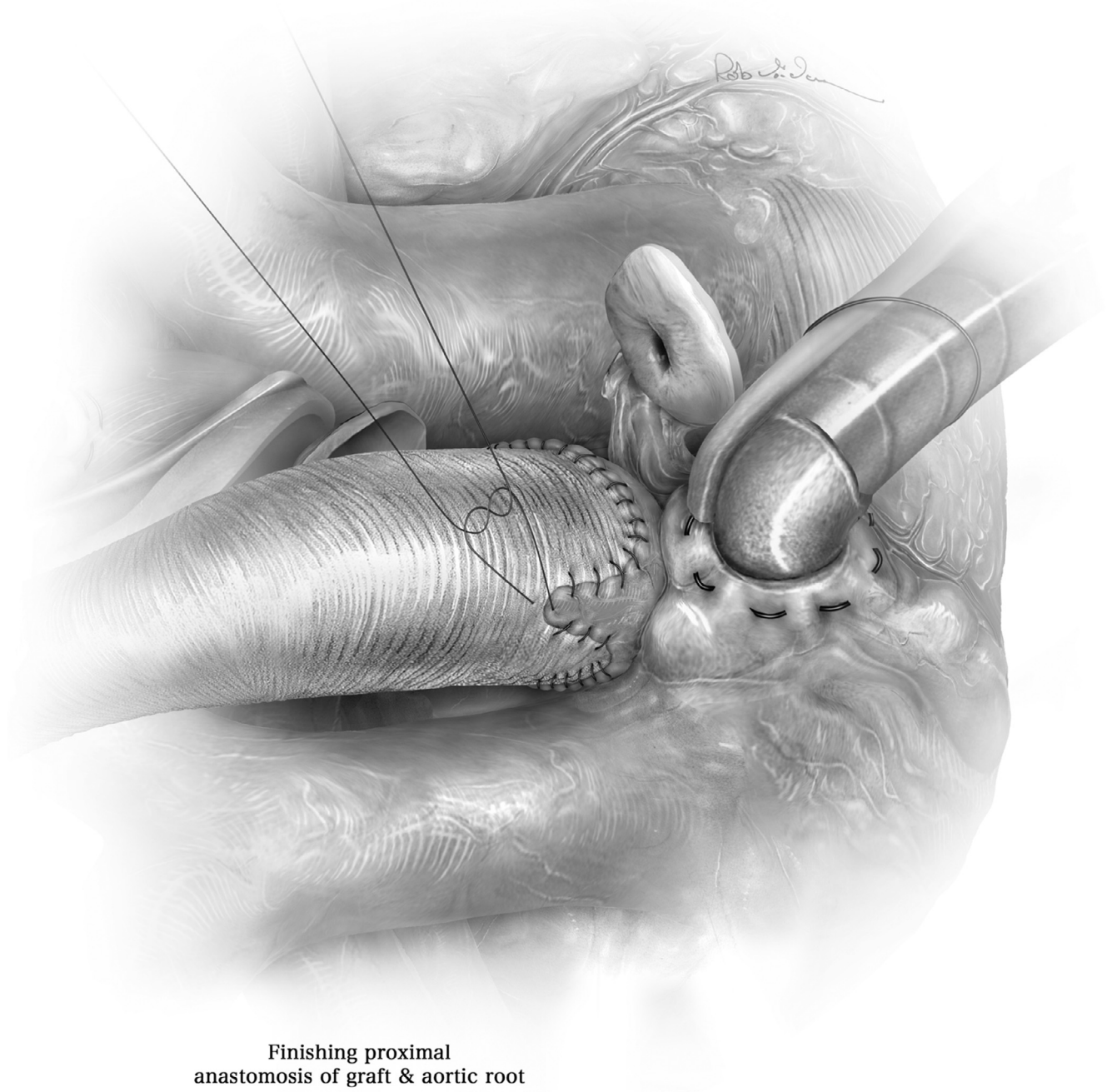
A



1st suture row begun  
in nadir of left sinus

**Figure 5** (A and B) The graft is now sutured to the remnants of the aortic root taking care that the needle is passed very close to or actually best through the cusp insertion lines. It is best to start in the nadir of the sinus since these stitches will be difficult to control with the heart beating. Keeping tension on stay sutures placed above the commissures facilitates this step. We begin in the center of the left cusp and suture each end of the suture towards the commissure. In the central part of the sinus the distance between the stitches is best identical between graft and aorta usually 3mm. Halfway up to the commissure the distance on the graft is increased to 5mm while the distance on the aorta is kept constant. This will place redundant graft material into the sinus. While it will contribute to physiologic bulging of the sinuses it is very important in order to avoid commissural height restriction at all cost. Once the sinus sutures have been completed they are tied; it is practical to leave these sutures long to use them as stay sutures for the subsequent maneuvers.

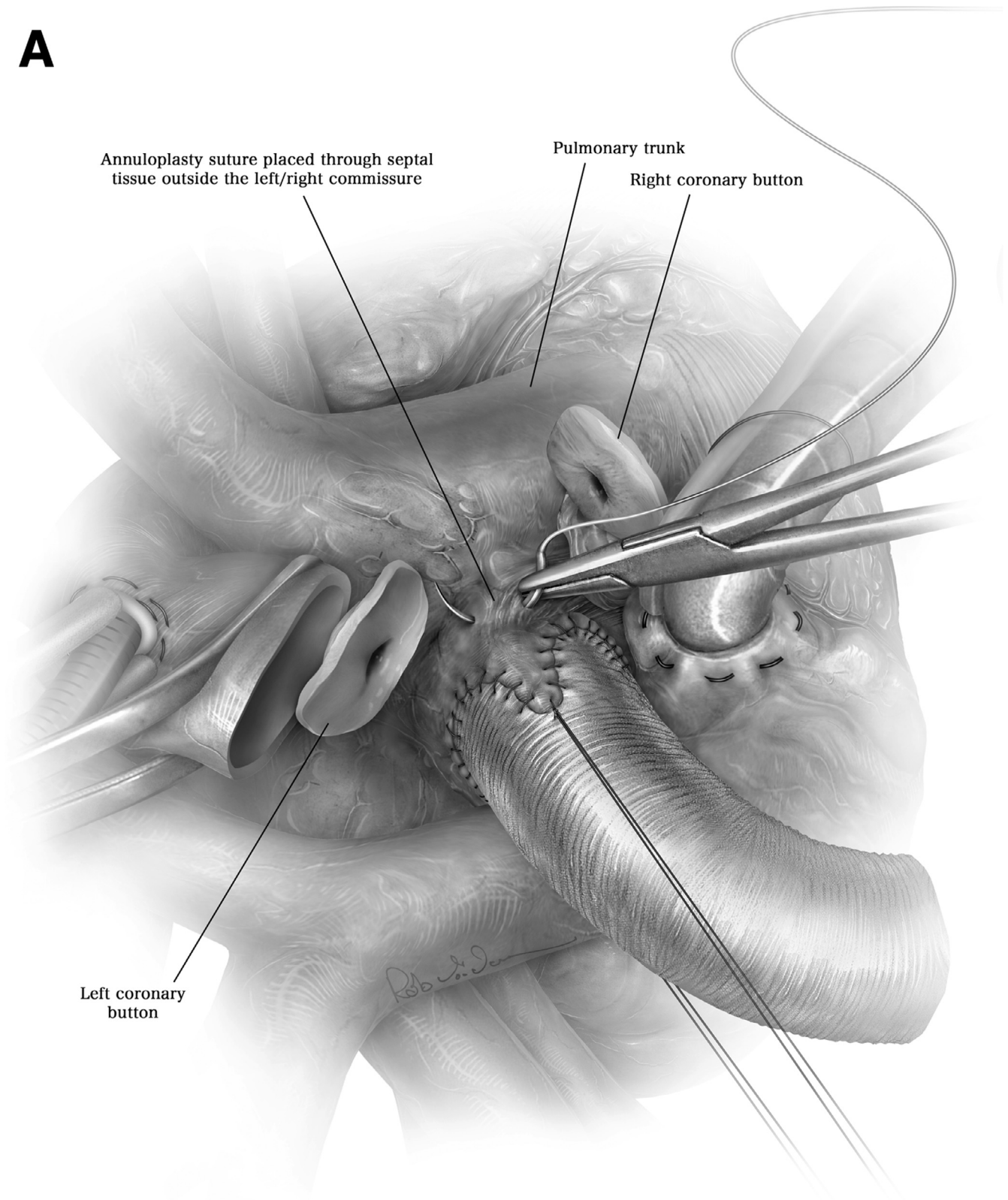
**B**



Finishing proximal  
anastomosis of graft & aortic root

**Figure 5 Continued.**

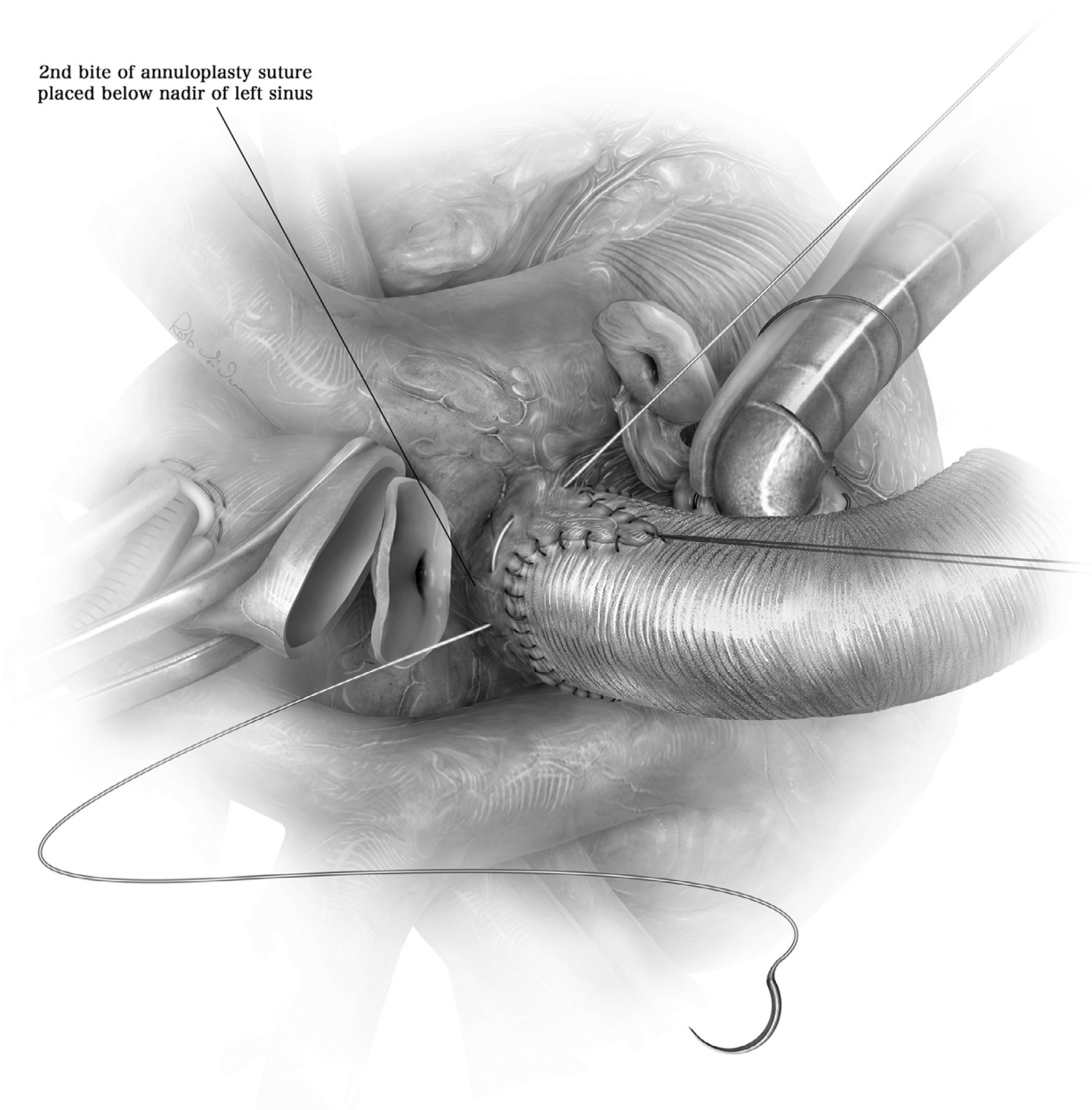


**A**

**Figure 6** (A-D) If an annuloplasty is necessary (we employ it in connective tissue disease and preexistent annular diameter >27mm) a simple suture annuloplasty can be placed. A strong expanded polytetrafluorethylene suture (PTFE) (Gore-Tex CV-0; WL Gore and Associates, Munich, Germany) is placed through the septal tissue outside the left/right commissure and then through the bulk of tissue outside the nadirs of the 3 sinuses. This is facilitated by pulling on the graft while passing the needle through the tissues. A Hegar dilator of predetermined size is placed through the graft and the valve into the left ventricular outflow tract, and the PTFE suture is firmly tied around the Hegar.

**B**

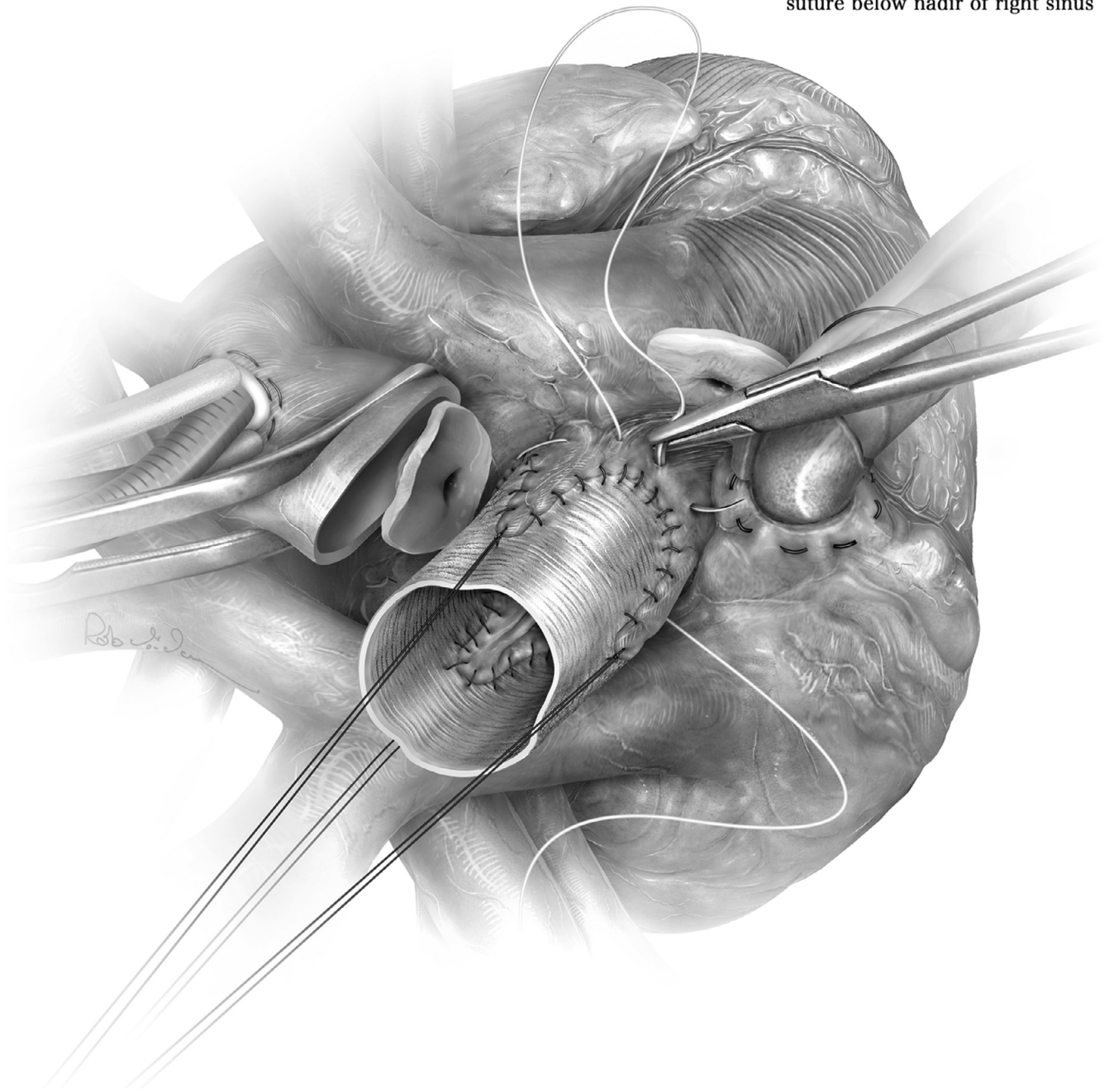
2nd bite of annuloplasty suture placed below nadir of left sinus



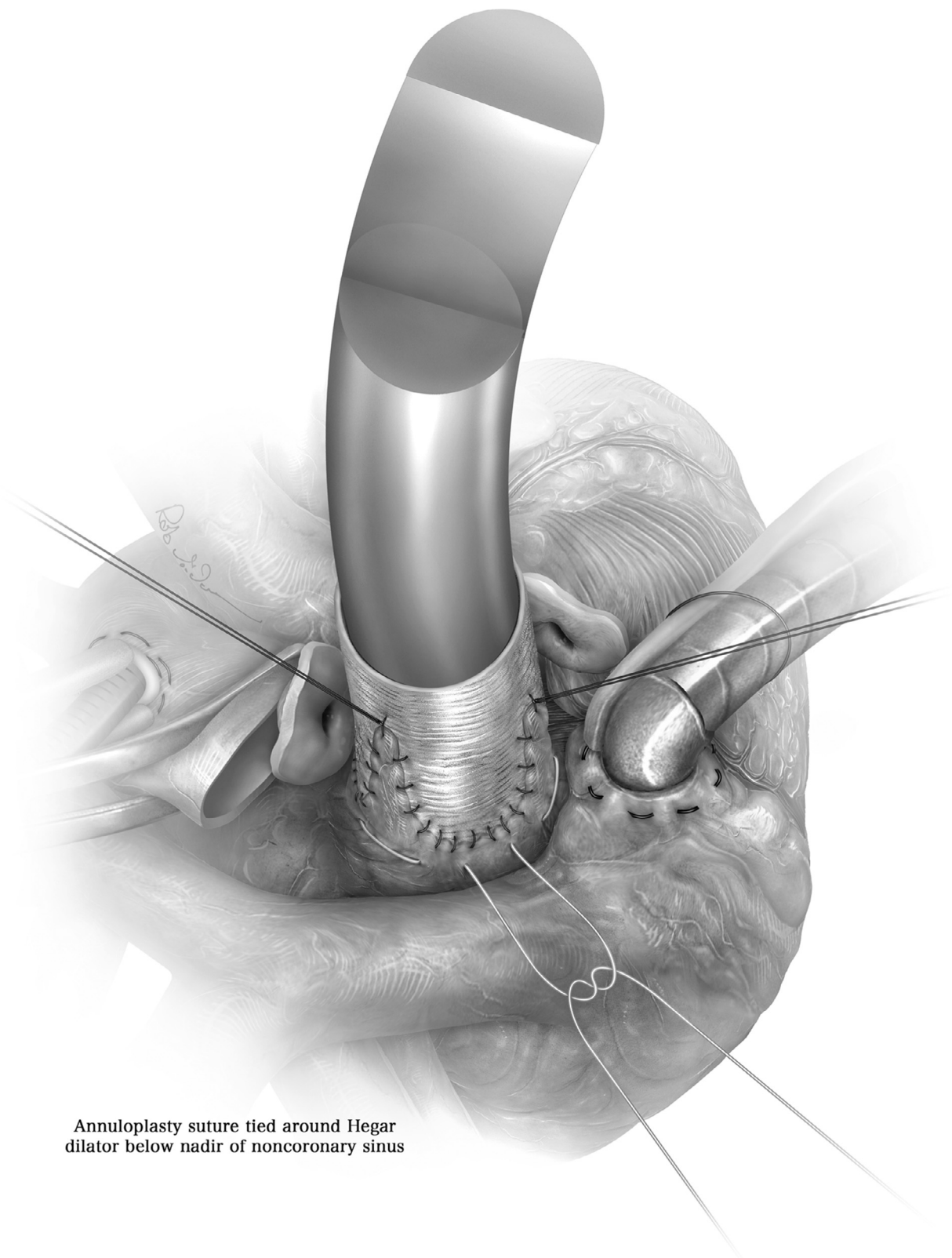
**Figure 6 Continued.**

**C**

Clockwise bite of annuloplasty suture below nadir of right sinus

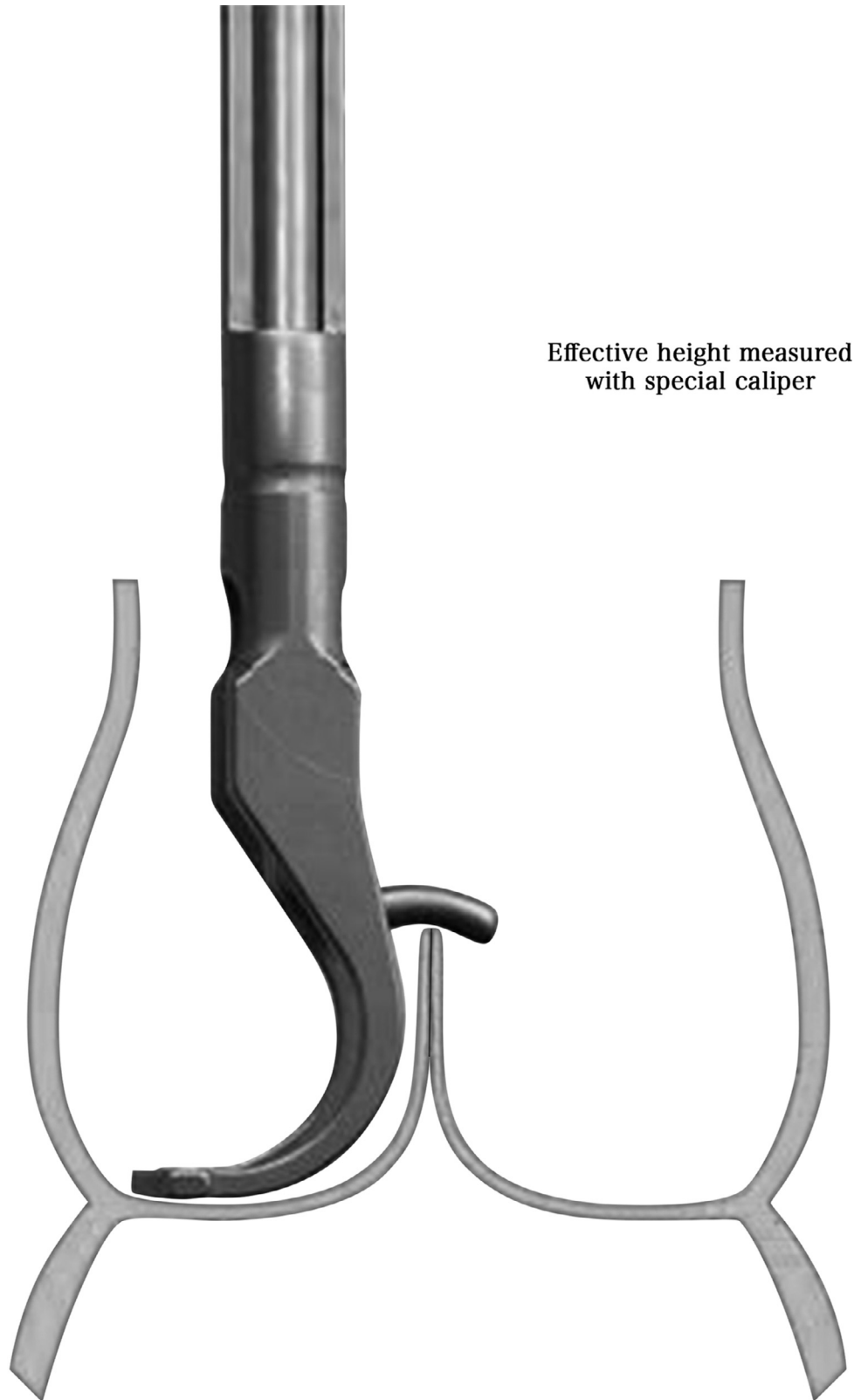


**Figure 6 Continued.**

**D**

Annuloplasty suture tied around Hegar dilator below nadir of noncoronary sinus

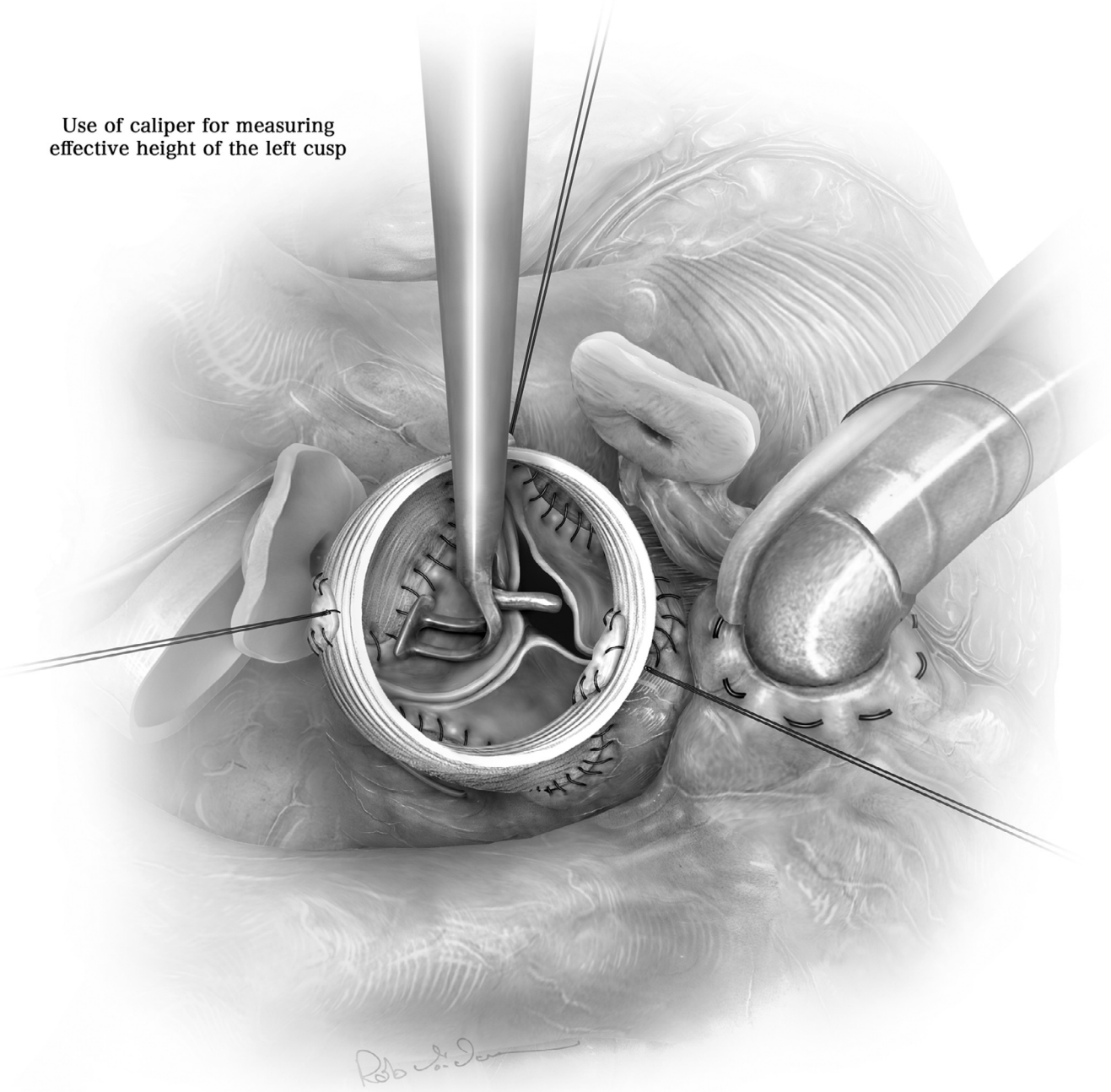
**Figure 6 Continued.**

**A**

**Figure 7** (A and B) Once the root replacement is complete the valve has to be assessed for its configuration. Cusp prolapse may have been apparent already preoperatively (best indicated through eccentricity of the regurgitant jet); it may have been masked by root dilatation and only become apparent after normalization of root dimensions. Also the preoperative degree of regurgitation correlates with the incidence and severity of prolapse seen after root replacement. The more root replacement reduces intercommissural distance the more cusp prolapse has to be expected; it thus has to be expected especially in the presence of marked root dilatation. In order to achieve good exposure, the graft is cut about 2cm above the commissures. The ends of the commissural sutures are placed under upward and outward tension, carefully maintaining their circumferential orientation. The valve is carefully inspected, the three cusp margins should be at identical level and coapt well. The intraoperative measurement of cusp effective height<sup>6</sup> using a caliper (Fehling Instruments, Karlstein, Germany; Genesee Biomedical Inc., Denver, CO) has been helpful as additional test. Effective height should be approximately half of geometric height<sup>15</sup> is 20mm an effective height of 9-10mm will be normal. In using the caliper care has to be taken to align it with the axis of the left ventricular outflow tract.

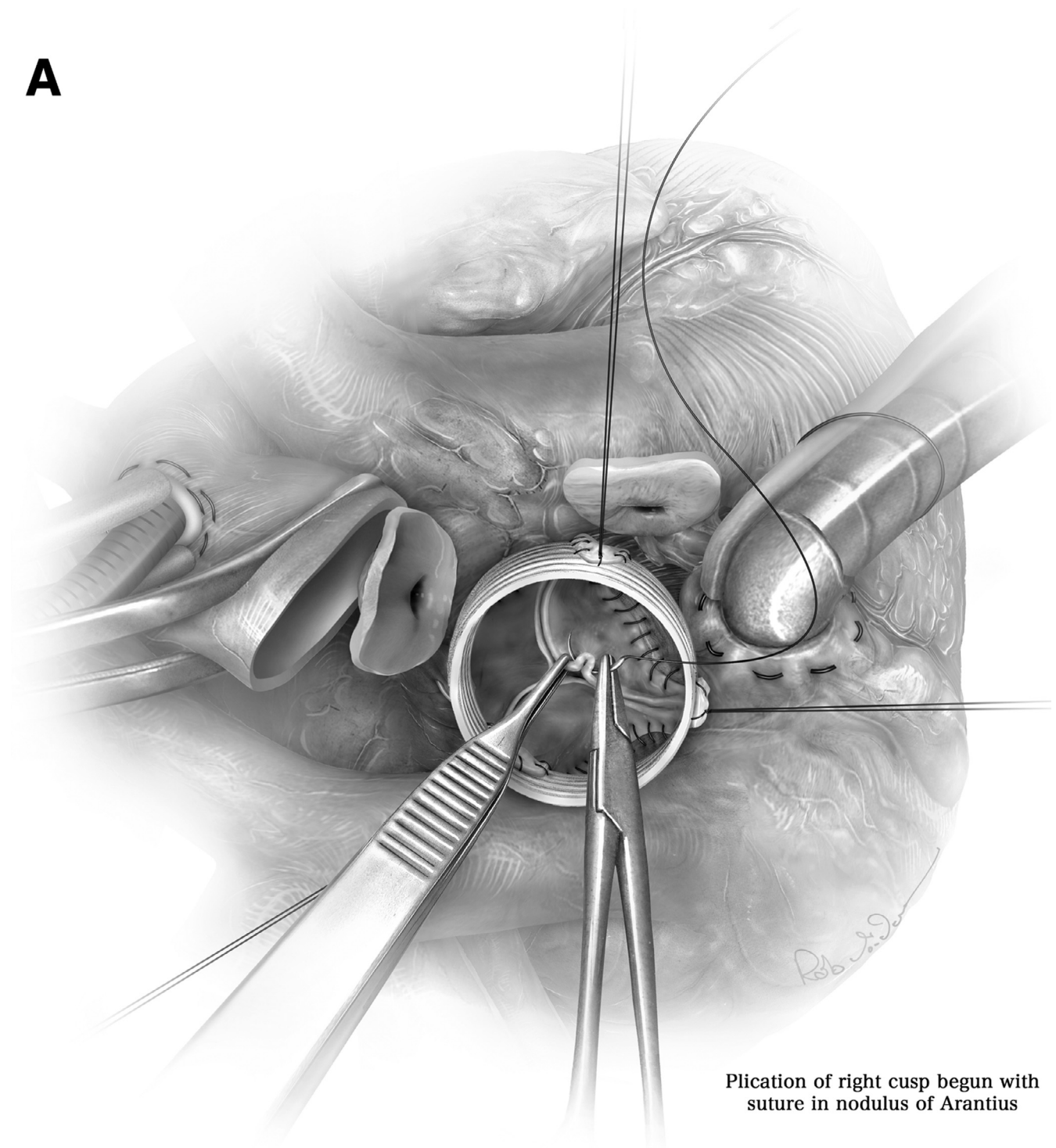
**B**

Use of caliper for measuring effective height of the left cusp



**Figure 7 Continued.**

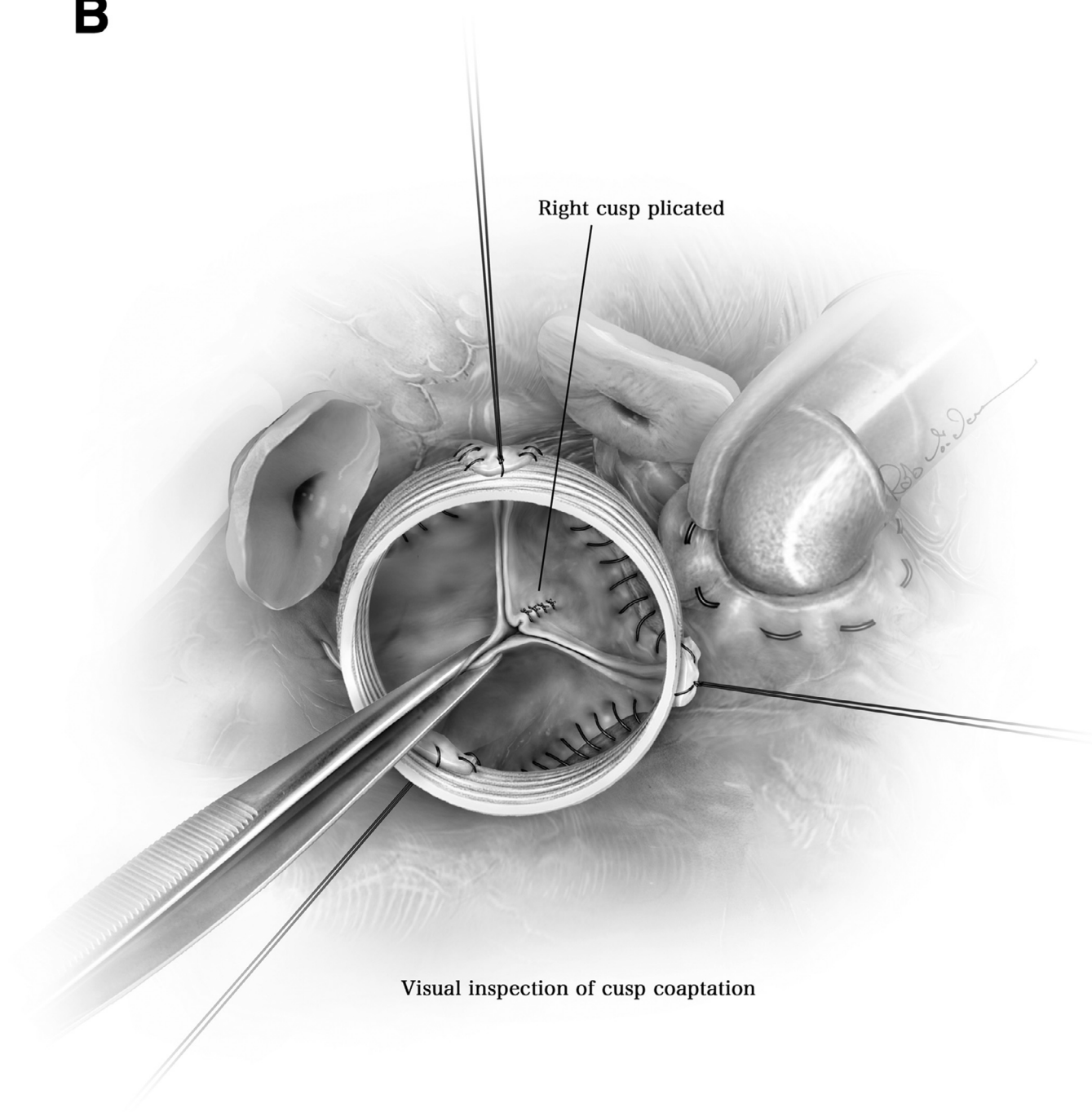


**A**

**Plication of right cusp begun with suture in nodulus of Arantius**

**Figure 8** (A and B) If prolapse is found, it can easily be corrected by shortening of the free cusp margin, in case of marked tissue redundancy also extending into the belly of the cusp. The easiest and most reproducible technique is plication in the central part of the cusp which has the lowest stress in diastole. This may be done stepwise; a first suture is placed in the tissue of the nodulus of Arantius, and its effect on cusp configuration is reassessed by visual inspection and also measurement of effective height. If more sutures are necessary they can be added. Once the desired configuration is achieved mild tension is placed on the end of the suture. If a bulge appears in the belly of the cusp later billowing may be the consequence. While the effect of billowing on valve durability is still uncertain, this can easily be avoided by placing additional plating sutures into the central belly of the cusp tissue until the bulge has disappeared. Restriction of the cusp after root replacement is rare. It may be caused by creating a graft tongue that is too wide for the given anatomy. This can easily be detected by visual inspection and by measuring an effective height larger than 10mm. If this is the case circumferential plication of the graft at the level of the sinotubular junction will reduce intercommissural distance and thus decrease restriction. Final inspection should show all cusp margins at identical level with good coaptation in the center. Some surgeons advocate a water test. We do not use it and have not found this to be helpful. The water test will only expose the valve to a pressure of several cm of water column and thus not mimic the physiologic scenario. Giving cardioplegia into the root will distort the valve because the graft has been trimmed to short length. Leaving the graft longer will make assessment of the valve and any correction much more difficult. For us valve assessment thus solely depends on inspection and measurement of effective height.

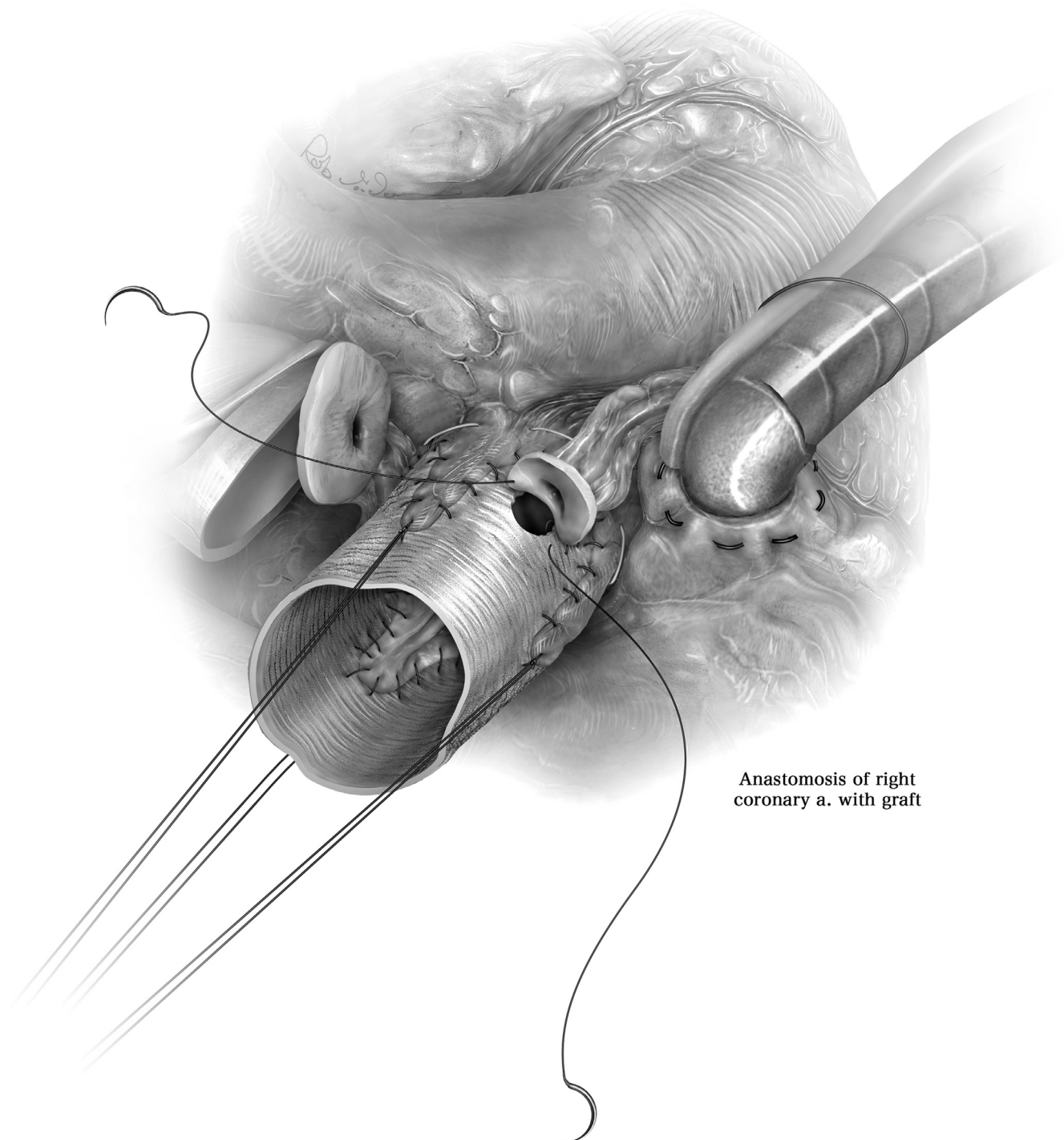
**B**



Right cusp plicated

Visual inspection of cusp coaptation

**Figure 8 Continued.**



Anastomosis of right  
coronary a. with graft

**Figure 9** Finally, the coronary arteries are reattached to the graft. We create openings in the graft that are only slightly larger than the ostial size. In suturing we take care that most of the aortic tissue is eliminated by placing the stitches close to the ostium. This will minimize the probability of coronary aneurysms, at least in patients with connective tissue disease.

## Comment

Over the past 25 years valve-preserving aortic replacement has become an increasingly accepted form of treatment for many patients with root aneurysms, with or without aortic regurgitation. By some root remodeling is felt to be inferior to valve reimplantation because of the assumed lack of annular reduction and stabilization.<sup>16</sup> On the other hand, we have been very satisfied with the functional long-term results if combined with cusp repair (if needed) as a standard approach.<sup>17</sup>

With increasing experience, we have found that normalization of root dimensions through VPS will unmask pre-existing prolapse in many patients. This may easily be detected by visual inspection if it is limited to one cusp only. If 2 or all 3 cusps are affected the results of both forms of VPS have been inferior, simply because visual judgment does not suffice to detect and correct prolapse adequately. The quantitative assessment of valve configuration with measurement of effective height using a caliper has been very helpful in order to improve valve configuration and extend the principle of VPS to more patients. After routinely applying the concept, we<sup>17</sup> and others<sup>7,18</sup> have been able to improve the results significantly. In retrospect, it may be argued that many failures of VPS irrespective of the technique used may have been caused by lack of recognition and correction of cusp prolapse, simply because valve configuration was simply eye-balled.

## Annuloplasty

In the past years, the addition of an annuloplasty has been propagated as a routine procedure in order to improve durability of aortic valve function.<sup>7</sup> The evidence supporting this hypothesis, however, is weak, since the authors not only introduced their current annuloplasty but also intraoperative assessment of effective height as configuration parameter.<sup>7</sup> Nevertheless, we have similarly adopted the concept of adding a suture annuloplasty<sup>10</sup> whenever annular dilatation (>27mm) is present. Computer simulation studies have shown that annular reduction increases coaptation height<sup>19</sup>; it may thus compensate inaccuracies of cusp repair. Clinically, a higher proportion of competent aortic valves have been observed with addition of an annuloplasty.<sup>11</sup> At this time, however, the benefit of an annuloplasty on the hard end point of freedom from reoperation has not yet been shown. Interestingly, we have been able to document annular reduction and stabilization even without annuloplasty.<sup>9</sup>

A controversy still exists between root remodeling and valve reimplantation, which is currently probably the more frequently practiced procedure. Valve reimplantation has been shown to result in 20-year valve stability, and the annular stabilization inherent in the procedure has been considered as the main reason.<sup>16</sup> On the other hand, even in the hands of David et al.<sup>16</sup> remodeling has produced excellent long-term stability, at least in patients without connective tissue disease. In individuals with very large preoperative root dimensions also reimplantation has been associated with suboptimal results.<sup>18</sup> The excellent durability of David has not been reproduced by others<sup>18</sup> including our own results.<sup>3,12</sup> This brings up the question to what degree

preoperative patient selection rather than the superiority of the technique<sup>20</sup> has been a strong determinant of functional results. In fact, we have not seen any evidence of long term superiority of reimplantation over root remodeling.<sup>3,12</sup>

In direct comparison root remodeling has been the procedure that requires less dissection (at least if done without a ring annuloplasty) and shorter ischemic times. This is particularly so if muscle extension into the sinus is present; in that scenario reimplantation would require very deep dissection,<sup>21</sup> which is feasible but traumatic. Experimental studies have shown better preservation of cusp motion with remodeling<sup>22,23</sup>; whether this translates into better true long-term valve durability with the potential of a life-long cure still remains to be shown.

## Conclusion

In conclusion, root remodeling is a viable option in VPS. If done adequately excellent long term stability can be achieved. An important technical detail is generation of appropriate commissural height; this can be achieved by creation of graft tongues that are longer than the height of the native commissures. The second most important technical detail is maximal attention to valve configuration; this is probably the single most important determinant of valve function and durability. The intraoperative measurement of effective height in addition to careful inspection has proven to be extremely helpful in this regard. The addition of an annuloplasty helps in achieving good coaptation. In its current form, remodeling requires less dissection and less suturing compared to valve reimplantation and thus appears to be the more efficient form of VPS (Figs. 1-9).

## References

1. Sarsam MA, Yacoub M: Remodeling of the aortic valve anulus. *J Thorac Cardiovasc Surg* 105:435-438, 1993
2. David TE, Feindel CM: An aortic valve-sparing operation for patients with aortic incompetence and aneurysm of the ascending aorta. *J Thorac Cardiovasc Surg* 103:617-621, 1992. discussion 622
3. Kuniyara T, Aicher D, Rodioncheva S, et al: Preoperative aortic root geometry and postoperative cusp configuration primarily determine long-term outcome after valve-preserving aortic root repair. *J Thorac Cardiovasc Surg* 143:1389-13895, 2012
4. David TE: Current readings: Aortic valve-sparing operations. *Semin Thorac Cardiovasc Surg* 26:231-238, 2014
5. Asano M, Kuniyara T, Aicher D, et al: Mid-term results after sinutubular junction remodelling with aortic cusp repair. *Eur J Cardiothorac Surg* 42:1010-1015, 2012
6. Schäfers HJ, Bierbach B, Aicher D: A new approach to the assessment of aortic cusp geometry. *J Thorac Cardiovasc Surg* 132:436-438, 2006
7. Lansac E, Di Cetta I, Sleilaty G, et al: Remodeling root repair with an external aortic ring annuloplasty. *J Thorac Cardiovasc Surg* 153:1033-1042, 2017
8. Yacoub MH, Aguib H, Gamrah MA, et al: Aortic root dynamism, geometry, and function after the remodeling operation: Clinical relevance. *J Thorac Cardiovasc Surg* 156:951-962.e2, 2018
9. Kuniyara T, Arimura S, Sata F, et al: Aortic annulus does not dilate over time after aortic root remodeling with or without annuloplasty. *J Thorac Cardiovasc Surg* 155:885-894.e3, 2018
10. Schneider U, Aicher D, Miura Y, et al: Suture annuloplasty in aortic valve repair. *Ann Thorac Surg* 101:783-785, 2016
11. Aicher D, Schneider U, Schmied W, et al: Early results with annular support in reconstruction of the bicuspid aortic valve. *J Thorac Cardiovasc Surg* 145(3 Suppl):S30-S34, 2013

12. Schneider U, Ehrlich T, Karlova I, et al: Valve-sparing aortic root replacement in patients with Marfan syndrome—the Homburg experience. *Ann Cardiothorac Surg* 6:697–703, 2017
13. de Kerchove L, Boodhwani M, Glineur D, et al: Valve sparing-root replacement with the reimplantation technique to increase the durability of bicuspid aortic valve repair. *J Thorac Cardiovasc Surg* 142:1430–1438, 2011
14. David TE, David CM, Feindel CM, et al: Reimplantation of the aortic valve at 20 years. *J Thorac Cardiovasc Surg* 153:232–238, 2017
15. Schäfers HJ, Schmied W, Marom G, et al: Cusp height in aortic valves. *J Thorac Cardiovasc Surg* 146:269–274, 2013
16. David TE, Feindel CM, David CM, et al: A quarter of a century of experience with aortic valve-sparing operations. *J Thorac Cardiovasc Surg* 148:872–879, 2014. discussion 879–80
17. Schäfers HJ, Raddatz A, Schmied W, et al: Reexamining remodeling. *J Thorac Cardiovasc Surg* 149(2 Suppl):S30–S36, 2015
18. Miyahara S, Matsueda T, Izawa N, et al: Mid-term results of valve-sparing aortic root replacement in patients with expanded indications. *Ann Thorac Surg* 100:845–851, 2015. discussion 852
19. Marom G, Haj-Ali R, Rosenfeld M, et al: Aortic root numeric model: annulus diameter prediction of effective height and coaptation in post-aortic valve repair. *J Thorac Cardiovasc Surg* 145:406–411.e1, 2013
20. Miller DC: Aortic valve-sparing surgery: Yes, but not for every patient and select the center very carefully. *J Am Coll Cardiol*. 68:1848–1850, 2016
21. Nawaytou O, Mastrobuoni S, de Kerchove L, et al: Deep circumferential annuloplasty as an adjunct to repair regurgitant bicuspid aortic valves with a dilated annulus. *J Thorac Cardiovasc Surg* 156:590–597, 2018
22. Fries R, Graeter T, Aicher D, et al: In vitro comparison of aortic valve movement after valve-preserving aortic replacement. *J Thorac Cardiovasc Surg* 132:32–37, 2006
23. Leyh RG, Schmidtke C, Sievers HH, et al: Opening and closing characteristics of the aortic valve after different types of valve-preserving surgery. *Circulation* 100:2153–2160, 1999