

Anatomic assessment of the mandibular buccal shelf for miniscrew insertion in white patients

Tarek Elshebiny, Juan Martin Palomo, and Sebastian Baumgaertel

Cleveland, Ohio

Introduction: Cortical bone thickness, bone width, insertion depth, and proximity to nerves are important factors when planning and placing orthodontic miniscrews. The objective of this study was to anatomically assess the mandibular buccal shelf in a white patient population as the insertion site for orthodontic miniscrews by investigating these 4 variables. **Methods:** Measurements were made on cone-beam computed tomography scans of 30 white patients (18 girls, 12 boys; mean age, 14.5 ± 2 years). All measurements were taken adjacent to the distobuccal cusp of the first molar, and the mesiobuccal and distobuccal cusps of the second molar. Additionally, bone depth was measured at 2 height levels, 4 and 8 mm from the cemento-enamel junction. Stereolithographic models of patients were superimposed on the cone-beam computed tomography volumes to virtually create an outline of the soft tissue on the cone-beam computed tomography image to allow identification of the purchase point height (mucogingival junction). The inferior alveolar nerve was digitally traced. Miniscrews (1.6×10 mm) were virtually placed at the buccal shelf, and their insertion depths and relationships to the nerve were assessed. Analysis of variance with post hoc analysis was used for data analysis. **Results:** Insertion sites and measurement levels had significant impacts on both cortical bone thickness and bone width. Cortical bone thickness was typically greatest at the distobuccal cusp of the second molar. Bone width was also greatest at the distobuccal cusp of the second molar 8 mm from the cemento-enamel junction. The greatest insertion depth was found again at the distobuccal cusp to the second molar, whereas the miniscrews had the greatest proximity to the nerve at this site also. **Conclusions:** The distobuccal cusp level of the mandibular second molar is the most appropriate site for miniscrew insertion at the buccal shelf in white patients. (Am J Orthod Dentofacial Orthop 2018;153:505-11)

One of the most important factors when placing orthodontic miniscrews is the presence of sufficient bone at the insertion site.¹ Miniscrews are placed in many anatomic sites depending on the biomechanics used.²⁻⁴ The most popular anatomic sites appear to be the palate, lingual aspect of the maxillary alveolar process, retromolar area, and maxillary and mandibular buccal alveolar processes.²⁻⁶ Several studies have used cone-beam computed tomography (CBCT) to assess cortical bone thickness and overall bone depth to determine the most favorable anatomic insertion sites and to evaluate the structures at risk at various sites.^{1,7}

Recently, the mandibular buccal shelf has been used as an insertion site for orthodontic miniscrews. Indications for the buccal shelf as the insertion site are plentiful, but this site seems to be most useful for the correction of Class III malocclusions.⁸⁻¹⁰ However, despite reports of numerous treated patients, there was inconsistency in selecting the exact placement site in the mandibular buccal shelf; recommendations included adjacent to the first molar, between the first and second molars, and adjacent to the second molar.^{10,11} This wide range of recommendations may be due to strong local anatomic variations at the buccal shelf or the lack of studies that investigated the local anatomy. The purposes of this study were to remedy this lack of anatomic information by evaluating cortical bone thickness and bone width of the mandibular buccal shelf at different potential insertion sites and to assess the relationship between the miniscrews and the inferior alveolar nerve as the only sensitive anatomic structure in this area.

From the Department of Orthodontics, School of Dental Medicine, Case Western Reserve University, Cleveland, Ohio.

All authors have completed and submitted the ICMJE Form for Disclosure of Potential Conflicts of Interest, and none were reported.

Address correspondence to: Sebastian Baumgaertel, Department of Orthodontics, School of Dental Medicine, Case Western Reserve University, 10900 Euclid Ave, Cleveland, OH 44106; e-mail, spb155@case.edu.

Submitted, February 2017; revised and accepted, August 2017.

0889-5406/\$36.00

© 2018 by the American Association of Orthodontists. All rights reserved.

<https://doi.org/10.1016/j.ajodo.2017.08.014>

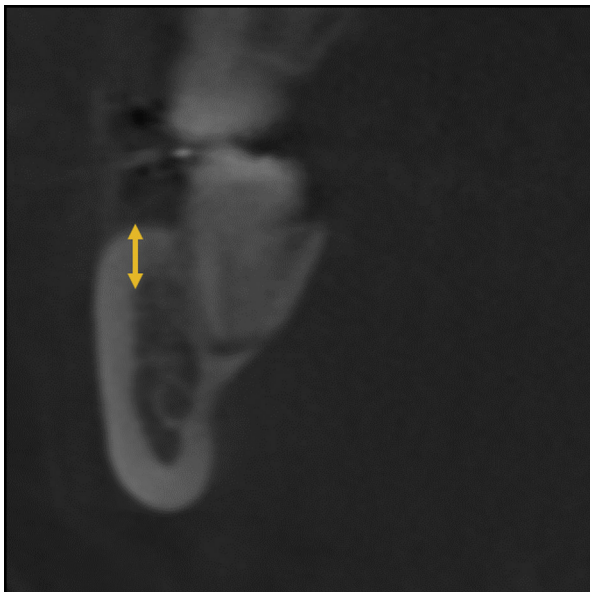


Fig 1. Coronal slice at the distal root of the second molar showing measurement of the cortical bone.

MATERIAL AND METHODS

This study was approved by the Institutional Review Board of Case Western Reserve University in Cleveland, Ohio. The sample consisted of 30 CBCT scans of untreated orthodontic patients (18 girls, 12 boys; average age, 14.5 ± 2 years) from the Department of Orthodontics at Case Western Reserve University who had CBCT imaging prescribed as part of their initial records. No CBCT image was taken for research purposes only. Inclusion criteria consisted of white patients seeking orthodontic treatment and full permanent dentition with fully erupted mandibular second molars and no craniofacial pathology or developmental abnormality. All CBCT images were taken with a low-dose scanner, CB Mercuray (Hitachi Medical Systems of America, Twinsburg, Ohio), using 2 mA, 120 kV(p), resulting in a voxel size of 0.37 mm. All images were analyzed with Dolphin 3D (version 11.9; Dolphin Imaging and Management Solutions, Chatsworth, Calif).

After proper orientation, cortical bone thickness and buccal shelf bone width were surveyed at 3 sites on each side: buccal to the distobuccal cusp of the mandibular first molar (6D), and buccal to the mesiobuccal (7M) and distobuccal (7D) cusps of the mandibular second molar. Cortical bone thickness was defined as the dimension of the cortical bone measured from the midpoint of the osseous ledge buccal to the mandibular first and second molars (buccal shelf), parallel to the contour of the buccal root surfaces of the first or second molar (Fig 1).

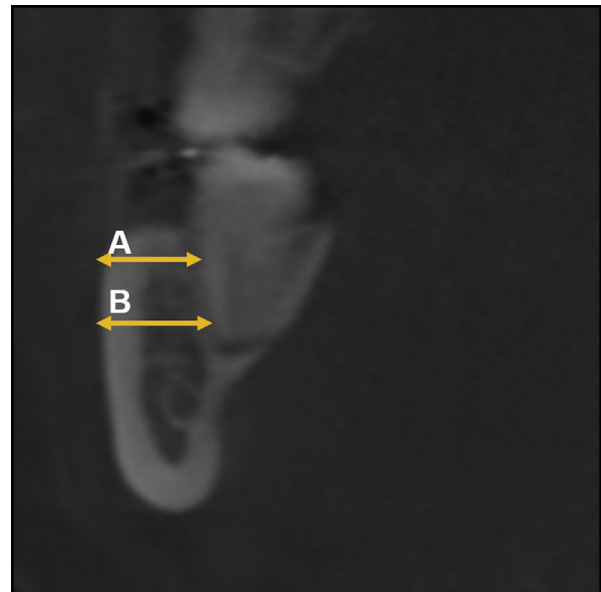


Fig 2. Coronal slice at the distal root of the second molar showing measurement of the overall bone width at: A, 4 mm from the CEJ and B, 8 mm from the CEJ.

Buccal shelf bone width was defined as the total amount of bone available in the buccolingual direction from the most buccal point of the alveolar bone to the root of the mandibular molars at 4 and 8 mm from the cemento-enamel junction (CEJ), parallel to the occlusal plane. Again, measurements were taken at the same 3 sites: buccal to the distobuccal cusp of the mandibular first molar (6D4, 6D8), buccal to the mesiobuccal cusp of the mandibular second molar (7M4, 7M8), and buccal to the distobuccal cusp of the mandibular second molar (7D4, 7D8) (Fig 2).

The inferior alveolar nerve canal was digitally traced using a tool in the software (Fig 3). Stereolithographic models of the patients were superimposed on the CBCT volumes to virtually create an outline of the soft tissues (Fig 4). Miniscrews (1.6 mm diameter \times 10 mm shank length) were then virtually placed at the designated sites. Based on the recommendations of Chang et al,¹⁰ the insertion was initiated (purchase point) at the mucogingival junction as identified on the stereolithographic model. The insertion took place perpendicular to the occlusal plane and was considered complete with the screw head 5 mm above the level of the soft tissue (Fig 5). The insertion depth of the miniscrew and the relationship to the digitally traced inferior alveolar nerve were also assessed at the 3 sites (D6, M7, D7) (Fig 6).

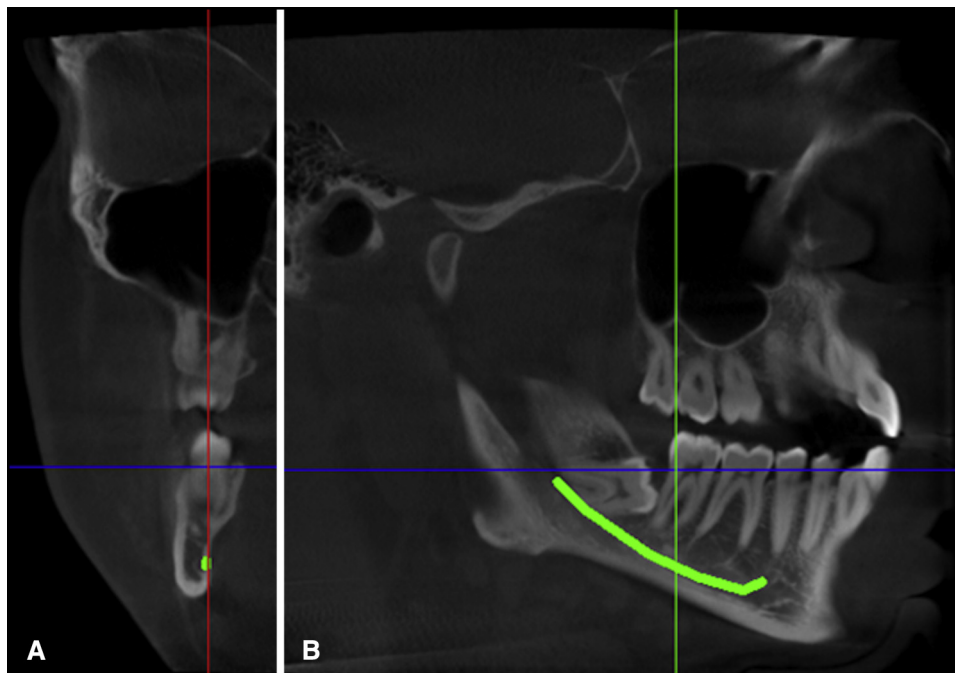


Fig 3. Three-dimensional reconstructions of CBCT image showing the traced nerve canal in different views: **A**, coronal slice; **B**, sagittal slice.

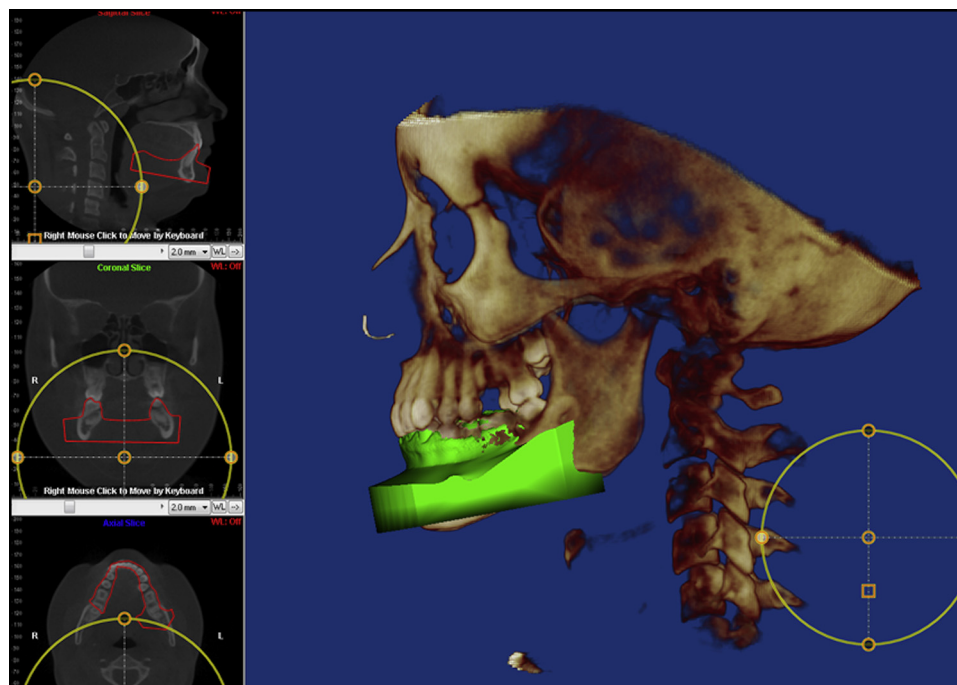


Fig 4. Lower stereolithographic model superimposition on volume renderings in different views.

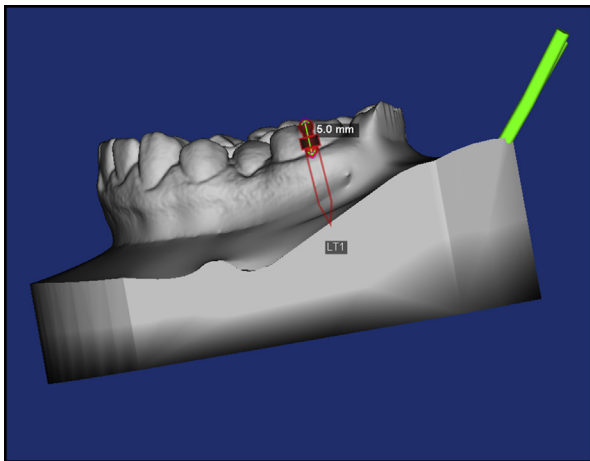


Fig 5. Stereolithographic model after virtual placement of the mini implant showing the screw head 5 mm above the level of the soft tissue.

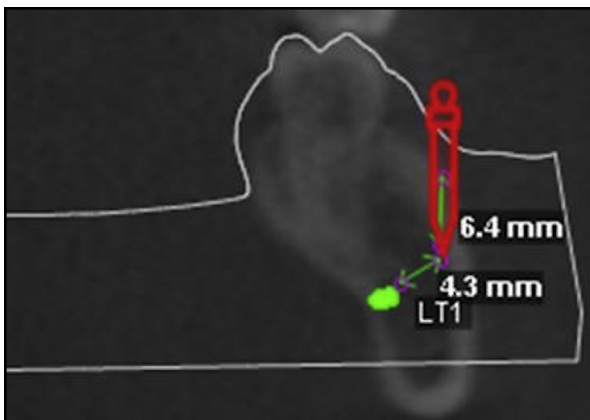


Fig 6. Tomographic slice with traced inferior alveolar nerve, virtually placed miniscrew, and measurements of insertion depth and distance to the nerve.

Statistical analysis

Software (version 17.0; SPSS, Chicago, Ill) was used for all statistical analyses, and significance levels for all tests were set at $P \leq 0.05$. An a priori power calculation suggested that a minimum sample size of 24 participants would be required. Preliminary data analysis suggested a normal frequency distribution (Shapiro-Wilk test). Reliability of the measurement method was assessed by repeating all measurements twice, 2 months apart on 10 slices of 10 CBCTs each. Intraclass correlation showed good reliability ($r = 0.9$). A paired Student t test was used for additional preliminary data analysis to test for differences between the left and right sides. No statistically significant differences were found, so the data

were pooled. Analysis of variance was used to evaluate the influence of the site and measurement level on cortical bone thickness, buccal shelf bone width, amount of implant-bone engagement, and distance from the implant tip to the inferior alveolar nerve, with the Tukey post hoc test evaluating further interactions of the different variables.

RESULTS

Buccal shelf bone width (Table I) was generally thinnest at the distobuccal cusp level of the mandibular first molar when measured at 4 mm from the CEJ (6D4; 3.48 ± 1.29 mm) and thickest at the distobuccal cusp of the mandibular second molar when measured at 8 mm from the CEJ (7D8; 8.13 ± 1.97 mm) (Table I). Multiple post hoc group comparisons showed a significant statistical difference when comparing 6D4 with all other sites. 6D8 (5.10 ± 1.35 mm) showed no significant difference compared with 7M4 (5.64 ± 1.18 mm), and 7M4 only showed a significant difference to 6D8. 7M8 (6.93 ± 1.07 mm) showed no significant difference compared with 7D4 (7.46 ± 1.21 mm), and 7D4 showed no difference compared with 7M8 and 7D8 (8.13 ± 1.97 mm), which showed a significant difference to all other sites.

The findings of cortical bone thickness (Table II) showed the least thickness at 6D (2.0 ± 0.71 mm) and the most thickness at 7D (3.96 ± 0.57 mm). Multiple post hoc group comparisons showed a significant statistical difference when comparing the cortical bone thickness in the 3 sites (Tables III and IV). The insertion depth was found to be the least at 6D (4.98 ± 0.84 mm) and the greatest at 7D (8.40 ± 1.23 mm). The screws had the greatest proximity to the nerve at this latter site also (5.46 ± 1.63 mm). Statistical analysis showed significant main effects of both site and measurement level on buccal shelf bone width and cortical bone thickness. Also, the sites had a significant effect on the insertion depth and distance from the implant tip to the inferior alveolar nerve.

DISCUSSION

The decision on where to place an orthodontic mini implant is usually based on several factors such as biomechanics used (direct or indirect anchorage) and local anatomy. Local anatomy is usually subject to considerable individual variation, but certain insertion sites appear to exhibit reliable and reproducible patterns^{1,5,7}; with CBCT technology, we can gain information on the osseous anatomic relationships. To date, cortical bone thickness and bone width are considered important microanatomic and macroanatomic factors, respectively,

Table I. Bone depth and cortical bone thickness plus standard deviations at different insertion sites in the buccal shelf

	Insertion site						P value
	6D4	6D8	7M4	7M8	7D4	7D8	
Bone depth (mm)	3.48 ± 1.29	5.10 ± 1.35	5.64 ± 1.18	6.93 ± 1.07	7.46 ± 1.21	8.13 ± 1.97	0.000

Table II. Insertion depth and distance to the inferior alveolar nerve plus standard deviations at different insertion sites in the buccal shelf

	Insertion site			P value
	6D	7M	7D	
Insertion depth (mm)	4.98 ± 0.84	6.72 ± 0.98	8.40 ± 1.23	0.000
Distance to nerve (mm)	7.70 ± 1.10	6.30 ± 1.20	5.46 ± 1.63	0.000
Cortical bone thickness	2.0 ± 0.71	3.52 ± 0.54	3.96 ± 0.57	0.000

when planning and placing an orthodontic miniscrew.¹² Because of their importance, several studies have used CBCT in the assessment of bone quality and quantity to determine the most favorable insertion sites and to evaluate the structures at risk at various insertion sites.^{1,5,7} The mandibular buccal shelf has become a widely used insertion site for mini-implants, especially in Class III patients. Chang et al¹⁰ showed highly successful insertions (over 90%) and impressive treatment results when using implants at the buccal shelf in Asian patients.

The purpose of this study was to investigate the anatomy of the mandibular buccal shelf in white patients by assessing cortical bone thickness and overall buccal shelf bone width at 3 sites and for the latter also at 2 levels from the CEJ by using 3-dimensional (3D) images generated with CBCT technology. A second purpose of this study was to assess the final insertion depth of the miniscrew at each site and the proximity of the miniscrew to the inferior alveolar nerve in each site.

Our findings suggest that some regions of the mandibular buccal shelf in white patients might be superior to other regions. There was a clear pattern of buccal shelf bone width increasing at lower levels and more distal measurement sites. Overall, buccal shelf bone width was significantly thinner buccal to the mandibular first molar to the point that it was, on average, unable to serve as a reliable insertion site; however, individual variations as shown by the standard deviations were relatively high, and individual 3D imaging is indicated if one considers using this site in white patients. In contrast, buccal shelf bone width at the mandibular second molar showed a consistent pattern of sufficient

bone width to be considered a reliable insertion site in the mandibular buccal shelf. To be precise, the most favorable width readings were obtained from the bone buccal to the distal half of the second molar.

Cortical bone thickness is an important factor in obtaining sufficient primary stability for the miniscrew, and it correlates directly with placement torque, which can in turn influence success rates.¹³ Baumgaertel¹⁴ confirmed that cortical bone thickness is an important factor with the discussion of a widely used protocol for implant site preparation. Accordingly, it appears that knowledge of cortical bone thickness can be beneficial when selecting placement sites and performing the placement because extremes in cortical bone thickness can affect the insertion outcome. Areas of excessively thin cortical bone will not provide sufficient primary stability for maximum success, showing increased early miniscrew failures. Areas of excessively thick cortical bone, while providing excellent primary stability, will result in excessive compression of the bone, which may lead to delayed miniscrew failures. In the latter areas, predrilling is generally recommended. Our investigation showed that cortical bone thickness behaved similarly to the overall buccal shelf bone width, since the greatest thickness was found buccal to the distal aspect of the second molar. A previous study showed that mandibular buccal cortical bone thickness increased toward the distal aspect, and the buccal shelf proved no exception to this.¹ Although there was a significant statistical difference when comparing cortical bone thickness at the 3 sites, clinically they all proved to provide sufficient thickness for adequate miniscrew retention. In fact, cortical bone at all measurement sites was greater than traditionally considered desirable for miniscrew insertion, possibly tempting practitioners to use a predrilling protocol or screws with a greater yield strength such as stainless steel screws. In our clinical experience, neither is required routinely because torque levels from a drill-free protocol are regularly at physiologic levels in white patients and well below the levels at which most titanium-alloy miniscrews would fracture. We explained the desirable torque levels despite thick cortical bone with the fact that screws are not completely inserted as is discussed below (Fig 7). However, anatomic extremes are probably present in any patient population, and on

Table III. Post hoc analysis results for bone depth

Bone depth	Location	Significance
6D4	6D8	0.000
	7M4	0.000
	7M8	0.000
	7D4	0.000
	7D8	0.000
6D8	6D4	0.000
	7M4	0.160
	7M8	0.000
	7D4	0.000
	7D8	0.000
7M4	6D4	0.000
	6D8	0.160
	7M8	0.000
	7D4	0.000
	7D8	0.000
7M8	6D4	0.000
	6D8	0.000
	7M4	0.000
	7D4	0.160
	7D8	0.000
7D4	6D4	0.000
	6D8	0.000
	7M4	0.000
	7M8	0.160
	7D8	0.035
7D8	6D4	0.000
	6D8	0.000
	7M4	0.000
	7M8	0.001
	7D4	0.035

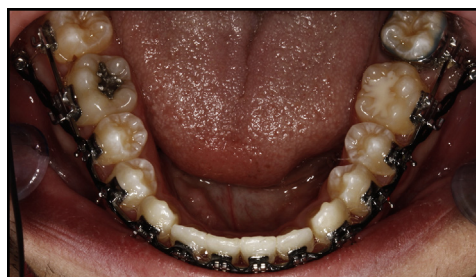occasion, excessive torque levels may be encountered at the buccal shelf. In this case, performing a cortical bone perforation should be considered an appropriate preparatory step before screw insertion.¹⁴

Since cortical bone thickness measurements are generally small, it may be advantageous to image at smaller fields of view to reduce voxel size and the impact of the partial volume effect. We relied on CBCT scans of existing patients, who were all imaged at a larger field of view. Sample size calculation, however, showed that given the size of the sample in this study, conclusions drawn even in regard to cortical bone thickness should be valid.

Knowledge of how much of the implant shank is actually retained in the bone can give practitioners a better understanding of the biomechanics of loading the miniscrew, which may impact success rates.^{15,16} To assess the final insertion depth of the miniscrews at each site, it was important to ensure that all implants were placed with the same technique. We used the recommendation of Chang et al¹⁰ to begin the insertion at the mucogingival junction and chose as the point of completion the location of the screw head 5 mm above the level of the soft tissue (Figs 5 and 6). Contrary to other recommendations from this study, we chose a screw

Table IV. Post hoc analysis results for cortical bone thickness

Cortical bone thickness	Location	Significance
6D	7M	0.000
	7D	0.000
7M	6D	0.000
	7D	0.001
7D	6D	0.000
	7M	0.001

**Fig 7.** Miniscrews placed at the buccal shelf using anatomic guidelines from this study.

length of only 10 mm. To not create any confusion for readers, we used a different screw design than that of Chang et al with a transmucosal collar that added 2 mm of additional screw length between shank and head, leading to a similar overall screw length. This insertion technique coupled with the proper implant length would again ensure a final screw position similar to that recommended by Chang et al, which would bring the screw head close to the level of the archwire. It may very well be the case, however, that even shorter screws could be used at this site as was highlighted by Park¹⁷ over a decade ago. Not focusing on the actual buccal shelf, he placed 6-mm long screws angled vertically buccal to the mandibular molars.

To accurately simulate a clinical insertion, the scanned models of the mandibular arch were matched to the CBCT scan, which then showed a precise outline of the soft tissue. Insertion depth increased toward the posterior with the greatest measurement again at the distal aspect of the second molar. As described by Shantavasinkul et al,¹⁵ this should create the most favorable loading mechanics of the 3 investigated insertion sites in the buccal shelf.

Understanding the location of anatomic structures at various sites when placing orthodontic miniscrews is important to avoid undesired side effects or damage to sensitive structures. Previous studies evaluated risk of damage of anatomic structures such as roots and maxillary sinus.^{7,18} To provide a better 3D understanding of

the structures associated with the buccal shelf, we evaluated the relationship of the inferior alveolar nerve to the miniscrew. The ability to digitally trace the nerve (Fig 3) should help the clinician during insertion and decrease the probability of violating the nerve. We found that the screws had the greatest proximity to the nerve at the D7 site. However, even here, an ample safe distance was present to be considered safe.

On average, it can be expected that, within the limitations of this study, the most favorable overall anatomic relationships for mandibular buccal shelf orthodontic miniscrew placement in white patients are at the level of the distobuccal cusp of the second molar. This site is also clinically accessible in most patients with a straight driver that facilitates placement. In patients with limited mouth opening, the distal location of the insertion site can create difficulty to access the site at the best angle; then a contra-angle insertion instrument should be selected for better access. However, with placement, it is important to consider the potential proximity to the inferior alveolar nerve and to keep in mind that averages are a good first step for identifying favorable insertion sites, but they do not replace individual diagnosis and treatment planning.

Ethnicity does appear to play a role in the morphology of the buccal shelf because we found a smaller suitable insertion area than those in other studies that were conducted on Asian patients. This may be due to the more brachycephalic facial pattern in that group or other factors prevalent in Asian patients and missing in white patients. Taking this thought 1 step further, an interesting area of future research would be to see whether buccal shelf anatomy may be different among different malocclusions or whether there is a sex influence, another factor not considered in this study. In addition, this study should be followed by clinical implementations and outcome assessments of the insertion site and technique outlined in this article.

CONCLUSIONS

The mandibular buccal shelf is a suitable site for orthodontic miniscrews in white patients. Within the limitations of this study, cortical bone thickness, buccal shelf bone width, and insertion depth in this patient population appear to be the most favorable sites buccal to the second molar. Insertions buccal to the first molar will require 3D imaging or at least digital palpation to clarify whether the patient has sufficient bone, because, on average, this site appears to be unsuitable in white patients.

REFERENCES

1. Baumgaertel S, Hans MG. Buccal cortical bone thickness for mini-implant placement. *Am J Orthod Dentofacial Orthop* 2009;136:230-5.
2. Park HS, Kwon OW, Sung JH. Nonextraction treatment of an open bite with microscrew implants anchorage. *Am J Orthod Dentofacial Orthop* 2006;130:391-402.
3. Roth A, Yildirim M, Diedrich P. Forced eruption with microscrew anchorage for preprosthetic leveling of the gingival margin. *J Orofac Orthop* 2004;65:513-9.
4. Park YC, Choi YJ, Choi NC, Lee JS. Esthetic segmental retraction of maxillary anterior teeth with a palatal appliance and orthodontic mini-implants. *Am J Orthod Dentofacial Orthop* 2007;131:537-44.
5. Baumgaertel S. Quantitative investigation of palatal bone width and cortical bone thickness for mini-implant placement in adults. *Am J Orthod Dentofacial Orthop* 2009;136:104-8.
6. Xun C, Zeng X, Wang X. Microscrew anchorage in skeletal anterior open-bite treatment. *Angle Orthod* 2007;77:47-56.
7. Baumgaertel S. Cortical bone thickness and bone width of the posterior palatal alveolar process for mini-implant insertion in adults. *Am J Orthod Dentofacial Orthop* 2011;140:806-11.
8. Jing Y, Han X, Guo Y, Li J, Bai D. Nonsurgical correction of a Class III malocclusion in an adult by miniscrew-assisted mandibular dentition distalization. *Am J Orthod Dentofacial Orthop* 2013;143:877-87.
9. Chen K, Cao Y. Class III malocclusion treated with distalization of the mandibular dentition with miniscrew anchorage: a 2-year follow-up. *Am J Orthod Dentofacial Orthop* 2015;148:1043-53.
10. Chang C, Sean SY, Liu W, Roberts WE. Primary failure rate for 1680 extra-alveolar mandibular buccal shelf mini-screws placed in movable mucosa or attached gingiva. *Angle Orthod* 2015;85:905-10.
11. Chang C, Huang C, Roberts WE. 3D cortical bone anatomy of the mandibular buccal shelf: a CBCT study to define sites for extra-alveolar bone screws to treat Class III malocclusion. *Int J Orthod Implantol* 2016;41:74-82.
12. Baumgaertel S. Planning and placing temporary anchorage devices (TADs) with the aid of CBCT imaging. In: Kapila S, editor. *Cone beam computed tomography in orthodontics: indications, insights, and innovations*. Hoboken, NJ: Wiley-Blackwell; 2014. p. 411-26.
13. Wilmes B, Rademacher C, Olthoff G, Drescher D. Parameters affecting primary stability of orthodontic mini-implants. *J Orofac Orthop* 2006;67:162-74.
14. Baumgaertel S. Predrilling of the implant site—is it necessary for orthodontic mini-implants? *Am J Orthod Dentofacial Orthop* 2010;137:825-9.
15. Shantavasinkul P, Akkus O, Palomo JM, Baumgaertel S. Surface strain distribution of orthodontic miniscrews under load. *Am J Orthod Dentofacial Orthop* 2016;150:444-50.
16. Büchter A, Wiechmann D, Koerdt S, Wiesmann HP, Piffko J, Meyer U. Load-related implant reaction of mini-implants used for orthodontic anchorage. *Clin Oral Implants Res* 2005;16:473-9.
17. Park HS. An anatomical study using CT images for the implantation of micro-implants. *Korean J Orthod* 2002;32:435-41.
18. Min KI, Kim SC, Kang KH, Choc JH. Root proximity and cortical bone thickness effects on the success rate of orthodontic micro-implants using cone beam computed tomography. *Angle Orthod* 2012;82:1014-21.