

# Cortical bone thickness and bone depth of the posterior palatal alveolar process for mini-implant insertion in adults

Sebastian Baumgaertel  
Cleveland, Ohio

**Introduction:** Cortical bone thickness and bone depth are important factors when placing an orthodontic mini-implant. The objective of this study was to investigate both variables for the palatal alveolar process. **Methods:** Thirty dry human skulls were imaged by using cone-beam computed tomography technology. Two-dimensional slices bisecting the posterior interdental sites were generated, and cortical bone thickness and bone depth were measured at 4, 8, and 12 mm from the alveolar crest. Two-way repeated measures analysis of variance (ANOVA) was used to analyze the measurements. **Results:** Interdental site and measurement level had a significant impact on both cortical bone thickness and bone depth. Cortical bone thickness was typically greatest at the 8-mm measurement level and more anterior interdental sites. Bone depth decreased with higher measurement levels and was smallest at the most posterior-superior measurement points. **Conclusions:** Cortical bone thickness and bone depth of the palatal alveolar process are, on average, favorable for the insertion of orthodontic mini-implants; however, some sites should routinely be avoided to prevent damage to the maxillary sinus unless 3-dimensional imaging is available. (*Am J Orthod Dentofacial Orthop* 2011;140:806-11)

It is generally accepted that anatomic factors should be included in the planning for an orthodontic mini-implant (OMI).<sup>1</sup> Multiple anatomic factors are important for the long-term success of an OMI (Table 1). Of those, the group of osseous factors is of particular interest, since it is the bone that ultimately is responsible for the anchorage capacity of the OMI. It appears that the majority of anchorage capacity results from the quality and quantity of cortical bone, whereas cancellous bone probably contributes little to the stability of OMI.<sup>2-4</sup>

Another important factor to determine the suitability of a potential insertion site is overall bone availability or bone depth. There should be enough bone to place an OMI of a certain length without contralateral perforation or perforation into the maxillary sinus or the nasal cavity, thus creating an oral-antral connection.

Because of their importance, cortical bone thickness and bone depth have been investigated thoroughly for most OMI insertion sites.<sup>5-12</sup> However, to date, no comprehensive data exist for a clinically very useful site: the palatal aspect of the posterior alveolar process (Fig 1).

The purpose of this study was therefore to investigate cortical bone thickness and bone depth of the posterior palatal alveolar process.

## MATERIAL AND METHODS

The sample consisted of 30 dry skulls of white adults from the Hamman-Todd Osteological Collection at the Cleveland Museum of Natural History, Cleveland, Ohio (26 male, 4 female; average age,  $31.2 \pm 10.6$  years; range, 19-50 years). Inclusion criteria were intact maxillary jaws with no more than a 1 tooth missing per quadrant (excluding third molars) and without evidence of any preexisting craniofacial dysmorphology (determined by inspection or listed in the health history on file, if present).

The skulls were imaged with a state-of-the-art cone-beam computed tomography unit (CB Mercuray, Hitachi Medical, Tokyo, Japan) at a 9-in field of view, 100 kVp, and 10 mA. The resulting voxel size was 0.28 mm. The software used was Accurex (Cybermed, Seoul, Korea).

Six interdental sites on each side were surveyed in this study, from the mesial aspect of the maxillary canine to

Associate clinical professor, Department of Orthodontics, School of Dental Medicine, Case Western Reserve University, Cleveland, Ohio.

The author reports no commercial, proprietary, or financial interest in the products or companies described in this article.

Reprint requests to: Sebastian Baumgaertel, Case Western Reserve University, School of Dental Medicine, Department of Orthodontics, 10900 Euclid Ave, Cleveland, OH 44106; e-mail, [sxb155@case.edu](mailto:sxb155@case.edu).

Submitted, January 2010; revised and accepted, May 2011.

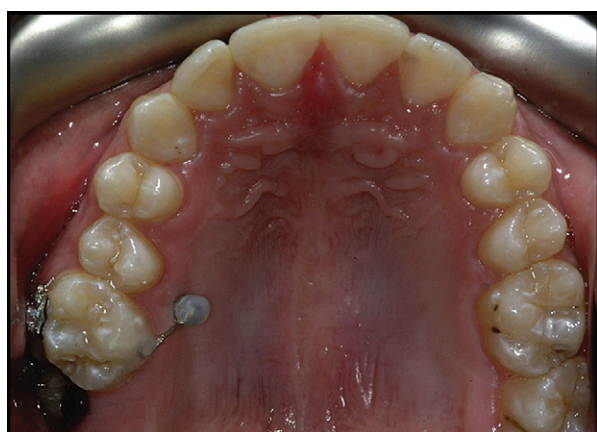
0889-5406/\$36.00

Copyright © 2011 by the American Association of Orthodontists.

doi:10.1016/j.ajodo.2011.05.020

**Table I.** Important anatomic factors for OMI planning

Osseous factors	Soft-tissue factors	Vulnerable structures
Cortical bone thickness	Quality (mucosa vs attached gingiva)	Roots
Bone depth	Tissue thickness	Nerves
Bone mineral density	Mobility	Blood vessels
	Tension (frenum proximity)	Sinus/nasal cavity



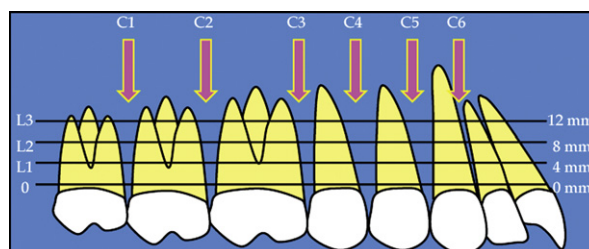
**Fig 1.** Clinical example of an OMI at the posterior palatal alveolar process.

the distal aspect of the maxillary second molar, and measurements were taken at 3 levels (Fig 2), creating 18 measurement sites.

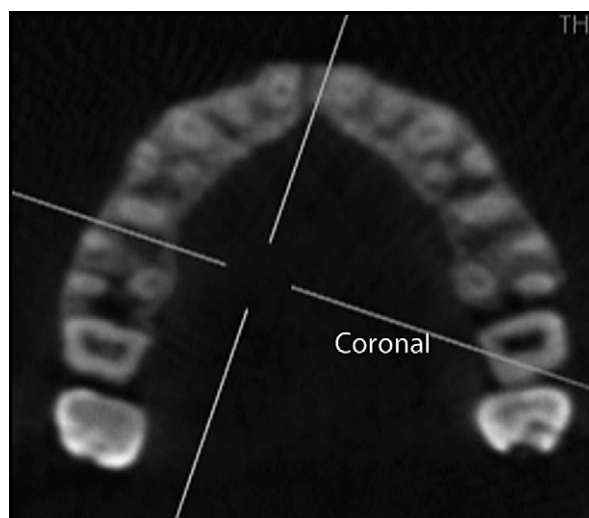
The images were oriented as follows.

1. By using the sagittal view, the axial plane was oriented parallel to the palatal plane and adjusted to approximately midroot level.
2. By using the axial view, the coronal plane was adjusted to section through the alveolar process at 90° to the palatal bone surface bisecting the interdental site (Fig 3).
3. A clear section of the alveolar process appeared as a result in the coronal view, on which measurements of cortical bone thickness and bone depth were created at 4, 8, and 12 mm (levels 1-3) from the alveolar crest, and again at 90° to the surface of the bone (Fig 4). The alveolar crest level was defined as 1 mm apical to the cemento-enamel junction of the adjacent teeth.

Cortical bone thickness was defined as the buccolingual dimension of the palatal cortical bone measured perpendicular to the bone surface from its outer surface to the demarcation of cortical and cancellous bones



**Fig 2.** Diagrammatic illustration of the measurement levels (L), interdental sites (C), and measurement sites.



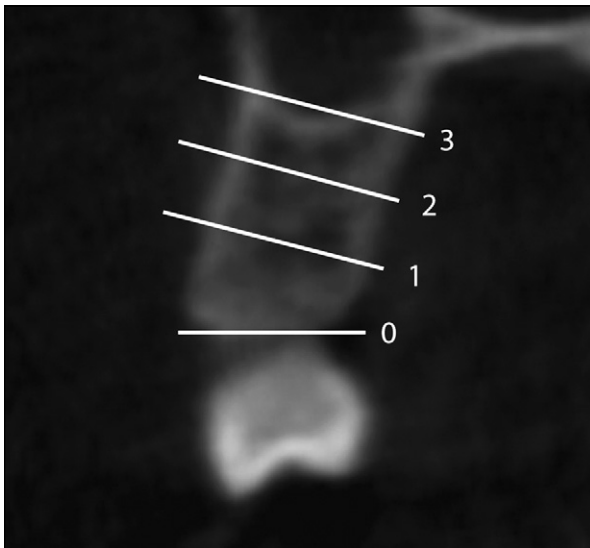
**Fig 3.** Axial slice of alveolar process illustrating the interdental sites and the orientation of the coronal slice at the site being surveyed.

(Fig 5). The cutoff lines between bone and air, and cortical bone and cancellous bones, were determined visually with gray-white discrimination and drawn manually as described by Baumgaertel.<sup>11</sup>

Bone depth was defined as the total amount of bone available in the buccolingual direction measured from the palatal surface of the alveolar process to either the buccal surface of the alveolar process or the inner surface of the maxillary sinus, depending on the measurement level. Measurements were also taken at 90° to the palatal bone surface (Fig 5).

**Statistical analysis**

SPSS software (version 17.0; SPSS, Chicago, Ill) was used for all statistical analyses, and significance levels for all tests were set at  $P \leq 0.05$ . Preliminary data analysis suggested normal frequency distribution (Shapiro-Wilk test) and equality of variances (Levene’s test). Intraclass correlation was used to determine the reliability of the



**Fig 4.** Coronal slice illustrating the measurement levels.

measurement method: on 10 slices on 10 skulls, all measurements (cortical bone thickness and bone depth) were repeated twice, 6 months apart. The paired Student *t* test was used for additional preliminary data analysis to test for differences between the left and right sides. No statistically significant differences were found, so the data were pooled. Two-way repeated measures analysis of variance (ANOVA) was used to evaluate the influence of interdental site and measurement level on cortical bone thickness and bone depth.

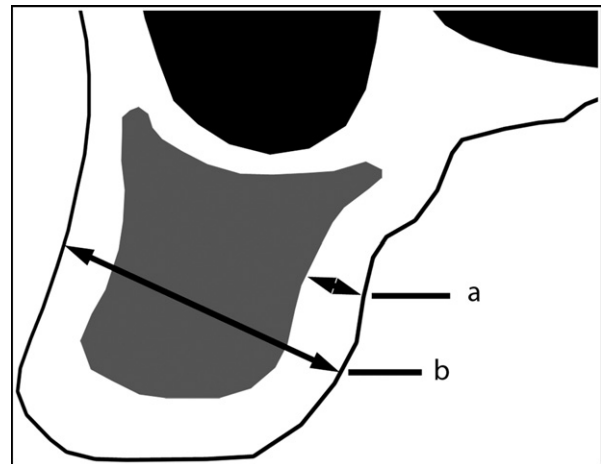
## RESULTS

Intraclass correlations ( $r = 0.88$  for cortical bone thickness;  $r = 0.99$  for bone depth) suggested high reliability for both measurements.

Cortical bone thickness was generally thinnest at level 3 ( $1.17 \pm 0.33$  mm) and thickest at level 2 ( $1.26 \pm 0.30$  mm). The interdental site with the least overall cortical bone thickness was located distal to the second molar ( $1.06 \pm 0.26$  mm), and the interdental site with the greatest overall cortical bone thickness was located between the canine and the first premolar ( $1.33 \pm 0.32$  mm). Cortical bone thickness ranged from a mean of 1.0 mm ( $\pm 0.27$  mm) at contact 2, level 3 to a mean of 1.38 mm ( $\pm 0.26$  mm) at contact 4, level 2 (Table II).

Statistical analysis showed significant main effects of both interdental site and measurement level, and a significant interaction of interdental site and measurement level.

The findings for bone depth were different in that, relative to the interdental site, it was smallest in the anterior between the lateral incisor and the canine ( $7.6 \pm$



**Fig 5.** Schematic illustrating cortical bone thickness measurements (a) and bone depth measurements (b).

1.86 mm) and greatest in the posterior distal to the second molar ( $9.84 \pm 4.94$  mm). Relative to the measurement level, bone depth was smallest at level 3 ( $7.59 \pm 4.39$  mm) and greatest at level 1 ( $10.04 \pm 2.77$  mm). More specifically, it ranged from 5.29 mm ( $\pm 5.00$  mm) at contact 2, level 3 to 12.62 mm ( $\pm 2.68$  mm) at contact 1, level 1. However, standard deviations as a measure of dispersion were generally high for bone depth (Table III).

Both interdental site and measurement level, and their interactions, had a statistically significant impact on bone depth.

## DISCUSSION

The purpose of this study was to investigate the anatomy of the palatal alveolar process by using 3-dimensional (3D) images of dry skulls generated with cone-beam computed tomography technology. This was an indirect, nondestructive method. To properly interpret the results, it is important to understand the reliability and accuracy of the chosen method. This study included a reliability assessment that indicated excellent reliability. The accuracy of measurements generated with cone-beam computed tomography is typically found to be high but might be limited by the size of the smallest unit of the digital 3D images: the voxels—0.28 mm in this study. The smaller the object to be measured, the greater the likelihood that voxel size will affect accuracy. Tsutsumi et al<sup>13</sup> found that the object dimensions should be at least 3 to 4 times the voxel size to maintain high accuracy. This requirement, while not presenting a problem for bone depth measurements, was also fulfilled for cortical bone thickness, considering that the average cortical bone thickness in this study

**Table II.** Cortical bone thickness for levels (L1-L3), interdental sites (C1-C6), and specific measurement sites (C1L1-C6L3) in millimeters (n = 60)

	Mean	SD	Minimum	Maximum
Measurement level				
L1	1.2	0.30	0.42	2.63
L2	1.26	0.30	0.54	2.13
L3	1.17	0.33	0.3	2.2
Interdental site				
C1	1.06	0.27	0.3	1.88
C2	1.11	0.3	0.4	2.13
C3	1.16	0.28	0.55	1.9
C4	1.28	0.29	0.49	2.16
C5	1.33	0.32	0.63	2.63
C6	1.3	0.31	0.42	2.13
Measurement site				
C1L1	1.1	0.23	0.68	1.58
C1L2	1.1	0.27	0.57	1.88
C1L3	1.0	0.28	0.30	1.75
C2L1	1.09	0.28	0.43	1.74
C2L2	1.25	0.31	0.54	2.13
C2L3	1.0	0.27	0.40	1.80
C3L1	1.14	0.29	0.55	1.80
C3L2	1.11	0.24	0.57	1.60
C3L3	1.23	0.30	0.67	1.90
C4L1	1.22	0.26	0.70	1.80
C4L2	1.38	0.26	0.79	1.82
C4L3	1.22	0.31	0.49	2.16
C5L1	1.35	0.33	0.76	2.63
C5L2	1.39	0.29	0.75	1.90
C5L3	1.27	0.34	0.63	2.20
C6L1	1.29	0.33	0.42	2.13
C6L2	1.34	0.29	0.63	1.94
C6L3	1.28	0.31	0.60	1.97

was approximately 1.2 mm. However, particularly in areas of extremely thin cortical bone, measurements might suffer from some inaccuracy; this might be the greatest limitation of this study. This, however, should not reach clinical relevance.

The findings of this study suggest that, for the palatal aspect of the alveolar process, both cortical bone thickness and bone depth are different depending on the measurement site location, in both the anteroposterior and coronal-apical directions. Therefore, apparently in this anatomic region, not all potential interdental sites are created equal.

Compared with cancellous bone, cortical bone has a higher modulus of elasticity, which makes it stronger and more resistant to deformation.<sup>14</sup> This is probably the reason for the superior anchorage quality. It thus comes as no surprise that a strong relationship is suggested between cortical bone thickness and primary implant stability, for both dental implants and OMI.<sup>2,3,15</sup> This is an important relationship that should be considered in the planning of an OMI, because,

**Table III.** Bone depth for measurement levels (L1-L3), interdental sites (C1-C6), and specific measurement sites (C1L1-C6L3) in millimeters (n = 60)

	Mean	SD	Minimum	Maximum
Measurement level				
L1	10.04	2.77	1.11	17.48
L2	9.39	3.38	0.8	16.03
L3	7.59	4.39	0.3	17.77
Interdental site				
C1	9.84	4.94	0.3	17.77
C2	8.91	5.29	0.4	16.03
C3	8.89	3.86	0.9	15.42
C4	9.15	2.39	0.6	15.25
C5	9.68	1.96	4.45	16.8
C6	7.6	1.86	1.41	14.07
Measurement site				
C1L1	12.62	2.68	1.80	17.48
C1L2	11.03	3.86	1.00	15.90
C1L3	5.89	5.17	0.30	17.77
C2L1	12.15	2.85	3.40	15.90
C2L2	9.30	5.27	0.80	16.03
C2L3	5.29	5.00	0.40	15.70
C3L1	10.41	1.96	2.10	13.94
C3L2	9.83	3.18	1.90	15.42
C3L3	6.43	4.67	0.90	15.36
C4L1	8.99	1.47	1.11	12.12
C4L2	9.30	2.07	1.49	13.20
C4L3	9.14	3.29	0.60	15.25
C5L1	9.08	1.17	5.50	11.79
C5L2	9.60	1.50	6.81	12.84
C5L3	10.35	2.69	4.45	16.80
C6L1	7.02	1.22	1.41	11.77
C6L2	7.30	1.63	1.51	11.83
C6L3	8.47	2.27	1.71	14.07

without primary stability, adequate secondary stability cannot be achieved.<sup>16</sup> Motoyoshi et al<sup>17</sup> therefore recommended that OMI should not be placed in areas with less than 1 mm of cortical bone thickness.

The other factor that might determine secondary stability is the host response to the OMI. Here, an insertion with excessive torque and compression of the surrounding tissues could cause sufficient trauma to adversely affect the healing response around the implant.<sup>18</sup> Ueda et al<sup>19</sup> showed that excessive compression of the peri-implant bone can cause compression osteonecrosis and result in resorptive remodeling rather than the much-desired depositional healing response. Because predrilling can reduce insertion torque, a strong case can be made for perforating the cortical bone at sites of excessive cortical bone thickness.<sup>20</sup> Baumgaertel<sup>21</sup> recommended predrilling in areas where cortical bone thickness exceeds 1.5 mm.

By taking into consideration the above, it appears that all investigated insertion sites fulfilled the criteria of Motoyoshi et al<sup>17</sup> for implant site selection and

that, on average, predrilling is not necessary according to the guidelines of Baumgaertel<sup>21</sup> to achieve proper insertion torque levels.

The other dependent variable in this study was bone depth, an important factor when considering the limits of the available osseous space. When an OMI is inserted on the palatal aspect of the alveolar process, the osseous space is limited to the mesial and distal aspects by the position of the adjacent roots and in a buccal direction by either the buccal cortical plate or the maxillary sinus.<sup>6</sup> This latter dimension is bone depth, which was investigated in this study.

Büchter et al<sup>22</sup> observed excessive tipping moments at the cortical level if the distance from the bone surface to the point of force application is too large. This could impact the success rates of OMIs. Therefore, if possible, an OMI should always be seated completely. Recently, Pickard et al<sup>23</sup> found that the most stable OMI orientation was in the direction of force application, followed by an angle of 90° to the bone surface. Because the former is not feasible for interradiolar sites, an OMI should be placed perpendicular to the surface of the bone. Because the shortest commercially available OMI is currently 6 mm long, and perforation into the sinus should be avoided to prevent any undesirable side effects, the minimal acceptable bone depth for the insertion of an OMI should be more than 6 mm.<sup>10</sup>

In this study, not all sites fulfilled this criterion: on average, contact 1, level 3 and contact 2, level 3, the most posterior-superior sites investigated, had less than the required 6 mm of bone depth. This general area is critical for fundamental anatomic reasons as well as typically being where the greater palatine foramen can be found. All other sites formally fulfilled the minimal requirement of more than 6 mm of bone depth; however, the entire level 3 had a marked increase in the standard deviation, indicating strong variability of the measurements, probably reflecting the variable anatomy of the maxillary sinus. Level 1 had the lowest standard deviation and thus seemed to be most predictable in terms of bone depth.

On average, there is ample bone depth at levels 1 and 2, and routine insertion of OMIs should take place here. Unfortunately, individual variations for bone depth measurements are generally high because of the great variability of the maxillary sinus. Avoiding sinus perforation might therefore require 3D imaging of each patient.

## CONCLUSIONS

The palatal aspect of the alveolar process can be a suitable site for OMIs, since both cortical bone thickness and bone depth appear to be favorable, except in

the posterior-superior region. However, individual variations for bone depth were large. This might require individual 3D imaging to prevent perforation of the maxillary sinus at some sites.

## REFERENCES

1. Baumgaertel S, Razavi MR, Hans MG. Mini-implant anchorage for the orthodontic practitioner. *Am J Orthod Dentofacial Orthop* 2008;133:621-7.
2. Wilmes B, Rademacher C, Olthoff G, Drescher D. Parameters affecting primary stability of orthodontic mini-implants. *J Orofac Orthop* 2006;67:162-74.
3. Motoyoshi M, Yoshida T, Ono A, Shimizu N. Effect of cortical bone thickness and implant placement torque on stability of orthodontic mini-implants. *Int J Oral Maxillofac Implants* 2007;22:779-84.
4. Chun YS, Lim WH. Bone density at interradiolar sites: implications for orthodontic mini-implant placement. *Orthod Craniofac Res* 2009;12:25-32.
5. Henriksen B, Bavitz B, Kelly B, Harn SD. Evaluation of bone thickness in the anterior hard palate relative to midsagittal orthodontic implants. *Int J Oral Maxillofac Implants* 2003;18:578-81.
6. Poggio PM, Incorvati C, Velo S, Carano A. "Safe zones": a guide for miniscrew positioning in the maxillary and mandibular arch. *Angle Orthod* 2006;76:191-7.
7. Kim HJ, Yun HS, Park HD, Kim DH, Park YC. Soft-tissue and cortical-bone thickness at orthodontic implant sites. *Am J Orthod Dentofacial Orthop* 2006;130:177-82.
8. Kang S, Lee SJ, Ahn SJ, Heo MS, Kim TW. Bone thickness of the palate for orthodontic mini-implant anchorage in adults. *Am J Orthod Dentofacial Orthop* 2007;131(4 Suppl):S74-81.
9. Kim SH, Yoon HG, Choi YS, Hwang EH, Kook YA, Nelson G. Evaluation of interdental space of the maxillary posterior area for orthodontic mini-implants with cone-beam computed tomography. *Am J Orthod Dentofacial Orthop* 2009;135:635-41.
10. Baumgaertel S, Hans MG. Assessment of infrazygomatic bone depth for mini-screw insertion. *Clin Oral Implants Res* 2009;20:638-42.
11. Baumgaertel S. Quantitative investigation of palatal bone depth and cortical bone thickness for mini-implant placement in adults. *Am J Orthod Dentofacial Orthop* 2009;136:104-8.
12. Baumgaertel S, Hans MG. Buccal cortical bone thickness for mini-implant placement. *Am J Orthod Dentofacial Orthop* 2009;136:230-5.
13. Tsutsumi K, Chikui T, Okamura K, Yoshiura K. Accuracy of linear measurement and the measurement limits of thin objects with cone beam computed tomography: effects of measurement directions and of phantom locations in the fields of view. *Int J Oral Maxillofac Implants* 2011;26:91-100.
14. Holmes DC, Loftus JT. Influence of bone quality on stress distribution for endosseous implants. *J Oral Implantol* 1997;23:104-11.
15. Miyamoto I, Tsuboi Y, Wada E, Suwa H, Iizuka T. Influence of cortical bone thickness and implant length on implant stability at the time of surgery—clinical, prospective, biomechanical, and imaging study. *Bone* 2005;37:776-80.
16. Lioubavina-Hack N, Lang NP, Karring T. Significance of primary stability for osseointegration of dental implants. *Clin Oral Implants Res* 2006;17:244-50.
17. Motoyoshi M, Inaba M, Ono A, Ueno S, Shimizu N. The effect of cortical bone thickness on the stability of orthodontic mini-implants and on the stress distribution in surrounding bone. *Int J Oral Maxillofac Surg* 2009;38:13-8.

18. O'Sullivan D, Sennerby L, Meredith N. Influence of implant taper on the primary and secondary stability of osseointegrated titanium implants. *Clin Oral Implants Res* 2004;15:474-80.
19. Ueda M, Matsuki M, Jacobsson M, Tjellstrom A. Relationship between insertion torque and removal torque analyzed in fresh temporal bone. *Int J Oral Maxillofac Implants* 1991;6:442-7.
20. Heidemann W, Gerlach KL, Gröbel KH, Köllner HG. Influence of different pilot hole sizes on torque measurements and pullout analysis of osteosynthesis screws. *J Craniomaxillofac Surg* 1998;26:50-5.
21. Baumgaertel S. Predrilling of the implant site: is it necessary for orthodontic mini-implants? *Am J Orthod Dentofacial Orthop* 2010;137:825-9.
22. Büchter A, Wiechmann D, Koerdt S, Wiesmann HP, Piffko J, Meyer U. Load-related implant reaction of mini-implants used for orthodontic anchorage. *Clin Oral Implants Res* 2005;16:473-9.
23. Pickard MB, Dechow P, Rossouw PE, Buschang PH. Effects of miniscrew orientation on implant stability and resistance to failure. *Am J Orthod Dentofacial Orthop* 2010;137:91-9.